

Sub-Tenon's triamcinolone for post-partum Purtscher's-like retinopathy

Jeffrey Olson
Behnaz Rouhani
Naresh Mandava

Rocky Mountain Lions Eye Institute,
University of Colorado Health
Sciences Center, Department of
Ophthalmology, Denver, CO, USA

Abstract: Sub-Tenon's injection of triamcinolone was performed in the right eye of a patient with bilateral Purtscher's-like retinopathy after childbirth. The response of macular edema to local triamcinolone was investigated with optical coherence tomography. Five weeks following the injection, optical coherence tomography improvement was seen following unilateral sub-Tenon's triamcinolone injection.

Keywords: Purtscher's-like retinopathy; triamcinolone; post-partum decreased vision

Introduction

First described in 1910, Purtscher's retinopathy is seen in severely traumatized patients and is characterized by sudden visual loss (Purtscher 1912). The characteristic ophthalmoscopic findings are multiple areas scattered throughout the posterior pole of superficial retinal whitening, which appear as focal areas of retinal arteriolar occlusion on fluorescein angiography (Grass 1997). Similar clinical findings have been reported in association with childbirth (Blodi et al 1990; Shaikh et al 2003), and have been termed Purtscher's-like retinopathy. The visual prognosis in Purtscher's-like retinopathy after childbirth is guarded, and to date, there is no definitive treatment. However, there are encouraging reports of visual recovery in patients with Purtscher's retinopathy receiving high dose intravenous corticosteroid therapy (Atabay et al 2003).

We report a patient with Purtscher's-like retinopathy following childbirth who received a sub-Tenon's capsule injection of triamcinolone with subsequent increase in visual acuity and decrease in retinal swelling.

Case report

Ten days after an emergent caesarian section for severe preeclampsia, Rh immunization, and fetal anemia, a 24 year-old primigravida primiparus patient presented with complaints of decreased vision in both eyes, right greater than left. There were no other systemic abnormalities such as elevated liver enzymes, low platelets or other hematologic abnormalities. Her initial vision was 20/200 OD, and 20/30 OS. Pupillary examination disclosed a 1+ relative afferent papillary defect in the right eye. Intraocular pressures were normal bilaterally, as was biomicroscopic examination of her anterior segment. Dilated fundus examination revealed bilateral Purtscher's-like retinopathy (Figures 1a, 1b), with widespread areas of macular ischemia and edema, as confirmed by optical coherence tomography (Figures 2a, 2b). Of note are the superficial areas of high intensity signal, indicative of retinal ischemia. The central thickness in the right eye was 272 microns, and in the left 239 microns. Fluorescein angiography was deferred as the patient was breast-feeding.

A sub-Tenon's injection of 0.5 cc of triamcinolone (40 mg/cc) was given in the right eye on day 15 after delivery. At one week following the injection, her visual acuity was unchanged and her intraocular pressure was normal. Five weeks following

Correspondence: Jeffrey Olson
1675 Ursula, Aurora Colorado 80045,
USA
Tel +1 720 848 2500
Fax +1 720 848 5079
Email jeffrey.olson@uchsc.edu

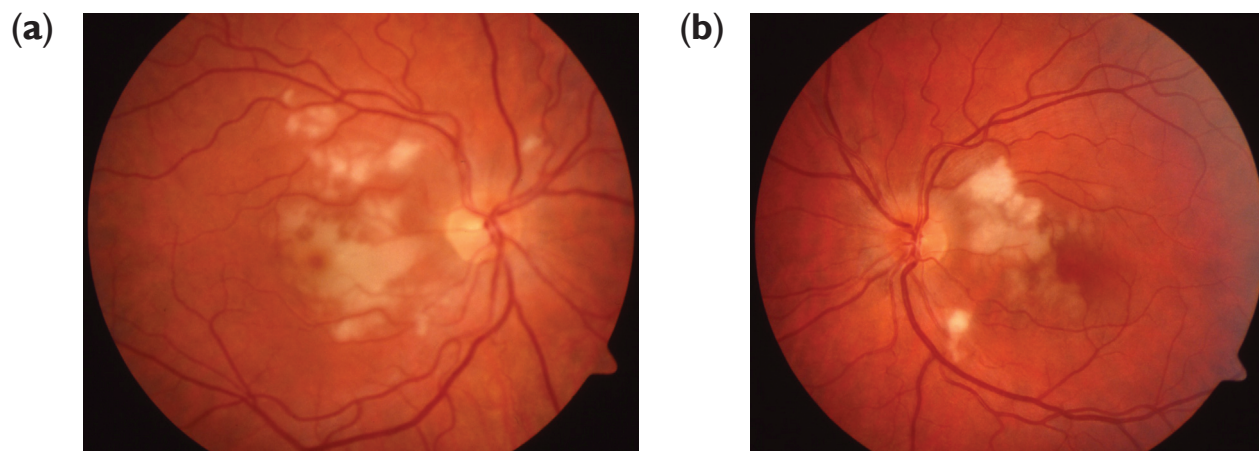


Figure 1 Fundus photographs of right (a) and left eye (b), demonstrating widespread areas of macular ischemia and edema.

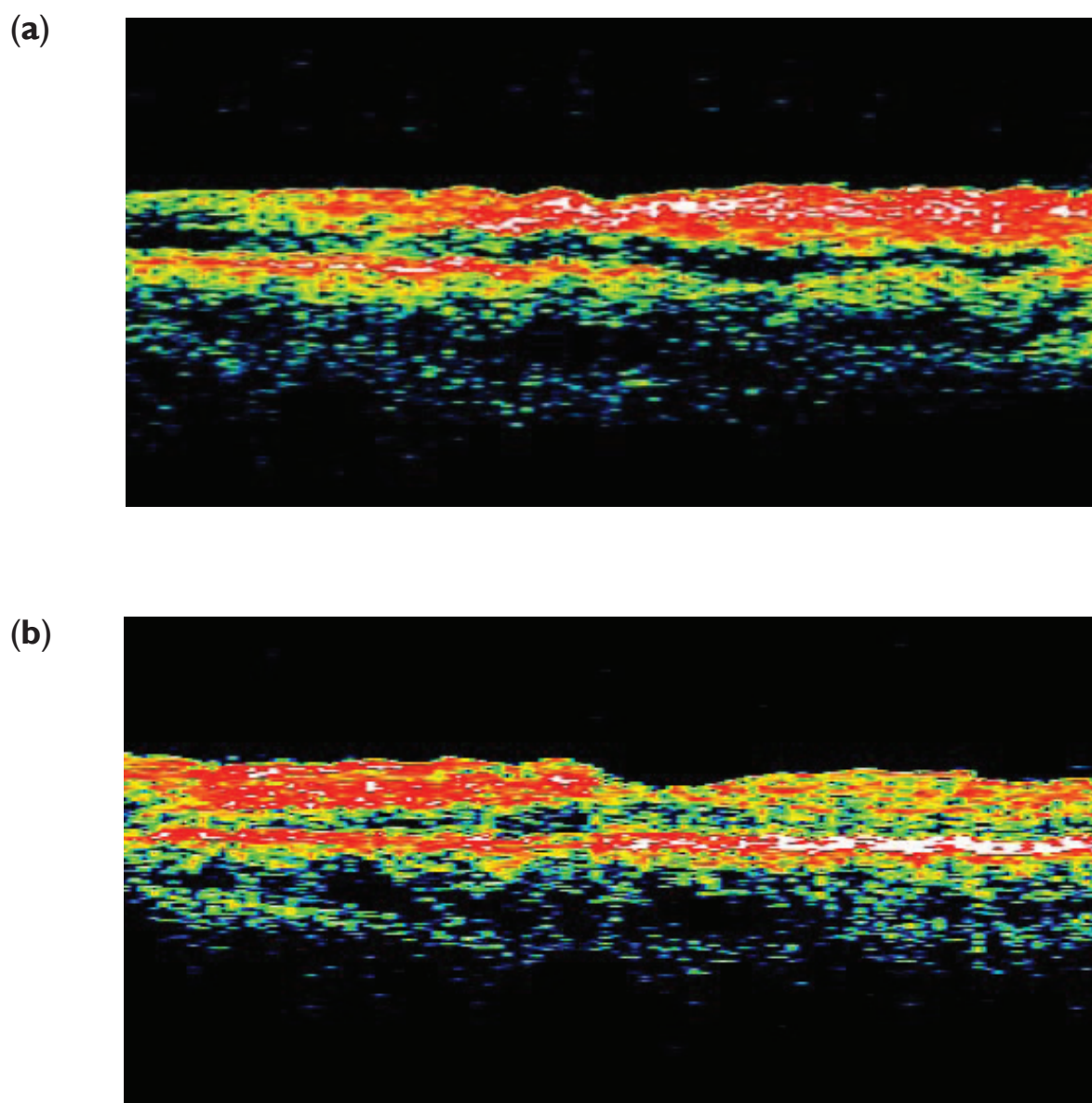


Figure 2 Optical coherence tomography of right (a) and left eye (b), shows superficial areas of high reflectivity, indicative of ischemia.

the injection, the patient was visited. She noted a marked improvement in the vision in her right eye. On examination a her acuity had improved to 20/60 in the right eye and 20/20 in the left, with normal intraocular pressures. Her fundus examination showed marked improvement, with most of the superficial ischemic areas resolving. Repeat optical coherence tomography in both eyes (Figures 3a, 3b) demonstrated a reduction in the edema of the right eye by 30% from baseline, whereas the left, untreated eye showed a reduction in swelling of 14%. Intraocular pressures remained normal, and there was no evidence of cataract formation. She was followed up for 6 months after injection. Her visual acuity remained 20/60 in the right eye and 20/20 in the left eye.

Discussion

Nearly a century ago Otmar Purtscher described a case of visual loss in a severely traumatized patient whose exam showed multiple superficial retinal hemorrhages and white patches throughout the posterior pole. Since that time, similar findings have been associated with other conditions including compressive chest injuries, acute pancreatitis, fat embolism, retro-bulbar anesthesia, connective tissue diseases (Grass 1997), and childbirth (Blodi et al 1990; Shaikh et al 2003).

The pathogenesis of Purtscher's-like retinopathy post-partum is unknown, but may be related to arteriolar obstruction by complement induced leukoemboli produced during

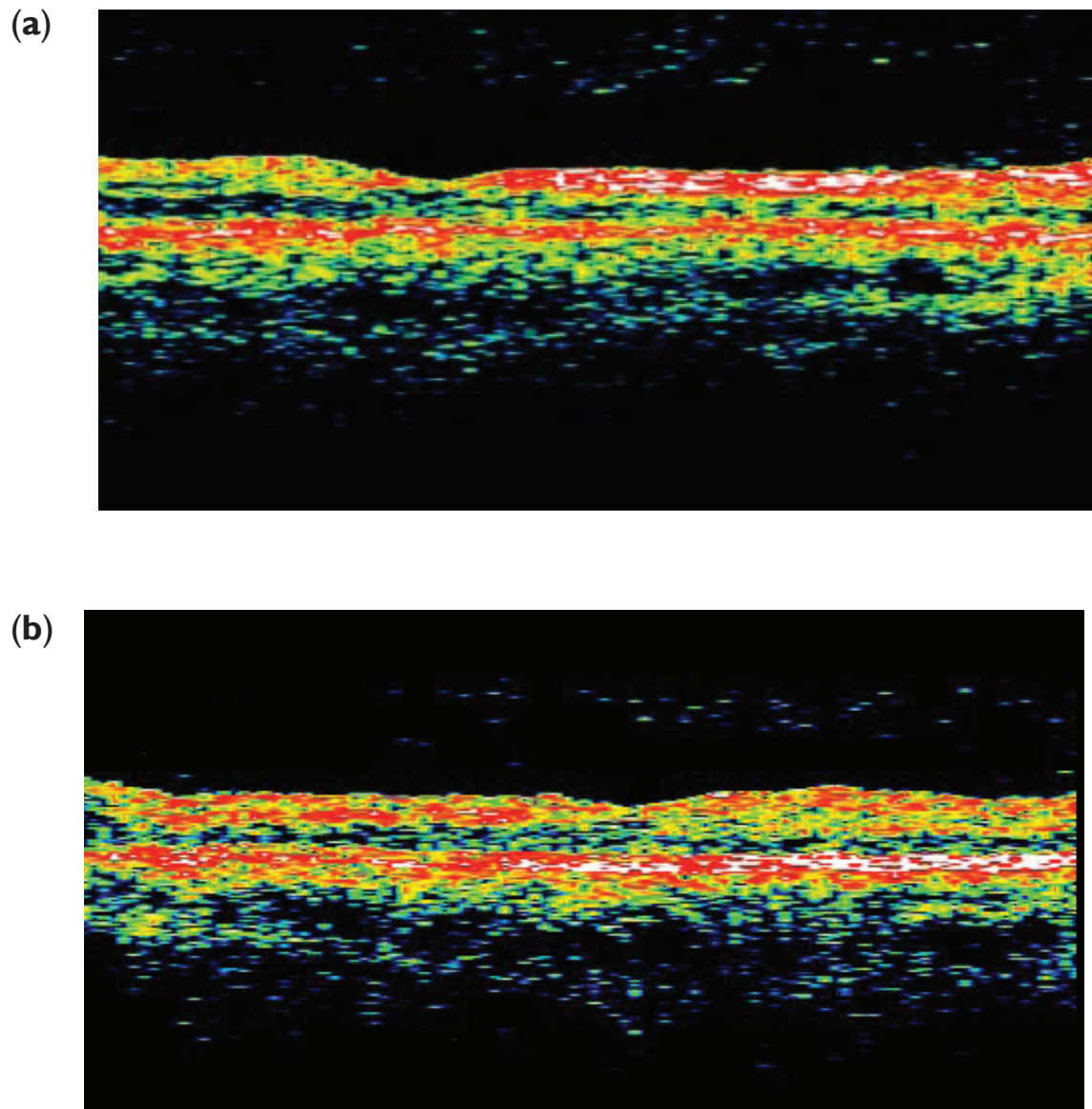


Figure 3 Optical coherence tomography of right (a) and left eye (b), following injection of sub-Tenon's steroid in the right eye. Overall, edema and ischemia is improved.

parturition (Blodi et al 1990). Similar clinical findings have been reported in the setting of amniotic fluid embolism. However, in the absence of a patent foramen ovale or pulmonary arteriovenous-shunts, it is unlikely that amniotic emboli are the direct cause of the observed retinal arteriolar obstructions. Other investigators have theorized that subclinical amniotic fluid emboli may activate complement and induce granulocyte microemboli, which could occur on both sides of the pulmonary capillary bed.

The visual recovery of postpartum patients with Purtscher's-like retinopathy is varied (Blodi et al 1990; Shaikh et al 2003). Of the four patients described by Blodi, three enjoyed significant improvement in central acuity, whereas one suffered permanent visual loss. Another case of Purtscher-like retinopathy has been described in a patient with HELLP syndrome during antepartum. Generally Purtscher-like retinopathy has a favorable prognosis but this case resulted in permanent loss of vision (Stewart et al 2007).

Currently, there is no definitive treatment for postpartum Purtscher's-like retinopathy. In vivo, corticosteroids have been shown efficacious in inhibiting complement-induced granulocyte aggregation (Hammerschmidt et al 1979). Clinically, there are two reports of visual recovery after high dose,

intravenous corticosteroid therapy in post-traumatic patients (Atabay et al 1993).

The case presented here is unique in that the patient had bilateral, asymmetric Purtscher's-like retinopathy postpartum, with quantitative OCT improvement following unilateral local steroid therapy.

Disclosure

The authors have no proprietary interest.

References

- Atabay C, Kansu T, Nurlu G. 1993. Late visual recovery after intravenous methylprednisolone treatment of Purtscher's-like retinopathy. *Ophthalmologica*, 209:330–3.
- Blodi BA, Johnson MW, Gass JD, et al. 1990. Purtscher's-like retinopathy after childbirth. *Ophthalmology*, 97:1654–9.
- Grass JDM. 1997. Stereoscopic atlas of macular diseases, 2nd edition. St. Louis, CV Mosby Co.
- Hammerschmidt DE, White JG, Craddock PR, et al. 1979. Corticosteroids inhibit complement-induced granulocyte aggregation. A possible mechanism for their efficacy in shock states. *J Clin Invest*, 63:798–803.
- Purtscher O. 1912. Angiopathia retinae traumatica. Lymphorrhagien des Augengrundes. *Arch Ophthalmol*, 82:347–71.
- Shaikh S, Ruby AJ, Piotrowski M. 2003. Preeclampsia-related chorioretinopathy with Purtscher's-like findings and macular ischemia. *Retina*, 23:247–50.
- Stewart MW, Brazis PW, Guler CP, et al. 2007. Purtscher-like retinopathy in a patient with HELLP syndrome. *Am J Ophthalmol*, 143:886–7.