

Renal transplant patient with; ureteral necrosis and urine leakage due to double J catheter distortion.

Serhat Dogan¹, Mehmet Erikoglu²

¹Malatya Education and Research Hospital General Surgery Department, Malatya, Turkey

²Necmettin Erbakan University Meram Medical School Faculty of Medicine, Department of General Surgery, Konya Turkey

Dear Editor,

First cadaveric kidney transplant was performed in 1933 in Russia by Voronoy (1,2). Renal failure is treated with renal transplantation. After renal transplantation (tx) rate of urinary complications are 5-12.5%. Double-j ureteral stents was developed by Finney in 1978 (3). After renal transplantation double J catheter-related urinary complications are quite rare. Our aim is, in this study we explain ureteral necrosis, and double J catheter was distortion and anastomotic leakage of urine in renal transplant patient.

Fifty five years old female patient after cadaveric renal transplantation, post-operative third day detected high flow urine leakage and patient were urgently operated. In operation ureter anastomosis was necrotic in the posterior side, necrotic portion was excised. Performed a new ureteroneocystostomy. After the second operation ,post-operative third day from the kidney logy drain arrive urine. Than taken directly urinary tract X-ray and unenhanced CT, Double J catheter king over the anastomosis was detected. Urgently we made a cystoscope, double J catheter pulled to bladder so the patient's urine leakage solved. In this case, we saw ureter necrosis and leakage depends on double j catheter distortion over anastomosis catheter pulled in to the bladder (Figure1 and Figure 2).

Successful renal transplantation increases overall survival and quality of life, and reduces morbidity in most patients with end-stage renal disease when compared with dialysis (4). To decrease the urologic complications, the surgical approach in both donor and recipient is equally important. Treatment should be initiated immediately upon diagnosis this complication. The incidence of urologic complications after kidney transplantation remains high despite improvements in diagnosis and operative techniques.

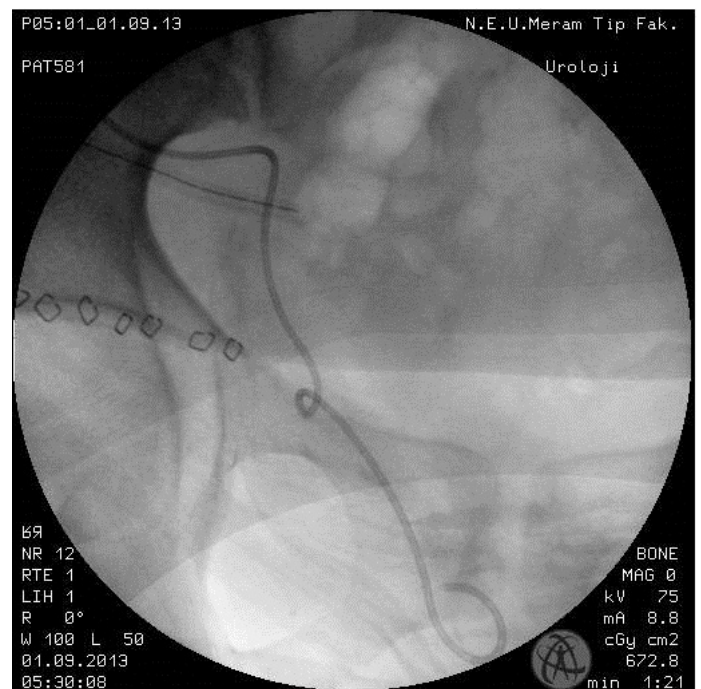


Figure1. The appearance of the kinged Double

The leakage of ureter necrosis, depends on procedure of the renal hilum dissection so nutritional impaired. Therefore, during the removal of the kidney and ureter, renal hilum be dissected more carefully and nutrition must be protected. Disorder of double J catheter leakage of urine is quite rare. Some cases can be managed by an endourologic approach, but in the majority of cases, open surgical management is needed. In our study we use each of them. We prefer open surgery for first complication which is uriner necrosis . And second complication we managed by an endourologic approach.

During the kidney transplantation, double J catheter

Received: 19.03.2018 **Accepted:** 27.04.2018 **Available online:**

Corresponding Author: Serhat Dogan, Malatya Education and Research Hospital General Surgery Department, Malatya, Turkey
E-mail: drserhatdogan@gmail.com

selected more carefully to plant into the ureter, selected true size which wright lenght More carrefull when make anastomosis. In conclusion, urologic complications will always occur in the posttransplant period. Early diagnosis by experienced personnel and use of interventional radiology can greatly reduce the need for surgical treatment.

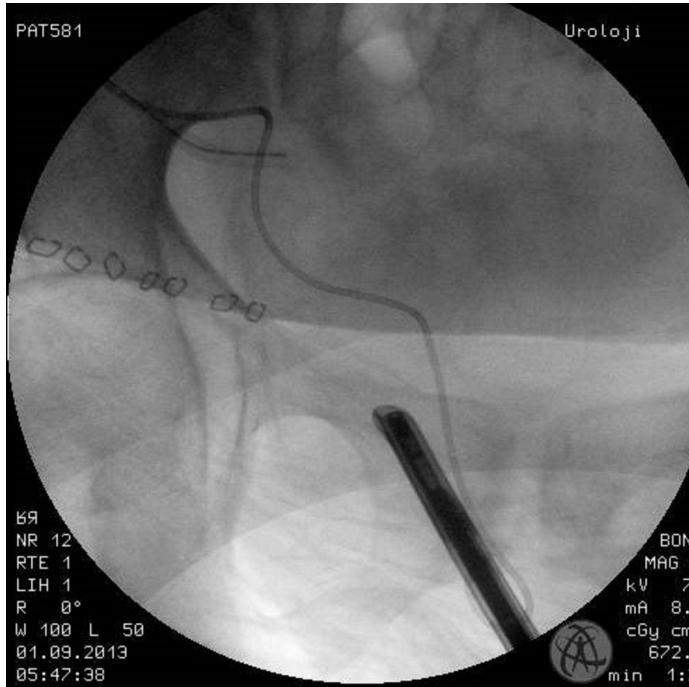


Figure 2. The appearance of the Double J catheter

Competing interests: The authors declare that they have no competing interest.

Financial Disclosure: There are no financial supports

Ethical approval: This work has been approved by the Institutional Review Board.

REFERENCES

1. Gulay H. Temel ve Sistemik Cerrahi. İzmir Güven Kitapevi. 2005; 1.cilt, 647-711.
2. Matevossian E, Kern H, Huser N, Doll D, Snopok Y, Nährig J, et al. Surgeon Yurii voronoy (1895-1961)-a pioneer in the history of clinical transplantation: in memoriam at the 75th anniversary of the first human kidney transplantation. *Transpl Int* 2009;22(12):1132-9.
3. Finney RP. Double-j and diversion stents. *Urol Clin North Am* 1982;9(1):89-94.
4. Laupacis A, Keown P, Pus N, Krueger H, Ferguson B, Wong C, et al. A study of the quality of life and cost-utility of renal transplantation *Kidney Int* 1996;50(1):235-42.