

## Assessment of the dental and skeletal effects of fan-type rapid maxillary expansion screw and Hyrax screw on craniofacial structures

### Abstract

**Aims and Objectives:** The purpose of the study was to assess the skeletal and dental effects of fan-type rapid maxillary expansion (RME) appliance and Hyrax RME appliance on the craniofacial structures. **Materials and Methods:** The sample of the study included 12 patients with constricted maxillary arches. Acrylic bonded type of attachment was used for both groups. Changes in sagittal, vertical, and transverse relationship were assessed with lateral and frontal cephalograms, respectively. Intercanine and intermolar widths were measured with stone models. Pre- and immediate post-treatment records were statistically analyzed with Wilcoxon signed-rank test. The differences between the groups were evaluated using Mann-Whitney U-test. Since the data pertaining to intercanine width and intermolar width were normally distributed, parametric test of significance (unpaired *t*-test) was used to compare them. **Results:** Results showed that Hyrax presented with significantly greater increments for both nasal cavity width and maxillary width when compared to fan-type RME. Both groups had retroclination of incisors. The increase in the intercanine width was almost similar in both groups. **Conclusion:** Fan-type RME caused only minimal expansion of the intermolar width when compared to the Hyrax. The ratio between the intercanine and intermolar width expansion was nearly 4:1 in the fan-type RME and 0.75:1 in Hyrax.

**Keywords:** Fan-type rapid maxillary expansion, Hyrax, intermaxillary width, intermolar width, nasal cavity width

### Introduction

Narrow maxillary arches have been associated with mouth breathing and digit-sucking habits.<sup>[1-6]</sup> The imbalance in the equilibrium between the intra- and extra-oral muscles is cited as the cause in these cases. Cheek pressures are greatest at the corners of the mouth and this explains the “V-” shaped maxillary arches in such cases with more constriction in the intercanine width. These cases require selective anterior expansion of the arch as part of the treatment. Moreover, the indication for the treatment is high since constricted maxillary arch is least likely to correct spontaneously.<sup>[7]</sup> This sort of selective expansion is also needed in cleft palate cases where the anterior segment is collapsed, and there is a normal relationship in the posterior segment.<sup>[8]</sup> Schellino *et al.*<sup>[9]</sup> designed a fan-type rapid maxillary expansion (RME) screw named “ragno” stating that it will work asymmetrically and produces selective expansion. The objective of this study is to

evaluate the dental and skeletal effects of tooth-borne fan-type RME and Hyrax RME on craniofacial structures.

### Subjects and Methods

The sample of the study included 12 patients who reported to the Department of Orthodontics, Tamil Nadu Government Dental College and Hospital with complaint of malocclusion. The criteria for case selection included patients in the late mixed or early permanent dentition with tapered maxillary arch and unilateral or bilateral crossbites requiring palatal expansion as part of their treatment. No consideration was given to the gender of the patients, and patients with palatal clefts and premature synostosis of the palate were not included in the study. Midpalatal suture patency was assessed with occlusal radiographs [Figure 1a and b]. The study was proposed at the Institutional Ethics Committee, Tamil Nadu Government Dental College and Hospital, and the approval was obtained.

Umarevathi  
Gopalakrishnan,  
Premkumar Sridhar<sup>1</sup>

Department of Orthodontics, Sri Venkateswara Dental College and Hospital, <sup>1</sup>Department of Orthodontics, Tamil Nadu Government Dental College and Hospital, Chennai, Tamil Nadu, India

This is an open access article distributed under the terms of the Creative Commons Attribution-NonCommercial-ShareAlike 3.0 License, which allows others to remix, tweak, and build upon the work non-commercially, as long as the author is credited and the new creations are licensed under the identical terms.

For reprints contact: [reprints@medknow.com](mailto:reprints@medknow.com)

**How to cite this article:** Gopalakrishnan U, Sridhar P. Assessment of the dental and skeletal effects of fan-type rapid maxillary expansion screw and Hyrax screw on craniofacial structures. *Contemp Clin Dent* 2017;8:64-70.

### Address for correspondence:

Dr. Umarevathi Gopalakrishnan,  
No. 6, RI, VRISA, 3<sup>rd</sup> Main  
Road, 4<sup>th</sup> Cross Street,  
LH Nagar, Adambakkam,  
Chennai - 600 088,  
Tamil Nadu, India.  
E-mail: [gopkr\\_uma@yahoo.com](mailto:gopkr_uma@yahoo.com)

### Access this article online

#### Website:

[www.contempclindent.org](http://www.contempclindent.org)

DOI: 10.4103/0976-237X.205066

#### Quick Response Code:



The patients were divided into two groups by concealed randomization using opaque envelope method. Group 1 had six patients who were treated with fan-type expansion screw. Group 2 had six patients who were treated with Hyrax expansion screw.

Both screws were adapted parallel to the occlusal plane of the upper teeth. The hinge point of the fan-type RME screw was positioned in line with the distal surface of the upper first permanent molar. The anterior arms were adapted to the lingual surface of the canines and premolars. Posterior arms were bent perpendicular to the screw body and adapted to the molars. The anterior and posterior arms along with the corresponding teeth from canines to molars were enclosed in the clear acrylic material. The incisors were left free [Figure 2].

The Hyrax screw was positioned parallel to the second premolars or primary molars. The anterior and posterior arms were adapted to the lingual surfaces of the canines, premolars, and molars. The anterior and posterior arms along with the corresponding teeth were included in clear acrylic material. The incisors were left free.

The thickness of the occlusal acrylic part was limited to the freeway space. Activation was started after 24 h of cementation. The appliances were activated one-quarter turn twice per day, in the morning and evening. Both groups were expanded equally for 3 weeks. Suture opening was confirmed with occlusal radiographs [Figure 3a and b]. After expansion, the screw was fixed with ligature wire and left for a week to minimize discomfort during removal. After removal of the screw, alginate impressions, photographs, and radiographs were taken and findings were recorded. The appliance was cemented back after taking impressions and radiographs, to be used as the retainer for 3 months following which routine orthodontic treatment was carried out.

Sagittal and vertical parameters were assessed with lateral cephalogram according to the analysis by Bjork.<sup>[10]</sup> Maxillary width and nasal width were measured on the frontal cephalogram. The maxillary width is measured between right and left jugal points (defined as the crossing of the outline of the tuberosity with that of the jugal process). Nasal width was measured between the widest points in the nasal cavity. The cephalometric landmarks used are defined in Figure 4a and b. Stone models were used to measure intercanine and intermolar widths. Intercanine width was measured with a divider between the cusp tips of canines. Intermolar width was measured between the deepest points of the central sulci of the upper first molar teeth.

## Results

### Statistical analysis

The findings of the lateral and frontal radiographs and dental casts were analyzed statistically. The arithmetic

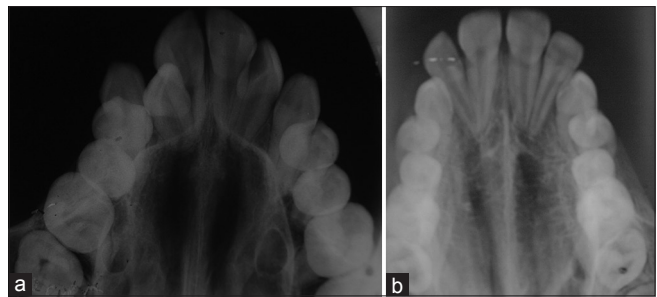


Figure 1: Pretreatment occlusal radiograph of (a) fan-type rapid maxillary expansion (b) Hyrax

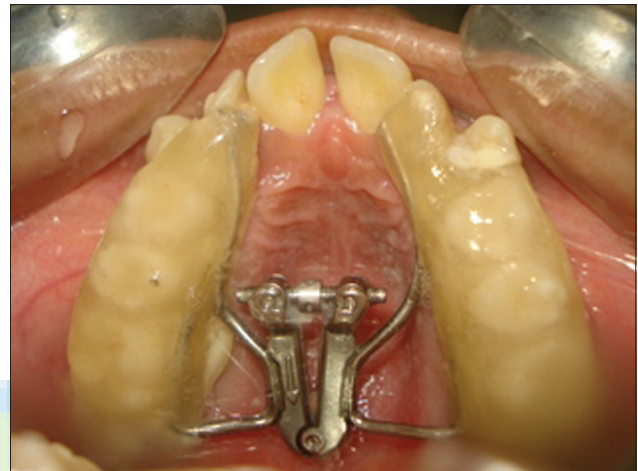

Figure 2: Fan-type rapid maxillary expansion

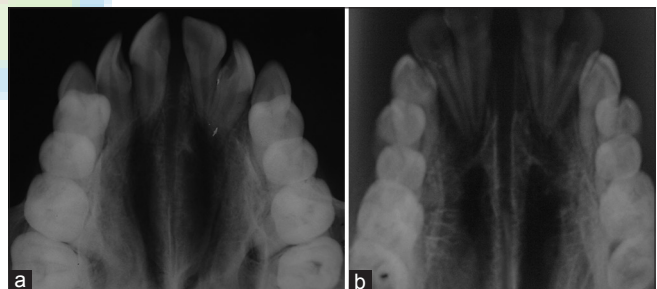


Figure 3: Posttreatment occlusal radiograph of (a) fan-type rapid maxillary expansion (b) Hyrax

mean and standard deviation between the pre- and post-treatment measurements of each group was analyzed using Wilcoxon signed-rank test. Comparison between the groups was done using Mann-Whitney U-test. Pre- and post-treatment values are given in Table 1 for fan-type RME and Table 2 for Hyrax. Differences between the pre- and post-treatment findings are given in Table 3 for fan-type RME (Group 1) and in Table 4 for Hyrax (Group 2). Comparison between the two groups is given in Table 5. Since the data pertaining to intercanine width and intermolar width were normally distributed, parametric test of significance (unpaired *t*-test) was used for comparison between the groups [Table 6].

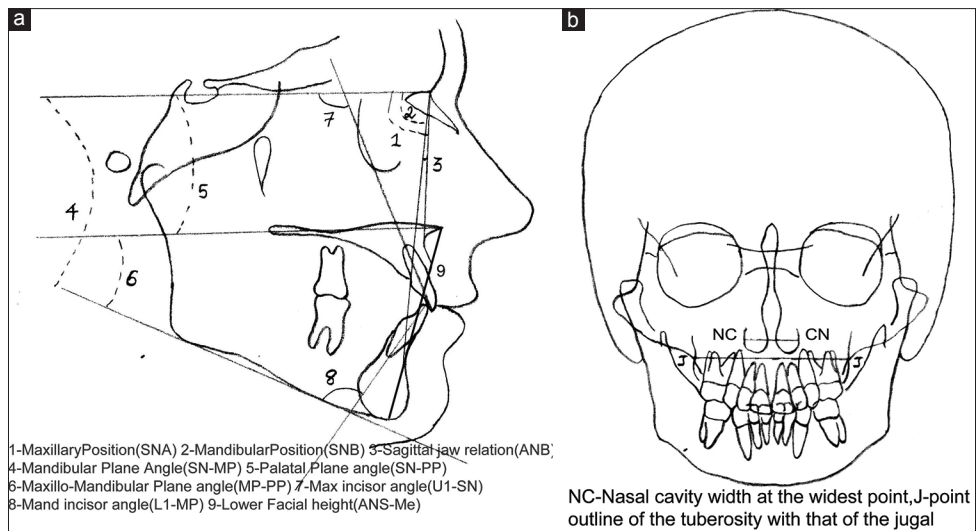


Figure 4: Landmarks used in (a) lateral cephalogram (b) frontal cephalogram

Table 1: Pre- and post-treatment values for fan-type rapid maxillary expansion

Parameter	Patients age (years)											
	13		11		12		12		14		12	
	Pre	Post	Pre	Post	Pre	Post	Pre	Post	Pre	Post	Pre	Post
SNA (°)	80	82	76	78	75	76	80	82	80	82	79	80
SNB (°)	71.5	71	75	74	74	73	79	78	74	73	78	77
ANB (°)	8.5	11	1	4	1	3	1	4	6	9	1	3
SN-MP (°)	40	41	34	34	32	33	38	38	32	33	30	31
SN-PP (°)	7	8	5	6	7	9	1	3	7	8	6	8
MP-PP (°)	33	35	29	30	24	26	36	38	32	33	30	31
N-ANS (mm)	47	49	46	45	45	46	44	45	40	41	47	48
ANS-Me (mm)	59	61	51	53	53	54	65	65	59	60	51	52
UI-SN (°)	106	103	106	101	114	115	118	112	107	104	112	113
L1-MP (°)	98.5	98	92	91	96	96	88	89	88	88	92	93
NC-CN (mm)	26	28	29	30	27	29	28	30	28	30	27	29
JL-JR (mm)	50	51	55	56	51	51	60	61	53	54	61	61
Upper intercanine width (mm)	31	37	28	37	33	37	24	32	35	46	30	36
Upper intermolar width (mm)	42.5	45	42	44	44	46	44	46	46	47	41	43

Table 2: Pre- and post-treatment values for Hyrax rapid maxillary expansion

Parameter	Patients age (years)											
	12		12		13		12		12		14	
	Pre	Post	Pre	Post	Pre	Post	Pre	Post	Pre	Post	Pre	Post
SNA (°)	84	86	73	74	84	86	77	78	80	81	76	78
SNB (°)	85.5	81	76	73	76	75	68	67	78	76	74	73
ANB (°)	0.5	5	-3	1	8	10	9	11	2	5	2	5
SN-MP (°)	30	36	36	40	24	28	45	48	33	36	31	38
SN-PP (°)	7	8	5	7	6	9	8	9	7	9	5	6
MP-PP (°)	24	26	31	34	17	20	40	43	28	33	29	34
N-ANS (mm)	47	49	57	58	52	53	53	55	45	48	47	46
ANS-Me (mm)	63	65	70	73	56	59	68	71	50	53	51	54
UI-SN (°)	118	112	117	114	114	111	113	110	117	114	109	105
L1-MP (°)	92	95	84	84	107	107	86	85	84	84	89	88
NC-CN (mm)	28	31	30	34	26	28	26	30	27	30	28	32
JL-JR (mm)	62	66	58	64	61	65	58	63	61	66	59	64
Upper intercanine width (mm)	35	40	31	37	33	40	31	37	30	36	35	41
Upper intermolar width (mm)	46	56	44	51	40	48	39	44	40	47	46	57

**Table 3: Comparison between pre- and post-treatment findings of fan-type Screw**

Variable	Median	Range	P
SNA (°)			
Pre	78.5000	11.00	0.024
Post	79.5000	12.00	
SNB (°)			
Pre	76.0000	17.50	0.026
Post	74.0000	14.00	
ANB (°)			
Pre	2.0000	12.00	0.027
Post	5.0000	10.00	
SN-MP (°)			
Pre	32.0000	21.00	0.027
Post	37.0000	20.00	
SN-PP (°)			
Pre	6.5000	3.00	0.026
Post	8.5000	3.00	
MP-PP (°)			
Pre	28.5000	23.00	0.026
Post	33.5000	23.00	
N-ANS (mm)			
Pre	49.5000	12.00	0.071
Post	51.0000	12.00	
ANS-Me (mm)			
Pre	59.5000	20.00	0.020
Post	62.0000	20.00	
UI-SN (°)			
Pre	115.5000	9.00	0.024
Post	111.5000	9.00	
L1-MP (°)			
Pre	87.5000	23.00	1.000
Post	86.5000	23.00	
NC-CN (mm)			
Pre	27.5000	4.00	0.026
Post	30.5000	6.00	
JL-JR (mm)			
Pre	60.0000	4.00	0.026
Post	64.5000	3.00	
Upper intercanine width (mm)			
Pre	32.0000	5.00	0.024
Post	38.5000	5.00	
Upper intermolar width (mm)			
Pre	42.0000	7.00	0.027
Post	49.5000	13.00	

**Table 4: Comparison between pre- and post-treatment findings of HYRAX Screw**

Variable	Median	Range	P
SNA (°)			
Pre	79.5000	5.00	0.023
Post	81.0000	6.00	
SNB (°)			
Pre	74.5000	7.50	0.020
Post	73.5000	7.00	
ANB (°)			
Pre	1.0000	7.50	0.026
Post	4.0000	8.00	
SN-MP (°)			
Pre	33.0000	10.00	0.046
Post	33.5000	10.00	
SN-PP (°)			
Pre	6.5000	6.00	
Post	8.0000	6.00	0.024
MP-PP (°)			
Pre	31.0000	12.00	0.024
Post	32.0000	12.00	
N-ANS (mm)			
Pre	45.5000	7.00	0.096
Post	45.5000	8.00	
ANS-Me (mm)			
Pre	56.0000	14.00	0.038
Post	57.0000	13.00	
UI-SN (°)			
Pre	109.5000	12.00	0.114
Post	108.0000	14.00	
L1-MP (°)			
Pre	92.0000	10.50	0.705
Post	92.0000	10.00	
NC-CN (mm)			
Pre	27.5000	3.00	0.020
Post	29.5000	2.00	
JL-JR (mm)			
Pre	54.0000	11.00	0.046
Post	55.0000	10.00	
Upper intercanine width (mm)			
Pre	30.5000	11.00	0.027
Post	37.0000	14.00	
Upper intermolar width (mm)			
Pre	43.2500	5.00	0.024
Post	45.5000	4.00	

**Lateral cephalometric findings**

Group 1 (fan-type RME) showed significant increase for SNA ( $P = 0.024$ ), ANB ( $P = 0.027$ ), SN-PP ( $P = 0.026$ ), SN-MP ( $P = 0.027$ ), MP-PP ( $P = 0.026$ ), and ANS-Me ( $P = 0.020$ ). Values for SNB ( $P = 0.026$ ) and UI-SN ( $P = 0.024$ ) decreased significantly. N-ANS ( $P = 0.071$ ) value increased and L1-MP ( $P = 1.000$ ) value decreased but not significantly.

Group 2 (Hyrax) showed significant increase for SNA ( $P = 0.023$ ), ANB ( $P = 0.0026$ ), SN-MP ( $P = 0.046$ ), SN-PP ( $P = 0.024$ ), MP-PP ( $P = 0.024$ ), and ANS-Me ( $P = 0.038$ ). Significant decrease was observed for SNB ( $P = 0.020$ ). UI-SN ( $P = 0.114$ ) decreased but insignificantly. No significant change was seen in N-ANS ( $P = 0.096$ ) and L1-MP ( $P = 0.705$ ).

When the two groups were compared using Mann-Whitney U-test, significant differences were found for

SN-MP ( $P = 0.003$ ), MP-PP ( $P = 0.006$ ), SNB ( $P = 0.045$ ), and ANS-Me ( $P = 0.004$ ). Group 2 (Hyrax) showed a significant increase for SN-MP, MP-PP, and ANS-Me and a significant decrease for SNB compared to fan-type RME.

### Frontal cephalometric findings

Group 1 (fan-type RME) showed significant increase for nasal cavity (NC-CN) width ( $P = 0.026$ ) and maxillary (JL-JR) width ( $P = 0.026$ ).

Group 2 (Hyrax) also showed significant increase for nasal cavity width ( $P = 0.020$ ) and maxillary width ( $P = 0.046$ ).

When the two groups were compared using Student's *t*-test, significant differences were observed. Group 2 showed significant increase for both nasal cavity width ( $P = 0.007$ ) and maxillary width ( $P = 0.003$ ) when compared to Group 1.

### Transverse dental findings

Since the data pertaining to intercanine width and intermolar width were normally distributed, parametric test of significance (unpaired *t*-test) was used to compare between the groups [Table 6].

Group 1 showed significant increase for both upper intercanine width ( $P = 0.001$ ) and intermolar width ( $P = 0.000$ ).

Group 2 also showed significant increase for both upper intercanine width ( $P = 0.000$ ) and intermolar width ( $P = 0.000$ ).

When the two groups were compared using *t*-test, Group 2 showed a significant increase for the intermolar width than Group 1 ( $P = 0.000$ ). Insignificant difference was seen for intercanine width ( $P = 0.235$ ). Figure 5 represents graphical representation of the transverse dental findings.

### Discussion

A discrepancy in the transverse dimension of the upper jaw and denture base requires a palatal sutural expansion procedure. Sutures have a distinctive property in that these structures regenerate after orthopedic therapy instead of forming scar or repair tissue.<sup>[11]</sup> This is similar to the response of the periodontal ligament to orthodontic force. This attribute makes RME feasible.

Patients with narrow maxilla sometimes require a selective anterior expansion, especially when there is no posterior crossbite and the molar width is normal. This is most often the case in habit-induced constriction of the arches and cleft palate cases. In habit-induced constriction, the narrowness in the cuspid region is more because of greater muscle force at the corners of the mouth. In cleft palate cases, the width between the pterygoid hamuli is slightly wider than in noncleft cases. With full pterygoid width and anterior collapse, the stereotype malocclusion associated

**Table 5: Comparison between fan-type rapid maxillary expansion and Hyrax**

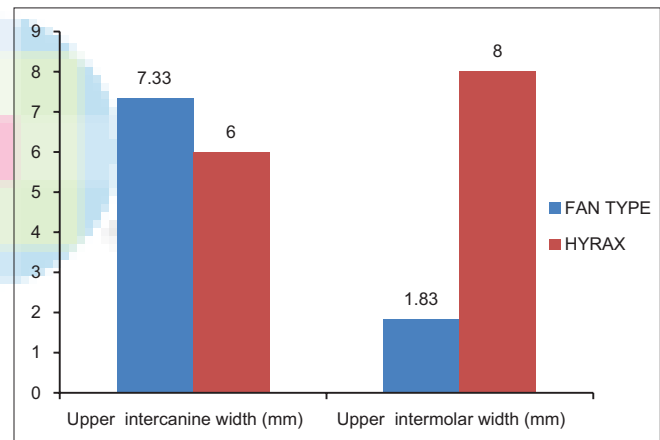
Variable	Mean±SD		P
	Fan	Hyrax	
SNA (°)	1.500±0.548	1.667±0.516	0.575
SNB (°)	-2.083±1.429	-0.917±0.204	0.045
ANB (°)	3.083±1.021	2.583±0.492	0.397
SN-MP (°)	4.500±1.643	0.667±0.516	0.003
SN-PP (°)	1.667±0.816	1.500±0.548	0.789
N-ANS (mm)	1.333±1.366	0.833±0.983	0.340
ANS-Me (mm)	2.833±0.408	1.167±0.753	0.004
UI-SN (°)	-3.667±1.211	-2.500±2.950	0.550
L1-MP (°)	0.167±1.472	0.083±0.801	0.740
NC-CN (mm)	3.333±0.816	1.833±0.408	0.007
JL-JR (mm)	4.833±0.753	0.667±0.516	0.003

SD: Standard deviation

**Table 6: Comparison for transverse dental findings**

Parameter	Fan	Hyrax	P
Upper intercanine width (mm)	7.33±2.5	6.00±0.63	0.235 (NS)
Upper intermolar width (mm)	1.83±0.41	8.00±2.19	<0.001**

\*\*Highly significant  $P < 0.010$ , significant  $P < 0.050$ . NS: Not significant



**Figure 5: Graphical representation of the transverse dental parameters**

with cleft palate manifests as a normal lateral relationship of the most posterior teeth, the crossbite only becoming evident toward the anteriors.<sup>[8,12,13]</sup> When the regular RME screw is used in such cases, a near parallel expansion of molars and cuspid region occurs.<sup>[14-18]</sup> The arch is expanded in the region where it is not required. To that end, Schellino *et al.*<sup>[9]</sup> introduced the fan-type RME claiming that it works asymmetrically. Doruk *et al.*<sup>[9]</sup> compared the effects of tissue-borne fan-type RME with Hyrax and concluded that intercanine expansion was significantly greater in fan-type RME than Hyrax. Luca Levirini and Filippi<sup>[20]</sup> reported a case of narrow maxilla treated with fan-type RME that had greater intercanine expansion than intermolar expansion. In Doruk *et al.*'s study, the design was a more of a splint like with full coverage. In this

study, we used the tooth-borne RME design of McNamara wherein the incisors were left uncovered.

Occlusal radiographs revealed a more typical V opening for the fan-type RME [Figure 3a] compared with the Hyrax [Figure 3b]. Similar to the posterior resistance offered by the circummaxillary sutures which allows the two halves of the maxilla to open in a V pattern,<sup>[15,21-23]</sup> the distal hinge in the fan-type screw offers a posterior resistance that allows a more “V-” shaped opening of the maxillary dental arch. The hinge therefore acts as an additional resistance to facilitate a more V-shaped opening.

Both fan-type RME and Hyrax moved the maxilla forward and downward. This would indicate that both fan-type RME and Hyrax had buttressing effect on the skeletal structures behind maxilla. Significant palatal plane tipping was noted in both groups. Mandible is rotated downward and backward more by Hyrax than fan-type RME. Since the rotation of the mandible is caused mainly by the tipping of the alveolus and the teeth along with their extrusion in the course of posterior expansion, the reduced mandibular opening by the fan-type RME would suggest that its posterior expansion is very minimal. Both groups caused retroclination of upper incisors though it was insignificant in fan-type RME group. This is in contrary to the findings of Doruk *et al.*<sup>[19]</sup> who reported a labial tipping in the fan-type RME. This could be attributed to the difference in design of the appliances between the two studies. Since the incisors were left uncovered in this study compared to the full-coverage design in latter study, they are subjected to the lingual force of the lip muscles which caused the lingual tipping of the incisors.

Hyrax presented with significantly greater increments for both nasal cavity width and maxillary width when compared to fan-type RME. The limited parallel opening for the fan-type RME attributed to the distal hinge could have caused the minimal nasal widening compared to Hyrax. Since the maxillary width was assessed at the level of jugal points, the restricted posterior expansion by the hinge in the fan-type RME led to this maxillary width difference between fan-type RME and Hyrax.

The increase in the intercanine width was almost similar in both groups. Fan-type RME caused only minimal expansion of the intermolar width when compared to the Hyrax attributed to the distal hinge. The ratio between the intercanine and intermolar width was nearly 4:1 in the fan-type RME and 0.75:1 in Hyrax. This is in accordance with the findings of Doruk *et al.*<sup>[19]</sup> and Levrini and Filippi.<sup>[20]</sup>

## Conclusion

The results suggest that the fan-type RME screw can expand the maxilla asymmetrically with less posterior expansion both dentally and skeletally. These findings may be of great benefit in the treatment of patients exhibiting

anterior maxillary narrowness with normal intermolar width. More studies involving an increased sample size and long-term follow-up are needed to have a better knowledge about the clinical efficiency of the fan-type screw.

## Financial support and sponsorship

Nil.

## Conflicts of interest

There are no conflicts of interest.

## References

- Gross AM, Kellum GD, Franz D, Michas K, Walker M, Foster M, *et al.* A longitudinal evaluation of open mouth posture and maxillary arch width in children. *Angle Orthod* 1994;64:419-24.
- Hanson ML, Cohen MS. Effects of form and function on swallowing and the developing dentition. *Am J Orthod Oral Surg* 1973;64:63-82.
- O’Ryan FS, Gallagher DM, LaBanc JP, Epker BN. The relation between nasorespiratory function and dentofacial morphology: A review. *Am J Orthod Oral Surg* 1982;82:403-10.
- Metz HC. Pernicious habit retarding lateral development of anterior teeth. *Am J Orthod Oral Surg* 1930;16:968-70.
- Beck LK. Chronic mouth-breathing. *Am J Orthod Oral Surg* 1923;9:263-4.
- Linder-Aronson S. Respiratory function in relation to facial morphology and the dentition. *Br J Orthod* 1979;6:59-71.
- Proffit WR, Fields HW, Sarver DM. *Contemporary Orthodontics*. 4<sup>th</sup> ed. St. Louis: Elsevier; 2007. p. 153.
- Subtelny J, Rochester NY. Width of the nasopharynx and related anatomic structures in normal and unoperated cleft palate children. *Am J Orthod* 1955;41:889-909.
- Schellino E, Modica R, Benech A, Modaro E. REM: The spider lives according to Schellino and Modica. *Boll Intern Orthod*. Leone 1996;55:36-9.
- Bjork A. *The Face in Profile. An Investigation into Facial Prognathism*. Dissertation, University of Lund, Sweden; 1947.
- Ten Cate AR, Freeman E, Dickinson JB. Sutural development: Structure and its response to rapid expansion. *Am J Orthod* 1977;71:622-36.
- Graber TM. Craniofacial morphology in cleft palate and cleft lip deformities. *Surg Gynecol Obstet* 1949;88:359-69.
- Graber TM. The congenital cleft palate deformity. *J Am Dent Assoc* 1954;48:375-95.
- Suzuki A, Takahama Y. A jointed fan-type expander: A newly designed expansion appliance for the upper dental arch of patients with cleft lip and/or palate. *Cleft Palate J* 1989;26:239-41.
- Sandikçioğlu M, Hazar S. Skeletal and dental changes after maxillary expansion in the mixed dentition. *Am J Orthod Dentofacial Orthop* 1997;111:321-7.
- Geran RG, McNamara JA Jr., Baccetti T, Franchi L, Shapiro LM. A prospective long-term study on the effects of rapid maxillary expansion in the early mixed dentition. *Am J Orthod Dentofacial Orthop* 2006;129:631-40.
- Weissheimer A, de Menezes LM, Mezomo M, Dias DM, de Lima EM, Rizzato SM. Immediate effects of rapid maxillary expansion with Haas-type and hyrax-type expanders: A randomized clinical trial. *Am J Orthod Dentofacial Orthop* 2011;140:366-76.
- Gunyuz Toklu M, Germec-Cakan D, Tozlu M. Periodontal, dentoalveolar, and skeletal effects of tooth-borne and tooth-bone-

- borne expansion appliances. *Am J Orthod Dentofacial Orthop* 2015;148:97-109.
19. Doruk C, Bicakci AA, Basciftci FA, Agar U, Babacan H. A comparison of the effects of rapid maxillary expansion and fan-type rapid maxillary expansion on dentofacial structures. *Angle Orthod* 2004;74:184-94.
  20. Levrini L, Filippi V. A fan-shaped maxillary expander. *J Clin Orthod* 1999;33:642-3.
  21. Timms DJ. A study of basal movement with rapid maxillary expansion. *Am J Orthod Oral Surg* 1980;77:500-7.
  22. Hayes JL. Rapid maxillary expansion. *Am J Orthod Dentofacial Orthop* 2006;130:432-3.
  23. Garrett BJ, Caruso JM, Rungcharassaeng K, Farrage JR, Kim JS, Taylor GD. Skeletal effects to the maxilla after rapid maxillary expansion assessed with cone-beam computed tomography. *Am J Orthod Dentofacial Orthop* 2008;134:8-9.

