

ELECTIVE SURGERY OF UMBILICAL HERNIA AS A FIRST CLINICAL MANIFESTATION OF A GASTROINTESTINAL STROMAL TUMOR (GIST) – CASE REPORT

BARTOSZ CYBUŁKA, MACIEJ GOLAŃSKI, JACEK RAPEŁA, ANDRZEJ WACH

Department of Surgery Public Hospital in Grodzisk Wlkp.
Ordynator: lek. A. Wach

Gastrointestinal stromal tumor is a rare pathology. GISTs account for 0.3-1% of all tumors of the gastrointestinal tract. At the same time, this type of cancer is the most common, malignant, non-epithelial tumor of the gastrointestinal tube. Over 90% of GISTs are found in the stomach and small intestine. This cancer usually develops without characteristic clinical symptoms and is diagnosed incidentally.

This clinical situation, in which the first symptom of a GIST-pattern tumor includes a fully-symptomatic, non-complicated umbilical hernia, is an unprecedented anomaly.

This work presents a case report of a 77-year old female patient undergoing elective surgery, in which the contents of the hernial sac included a stromal tumor. Disseminated, multi-focal progression of the disease was found intraoperatively.

Postoperative histopathology and immunohistochemistry revealed a gastrointestinal stromal tumor GIST of the spindle cell type, showing a CD-117, CD-34, SMA expression with possible starting point in the small intestine.

Key words: GIST, stromal tumor, umbilical hernia

GISTs are the most common mesenchymal tumor of the gastrointestinal tract. Histologically, the precursor of the transformation anomaly are the interstitial cells of Cajal, responsible for motor function of the gastrointestinal tract. The most common tumor location is the stomach (60%), while the small intestine ranks second (30%). The other parts of the gastrointestinal tract are much less often involved in the disease process. Only 5% of GISTs are found in the large intestine and less than 5% are found in the esophagus.

The primary location of the stromal tumor, outside the gastrointestinal tube, in the retroperitoneum, account for less than 10% of diagnosed cases.

The clinical course of the disease is usually oligosymptomatic or asymptomatic. The dominant clinical symptoms include stomach pain, gastrointestinal bleeding and passage disorders. 25% of cases are diagnosed incidentally. 10% of cases are diagnosed postmortem.

75% of GISTs are diagnosed in patients over 50 years of age (1, 2).

There is very little available literature on the location of GISTs in the hernial sac.

Mulla et al. 2007 and Tinoco-González 2014 have documented cases of stomal tumor exploration in the incarcerated inguinal hernia sac (3, 4).

In 2015 Żyłuk has reported a case of a patient undergoing surgery for incarcerated femoral hernia with stromal tumor found during revision surgery of the small intestine (5).

A clinical case, in which a GIST was found in the umbilical hernia sac, has not been reported in literature up to date.

CASE REPORT

A 77-year old female patient was admitted to the Department of Surgery in Grodzisk

Wielkopolski for elective surgery of the umbilical hernia. During the six months preceding hospitalization the patient reported a gradually increasing size of the hernia. Hypertension, persistent atrial fibrillation and status post classic cholecystectomy were found in medical history of the patient. Physical examination did not reveal features of incarceration, no pathology of the hernial rings was found, the contents of the hernia sac were freely reduced into the abdominal cavity. Moreover, there was no skin damage or defects over the umbilical hernia.

Due to hernia size, the patient was qualified for surgery under general anaesthesia. In the operating room, following the initial preparation of the surgical site, a 7-cm curved incision was performed below the umbilicus. The umbilical hernia sac was dissected up to the inguinal ring. The hernia sac was opened under visual control. A small amount of serous liquid was found with a pathological tumorous mass, solid-cystic appearing under macroscopic ex-

amination, filled with blood contents. The pathological lesion from the abdominal cavity passed through the hernial rings. Soon it turned out that this was only the “tip of the iceberg”. A decision was made on the conversion to midline laparotomy (fig. 1). Upon laparotomy multiple, “hundreds” of tumorous lesions were found, ranging from a few millimetres to ca. 10 cm in diameter (fig. 2, 3, 4). Neoplastic lesions in multiple clusters covered the gastrocolic omentum, parietal peritoneum, inner surface of the hernia sac, parts of the visceral peritoneum, outer surface of the serosa of the small intestine and the large intestine. Some of the lesions presented a partly cyst-like structure, filled with blood; some of them could be easily dissected bluntly, using fingers (fig. 5). Intraoperative evaluation of the liver did not reveal any metastatic lesions.

During further surgery an excess of hernia sac covered in tumors was resected and a radical resection of the gastrocolic omentum was performed (fig. 6). Part of the cancerous

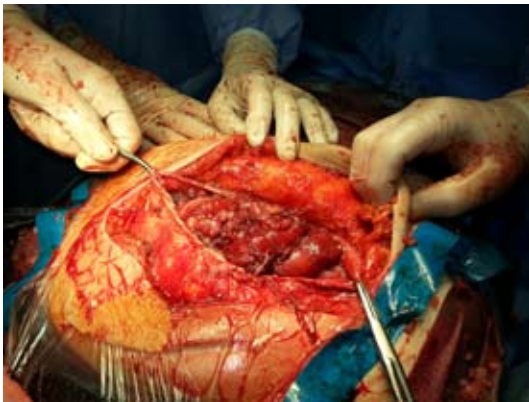


Fig. 1. Midline laparotomy

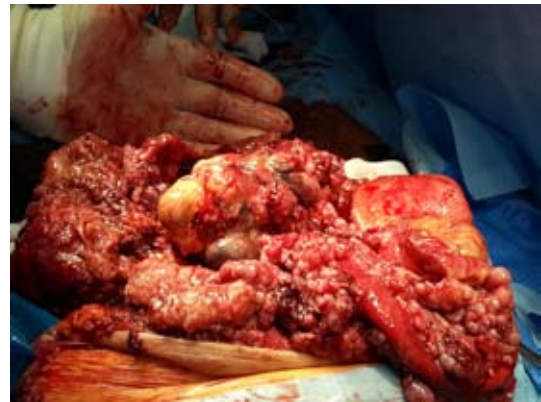

Fig. 2. Solid-cystic appearing GIST filled with blood

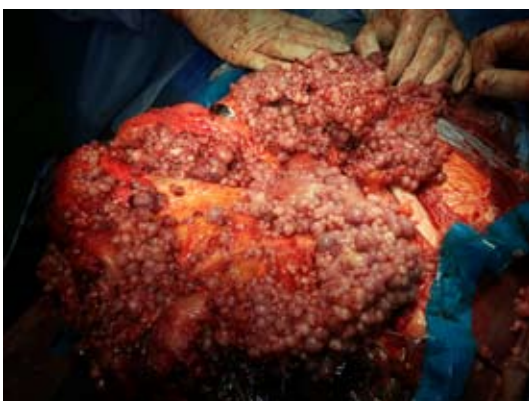

Fig. 3. Disseminated GIST

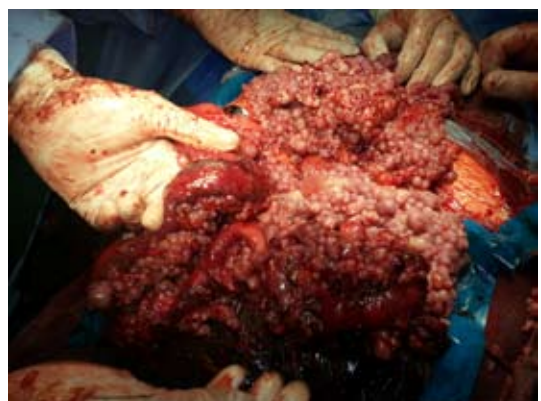

Fig. 4. Neoplastic involvement of the small intestine

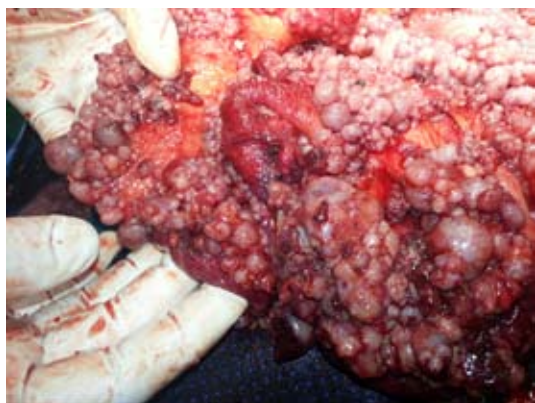

Fig. 5. High tumour aggressiveness

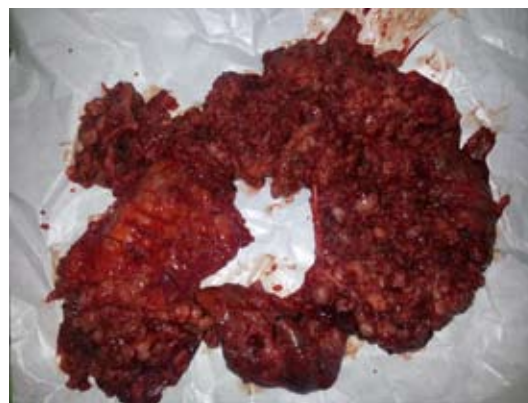

Fig. 6. Resected hernia sac with gastrocolic omentum

dissemination was reduced, which covered the inner surface of the abdominal cavity. Radical resection of all macroscopic lesions was unrealizable (fig. 7). The abdominal wound was closed layer by layer. A 24 Fr Redon pelvic drain was placed in the abdominal cavity. The subcutaneous tissue in the umbilical region was secured with a 14 Fr Redon drain.

Postoperative material was prepared for histopathological examination.

The histopathological examination revealed a disseminated GIST of the spindle cell type. Immunohistochemical examination revealed a CD-117, CD-34, SMA (smooth muscle actin) expression. Expression of S100 proteins was not found. Under microscopic examination 30 mitoses were found per 50 high-power fields (HPF).

DISCUSSION

A palpable nodule in the umbilical region may be the first clinical manifestation of a neoplastic disease. Metastatic skin tumor at the umbilical ring is referred to in the literature as the Sister Mary Joseph nodule. It is associated with the dissemination of the cancer process of the abdomen and the pelvis through lymphatic and blood circulatory system. The observed pathological lesion of the umbilical region accompanies only 1-3% of advanced cancer process cases (6, 7).

Stromal tumors are rare. Epidemiologically they account for 0.1-3% of all gastrointestinal tumors. Stromal tumors may be potentially found in any segment of the gastrointestinal tract. A malignant course of the disease with direct infiltration and metastases via the blood

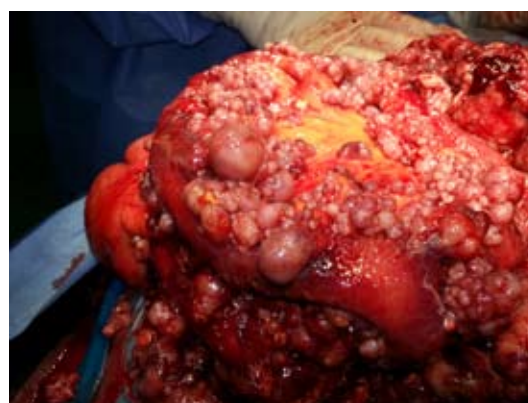

Fig. 7. High mitotic index of the neoplastic cells

to the liver is found in 30% of cases. Metastases to regional lymph nodes are rare (8, 9, 10).

More than 90% of GISTs show a tyrosine kinase gene expression (CD-117 c-KIT). CD-34 expression is found in 60-70% of GISTs. Mutations of the receptor tyrosine kinase gene are not found in 10-15% of GISTs (11).

The basic treatment method includes surgical resection with a healthy tissue margin.

Radical lesion excision conditions a 5-year survival rate of 42%; lack of radical resection reduces the survival rate to 10% (12).

Specific immunohistochemical configuration allows for the use of tyrosine-kinase inhibitors (imatinib, sunitinib) in cancer treatment (13).

Since 2000 a tyrosine-kinase inhibitor, imatinib (Glivec), is used in the neoadjuvant and adjuvant therapy. The use of this therapy prior to surgical intervention allows for a radical resection of a R0 tumor. Pharmacological treatment complementary to surgery

reduces the risk of recurrence in high-risk tumours (14).

Unfortunately, remote metastases are found in 10-20% patients diagnosed with GIST. The annual risk of the disseminated tumor in Poland is estimated at 150 – 190 newly diagnosed cases.

In the presented case report an incidentally diagnosed tumor during dissection of the umbilical hernia sac turned out to be an advanced neoplastic process. Elective qualification of the patient to a relatively common surgery performed at the Department of surgery resulted in lack of preoperative imaging diagnostics. The diagnosis of GIST was incidental and occurred intraoperatively. This supports the insidious course of the disease.

The tumor size of more than 10 cm, multifocality of lesions, high mitotic index $\geq 5/50$ HPF, tumor location outside the stomach, the advanced age of the patient suggested high tumor aggressiveness (tab. 1, 2, 3).

Stromal tumors may be potentially found in any segment of the gastrointestinal tract. Potential clinical manifestations include, but are not limited to bleeding, gastrointestinal obstruction due to pathological mass.

Several new cases are diagnosed incidentally during imaging examination of the gastrointestinal lumen. Histopathological examinations confirm the specific GIST-type tumor structure. In postoperative diagnostics immunohistochemical examinations are essential to confirm the diagnosis, determine prognostic factors, which eventually determine the adjuvant treatment.

SUMMARY

In rare cases, pathological lesions in the umbilical region may be the first manifestation of a neoplastic disease. Metastasis to the umbilical region is known as the Sister May Joseph nodule.

A clinical case in which the contents of the umbilical hernia sac include a stromal tumor is extremely rare. A search of the PubMed NCBI database produced two cases of incarcer-

Table 1. Assessment of clinical aggressiveness of GIST in accordance with the NIH guidelines (2)

Aggressiveness	Tumor size (cm)	Mitotic number (HPF)
Very low	< 2	< 5/50
Low	2-5	< 5/50
Intermediate	≤ 5	6-10/50
	5-10	< 5/50
High	> 5	> 5/50
	> 10	each
	each	> 10/50

Table 2. Immunohistochemical markers for GIST (15, 16, 17)

Marker	Incidence
KIT (CD-117)	100%
CD-34	70%
SMA	20–30%
S-100	10%
Desmin	<5%

Table 3. Poor prognostic factors for GIST (15, 16, 17)

Poor prognostic factors
Tumor size (>10 cm)
High mitotic index $\geq 5/50$ HPF
Location outside the stomach
Disseminated neoplasm
Remote metastases
Tumor damage during surgery
Perforation
Multifocality
Advanced age

ated inguinal hernia and one case of incarcerated femoral hernia with an intraoperatively diagnoses GIST.

The anomaly presented in this paper has been incidentally found during an elective umbilical hernioplasty.

Up to date there have been no reports of a GIST located in the non-complicated umbilical hernia sac.

REFERENCES

1. Blackstein, Blay JY, Corless C et al.: Gastrointestinal stromal tumours: consensus statement on diagnosis and treatment. *Can J Gastroenterol* 2006; 20(3): 157-63.
2. Fletcher CDM, Berman JJ, Corless C et al.: Diagnosis of gastrointestinal stromal tumors: a consensus approach. *Hum Pathol* 2002; 33: 459-65.
3. Mulla M, Yeung J, Reynolds J: Gastrointestinal-stromal tumour (GIST) mimicking an indirect inguinal hernia, a rare presentation. *Eur Surg ACA* 2007; 39(4).
4. Tinoco-González J: Gastrointestinal stromal tumor (GIST) presenting as a groin mass mimicking and incarcerated hernia. *Int J Surg Case Rep* 2015; 6C: 166-68.
5. Żyluk A, Majewski W: Parietal Strangulation Of Small Intestine In Femoral Hernia Site With Symptoms Of Intestinal Obstruction In Patient With Incidentally Found Small Intestine Tumor – A Case Report. *Pol Przegl Chir* 2015; 87(8): 413-16.
6. Trebing D, Göring HD: The umbilical metastasis. Sister Mary Joseph and her time. *Hautarzt* 2004; 55: 186-89.
7. Deb P, Rai RS, Rai R et al.: Sister Mary Joseph nodule as the presenting sign of disseminated prostate carcinoma. *J Cancer Res Ther* 2009; 5: 127-29.
8. Beham AW, Schaefer IM, Schüler P et al.: Gastrointestinal stromal tumors. *Int J Colorectal Dis* 2012; 27: 689-700.
9. Goethsch WG, Bos SD, Breekveldt-Postma N et al.: Incidence of gastrointestinal stromal tumors is underestimated: results of a nation-wide study. *Eur J Cancer* 2005; 41: 2868-72.
10. Diaconescu MR, Diaconescu S: Mesenchymal (Non-epithelial) "Non-GIST" Tumors of the Digestive Tract. *Chirurgia* 2012; 107: 742-50.
11. Miettinen M, Wang ZF, Lasota J: DOG1 antibody in the differential diagnosis of gastrointestinal stromal tumors: a study of 1840 cases. *Am J Surg Pathol* 2009; 33: 1401-08.
12. Pierie JP, Choudry U, Muzikansky A et al.: The effect of surgery and grade on outcome of gastrointestinal stromal tumors. *Arch Surg* 2001; 136(4): 383-89.
13. Miettinen M, Lasota J: Gastrointestinal stromal tumors (GISTs): definition, occurrence, pathology, differential diagnosis, and molecular genetics. *Pol J Pathol* 2003; 54:3-24.
14. Sepe PS, Brugge WR: A guide for the diagnosis and management of gastrointestinal stromal cell tumors. *Nat Rev Gastroenterol Hepatol* 2009; 6: 363-37.
15. Karagülle E, Türk E, Yildirim E et al.: Multifocal intestinal stromal tumors with jejunal perforation and intraabdominal abscess: report of a case. *Turk J Gastroenterol* 2008; 19(4): 264-67.
16. Paramythiotisa D, Panidisa S, Papadopoulou V, Panagiotou D, Panteliadoub P, Michalopoulos A. Perforated gastrointestinal tumour of the small intestine: a case report presenting with peritonitis. *J Curr Surg* 2011; 1(1): 44-46.
17. Efremidou EI, Liratzopoulos N, Papageorgiou MS et al.: Perforated GIST of the small intestine as a rare cause of acute abdomen: surgical treatment and adjuvant therapy. Case report. *J Gastrointest Liver Dis* 2006; 15(3): 297-99.

Received: 29.02.2016 r.

Address correspondence: 62-065 Grodzisk Wlkp., ul. Mossego 3

e-mail: b.cybulka@wp.pl