

## CASE REPORTS

### SURGICAL TRAP OF A ROUTINE PROCEDURE. SCROTAL HERNIA WITH CONCOMITANT SLIDING OF THE URINARY BLADDER – CASE REPORT

*BARTOSZ CYBUŁKA, MAREK PODGÓRNY, JACEK RAPEŁA, ANDRZEJ WACH*

Department of Surgery and Gastroenterology SPZOZ in Grodzisk Wlkp.  
Ordynator: lek. A. Wach

The content of the hernial sac may comprise peritoneal cavity elements, such as small and large bowel loops, visceral adipose tissue, the greater omentum, appendix (amyand hernia), and Meckel's diverticulum. The sliding of part of the urinary bladder wall to the inguinal canal is rare, being observed in 1%-4% (0.5%-3%) of inguinal hernia cases. Complete migration of the urinary bladder to the scrotum is considered a rare anomaly. As of today, 100 such cases have been described.

**Key words:** scrotal hernia, sliding hernia, sliding of the urinary bladder, scrotal cystocele

During life the risk of full symptom inguinal hernia development is observed in 27% of male and 3% of female cases (1).

Considering epidemiology, the sliding of the urinary bladder to the inguinal hernia sac is observed in 0.5-4% of cases (2, 3, 4). A large scrotal hernia of the urinary bladder is even rarer (5, 6). The term scrotal cystocele dominates in english literature data, proposed by Levin in 1951 (7). Since the above-mentioned date, Levin described 32 such cases.

Hernia repair procedures are the most common surgical interventions in Poland. Hernia plasty is one of the first surgical procedures performed. During surgical training the young adept is obliged to perform 55 hernia plasty operations on his own, and in 15 cases be the assisting surgeon.

The aim of the study was to present a rare anatomical variant, which the surgeon might encounter during elective inguinal hernia surgery. In most cases proper inguinal hernia repair does not pose a problem for the surgeon. In selected cases the routine procedure might prove to be a challenge.

Preoperative physical examination, surgical alertness, and imaging diagnostics (cystogra-

phy) enabled to diagnose scrotal cystocele, considered a rare pathology.

#### CASE REPORT

A 61-year old male patient was admitted to the Department of Surgery for treatment of left-sided inguinal hernia sliding to the scrotum. The patient had a history of arterial hypertension and pacemaker implantation. Stage II obesity was diagnosed with the BMI amounting to 38.74.

During the physical examination the patient complained of pain, left-sided inguinal and scrotal discomfort. On admission, we observed an enlarging pathological mass in the vicinity of the left inguinal ligament. Pain symptoms and the size of the hernia significantly intensified during the past 6 months.

The patient complained of unspecific symptoms, such as reduction of the size of the hernia after miction, increased miction after compression of the scrotal area, ischuria paradoxa, incomplete urinary bladder emptying, and periodic symptoms of dysuria.

Imaging examinations showed the cystoscopic image of the mucous membrane free of pathology. The ultrasound examination showed a homogenous, well-limited hypoechogenic fluid reservoir located in the left inguinal and scrotal area. The fluid reservoir was present even after urinary bladder emptying. Laboratory results showed no abnormalities.

Final diagnosis was based on ascending cystography, which showed the presence of a massive, left-sided, inguinoscrotal bladder hernia (fig. 1).

Due to persistent symptoms reported by the patient, significant cosmetic defect, and hygienic problem of the inguino-scrotal area the patient was qualified for surgery. After the introduction of spinal anesthesia an oblique inferior incision was performed in the left groin, the lower pole of the wound being extended to the antero-lateral wall of the scrotum. After opening the left inguinal canal the hernial sac containing the sliding scrotal bladder hernia was subject to preparation (fig. 2). The apex of the oblique hernial sac after crossing the deep inguinal ring migrated to the left testicular level (fig. 3). Under visual control the deep inguinal ring was subject to preparation and dilatation.

Without violating the continuity of the urinary bladder walls the excessive content of the hernial sac was reduced to the abdominal cavity. Due to the vascular pedicle of the left testicle, surgery was extended to left-sided orchietomy (fig. 4). Previously, the patient was informed in detail about the possibility of surgical extension. He consented in writing to the removal of the left testicle.

The inefficient posterior wall of the inguinal canal was supplied by redoubling the

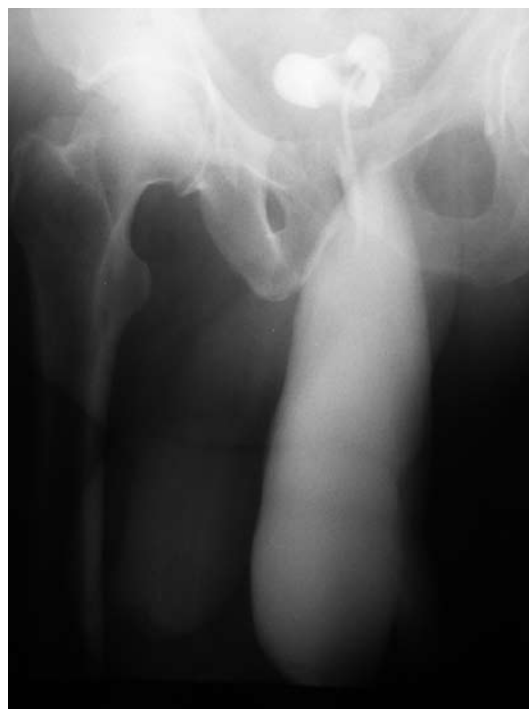

Fig. 1. Preoperative ascending cystography

transverse fascia and placing a continuous suture between the internal oblique muscle and inguinal ligament. Hernioplasty was performed applying a polypropylene mesh, 10x5 cm in size by means of Lichtenstein's method (fig. 5). The area above the external oblique muscle aponeurosis was secured by a suction Redon 14 Fr drain. Additionally, a gravitational drain was left inside the scrotal sac at the site of the orchietomy. The operative wound was closed by means of interrupted, adaptation sutures.

Intraoperative blood loss was insignificant. During the procedure bipolar electrocoagulation was used, due to the presence of a cardiac

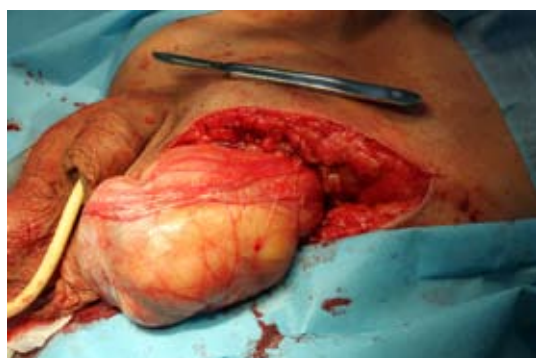

Fig. 2. Hernial sac with urinary bladder content

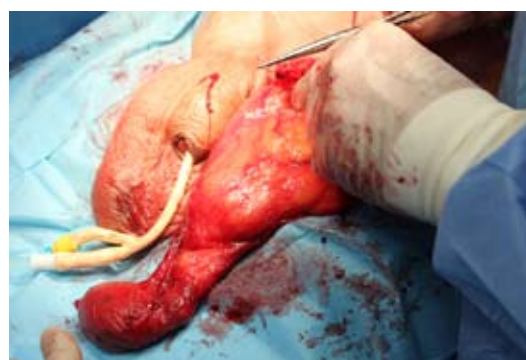

Fig. 3. Dissected hernial sac and urinary bladder and isolated left testicle

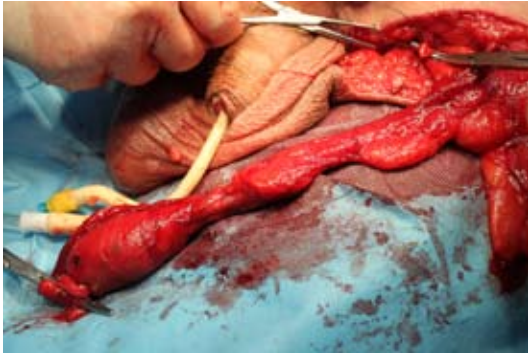

Fig. 4. Dissected left testicle with elements of the spermatic cord

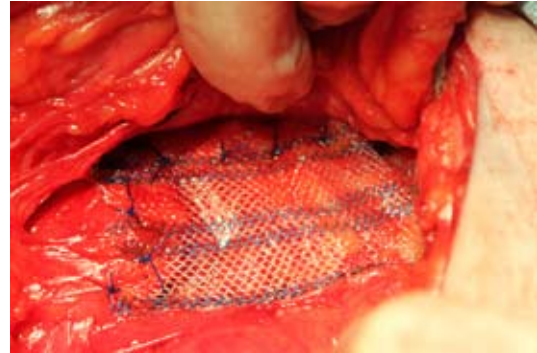


Fig. 5. Supplied posterior wall of the inguinal canal by means of a polypropylene mesh: tension-free technique

pacemaker. During the postoperative period antibiotics were administered (Tarfazolin 1,0 i.v. Metronidazol 1,0 i.v.). Foley's catheter (18 Fr) was inserted into the urinary bladder.

During the postoperative period the Redon drain was removed after three days. Eight days after surgery the patient was discharged from the hospital in good general condition.

Control ascending cystography performed 30 days after surgery showed proper localization of the urinary bladder above the pubic symphysis (fig. 6). The volume capacity of the bladder after repair surgery was not reduced amounting to approximately 350 ml.

During postoperative monitoring we observed wound inflammation. The control examination showed the presence of two fluid compartments, one in the lower pole of the wound and one in the left scrotal area. Both fluid compartments required surgical incisions, revision, and drainage. There was no evidence of polypropylene mesh infection. The bacteriological material showed no significant *Staphylococcus haemolyticus* MRS growth. The methicillin-resistant strain showed susceptibility to clindamicin and dapromycin. Dressings, wound drainage, and target antibiotics proved effective. Supervision over the wound healing process was under ambulatory control. Sixty-three days thereafter, the wound was considered as healed.

## DISCUSSION

Surgery in case of an inguinal hernia is one of the most commonly performed procedures

in general surgery around the world. It is estimated that each year approximately 20 million of such operations are performed. In Poland, there are more than 40 thousand such procedures performed. For comparison, in the United States there are more than 700 thousand such procedures. Inguinal hernia surgery predominates, accounting for 70% of cases. The second most frequent surgical interventions concern femoral hernias in the female population, accounting for 12% of cases (8).

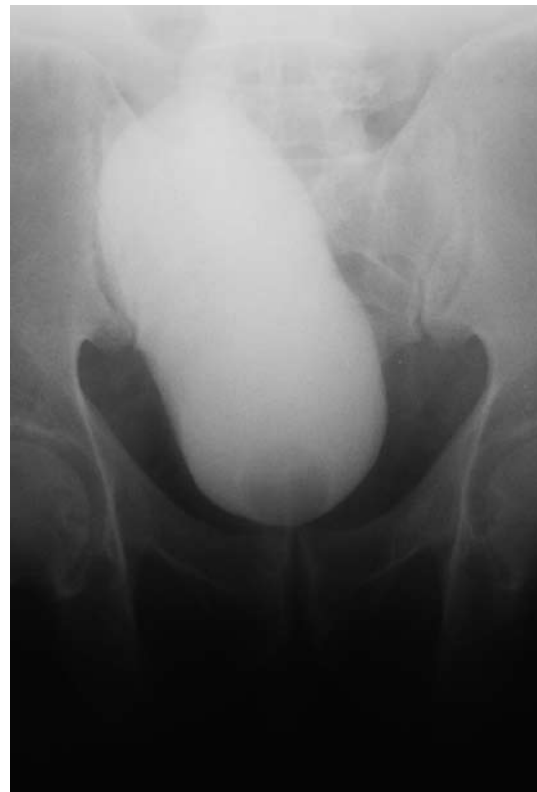

Fig. 6. Control cystography 30 days after surgery

Proper diagnosis, appropriate treatment strategy, and postoperative care in most cases take place without negative complications.

The most important risk factors of scrotal bladder hernias include the following:

- obesity (9),
- past injuries of the pelvis, especially associated with damage to the pelvic ligament, supporting the urinary bladder. Damage to the symphysis barrier for the migration of the urinary bladder (10),
- previous abdominal wall and inguino-pubic area operations,
- subbladder obstruction (prostatic hypertrophy, urethral stricture, prostatitis, bladder neck stenosis, and in selected cases chronic, untreated phimosis),
- urinary bladder wall pathology (weakening muscular membrane, presence of bladder diverticula, chronic inflammation, malignancy),
- advanced age,
- general factors, such as smoking, COPD, congenital anomalies in collagen soft tissue structures.

Anatomically, retroperitoneal bladder translocation predominates. Considering the localization of the hernial sac in relation to the inferior abdominal vessels, medial hernias predominate (direct, simple). The above-mentioned pathology is more frequently observed in men. Right-sided scrotal cystocele is observed more frequently. Unfortunately, more than twice as often diagnosis is established intraoperatively, or during the postoperative period (2, 5, 11).

Diagnosis is based on a detailed medical history concerning disorders of urination. It is necessary to thoroughly assess the hernial ring and analyse the contents of the hernial sac. Amongst useful imaging examinations one should mention the following:

- ascending cystography considered as the „golden standard”,
- cystoscopy,
- abdominal ultrasound of the inguinal area and scrotal sac (12, 13),

- abdominal and pelvic CT,
- urography more rarely, due to poor visualization of the hernial sac.

Currently, in the PubMed database the term „scrotal cystocele” is cited in 30 articles. The term „bladder hernia” was observed in 155 cases, while „inguinal hernia with bladder” might be present in 509 studies.

## CONCLUSIONS

Scrotal cystocele is very rarely encountered. In most cases the above-mentioned disease entity is diagnosed during the postoperative period, based mainly on the presence of persistent urinary bladder leakage, and pathological urine secretion from the operative wound (14, 15). This prompts the surgical team to expand the urological diagnosis. Delayed diagnosis is often the cause of costly postoperative complications (16). It is extremely important for the surgeon to know the anatomical variant described earlier. This enables efficient preparation and hernial plasty, so important for the patient (tab. 1).

Table 1. Scrotal cystocele-management scheme

Opening of the inguinal canal and scrotal sac
Preparation of the hernial sac and its contents
Reduction of the hernial sac to the retropubic space
Resection of part of the urinary bladder (advanced inflammatory lesions, suspicion of neoplastic growth, narrow urinary bladder neck < 0,5 cm)
Hernioplasty using tension techniques (Bassini, Halsted)
The use of tension-free techniques with mesh implantation (Lichtenstein)
Hemostasis
Operative wound drainage (groin, scrotum)
Urinary bladder protection through prolonged urinary catheterization
Measurable benefits of perioperative antibiotics
Postoperative control of the surgical efficacy (cystography, cystoscopy, USG)

## REFERENCES

1. *Primates P, Goldacre MJ*: Inguinal hernia repair: incidence of elective and emergency surgery, readmission and mortality. *Int J Epidemiol*. 1996; 25 (4): 835-39.
2. *Oruç MT, Akbulut Z, Ozozan O et al.*: Urological findings in inguinal hernias: a case report and review of the literature. *Hernia* 2004; 8: 76-79.
3. *Gomella LG, Spires SM, Burton M et al.*: The surgical implications of herniation of the urinary bladder. *Arch Surg* 1985; 120: 964-67.
4. *Shelef I, Farber B, Hertzanu Y*: Massive bladder hernia: ultrasonographic imaging in two cases. *Br J Urol* 1998; 81: 492-93.
5. *Wagner AA, Arcand P, Bamberger MH*: Acute renal failure resulting from huge inguinal bladder hernia. *Urology*. 2004; 64 (1): 156-57.
6. *Regensburg RG et al.*: Micturition Related Swelling of the Scrotum. *Hernia* 2012; 16 (3): 355-57.
7. *Levine B*: Scrotal cystocele. *J Am Med Assoc* 1951; 147 (15): 1439-41.
8. *Redman JF, Williams EW, Meacham KR, Scriber LJ*: The treatment of massive scrotal herniation of the bladder. *J Urol* 1973; 110 (1): 59-61.
9. *Zajączkowski T*: Mosznowa przepuklina pęcherza moczowego. *Urol Pol* 2004; 3: 85-88.
10. *Krzemiński D, Szepietowski M, Nalej D, Lemański A*: Ześlizgowa przepuklina mosznowa z zawartością ściany pęcherza moczowego z lewostronnym poszerzeniem miedniczki nerkowej i moczowodu. *Urol Pol* 2006; 59: 2.
11. *Madden JL, Hakim S, Agorogiannis AB*: The anatomy and repair of inguinal hernias. *Surg Clin North Am* 1971; 51: 1269-92.
12. *Postma MP, Smith R*: Scrotal cystocele with bladder calculi (case report). *AJR Am J Roentgenol* 1986; 147 (2): 287-88.
13. *Thompson JE Jr, Taylor JB, Nazarian N, Ben-nion RS*: Massive inguinal scrotal bladder hernias: a review of the literature with 2 new cases. *J Urol* 1986; 136: 1299-1301.
14. *Bisharat M, O'Donnell M et al.*: Complications of inguinoscrotal bladder hernias: a case series. *Hernia* 2009; 13: 81-84.
15. *Prędki R, Kwias Z, Traczyk J*: Przypadek lewostronnej przepukliny pachwinowej z całkowitym przemieszczeniem pęcherza moczowego do moszny. *Urol Pol* 1994; 47: 4.
16. *Kim KH, Lee SW, Hur DS et al.*: Massive inguinal bladder hernia into the scrotum. *Korean J Urol* 2001; 42: 1011-12.

Received: 25.10.2015 r.

Address correspondence: 62-065 Grodzisk Wlkp., ul. Mossego 17

e-mail: b.cybulka@wp.pl