



Research Paper

Enchondroma of the Hand: Result of Surgery Curettage and Grafting and Possible Factors Affecting the Outcome

手部內生性軟骨瘤 - 外科刮除術的結果和可能影響結果的因素

Sun Tycus Tse Tao ^{a, b, *}, Keung Ip Fu ^{a, b}, Wong Tak Chuen ^{a, b}, Leung Priscilla Oi Yee ^{a, b}, Chan Jennette Sze Yan ^c^a Department of Orthopaedics and Traumatology, Pamela Youde Nethersole Eastern Hospital, Chai Wan, Hong Kong^b Department of Orthopaedics and Traumatology, Ruttonjee Hospital, Chai Wan, Hong Kong^c Department of Orthopaedics and Traumatology, Queen Mary Hospital, Pokfulam, Hong Kong

ARTICLE INFO

Article history:

Received 2 November 2015

Received in revised form

18 December 2015

Accepted 23 December 2015

Keywords:

chondroma

hand bones

operative

retrospective studies

risk factors

surgical procedures

treatment outcome

ABSTRACT

A retrospective review for enchondroma in the hand which had undergone operative treatment is presented. Twenty patients were treated operatively over a 10-year period. A total of 70% of the patients presented with pathological fracture. Enchondromas were most commonly located in the little finger (65%) and proximal phalange (60%). Enchondromas presented with pathological fractures and were treated definitively after the fracture had healed, except for one patient with open reduction, internal fixation of fracture, and bone grafting. All 20 patients underwent curettage of the enchondroma. In the same operative occasion, 16 patients received bone grafting, three patients received bone substitutes, and one had received bone cement. Fourteen (70%) of the patients suffered no major postoperative complications. Postoperative stiffness was encountered in seven patients. A secondary operation for relief of postoperative stiffness was performed in three patients. Factors were assessed for their risk of resulting in postoperative stiffness and occurrence of secondary operation. Factors included sex, age, pathological fracture, location of lesion, and preoperative stiffness. Only preoperative stiffness was a statistically significant risk factor contributing to postoperative stiffness and occurrence of a secondary operation.

中文摘要

這是一個關於用外科刮除術來治療手部內生性軟骨瘤的回顧性研究。在10年內有20例患者接受手術治療。當中70%病例呈現病理性骨折。內生性軟骨瘤最常位於小指(65%)和近端指骨(60%)。除了一個接受了開放性復位、內固定和自體骨移植的病例之外,所有呈現病理性骨折的病例都是在骨折癒合後才進行骨瘤治療。所有20名患者都接受了經歷了外科刮除術。當中16例接受了骨移植,3例接受了人工骨,1例接受了骨水泥。十四例(70%)沒有重大術後併發症。7例出現術後關節僵硬,當中3例因而要進行第二次手術。我們評估了可能導致術後僵硬和需要進行第二次手術的各種風險因素,包括性別、年齡、骨瘤的位置和術前的關節僵硬程度等。我們發現只有術前的關節僵硬程度是達到統計學上意義的風險因素。

Introduction

Chondroma is the second most common benign bone tumor following osteochondroma. A total of 13.4% of benign tumours are chondromas according to the Mayo clinic series.¹ Chondromas are benign tumours from cartilage origin,² composed of mature hyaline cartilage. Chondromas are further classified according to the

location with reference to bones. Chondromal lesions which are centrally located in the bone are called enchondromas. Chondromal lesions which are more eccentric and lead to bulging of the adjacent periosteum are called periosteal chondromas. Chondromas can also be located outside of bones in the soft tissue. Enchondromas can be solitary or multiple. Multiple enchondromas are related to failure of normal endochondral ossification, and lead to the production of cartilaginous masses. For solitary enchondromas, 55% were diagnosed in the 2nd to 4th decades of life.² The age of presentation before the 2nd decade of life is younger in multiple

* Corresponding author. E-mail: tycustse@gmail.com.

enchondroma cases. The most common location of enchondromas is in the hand. In Dahlin's series,² 124 of 290 enchondromas (43%) were located in the hand, followed by the femur and humerus. Enchondromas are slow-growing tumours. They are often asymptomatic and diagnosed incidentally. However, some enchondromas are diagnosed with initial presentation of pain after minor trauma which results in a pathological fracture.

Curettage and bone grafting have been the conventional methods of treatment. Other treatment methods include curettage and filling of bone substitute, cementation, and additional chemical treatment. Results from surgery are usually good and the recurrence rate is low (2–15%).³ Postoperative stiffness and deformity may be encountered. Various factors that have affected the outcome of surgery have been previously discussed. In this study, we review our local experience and identify possible factors affecting the outcome of surgery.

Materials and methods

A retrospective review of patients with an enchondroma of the hand (confirmed by histology) receiving surgery from 2001 to 2012 was completed. Outcomes analysed include the postoperative clinical range of motion and radiological trabecular remodelling. Outcomes were analysed based on the final range of motion of fingers and the need for additional subsequent surgery.

The average follow-up duration was 22.7 months, ranging from 8 months to 72 months. Potential factors affecting outcome were identified for analysis. These factors include pathological fracture, preoperative finger stiffness, location of lesion in the little finger, older age, sex, and location of the lesion in the proximal phalange.

Results

Findings of presentation (Figure 1)

In this study period, 20 cases were reviewed. Ten were men and 10 were women. There was no sex predilection. The average age of the group was 42.1 years (16–77 years). A total of 55% of the patients were diagnosed in the 3rd and 4th decade of life.

The left hand was involved in 11 patients. The most common digit involved was the little finger (13 cases, 65%) followed by the ring finger (three cases, 15%) and middle finger (two cases, 10%). The index finger and thumb were each involved in one case. The proximal phalange was the most common location (12 cases, 60%), followed by the metacarpal bone (four cases, 20%). For lesions that were located in the middle phalange and distal phalange there were two cases for each location.

With regards to initial presentation, 14 (70%) patients had presented with pathological fractures after a variety of trauma. One patient was diagnosed from incidental findings after investigation of vague hand pain. Five patients had presented with the presence of local swelling over the involved digits. Of these five patients, two had noted progression of the size and two patients had reported the presence of mild pain. Joint stiffness was also present in two cases. For this study, the average duration of symptoms before operation was 22.8 months, ranging from 6 months to 48 months.

Surgical treatment and postoperative outcome

One patient required a primary open reduction and internal fixation of a displaced metacarpal pathological fracture, accompanied with curettage of the endochondroma and bone grafting. All the other 13 patients with an initial presentation of pathological fracture, received surgery after the fracture had healed by

conservative treatment. The average duration from fracture to final surgery was 12 months (4–36 months).

Curettage was performed for all 20 cases. Conventional dorsal approach to the phalange and metacarpal were used. Additional bone grafting had been performed in 16 cases with autograft (14 from iliac crest, one from distal radius, and one from olecranon). Instead of grafting, bone substitutes were employed in three patients and cement injection for the remaining one patient.

Additional concomitant surgeries were performed in two cases: open reduction and internal fixation for a displaced metacarpal pathological fracture in one case and extensor tenolysis for preoperative finger stiffness for another case.

Correct preoperative diagnosis of enchondroma was noted in 19 cases (95%). One patient with a lesion in the middle phalanx of the left little finger had been clinically diagnosed as fibrous dysplasia before the operation, but had been treated similarly by curettage and bone grafting. Subsequent histological diagnosis was reviewed as enchondroma.

There were no major complications from surgery in 14 cases. Postoperative finger stiffness was encountered early in five patients. Two patients had complained about donor site pain or related thigh numbness. Wound infection was encountered in one patient and successfully treated with a course of antibiotics. Excluding the case with cement injection, an average duration of 4.2 months (38 months) was required for trabeculae remodelling to appear on radiographs.

At the final review, 12 patients were symptom free (60%). One patient had donor site pain and lateral thigh numbness. Finger stiffness was noted in seven patients, six of them were mild (< 20° difference when compared with contralateral finger total active motion) and one had moderate stiffness (> 20° but < 40° loss). Four out of these seven patients had preoperative stiffness, and three were moderate. A second surgery of tenolysis was performed in three patients for stiffness. Additional capsulotomy was performed in all three settings and removal of the implant in one setting.

Another patient had complaints of swelling and pain at the distal phalanx at 2-years postoperation follow-up. However, the patient then defaulted follow-up in the clinic and definite evidence of recurrence could not be obtained.

Potential factors affecting outcome (Table 1)

Possible factors influencing surgical outcome were assessed. These factors included the presence of a pathological fracture, location of the lesion, age, sex, and preoperative finger stiffness.

Pathological fracture

Fourteen patients presented with pathological fracture, six patients (42.8%) had postoperative finger stiffness at final follow-up, and three patients (21.4%) had to undergo subsequent surgery to improve their range of motion. Among the six patients in the nonfracture group, only one had postoperative stiffness (16.7%) and none required additional surgery. The presence of a pathological fracture seemed to result in a poorer surgical outcome. However, this difference was not statistically significant.

Location of lesion

Of the 13 patients who had the lesion in the little finger, there were five patients (38.5%) with postoperative stiffness and three patients (23.1%) required subsequent surgery. Of the seven patients who had lesions in the other fingers, two patients (28.6%) had postoperative stiffness and none required further surgery. Lesions

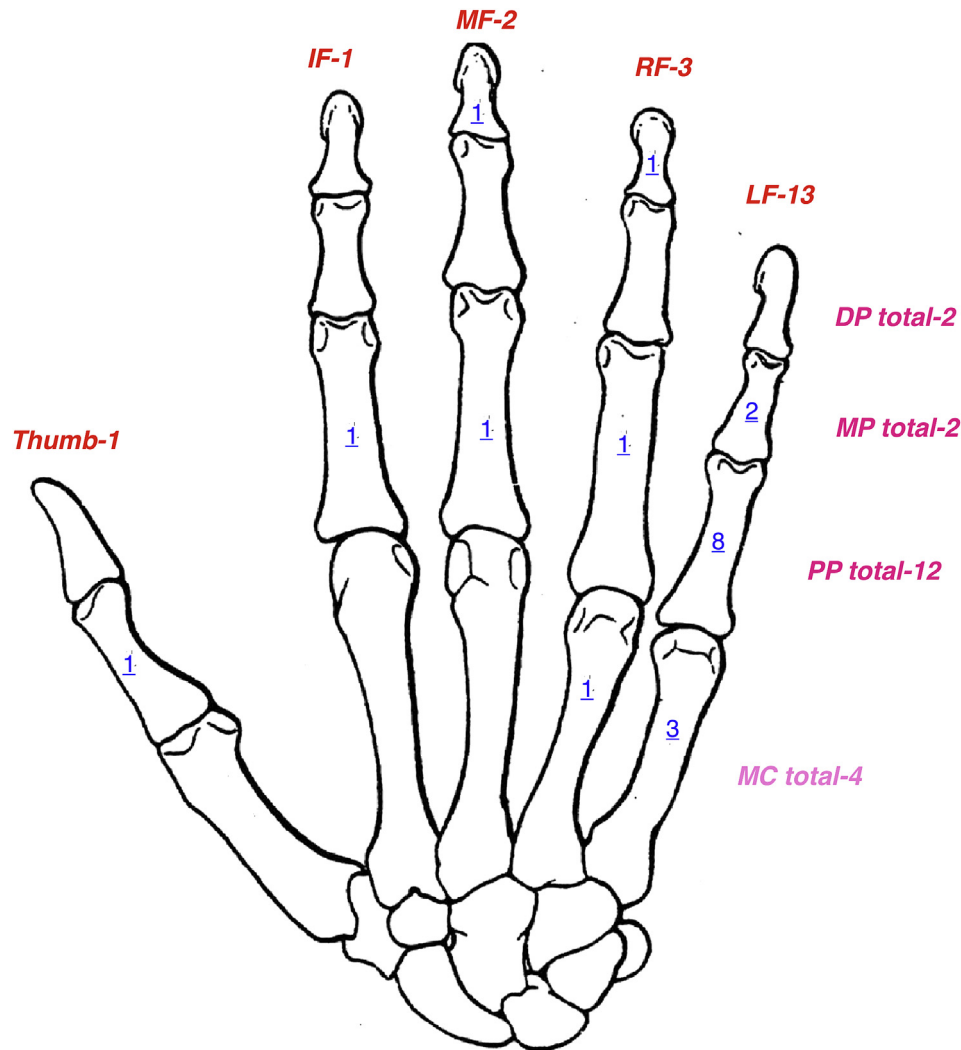


Figure 1. Distribution of enchondroma in this series. DP = Distal phalange; LF = Little finger; MC = Metacarpal bone; MP = Middle phalange; RF = Ring finger.

Table 1
Risk factors analysis for post-operation stiffness and subsequent operation

Risk factor groups:	Postop stiffness		<i>p</i>	Subsequent operation		<i>p</i>
	Subgroup: % of stiffness (no. cases of stiffness/total no. in subgroup)			Subgroup: % of subsequent operation (no. cases of subsequent operation/total no. in subgroup)		
Sex	Men: 30% (3/10)	Women: 40% (4/10)	1.00	Men: 20% (2/10)	Women: 10% (1/10)	1.00
Age (average 41.5 y)	Older than average age: 50% (5/10)	Younger than average age: 20% (2/10)	0.349	Older than average age: 30% (3/10)	Younger than average age: 0% (0/10)	0.2105
Pathological fracture	Fracture: 42.8% (6/14)	No fracture: 16.7% (1/6)	0.3544	Fracture: 21.4% (3/14)	No fracture: 0% (0/6)	0.5211
Location of lesion	Little finger: 38.5% (5/13)	Other fingers: 28.6% (2/7)	1.00	Little finger: 23.1% (3/13)	Other fingers: 0% (0/7)	0.5211
	Proximal phalange: 25% (3/12)	Others eg. DP/MP/MC: 50% (4/8)	0.356	Proximal phalange: 8.3% (1/12)	Others eg. DP/MP/MC: 25% (2/8)	0.536
Preoperative Stiffness	Preop stiffness present: 100% (4/4)	No preop stiffness: 18.8% (3/16)	0.0072*	Preop stiffness present: 50% (2/4)	No pre-op stiffness: 6.25% (1/16)	0.0877

DP = Distal phalange; MC = Metacarpal bone; MP = Middle phalange; postop = postoperative.

* Statistically significant.

in the little finger seemed to result in a poorer surgical outcome. However, this difference was not statistically significant.

Of the 12 patients who had lesions in the proximal phalange, there were three patients (25%) with postoperative stiffness and one patient (8.3%) required subsequent surgery. Of the eight patients who had lesions in the other bones (distal phalange, middle phalange, or metacarpal bone), four patients (50%) had postoperative stiffness and two patients (25%) required further surgery.

Lesions in the proximal phalanx appeared to have a slightly better surgical outcome. However, this difference was not statistically significant.

Age

The median age in the group was 41.5 years. In 10 patients older than the median age, five patients (50%) had postoperative stiffness

and three patients (30%) had subsequent surgery. Of the other 10 younger patients, two patients (20%) had postoperative stiffness and none required further surgery. Older patients seemed to have a poorer surgical outcome. However, this difference was not statistically significant.

Preoperative stiffness

Four patients had already suffered from stiffness of the fingers before surgery, though with improvement all (100%) of them still had stiffness after the operation, and two patients (50%) required subsequent surgery. Among the 16 patients without preoperative stiffness, postoperative stiffness was encountered in three patients (18.8%) and one patient (6.25%) required second surgery. The presence of preoperative stiffness was shown to result in a poorer postoperative outcome in terms of stiffness and requirement of further surgery. This difference was statistically significant.

Discussion

Tumours of the skeleton of the hand are rare. According to literature they account for 2–5% of all benign and malignant tumours of the skeleton.^{1,2} Among the benign bone tumours of the skeleton of the hand, enchondromas are the most common at 35–65%.²

Epidemiology

In previous literature, the proximal phalanx followed by the metacarpal are the common sites of lesions. For individual digits, the little finger is the most common digit involved. Figl and Leixnering⁴ reported a series of 35 cases of enchondroma in the hand. Seventeen were in the proximal phalanx (48.6%) followed by the metacarpal (eight cases, 22.9%). In the Sassoon et al⁵ series of 102 lesions, 40 were in the proximal phalanx (39.2%) and 24 (23.5%) were in the metacarpal. Gaulke,⁶ in a meta-analysis of 327 cases, 160 were in the proximal phalanx (48.9%) and 70 (21.4%) in the metacarpal. In the Goto et al⁷ study, there were 25 lesions, nine in the proximal phalanges (36%) and eight in the metacarpal (32%). In the present series, it was 60% and 20%, respectively.

For digit distribution, the little finger is the most common digit being involved with reported figures from 30% to 34.2%.^{5–7} In our present series, there was a higher incidence of the little finger being involved (65%). One possible reason is a higher chance of minor trauma to the little finger leading to diagnosis of enchondroma due to pain from impending or pathological fractures. Other asymptomatic lesions may remain undetected.

In various reports, there was no sex predilection for enchondromas and they were usually diagnosed in patients in aged in their 30s or 40s. The average ages in reported series were 36 years, 36 years, 39 years, and 39 years.^{4–7} In the Dahlin's series,² 35% were diagnosed in the 3rd and 4th decade. The average age in the present series was 42.1 years and 55% were aged in their 3rd and 4th decade. There was also no sex predilection. The epidemiology of the present series corresponds with reported literature.

Presentation and diagnosis

Patients may be asymptomatic or present with pain related to actual or impending pathologic fracture caused by the cortical weakening from expansile growth of the lesion. Frequency of pathological fracture and pain after trauma are reported as 43%, 65.7%, 100%, and 70%.^{4–6} The presence of a slow-growing swelling is the most common complaint for patients without trauma and pain. Five patients in the nontrauma group in the present series

presented with a slowly progressive swelling as their chief complaint.

Enchondroma usually can be diagnosed with plain radiography with typical features of a well-defined central lucency with or without speckles of calcification in the diaphysis or metaphysis of the bones of the hand. As the enchondroma grows, endosteal scalloping, cortical thinning, and expansile remodelling may occur. Five patients in the present series presented with local swelling as their chief complaint which corresponded to expansile remodelling. In cases of pathological fracture, as the trauma is usually trivial, displacement is mild and the fracture pattern is usually simple which makes conservative fracture treatment for healing feasible.

Treatment

Except for asymptomatic patients, surgery is usually indicated for histological diagnosis confirmation, pain reduction, and prevention from potential fracture. For patients presenting with pathological fracture, treatment of the pathologic fracture begins with a period of immobilization to achieve fracture healing. Thereafter, surgical treatment of the enchondroma is pursued. In the study by Sassoon et al⁵ on enchondromas of the hand with pathologic fracture, patients treated with immediate curettage and bone grafting and internal fixation had no significant difference in complication rates than patients treated in a delayed fashion.

The first step in the surgical treatment was an open biopsy through a small dorsal window. Curettage was then performed. The margin of the excision should be extended with a high-speed burr where sufficient bone exists. Chemical cauterisation of the cavity also may be performed with phenol. The decisive factor for successful treatment is the complete curettage of the tumour; we recommend usage of a high-speed burr. Curettage and autograft, with potential of mechanical stability, osteogenesis, osteoinduction, and osteoconduction, is the mainstay of treatment with satisfactory surgical outcome and low recurrence rate. Potential donor site morbidity is a concern. In the present series of 16 patients with autograft, one patient (6.25%) complained of persistent donor site pain and lateral thigh numbness which is symptomatic to the patient.

Goto et al⁷ reported treatment of 25 lesions with simple curettage without bone grafting. Replacement of the cortical window piece is recommended to enhance recovery of mechanical stability. Twenty-one had complete remodelling of the trabeculae and no recurrence was noted. However, potential of fracture in the presence of cortical thinning and lack of bony trabecular is a potential risk. Simple curettage of the lesion without intralesional bone grafting with replacement of the cortical window has been successful.⁷

An alternative method to autogenous bone grafting for filling the defect is the use of a bone substitute. Various types of bone substitute are available in the market. Gaasbeek et al⁸ reported results of treatment of 19 patients with curettage and filling with sterile calcium sulphate dihydrate/calcium phosphate. The material is gradually reabsorbed in an average of 10 weeks and gradually replaced by bony trabeculae. No recurrence is reported.

Yasuda et al⁹ reported the use of calcium phosphate bone cement to treat a series of enchondroma of the hand and foot with an average follow-up duration of 41 months. Incorporation of bone cement occurred at an average of 4.5 months with 2 cases showing partial incorporation only. At final follow-up, good functional results were achieved with no recurrence. Additional advantage of cement injection is immediate mechanical stability as advocated by Bickels et al¹⁰ in a series of 13 patients treated by curettage, bone cement filling, and intramedullary hardware.

In the present series, three patients are treated with bone substitute and one with cement for defect filling. Finger stiffness was noted in one case (25%) but no patients received second surgery. However, one patient with a lesion in the distal phalanx presented with recurrence of pain and swelling and a follow-up radiograph showing enlarging lucency and suspicion of recurrence.

Outcome from surgery is satisfactory as reported by various literatures. Though residual finger stiffness is not uncommonly encountered, they are usually not severe and there is no significant functional problem. In a review of 102 cases, Sassoon et al.⁵ reported that 68 patients (67%) had gained a full range of motion. Residual stiffness was mild and tenolysis was required in three patients.

In the present series, seven (35%) patients had residual stiffness at the final assessment, of which six of them were mild. Three patients received tenolysis surgery, of which one was performed at the time of curettage due to significant preoperative stiffness. The remaining 13 (65%) patients gained a full range of motion after operative treatment and rehabilitation. This result is compatible with the series by Sassoon et al.⁵

In this study, 14 of the patients suffered pathological fracture on presentation. In 13 of the patients, the fracture was first treated conservatively before proceeding to operative treatment. There was an average duration of 12 months before operative treatment was performed. Three cases waited exceptionally longer than others between the fracture and operative treatment (two cases for 36 months and one case for 24 months). These three patients required a longer duration due to two factors: (1) the duration of rehabilitation to reach improvement of satisfactory range of motion; and (2) the patient chose to delay operative treatment for personal reasons.

Recurrence after surgery was not high. In this study, none of the 20 cases had definite evidence of recurrence during follow-up periods.^{4,9,10} However, 7% and 14.3% recurrence rates were reported by Sassoon et al.⁵ and Gaulke.⁶ In this present series, the recurrence rate was 5%. Because enchondromas are slow-growing benign tumours, recurrence may remain asymptomatic for a long duration of time. It is recommended to have an extended period of follow-up assessment before the more realistic recurrence rate can be assessed.⁶

In this review, outcome assessment was based on the final range of motion of fingers and the need for second surgery. It was suspected that patients with pathological fracture, preoperative finger stiffness, lesion in little finger, and older age have less satisfactory outcomes. However, lesions in the proximal phalanx appear related to more satisfactory outcomes than other locations. This series showed that only preoperative stiffness was a statistically significant factor. We suspected that prolonged immobilisation in the management of pathological fracture may have contributed to the stiffness. We suggest active rehabilitation and controlled early mobilisation to be helpful in retaining a good range of motion when the fracture is healed. When preoperative stiffness is encountered, tenolysis can be performed at the time of the tumour surgery.

Conclusion

Enchondroma is a benign bone tumour in the hand. The proximal phalanx and little finger are the most common sites of enchondroma. Most enchondromas present as a pathological fracture, although others can be asymptomatic. Curettage and bone graft is still the mainstay of treatment. Application of bone substitutes or bone cement had also shown good results. Outcomes after surgery are usually good and recurrence rates were low both in this series and previous literatures.

Residual stiffness of the fingers is not uncommon, though most of them are mild. Preoperative stiffness significantly affects postoperative outcome in terms of postoperative range of motion. Some significant postoperative stiffness might require further operation of adhesiolysis. Other factors affecting postoperative stiffness were assessed in this study (age, presence of pathological fracture, and location of lesion), but did not yield any conclusive findings. Limiting preoperative stiffness might improve the postoperative outcomes of range of motion. We suggest a more active mobilisation during the rehabilitation, both during treatment for the pathological fracture and after definite surgery to achieve a good range of motion before and after surgery to help the final functional recovery.

Conflicts of interest statement

The authors have no conflicts of interest to declare.

Funding/Support statement

No financial or grant support was provided for the work described in this article.

References

- O'Connor MI, Bancroft LW. Benign and malignant cartilage tumours of the hand. *Hand Clin* 2004;**20**:317–23.
- Dahlin DC. *Bone tumours. General aspects and data on 6,221 cases*. 3rd ed. Springfield: Charles C. Thomas Publisher; 1978. p. 28–39.
- Müller PE, Dürr HR, Wegner B, et al. Solitary enchondromas: is radiographic follow-up sufficient in patients with asymptomatic lesions? *Acta Orthop Belg* 2003;**69**:112–8.
- Figl M, Leixnering M. Retrospective review of outcome after surgical treatment of enchondromas in the hand. *Arch Orthop Trauma Surg* 2009;**129**:729–34.
- Sassoon AA, Fitz-Gibbon PD, Harmsen WS, et al. Enchondromas of the hand: factors affecting recurrence, healing, motion, and malignant transformation. *J Hand Surg Am* 2012;**37**:1229–34.
- Gaulke R. The distribution of solitary enchondromata at the hand. *J Hand Surg Br* 2002;**27**:444–5.
- Goto T, Yokokura S, Kawano H, et al. Simple curettage without bone grafting for enchondromata of the hand: with special reference to replacement of the cortical window. *J Hand Surg Br* 2002;**27**:446–51.
- Gaasbeek RD, Rijnberg WJ, van Loon CJ, et al. No local recurrence of enchondroma after curettage and plaster filling. *Arch Orthop Trauma Surg* 2005;**125**:42–5.
- Yusuda M, Masada K, Takeuchi E. Treatment of enchondroma of the hand with injectable calcium phosphate bone cement. *J Hand Surg* 2006;**31**:98–102.
- Bickels J, Wittig JC, Kollender Y, et al. Enchondromas of the hand: treatment with curettage and cemented internal fixation. *J Hand Surg* 2002;**27**:870–5.