

Sentinel Lymph Node Biopsy in Well Differentiated Thyroid Cancer

Tamara Mijovic, Keith Richardson, Richard J. Payne and Jacques How
*McGill University, Montréal,
Canada*

1. Introduction

The management of occult cervical lymph node metastasis in well-differentiated thyroid cancer (WDTC) is controversial. Given the risks of hypocalcemia, recurrent laryngeal nerve injury, and increased operative time with a central compartment neck dissection (CCND), a routine adoption of prophylactic lymph node dissection has not been accepted by many as a standard management for occult metastasis (Henry et al., 1998; Pereira et al., 2005; Shen et al., 2010). Conversely, other thyroid surgeons feel that the complication rate is low and that the benefits of CCND outweigh the risks (Anand et al., 2009; Haigh et al., 2000; Keleman et al., 1998; Pelizzo et al., 2001; Pitman et al., 2003; Rettenbacher et al., 2000). As a result, sentinel lymph node biopsy (SLNB) has gained an increase in popularity in recent years.

The principle of SLNB and its historical rise in other fields will be the starting point of the chapter. The SLN is defined as the first lymph node in a regional lymphatic basin receiving lymph flow from a primary tumor. For the past nineteen years, SLNB has been an acceptable technique for identifying the presence of metastatic disease for cutaneous melanoma (Morton et al., 1992) and early breast cancer (Giuliano et al., 1994; Krag et al., 1993). Lymphatic mapping with SLN permits staging of malignant tumors in an effort to avoid complete nodal dissection and its associated morbidity. The ideology behind SLN surgery follows the concept that the sentinel node is predictive of a primary tumor that has the potential to metastasize. If the sentinel node is positive, the pathological status of additional lymph nodes may be positive as well. Recently, SLNB techniques have been proposed for other tumor types, including lung, gastrointestinal and gynecologic malignancies (Makar et al., 2001), squamous cell carcinoma of the head and neck (Pitman et al., 2003; Taylor et al., 2001), colorectal cancer (Saha et al., 2000) and thyroid cancer (Pelizzo et al., 2001; Dixon et al., 2000).

To understand the applicability of SLNB in thyroid cancer, the cervical lymphatic anatomy will be reviewed. The mechanism of lymphatic tumoral spread in thyroid cancer and the clinical significance of such lymph node metastases will then be discussed. The arguments in favor and against prophylactic CCND will follow thereby providing the context in which the idea of the SLNB shows its advantages in the management of WDTC. The benefits of SLNB over a formal CCND will be discussed in the chapter with emphasis on the major advantages such as a decreased risk of hypocalcemia, decreased risk to the

recurrent laryngeal nerve (RLN) injury and decreased operative time. Different techniques of SLN biopsy will then be outlined and our detailed institutional protocol, the McGill Thyroid Injection Protocol, will be illustrated. A comprehensive review of the literature on the outcomes of SLNB in the approach to management of thyroid cancer will then follow. Our chapter will conclude by addressing the pitfalls of SLNB in WDTC including the potential causes of false-negative cases in addition to adverse events related to the procedure.

2. Sentinel lymph node biopsy, a tool for the surgeon

In the field of oncology, lymph node status is one of the most important prognostic factors and a key element of tumor staging. It is also a guide towards the appropriate therapy and overall a crucial component in the assessment of patients with cancer. The approach to management of metastatic lymph nodes goes from medical management to various degrees of surgical aggressiveness.

2.1 The principle

In 1960, Gould (Gould et al., 1960) was the first to introduce the concept of the sentinel lymph node. According to him, lymphatic flow is unidirectional, and there is orderly progression of cancer cells from the primary organ to the first lymph node in the chain before spreading to other regional lymph nodes. This first lymph node draining a regional lymphatic basin from a primary tumor is defined as the sentinel lymph node, and its histological status is thought to be representative of the status of the other nodes in the chain. The SLNB technique finds its place where formal lymph node dissection is associated with significant morbidity, such as the groin or axilla.

2.2 The history

In 1992, the technique for lymphatic mapping was first described by Morton (Morton et al., 1992) in patients with cutaneous malignancy, and was found to be not only simple and practical, but also reliable with a reported false-negative rate of less than 1%. This report introduced modern surgical oncologists to a new surgical technique with a wide range of applications. Subsequently, Giuliano (Giuliano et al., 1994) exported the technique to breast cancer and demonstrated a reliable identification of SLN using a vital blue dye. In the last two decades, SLNB has been validated as an accurate method for assessing lymph node status and has gained consensus as the standard of management for identifying regional lymphatic spread in melanoma and breast cancer. The use of this technique in the management algorithms is under investigations for other solid cancer including thyroid.

3. Cervical lymph nodes in thyroid cancer

3.1 The anatomy

There are 500 lymph nodes in the body and 200 of these are in the head and neck region (Grodski et al., 2007). Historically, the location of cervical lymphadenopathies has been described in terms of chains and triangles, but currently, the most used system of nodal mapping anatomically classifies lymph nodes into levels (Sakorafas et al., 2010).

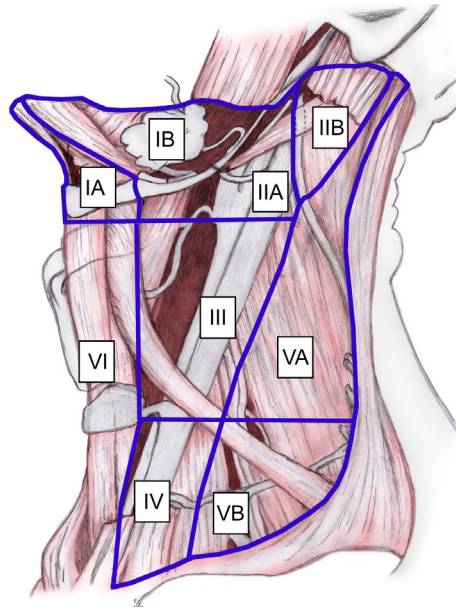


Fig. 1. Cervical lymph node levels (from Rugiero, 2008)

Level I is bound by the body of the mandible superiorly, stylohyoid muscle posteriorly, and the anterior belly of the digastric muscle on the contralateral side anteriorly. This level may be divided into level Ia, which refers to the nodes in the submental triangle (bound by the anterior bellies of the digastric muscles and the hyoid bone), and Ib, which refers to the submandibular triangle nodes.

Level II lymph nodes are related to the upper third of the jugular vein, extending from the skull base to the inferior border of the hyoid bone. The anterior border of level II is the stylohyoid muscle, and the posterior border is the posterior border of the sternocleidomastoid muscle. The spinal accessory nerve, which travels obliquely across this area, is used as a landmark to subdivide this group into IIB, the portion above and behind the nerve, and IIA, the part that lies anteroinferiorly and closer to the internal jugular vein.

Level III nodes are located between the hyoid superiorly and a horizontal plane defined by the inferior border of the cricoid cartilage. The sternohyoid muscle marks the anterior limit of level III, and the posterior border of the sternocleidomastoid muscle is the posterior border.

Level IV refers to the group of nodes related to the lower third of the jugular vein. These nodes are located between the inferior border of the cricoid cartilage and the clavicle, and, like level III, the anterior boundary is the sternohyoid muscle, and the posterior border is the posterior border of the sternocleidomastoid muscle.

Level V refers to the lymph nodes located in the posterior triangle of the neck. These include the spinal accessory, transverse cervical, and supraclavicular group of nodes. Level V is bound anteriorly by the posterior border of the sternocleidomastoid muscle and posteriorly

by the anterior border of the trapezius muscle. Level V extends from the apex of the convergence of the sternocleidomastoid and trapezius muscle superiorly to the clavicle inferiorly as shown below. This level is subdivided by a plane defined by the inferior border of the cricoid cartilage into level Va superiorly and level Vb inferiorly.

Level VI refers to lymph nodes of the anterior, or central, compartment of the neck. Defined by the carotid arteries laterally, the hyoid bone superiorly, and the suprasternal notch inferiorly, it is rich in lymphatics that drain the thyroid gland, subglottic larynx, cervical trachea, hypopharynx, and cervical esophagus. Lymph nodes in this compartment are located in the tracheoesophageal groove (paratracheal nodes), in front of the trachea (pretracheal nodes), around the thyroid gland (parathyroidal nodes), and on the cricothyroid membrane (precricoid or Delphian node) (Rugiero, 2008).

The thyroid gland contains a dense network of intrathyroidal lymphatics with communication across the isthmus. Lymphatic flow tends to be to the ipsilateral level VI lymph nodes primarily since thyroid lymphatics usually accompany a venous drainage pattern into the central compartment of the neck (Roh & Kock, 2010). The upper poles, along with the pyramidal lobe and isthmus also drain superiorly toward lymph node levels II/III while the lateral aspect of each lobe drain towards lymph node levels III/IV. The lower pole of the gland drains initially into level VI then goes on to levels IV and VII (Roh & Koch, 2010; Sakorafas et al., 2010).

3.2 Lymph nodes metastases in well-differentiated thyroid cancer

Papillary thyroid cancer (PTC) is the most common thyroid malignancy. It represents 75% of thyroid malignancies and 90% of WDTC. It spreads predominantly via the lymphatics to the local draining lymph nodes (Balasubramanian & Harrison, 2011). It is generally believed that the central cervical compartment is the primary zone of lymphatic involvement for all thyroid cancers except those located in the upper pole of the glands from which lymphatic drainage may flow directly into the lateral neck nodes (Henry et al., 1998). In keeping with the theory, Nogychi in a study of 68 patients after elective neck dissection, found 78% of nodal metastases in the paratracheal region and 22% in the jugular chain (Nogychi et al., 1987, as cited in Kelemen et al., 1998). Many groups have, however, reported that the risk of lymphatic metastases was greatest for the lateral nodal groups (level II, III and IV) (Caron et al., 2006; Gimm et al., 1998; Lee et al., 2008; Roh et al., 2007, 2008; Shah et al., 1990) while others have shown comparable rates of involvements in both the central cervical and lateral neck compartments (Machens et al., 2002).

Irrespective of location, lymph node metastases are a common finding in PTC and tend to occur relatively early. The incidence of lymph node metastases has been reported to be as high as 90% and the incidence of palpable disease ranges between 30-50% (Dixon et al., 2000; Grodski et al., 2007). Histological evidence of nodal metastases in patients with clinically node negative PTC is approximately 50% (Balasubramanian & Harrison, 2011), but rates anywhere between 25 to 90% have been reported in studies where elective neck dissections were performed on patients without suspicious lymphadenopathies (Cunningham et al., 2010). Interestingly, in a similar group of patients who were observed and did not undergo a neck dissection, the rate of recurrence was only 1.4%, thus questioning the clinical significance of such lymph node metastases (Kelemen et al., 1998).

3.3 Clinical significance of lymph nodes metastases

Most clinical trials confirm that regional nodes are usually the first site of recurrence (Kelemen et al., 1998). In fact, metastases to lymph nodes account for 75% of locoregional recurrence (Grodski et al., 2007). It is estimated that the risk for nodal recurrence is 30% to 50% during 10 years. The overall recurrence rate has been documented at 20%, with most of them discovered within 24 months. Of these, 70% are detected through a radioactive iodine whole body scan with only 40% being clinically apparent (Kelemen et al., 1998).

In a series of patients with nodal metastases and a final histological diagnosis of papillary, follicular, or Hürthle cell carcinoma, a recurrence rate of 19% has been recorded vs 2% in patients free of nodal disease (Kelemen et al., 1998). In an age-matched study of patients with differentiated thyroid cancer, recurrences were also more common among patients with nodal involvement (32 vs. 14%) (Grodski et al., 2007). The presence of central node metastases in the lymphadenectomy specimen is therefore an independent predictor of disease free survival but its actual significance on the overall prognosis remains controversial.

Although PTC lymph node metastases are reported by some to have no clinically important effect on outcome in low risk patients, a study among 9904 patients with PTC has found that lymph node metastases, along with other factors, predicted poor outcome on multivariate analysis (Podnos et al., 2005). All-cause survival at 14 years was 82% for PTC without lymph node and 79% with lymph node metastases ($p < 0.05$). Another recent study showed that lymph node involvement is an independent risk factor for decreased survival, but only in patients with follicular carcinoma and patients with papillary carcinoma over age 45 years (Zaydfudim et al., 2008). Multiple metastases and extracapsular nodal extension are other factors increasing the risk of regional recurrence (Leboulleux et al., 2005). However, in an analysis of 5123 patients over a 30-year period, even when corrected for TNM staging, a significantly higher mortality rate for patients with lymph node involvement has been shown (Grodski et al., 2007).

Despite these data, PTC has an excellent prognosis, but there is no doubt that lymphatic spread is associated with increased risk of loco-regional recurrence which may require an additional and more complicated surgery, overall significantly affecting patients' quality of life not only through the major psychological impact of cancer recurrence, but also through increased rates of all complications of exploration of scarred necks (Kelemen et al., 1998). We are therefore assisting to a paradigm shift in the aims of treatment of PTC, from a focus on survival to a focus of disease-free status as a valid endpoint to evaluate the effectiveness of therapy.

3.4 Cervical neck dissection in well-differentiated thyroid cancer

While few would argue against a formal therapeutic neck dissection in cases of macroscopic clinically apparent lymph node metastases in patients with WDTC, there is great heterogeneity in the surgical approaches to a clinically negative neck. Recommendations in the management of adenopathy associated with PTC are quite varied and include blind nodal sampling, central compartment neck dissection, and modified radical neck dissection (Anand et al., 2009). To eliminate the probability of leaving behind residual disease, routine total thyroidectomy with cervical lymph node dissection (CLND) would be theoretically the ideal operation. However, such an aggressive surgical approach will represent over-

treatment in a large percentage of patients, associated with longer surgical time and an unjustified increase of surgical morbidity (Sakorafas et al., 2010). Balancing the risk of increased morbidity from CLND with the benefit of removing a source of potential recurrence creates a controversial and difficult management decision. To help in the decision making process, guidelines for prophylactic CLND have been issued by different associations. Unfortunately, they remain vague and unclear with a certain degree of antagonistic recommendations.

3.4.1 In favor of prophylactic cervical lymph node dissection

Because of the high rate of occult lymph node metastases, their association with more frequent tumor recurrence and our inability to adequately identify these cases preoperatively, some experts argue in favor of routine prophylactic CLND in cases of WDTC. The British Thyroid Association (BTA) and the American Thyroid Association (ATA) are proponents of the prophylactic CLND (BTA, 2007; Cooper et al., 2009), especially in patients considered high risk. They maintain that the potential increased morbidity is small in experienced hands and hence a strong argument can be made for routine central CLND in all patients with WDTC and no known preoperative or intraoperative evidence of node involvement. More specifically, the ATA recommends prophylactic central neck dissection for patients with clinically uninvolved lymph nodes, especially for advanced tumors (T3 and T4 disease), and asserts that the central CLND may be appropriately omitted for T1 and T2 papillary and follicular thyroid cancers. They also acknowledge that omitting CLND for these smaller tumors, "may increase the chance of locoregional recurrence, but overall may be safer in less experienced surgical hands," to avoid the associated morbidity. This approach to microscopic nodal disease may result in fewer postoperative complications than routine dissection, but may fail to detect lymph node metastases in patients with smaller tumors, and may subject patients with larger tumors who do not have lymph node metastases to unnecessary lymph node resection. In addition, the guidelines allow for interpretation of these recommendations in the light of available surgical expertise at each institution, so that more invasive approaches are only recommended if experienced surgeons are available to carry them out, which is yet another factor contributing to the great variability in management.

Besides lower recurrence rates, prophylactic CLND has also the advantage of adequate staging, enhancing the effects of radioactive iodine by removing potentially positive lymph nodes while also lowering the postoperative thyroglobulin levels thereby facilitating follow-up (Grodski et al., 2007; Sakorafas et al., 2010).

In the discussion about the extent of prophylactic CLND in PTC, it should be remembered that the impact of the central compartment recurrence differs from that of a lateral compartment. It is generally accepted that lymph node metastases in the visceral compartment of the neck have greater clinical importance than metastases in the lateral neck areas (Henry et al., 1998). Reoperation for recurrence in the lateral compartment can be performed more easily than that for recurrence in the central compartment, where more critical structures (i.e., trachea, great vessels, etc) are located. Therefore, since metastases in the central compartment are very common, recurrences in the area are sometimes difficult to demonstrate, especially in males with a short and thick neck (Henry et al., 1998) and given that surgery for recurrence in the central compartment may be a complicated procedure,

prophylactic central CLND during the initial thyroid surgery (usually through the same incision) seems for many to be a reasonable management option (Sakorafas et al., 2010).

3.4.2 Against prophylactic cervical lymph node dissection

The American Association of Clinical Endocrinology, the American Association of Endocrine Surgeons (Cobin et al., 2001) and the NCCN do not recommend routine central CLND, particularly in low-risk patients with PTC. The argument against prophylactic CLND resides in the added complications associated with the procedure. The possible complications of central compartment neck dissection include hypoparathyroidism, injury to the recurrent and superior laryngeal nerves, hemorrhage and seroma (Sakorafas et al., 2010). The morbidity of prophylactic central neck dissection was evaluated in a study of 100 patients who underwent total thyroidectomy of which 50 patients with papillary thyroid cancer and no evidence of macroscopic metastases also had a prophylactic central neck dissection (Henry et al., 1998). In the group that had no neck dissection, there was no permanent hypoparathyroidism, but there were four cases of transient hypoparathyroidism (8%). In the group that underwent the prophylactic procedure, seven patients presented transient hypoparathyroidism (14%) and two patients (4%) remained with permanent hypoparathyroidism. The authors were also able to conclude that after total thyroidectomy for PTC, prophylactic central neck dissection does not increase recurrent laryngeal nerve morbidity but is responsible for a higher rate of hypoparathyroidism, especially in the early postoperative course (Henry et al., 1998). They attributed the hypoparathyroidism associated with neck dissection to the insufficiency of blood supply generated by the dissection. Similar rates of permanent hypoparathyroidism were also reported by Pereira (Pereira et al., 2005) (4.6%) with the extent of hypocalcemia correlating with the extent of surgery. A recent study by Mitra convincingly showed that total thyroidectomy combined with CCND led to a marked increase in both transient as well as permanent hypocalcemia (Mitra et al., 2011). These authors therefore concluded that the morbidity of bilateral cervical neck dissections is significant, and cautioned against the systematic implementation of this technique in the absence of gross nodal involvement.

Another factor contributing to the opposition towards routine lymph node dissection is the questionable usefulness of the procedure in preventing recurrence. Recent data has not demonstrated any therapeutic gain in achieving a significant reduction in local recurrence by adding CCND to total thyroidectomy (Zetoune et al., 2010). Despite the high frequency of microscopic lymph node metastases, the recurrence rate in patients with occult nodal disease who have not undergone nodal excision procedures has been reported as only 1.4% to 15% (McHenry et al., 1991; Shen et al., 2010; Takami et al., 2002) and the 5-year mortality rate ranges from 0.9% to 17% (Takami et al., 2002). To some, it therefore appears that there might be no real benefit for the patient to undergo more extensive surgery in presence of a clinically negative neck.

4. Sentinel lymph nodes biopsy in thyroid cancer

4.1 The middle ground in the controversy

The lack of consensus on the matter of prophylactic CLND validates the need for a modality with which the surgeon can rely on to accurately predict the necessity for the procedure.

Accordingly, being able to identify those patients who would benefit from nodal dissection before a more extensive procedure is undertaken would improve PTC management (Anand et al., 2009).

Preoperative ultrasound is unable to detect all metastatic lymph nodes in the central compartment of the neck (Roh & Koch, 2010) while intraoperative palpation and lymph node size assessment are not accurate predictors of lymph node status (Fukui et al., 2001). In this perspective, the SLNB is theoretically appealing for PTC since it could detect subclinical lymph node metastases, thereby allowing the formal CLND to be performed only in patients with documented lymph node metastases, thus avoiding the morbidity of CLND in a significant percentage of patients with node-negative disease. In other words, SLNB may be helpful in selecting patients who would benefit from CLND, thus reducing unnecessary surgery and possible morbidity in other patients (Roh & Koch, 2010; Sakorafas et al., 2010).

The main advantage of an accurate SLNB technique would be the identification of node-negative patients with thyroid cancer in whom an unnecessary prophylactic central node dissection could be avoided (Roh & Koch, 2010). It allows the surgeon to alter the surgical procedure in real time. Completing a central neck dissection at the time of initial surgery can also potentially avoid the higher complication rates that have been reported with reoperation in the central compartment. Another advantage of SLNB biopsy is that it may help identify, at the time of initial operation, patients who are likely to develop a challenging central compartment recurrence. The SLNB technique may also permit early detection of patients who may benefit from adjuvant radioactive iodine ablation (Anand et al., 2009; Roh & Koch, 2010). Alternatively, biopsies of sentinel lymph nodes may avoid the use of ablative ^{131}I treatment in patients with low-risk thyroid cancers with SLNs that are negative for metastases. Furthermore, malignant Hürthle cell tumors and well-differentiated follicular carcinomas are difficult to identify histologically, and SLNB in such cases may aid in establishing the diagnoses if metastases can be identified in SLNs (Takami et al., 2002).

In summary, the SLNB is an alternative approach that may guide the decision to proceed with formal lymphadenectomy. For this tool to be truly useful, it needs to accurately identify lymph node metastases, have a low false-negative rate and be associated with less morbidity than the formal CCND. SLNB for PTC has therefore been studied in several settings using different techniques; the sections that follow will review that data.

4.2 The technique

Since the introduction of the SLNB in PTC by Keleman (Keleman et al., 1998) several variations of the technique have been described. The variability resides mainly in the type of dye or isotope injected, the volume that was injected, the timing of injection, the site of injection and the subsequent assessment of the sentinel lymph node. Table 1 modified from the largest meta-analysis of SLNB in PTC, summarizes the techniques used in all the studies performed up to now on the topic (Balasubramanian & Harrison, 2011).

Vital blue dyes are the most frequently injected medium with methylene blue, isosulphan blue and patent blue V being the most common types. In general, methylene blue is found to be the least expensive and to generate less hypersensitivity reactions than the others. All of them, however, have been shown to have minimal reactivity except isosulfan blue.

Indeed, since rosaniline dyes are used in many commercially available products, including cosmetics, paper, and textiles, patients may be sensitized to isosulfan blue by previous exposure to apparently unrelated compounds. Moderate and severe allergic reactions, including anaphylaxis, have been reported in up to 2% of patients receiving isosulfan blue (Kelley and Holmes, 2011). All blue dye disappears during histologic processing and does not affect histologic analysis (Roh and Koh, 2010).

In terms of radioisotopes, different forms of ^{99m}Techneium labeled colloids have been used. The sentinel lymph node in these cases is localized either by a marking on the skin overlying the lymph node; alternatively, it can be localized by radiotracer using a gamma-probe intraoperatively.

Reference	n	Population	Dye/Isotope	Volume injected (mL)	Timing of injection	Injection site	Assessment of SLN
Cunningham et al. 2010	211	PTC	1% isosulphan blue	0.5-2	After mobilization	IT	FS and H
Anand et al. 2009	97	Suspicious and PTC	1% methylene blue	0.2-0.3	Before mobilization	PT	H
Takeyama et al. 2009	37	Suspicious and diagnostic	1% sulphan blue	0.1	Before mobilization	PT	FS and H
Lee et al. 2009	54	DTC	2% methylene blue	0.1-0.5	Before mobilization	PT	FS and H
Bae et al. 2009	11	PTC	2% methylene blue	0.5	After strap muscle retraction	IT	FS and H
Roh and Park, 2008	50	PTC	2% methylene blue	0.2	After strap muscle retraction	PT	FS and H
Wang et al. 2008	25	PTC	2% methylene blue	1-2	NA	PT	H
Rubello et al. 2006	153	PTC	0.5% patent blue V	0.25ml/cm	After strap muscle retraction	IT	FS and H
Abdella 2006	30	Benign nodules	1% isosulphan blue	0.5-1	After strap muscle retraction	IT	H
Peparini et al. 2006	9	PTC	2.5% patent blue V	0.1-0.2	NA	PT or IT	NA
Falvo et al. 2006	18	PTC	Methylene blue	0.4	After mobilization	IT	H
Dzodic et al. 2006	40	DTC	1% methylene blue	0.2	After strap muscle retraction	PT	FS and H

Reference	n	Population	Dye/Isotope	Volume injected (mL)	Timing of injection	Injection site	Assessment of SLN
<i>Chow et al. 2004</i>	15	PTC	2.5% patent blue V	0.5-1	After strap muscle retraction	IT	H
<i>Takami et al. 2003</i>	68	PTC	1% isosulphan blue	0.3	After strap muscle retraction	PT	FS and H
<i>Tsugawa et al. 2002</i>	38	PTC	1% patent blue VF	0.2-0.5	NA	IT	H
<i>Fukui et al. 2001</i>	22	PTC	2% methylene blue	0.1	After mobilization	PT	FS and H (but not all cases)
<i>Arch-Ferrer et al. 2001</i>	22	PTC	1% isosulphan blue	0.5	After mobilization	IT	H
<i>Catarci et al. 2001</i>	8	Suspicious and PTC	2.5% patent blue V	0.2-0.4	Before mobilization	IT	H
<i>Dixon et al. 2000</i>	40	Suspicious and DTC	Isosulphan blue	0.1-0.7	After strap muscle retraction	IT	FS and H
<i>Kelemen et al. 1998</i>	17	Suspicious and DTC	1% isosulphan blue	0.1-0.8	After strap muscle retraction	IT	FS and H
<i>Lee et al. 2009</i>	43	DTC	^{99m} Tc-labelled tin colloid	0.1-0.2	Preop US	IT	FS and H
<i>Boschin et al. 2008</i>	65	PTC	^{99m} Tc-labelled nanocolloid	0.1-0.2	Preop US	IT	FS and H
<i>Carcoforo et al. 2007</i>	64	Suspicious and PTC	^{99m} Tc-labelled nanocolloid	0.3	Preop US	PT	H
<i>Stoeki et al. 2003</i>	10	Suspicious and DTC	^{99m} Tc-labelled sulphur colloid	0.2	Preop US	PT and later IT	H
<i>Catarci et al. 2001</i>	8	Suspicious and PTC	^{99m} Tc-labelled colloidal albumin	0.1	Preop US	IT	H
<i>Rettenbacher et al. 2000</i>	9	Suspicious and DTC	^{99m} Tc-labelled nanocolloid	0.5	NA	IT	H

(Adapted from Balasubramanian & Harrison, 2011)

Legend: SLN, sentinel lymph node; SLNB, sentinel lymph node biopsy; PTC, papillary thyroid cancer; IT, intratumoral; PT, peritumoral; FS, frozen section; H, histology; DTC, differentiated thyroid cancer; US, ultrasound; NA, data not available.

Table 1. Characteristics of studies evaluating sentinel lymph node biopsy in thyroid surgery

We have found that the protocol currently used at our institution was easy to apply and had good outcomes (Figure 1). We therefore describe our technique in details. Following splitting of the strap muscles to expose the thyroid nodule, four quadrants around the tumor are injected with a total of 0.2cc's of methylene blue with a tuberculin syringe. At this juncture, one minute without manipulation is set aside to allow for diffusion of the dye. The lymphatic channels which stain blue (tract of blue dye, Figure 2) are then followed into the central compartment and associated blue lymph nodes are harvested and sent for frozen section analysis (Figure 3). Thyroidectomy is then performed. If there are no blue lymph nodes identified, thyroidectomy is performed. In either case, re-examination of the central

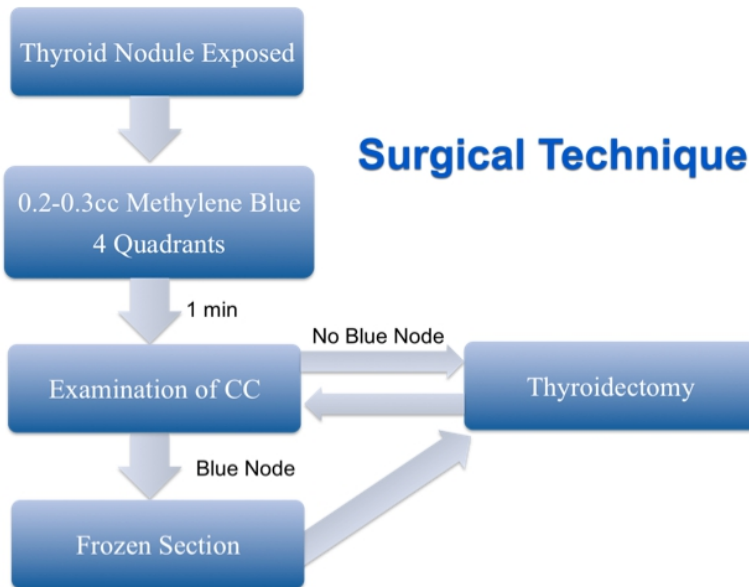


Fig. 1. Summary of the McGill Thyroid Injection Protocol

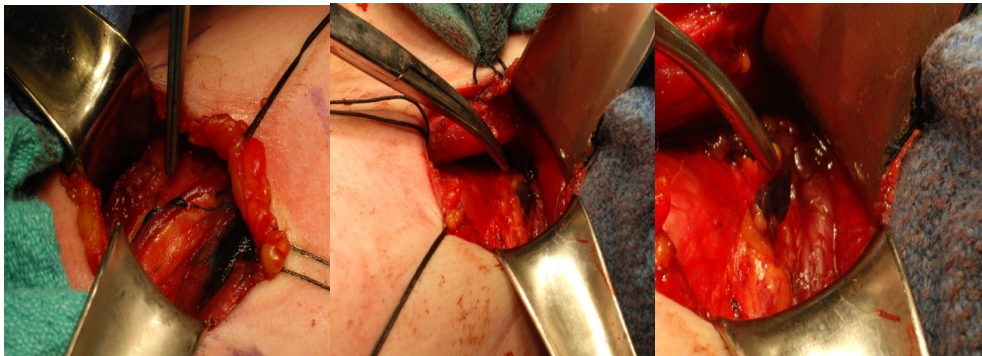


Fig. 2. Technique of SLN biopsy. Moments after injection of methylene blue, a tract of blue dye is seen heading towards the central compartment and pooling inside the SLN.

compartment is performed after thyroidectomy and all blue nodes are sent for frozen section analysis. All frozen section samples are submitted for permanent analysis following intra-operative assessment.

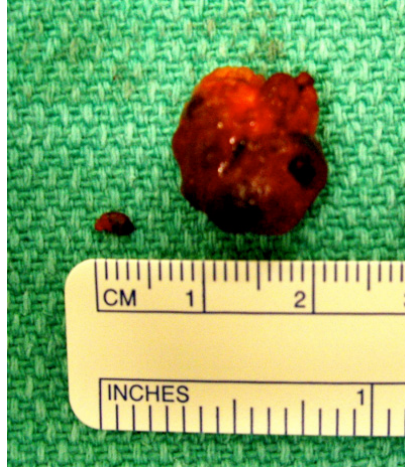

Fig. 3. The two lymph nodes above stained blue and were sent for frozen section analysis.

4.3 Review of outcomes

Keleman et al, in 1998, were the first to report the use of SLNB for thyroid carcinoma. Isosulfan blue dye was injected in 17 patients with thyroid neoplasms and the SLN was identified in 15 patients. SLN detection was missed in 11.8% of patients due to retrosternal localized SLN's and false-negative cases constituted 8%. Haigh & Giuliano in 2000 performed SLN biopsy in 17 cases and identified metastasis in 56% of cases. Notably, a control neck dissection was not carried out in all patients in both of these studies, and as such, positive and negative predictive values could not be determined. In a recent study, Cunningham et al (2010) performed a retrospective review of 211 patients and concluded that SLNB is feasible, safe and can identify patients who may benefit from CCND. As in the other previous studies, however, a CCND was not performed on all patients and thus a false negative rate could not be determined.

Given its aim of identifying the patients who do not require CCND, the single most critical qualitative descriptor for SLNB is the false-negative rate (FNR). This requires comparison of SLNB to a gold standard for the identification of occult metastases. The gold standard used varies from study to study. Most frequently, a control neck dissection is performed in all cases with its extent going from central compartment neck dissection only to a formal modified lateral neck dissection passing through a localized dissection of non-sentinel lymph nodes above and below the omohyoid (Dzodic, 2006). Another study used ^{131}I scan as the gold standard to help define the true-positive and true-negative SLN (Dixon et al., 2008).

Fukui et al conducted a study in 2001 on 22 patients with PTC who underwent a control lateral and central compartment neck dissection. SLN's were found in 21 of 22 patients

and the prediction of disease status was accurate in 19 of 21 patients (90%). Two false negatives were reported in this study. Using peritumoral injection of blue dye, Takami et al (2002) reported a 12.5% SLN FNR in a prospective study of 68 patients. Similarly, Roh et al (2007) reported a 22% FNR using peritumoral blue dye in 50 patients. In 2009, Anand et al published the largest prospective series on SLN biopsy to date (N = 98) showing the reliability of SLN biopsy in the management of well differentiated thyroid cancer. The study showed with a sensitivity of 100% that a negative SLN on permanent pathological analysis represents a negative central compartment. The primary goal of this study was to determine if the SLN in WDTC was indeed a sensitive predictor of the status of the central compartment while avoiding the possible confounding affect of frozen section analysis. For this reason frozen section analysis was not performed. In a recent study encompassing the largest series to date on the technique, frozen section analysis was employed to clarify its role in surgical practice. They studied a total of 157 patients injected with methylene blue. The sensitivity, specificity, positive predictive value and negative predictive value of the SLN biopsy technique to remove all disease from the central compartment was 92.9%, 100%, 100% and 98.8% respectively ($p < 0.0001$). This protocol would have eliminated the need for a CCND in 92% (144/157) in press (Richardson et al., in preparation).

A systematic review and meta-analysis of SLNB in thyroid cancer was recently published and looked at all the possible outcomes with the use of this technique (Balasubramanian & Harrison, 2011). Twenty-four studies were included in the analysis and great heterogeneity in techniques, assessment methodology and extent of nodal surgery were noted. The overall detection rate of SLN was 86.3% (blue dye 83.7%, and radioisotope 98.4%). The combined use of blue dye and radioisotope reached a detection rate of 96%. Sentinel lymph nodes with evidence of metastasis were present in 42.9% of patients with PTC and an identified SLNB. Following this positive SLN biopsy, 60.5% of patients had additional lymph node metastases identified on the neck dissection. The FNR of the blue dye technique was 7.7% while the radioisotope technique had a FNR of 16%. The combined techniques FNR was 0%. This meta-analysis also evaluated the methods of assessment of SLNB. It demonstrated that in this context simple frozen section was unreliable since it had a FNR of 12% (i.e. the frozen section was negative but the final histopathology of the same lymph node was positive). However, with the use of intraoperative immunohistochemical staining such as anticytokeratin and antithyroglobulin antibody, additional cases could be adequately identified thereby decreasing the FNR. This analysis concluded that SNB in thyroid cancer is a promising technique that has the potential to avoid prophylactic lymph node surgery in up to 57% of patients with clinically node-negative thyroid cancer. However, at this stage the data is still inconsistent and there appears to be a need for a more rigorous assessment of the SLNB technique in thyroid cancer.

4.4 Pitfalls of sentinel lymph node biopsy in papillary thyroid cancer

4.4.1 The false-negative rate

As described above, despite the more promising recent studies, FNRs as high as 22% have been reported and remain a serious concern regarding the value of SLNB (Sakorafas et al., 2010). Others have demonstrated that falsely negative SLNB happen even in cases of grossly positive metastatic PTC in the neck and have hypothesized that this is possibly occurring

because the normal path of lymphatic drainage was blocked by tumor-laden lymphatics (Dixon et al., 2000). In addition to blockage of lymphatics by tumor, lymphatic disruption during exposure of thyroid nodule or gland mobilization could also account for the lack of identification of the otherwise positive lymph node. We therefore recommend minimal dissection prior to injection of the dye.

It is also likely that the extensive lymphatic network in the neck complicates the practical application of the theoretical concept of SLNB in patients with thyroid cancer (Sakorafas et al., 2010). Noguchi et al., in 1987, demonstrated that up to 7% of thyroid metastases appear in the lateral compartment only, bypassing the central lymph nodes, which could explain the false-negative cases in studies limited to the central compartment.

Furthermore, the concept of "SLN blind spot" was introduced by some authors to account for some of the false-negative cases. They describe three such cases where a blue node adherent to the substance of the thyroid gland was found *ex vivo* by the pathologist, and might have not been found intraoperatively because the blue-stained thyroid gland masked the blue tract and blue node (Cunningham et al., 2010).

Given that lymph nodes harboring metastatic disease can be as small as 3 mm, the problem of a "crushed node" or a sample small enough that it may sacrifice permanent section has been reported. A pathologist with expertise in head and neck oncology, namely thyroid cancer, is therefore desirable for assessing the frozen section samples (Amir et al., 2011).

The lack of an approach toward multifocal disease is potentially another cause of false negatives. Indeed, while the dominant nodule may have been malignant, a non-dominant nodule also harboring disease that was not injected with methylene blue may be the source of the metastasis that is therefore missed because the nodule was not injected (Amir et al., 2011). Future studies designed to develop a novel approach to multifocal disease would therefore be very pertinent.

4.4.2 Adverse events related to sentinel node biopsy

In addition to the complications associated with a CCND that can follow a positive SLNB, the procedure of the SLNB has in itself been associated with some adverse events. From experience, we have noted that during injection, spillage of the dye may cause problems in identification of the sentinel lymph node, recurrent laryngeal nerve and parathyroid glands. This can, however, be easily overcome by slow intratumoral or peritumoral dye injection and immediate blotting of spillage at the injection site. One study has reported permanent hypoparathyroidism secondary to removal of a parathyroid gland that has stained blue (Cunningham et al., 2010). All degrees of skin responses to the blue dye have also been reported. For instance, methylene blue, despite its safety record, has been associated with intense erythema, superficial ulceration, and on one occasion a necrotic lesion (Kelley & Holmes 2011). Methylene blue-induced skin necrosis results from oxidation of surrounding tissues causing breakdown of cell membranes and inflammation, as well as a local vasoconstrictive effect due to methylene blue's inhibitory effect on nitric oxide. There is no increase in recurrent laryngeal injury rates associated with SLNB (Roh & Koch, 2010).

5. Conclusion

The management of occult cervical lymph node metastasis in WDTC is controversial. The SLNB is a safe and accurate method for assessing the possible involvement of the cervical lymph nodes by a primary thyroid tumour which allows for intraoperative decision making regarding the extent of neck dissection needed in each case. Despite the promising data, it might be too early to consider the SLNB technique as a standard of care in the management of patients with thyroid cancer. Several technicalities and pitfalls still need to be addressed. Most importantly, at this point, randomized controlled clinical trials are necessary to determine whether occult nodal metastases play a clinically significant role in longterm survival and disease-free survival, and whether SLNB and subsequent nodal management is associated with a survival benefit in patients with thyroid cancer.

6. References

- Amir, A.; Payne RJ.; Richardson, K.; Hier, M.; Mlynarek, AM.; Caglar, D. (2011). Sentinel Lymph Node Biopsy in Thyroid Cancer: It Can Work But There Are Pitfalls. *Otolaryngology Head and Neck Surgery*, (in press).
- Anand, SM.; Gologan, O.; Rochon L., Tamilia, M.; How, J.; Hier, MP.; Black, MJ.; Richardson, K.; Hakami, H.; Marzouki, HZ; Trifiro, M.; Tabah, R.; Payne, RJ. (2009) The Role of Sentinel Lymph Node Biopsy in Differentiated Thyroid Carcinoma. *Arch Otolaryngol Head Neck Surg*, Vol.135, pp. 1199-1204.
- Balasubramanian, S. & Harrison, BJ. (2011) Systematic review and meta-analysis of sentinel node biopsy in thyroid cancer. *Br J Surg*, Vol.98, pp. 332-344.
- British Thyroid Association, Royal College of Physicians. (2007) Guidelines for the management of thyroid cancer (Perros P, ed) 2nd edition. Report of the Thyroid Cancer Guidelines Update Group. London: Royal College of Physicians, 92p.
- Caron, NR.; Tan, YY.; Ogivlie, JB.; Triponez, F.; Reiff, ES.; Kebebew, E. (2006) Selective modified radical neck dissection for papillary thyroid cancer, Is level I, II and V dissection always necessary? *World J Surg*, Vol.30, pp.833e40.
- Cobin et al. (2001) AACE/AAES medical/surgical guidelines for clinical practice: management of thyroid carcinoma. *Endocr Pract*, Vol. 7, No.3, pp.(No. 3); 202-220.
- Cooper, DS.; Doherty, GM.; Haugen, BR.; Kloos, RT.; Lee, SL.; Mandel, SJ.; Mazzaferri, EL.; McIver, B.; Pacini, F.; Schlumberger, M.; Sherman, SI.; Steward, DL.; Tuttle, RM. 2009 Revised management guidelines for patients with thyroid nodules and differentiated thyroid cancer. *Thyroid* Vol.19, pp.1167-1214.
- Cunningham, DK.; Yao, KA.; Turner, RR.; Singer, FR.; VanHerle, AR.; Giuliano, AE. (2010). Sentinel Lymph Node Biopsy for Papillary Thyroid Cancer: 12 Years of Experience at a Single Institution. *Ann Surg Oncol*. Vol. 17, pp.2970-2975.
- Dixon, E.; McKinnon, JG.; Pasieka, JL. (2000) Feasibility of Sentinel Lymph Node Biopsy and Lymphatic Mapping in Nodular Thyroid Neoplasms. *World J Surg*, Vol. 24, pp.1396-1401.
- Dzodic, R. (2006). Sentinel Lymph Node Biopsy May Be Used to Support the Decision to Perform Modified Radical Neck Dissection in Differentiated Thyroid Carcinoma. *World J Surg*, Vol.30, pp.841-846.

- Fukui, Y.; Yamakawa, T.; Taniki, T.; Numoto, S.; Miki, H.; Monden, Y. (2001). Sentinel Lymph Node Biopsy in Patients with Papillary Thyroid Carcinoma. *Cancer*, Vol. 92, pp. 2868-2874.
- Gimm, O.; Rath, FW.; Dralle, H. (1998). Pattern of lymph node metastases in papillary thyroid carcinoma. *Br J Surg*, Vol. 85, pp.252e4.
- Giuliano, AE. et al. (1994). Lymphatic mapping and sentinel lymphadenectomy for breast cancer. *Ann Surg*, Vol. 220, No. 3, pp. 391-398
- Gould, E.; Winship, T.; Philbin, PH. (1960). Observations on a "sentinel node" in cancer of the parotid. *Cancer*, Vol.13, pp.77-78.
- Grodski, S.; Cornford, L.; Sywak, M.; Sidhu, S.; Debridge L. (2007). Routine level VI lymph node dissection for papillary thyroid cancer: surgical technique. *ANZ J Surg*. Vol. 77, pp.203-208.
- Henry, JF.; Gramatica, L.; Denizot, A.; Kvachenyuk, A.; Puccini, M.; Defechereux, T. (1998). Morbidity of prophylactic lymph node dissection in the central neck area in patients with papillary thyroid carcinoma. *Langenbeck's Arch Surg*, Vol.383, pp.167-169.
- Kelemen, PR; VanHerle, AJ; Giuliano, AE. (1998). Sentinel Lymphadenectomy in Thyroid Malignant Neoplasms. *Arch Surg*, Vol. 133, pp.288-292.
- Kelley, LM & Holmes, D.R. (2011). Tracer agents for the detection of sentinel lymph nodes in breast cancer: current concerns and directions for the future. *Surg Oncol*, Vol. 104, pp. 91-96.
- Krag, DN, et al. (1993). Surgical resection and radiolocalization of the sentinel lymph node in breast cancer using a gamma probe. *Surg Oncol*, Vol. 2, No. 6, pp.335-339.
- Leboulleux, S.; Rubino, C.; Baudin, E.; Caillou, B.; Hartl, DM.; Bidart, JM.; Travagli, JP.; Schlumberger, M. 2005 Prognostic factors for persistent or recurrent disease of papillary thyroid carcinoma with neck lymph node metastases and/or tumor extension beyond the thyroid capsule at initial diagnosis. *J Clin Endocrinol Metab*, Vol. 90, pp.5723-5729.
- Lee, J.; Sung, TY.; Nam, KH.; Chung, WY.; Soh, EY.; Park, CS. (2008). Is level IIB lymph node dissection always necessary in N1b papillary thyroid carcinoma patients? *World J Surg*, Vol. 32, pp. 716e21.
- Machens, A.; Hinze, R.; Thomusch, O.; Dralle H. Pattern of nodal metastasis for primary and reoperative thyroid cancer. *World J Surg*, Vol. 26, pp.22e8.
- Makar, A.P.H., et al., (2001). Surgical management of stage I and II vulvar cancer: The role of the sentinel node biopsy. Review of literature. *Int J Gynecol Cancer*, Vol. 11, No. 4, pp. 255-262.
- McHenry, C.; Rosen IB.; Walfish PG. (1991). Prospective Management of Nodal Metastases in Differentiated Thyroid Cancer. *Am J Surg*, Vol. 162, pp. 353-356.
- Mitra, I, et al. (2011). Effect of central compartment neck dissection on hypocalcemia incidence after total thyroidectomy for carcinoma. *J Laryngol Oto*, Vol.125, No.5, pp.497-501.
- Moo, T & Fahey III, TJ. (2011). Lymph node dissection in papillary thyroid carcinoma. *Seminars in Nuclear Medicine March*, Vol. 41, pp. 84-88.

- Morton, D.L., et al. (1992). Technical details of intraoperative lymphatic mapping for early stage melanoma. *Arch Surg*, Vol. 127, No.4, pp. 392-399.
- Noguchi, S.; Murakami, N. (1987). The value of lymph-node dissection in patients with differentiated thyroid cancer. *Surg Clin North Am*, Vol. 67, pp. 251-261.
- Pelizzo, MR.; Boschin, IM.; Toniato, A.; Bernante, P.; Piotto, A.; Rinaldo, A.; Ferlito A. (2001). The Sentinel Node Procedure with Patent Blue V Dye in the Surgical Treatment of Papillary Thyroid Carcinoma. *Acta Otolaryngol*. Vol. 121, pp. 421-424.
- Pereira, JA.; Jimeno, J.; Miquel, J.; Iglesias, M.; Munne, A.; Sancho, JJ.; Sitges-Serra, A. (2005). Nodal yield, morbidity, and recurrence after central neck dissection for papillary thyroid carcinoma. *Surgery*. Vol. 138, pp.1095-1101.
- Pitman, K.T., et al. (2003). Sentinel lymph node biopsy in head and neck cancer. *Oral Oncol*, Vol. 39, No, 4, pp. 343-349.
- Podnos, YD.; Smith, D.; Wagman, LD.; Ellenhorn, JD. (2005). The implication of lymph node metastasis on survival in patients with well-differentiated thyroid cancer. *Am Surg*, Vol. 71, pp.731-734.
- Rettenbacher, L.; Sungler, P.; Gmeiner, D.; Kässmann, H.; Galvan, G. (2000). Detecting the sentinel lymph node in patients with differentiated thyroid carcinoma. *Eur J Nucl Med*, Vol. 27, pp. 1399-1401.
- Richardson, K, et al. (2011). Sentinel Lymph Node Biopsy in Well Differentiated Thyroid Cancer. *Head & Neck*, (in press).
- Roh, JL.; Kim, JM.; Park, CI. (2008). Lateral cervical lymph node metastases from papillary thyroid carcinoma: pattern of nodal metastases and optimal strategy for neck dissection. *Ann Surg Oncol* Vol. 15, pp. 1177e82.
- Roh, JL. and Koch, WM. (2010). Role of sentinel lymph node biopsy in thyroid cancer. *Expert Rev Anticancer Ther*, Vol. 10, No.9; 1429-37.
- Roh, JL.; Park, JY.; Park, CI (2007). Total thyroidectomy plus neck dissection in differentiated papillary thyroid carcinoma patients: pattern of nodal metastasis, morbidity, recurrence, and postoperative levels of serum parathyroid hormone. *Ann Surg*, Vol. 245, pp. 604e10.
- Rugiero, FP. (July 29, 2008) Classification of Neck Dissection, In: *E-Medicine*, July 11, 2011, Available from: <http://emedicine.medscape.com/article/849834-overview>.
- Sakorafas, GH.; Sampanis, D.; Safioleas, M. (2010). Cervical lymph node dissection in papillary thyroid cancer: Current trends, persisting controversies, and unclarified uncertainties. *Surg Oncol*, Vol. 19, pp.e57-e70.
- Saha, S., et al. (2000). Sentinel lymph node mapping in colorectal cancer--a review. *Surg Clin North Am*, Vol.80, No. 6, pp. 1811-9.
- Shah JP. (1990). Cervical lymph node metastases diagnostic, therapeutic and prognostic implications. *Oncology*, Vol. 4, pp. 61e9.
- Shen, WT et al. (2010). Central neck lymph node dissection for papillary thyroid cancer: The reliability of surgeon judgment in predicting which patients will benefit. *Surgery*, Vol.148, pp. 398-403.
- Taylor, R.J., et al. (2001). Sentinel node localization in oral cavity and oropharynx squamous cell cancer. *Arch Otolaryngol Head Neck Surg*, Vol. 127, No.8, pp. 970-4.

- Takami, H.; Sasaki, K.; Ikeda, Y.; Tajima, G.; Kameyama, K. (2002). Thyroid Sentinel lymph node biopsy in patients with thyroid carcinoma. *Biomed Pharmacother*, Vol. 56, pp.83s-87s.
- Zaydfudim, V.; Feurer, ID.; Griffin, MR.; Phay, JE. (2008) The impact of lymph node involvement on survival in patients with papillary and follicular thyroid carcinoma. *Surgery*, Vol. 144, pp. 1070-1077.
- Zetoune, T et al. (2010). Prophylactic Central Neck Dissection and Local Recurrence in Papillary Thyroid Cancer: A Meta-analysis. *Ann Surg Oncol*, pp 3287-3293.