

GIANT ACROCHORDON OF LEFT SIDE NECK , A RARE CASE FINDING

Syed Mohd Faiz, Anuja Bhargava, Saurabh Srivastava, Harsha Singh, Deepika Goswami, Priyanka Bhat

Department of ENT

Era's Lucknow Medical College & Hospital, Sarfarazganj Lucknow, U.P., India-226003

Received on : xx-xx-xxxx

Accepted on : xx-xx-xxxx

Acrochordon are small, benign skin lesions with average size of 2-5 mm but larger lesions known as giant skin tags are rarely found in literature. Skin tags affects any age, including infants and can be frequently seen alone, but in some cases, can be associated with colonic polyp (Gardner syndrome) diabetes, or obesity. Theories about the causes include genetic predisposition, metabolic syndrome, hyperinsulinemia, and even virus infection (papillomavirus) Acrochordon is a clinical diagnosis and generally does not need histopathological confirmation . We are reporting a rare case of giant acrochordon of 1.5 cm found in neck.

Address for correspondence

Dr. Harsha Singh

Department of ENT

Era's Lucknow Medical College &
Hospital, Lucknow-226003

Email: harshasinghsmc@gmail.com

Contact no: +91-9599742014

KEYWORDS: Acrochordon, Metabolic syndrome, Birt-hogg-dube syndrome.

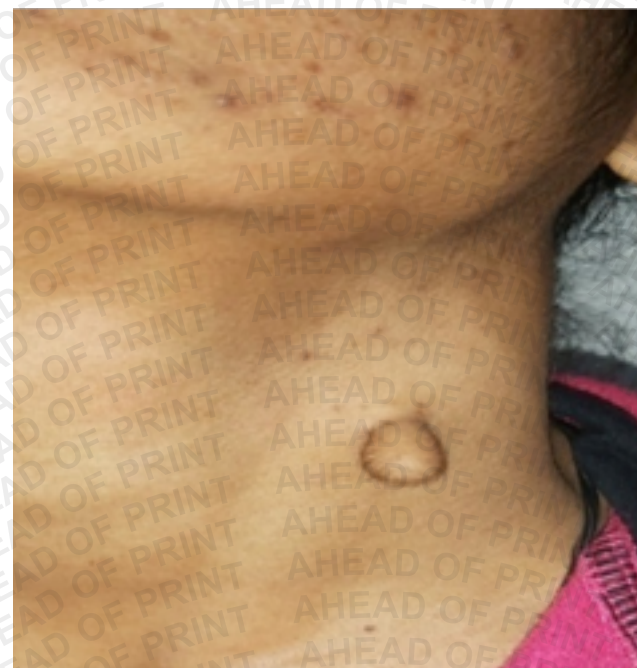INTRODUCTION

An acrochordon is a small, soft, common, benign, usually pedunculated neoplasm that is found particularly in persons who are obese. It is usually skin colored or hyper pigmented, and it may appear as surface nodules or papilloma on healthy skin. Although skin tags are said to involve nearly 46% of the human population, yet there are only a few case reports of giant skin tags in the literature (1). Etiology is unknown but they are known to occur in areas with sparse elastic tissue. Hormonal imbalance has also been postulated for their development. Other factors which promote their growth are TGF, EGF. Acrochordon is a clinical diagnosis and generally does not need histopathological confirmation. Histopathology as such shows acanthotic, flattened or frond like epithelium. Dermis is composed of loosely arranged collagen fibers with dilated lymphatic vessels and capillaries. Patient presents with small, soft usually pedunculated lesion. they are most commonly found on axilla, neck, inguinal folds. Mostly they are 2-5mm in diameter however larger ones are known to exist. They may be skin colored or hyper-pigmented. Acrochordons are benign lesions so immediate removal is not necessary. Various treatment options which are available are snip excision, cryotherapy, shave excision, electrodissection. Without histopathological confirmation acrochordon can't be differentiated from benign melanocytic nevi and neurofibromatosis. However, such histopathological differentiation is not needed as all are benign lesions and it will not affect treatment protocol. Other differential diagnosis include seborrheic keratosis, warts, lipoma, cysts, and neurofibroma (2). Multiple

fibrofolliculomas, trichodiscomas, and acrochordons compose the triad of cutaneous lesions characterizing the Birt-Hogg-Dubé syndrome, inherited in an autosomal dominant fashion.

CASE REPORT

A 22 year old female came with complaint of pedunculated mass over left side of neck present since birth, about the size of pea to start with and gradually progressed to the current size of 1.5cm in length (Fig 1). Ultrasound neck showed heterogenously hypoechoic space occupying lesion in left cervical region suggestive of lipoma Excisional biopsy is planned for this unusual achrochordon of neck.



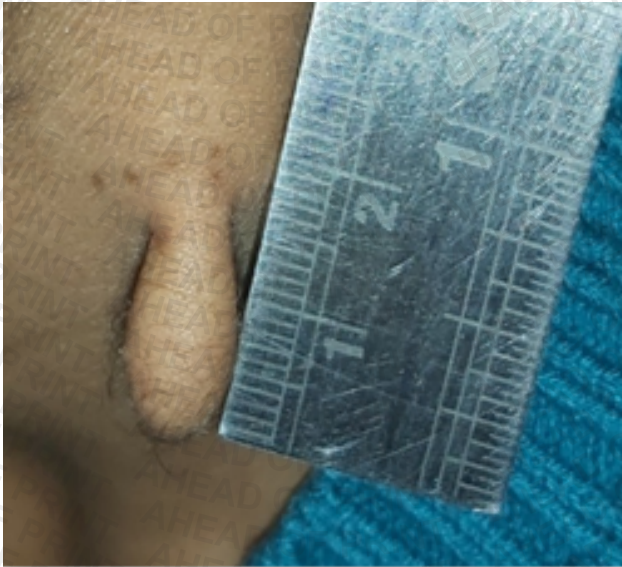


Fig 1: Picture Showing Anterior and Lateral view of Achrochordon of Neck

DISCUSSION

Skin tags are the most common fibrous lesions of skin and present with skin colored to hyperpigmented lesions they are usually asymptomatic but can be painful due to torsion, infarction, necrosis, attaining a reddish brown colour. They are usually 2-5 mm in size. In our patient the skin tag attained a 1.5 cm, such giant skin tags are rare to find. As there are only few reports of such giant skin tags in literature therefore differential diagnosis of the same should be kept in mind while dealing with bulky skin tumor (3-4). Skin tags affect any age, including infants and can be frequently seen alone, but in some cases, can be associated with colonic polyp (Gardner syndrome) diabetes, or obesity. An association between skin tags and insulin resistance has been found previously; these lesions are also considered marker for increased risk of cardiovascular disease (5). Theories about the causes include genetic predisposition, metabolic syndrome, hyperinsulinemia, and even virus infection (papillomavirus) (6-7). Previous reports in the literature have reported association between lipid profile and hypertension in patients with acrochordons (8-10). Men and women are equally affected and close to 50% of all individuals have at least one skin tag (3).

CONCLUSION

Acrochordons, also called skin tags, are very common benign skin growths. The cause of acrochordons is unknown, however there are several theories. Irritation or friction to the skin, as occurs with skin rubbing on skin in body folds, may play a role in their formation. Acrochordons are harmless and do not require removal. Typical skin tags can be removed for comfort or cosmetic purposes either by scissor excision, electrocautery (burning), or cryosurgery (freezing).

REFERENCES

1. Ghosh SK, Bandy Opadhyay D, Ghattejee G, et al. Giant skin tags on unusual locations. *J Eur Acad Dermatol Venereol*. 2009; 23: 237.
2. Banik R, Lubach D. Skin tags: localization and frequencies according to sex and age. *Dermatologica*. 1987; 174: 180-183.
3. Farshchian M, Soltanieh E, Mousavi I, et al. A Case Report of Giant Skin Tag. *Iran J Dermatol* 2009; 12:136-138.
4. Canalizo-Almedia S, Mercadillo PP, TiradoSanchez A. Giant skin tags: Report of two cases. *Dermatol Online J*. 2007; 13:30.
5. Sari R, Akman A, Alpsoy E, et al. The metabolic profile in patients with skin tags. *Clin Exp Med*. 2010; 10:193-197.
6. Tamega Ade A, Aranha AM, Guiotoku MM, et al. Association between skin tags and insulin resistance. *An Bras Dermatol*. 2010; 85: 25-31.
7. Gupta S, Aggarwal R, Gupta S, et al. Human papillomavirus and skin tags: Is there any association? *Indian J Dermatol Venereol Leprol*. 2008; 74: 222-225.
8. El Safoury OS, Abdel Hay RM, Fawzy MM, et al. Skin tags, leptin, metabolic syndrome and change of the life style. *Indian J Dermatol Venereol Leprol*. 2011; 77: 577-580.
9. Shaheen MA, Abdel Fattah NS, Sayed YA, et al. Assessment of serum leptin, insulin resistance and metabolic syndrome in patients with skin tags. *J Eur Acad Dermatol Venereol*. 2012; 26: 1552-1557.
10. Gorpelioglu C, Erdal E, Ardicoglu Y, et al. Serum leptin, atherogenic lipids and glucose levels in patients with skin tags. *Indian J Dermatol*. 2009; 54: 20-22.

