

Eczema: A Proposed Reclassification Based on the Signature Pathology Finding of Occluded Sweat Ducts

Herbert B. Allen*, Catherine A. Warner and Suresh G. Joshi

Drexel University College of Medicine Institutional Review Board, USA

*Corresponding author: Herbert B. Allen, Drexel University College of Medicine, Philadelphia, USA, Tel: 2157625550; Fax: 215 7625570; E-mail: Herbert.Allen@drexelmed.edu

Received date: February 01, 2016; Accepted date: March 25, 2016; Published date: April 01, 2016

Copyright: © 2016 Allen HB, et al. This is an open-access article distributed under the terms of the Creative Commons Attribution License, which permits unrestricted use, distribution, and reproduction in any medium, provided the original author and source are credited.

Abstract

Occluded sweat ducts are the hallmark of miliaria. The occlusions were thought to be due to biofilm or “slime” producing *Staphylococcus epidermidis*. Sulzberger first saw occluded ducts in eczema and 60 years later, these were rediscovered and shown to be due to many different species of staphylococci, including *S. aureus*, *epidermidis*, *tenuis* and many others. These occlusions also trigger the activation of the innate immune system, and this, while trying to attack and destroy the staphylococcal organisms, begins the cascade of events leading to the signs and symptoms of the many various forms of eczema. We propose a classification of these diseases as atopic eczema, seborrheic eczema, and others to unify these lesions with occluded ducts. Further, we propose a treatment protocol that addresses both the genetic and environmental “hits” in this classical “double-hit” disease.

Keywords: Staphylococcus; Sweat

Introduction

Diseases in the past have been descriptively named or named for their first or most important observers, or for their pathology. Examples of those would be erythema multiforme for descriptive, Alzheimer’s disease for name based, and angiolymphoid hyperplasia with eosinophilia for pathology based. We propose that the diseases which have occluded sweat ducts as part of their pathology be included under the broad heading of eczema. For instance, atopic dermatitis would be atopic eczema and Meyerson’s nevus would be nevoid eczema. These would tie together all these diseases which have occluded ducts in their pathology as well as itching as their main symptom.

Recently, sixty years after the original observation, the pathology of eczema was shown to have occluded eccrine sweat ducts in addition to the characteristic spongiotic dermatitis [1]. These ductal occlusions consisted of biofilms made by cutaneous, normal flora staphylococci, all of which contained a gene to make biofilms; [2] and, similar to miliaria (the prototypical ductal occlusion disease), these biofilms triggered both the clinical symptoms and the subsequent pathological findings of the disease [3]. The occluded ducts can be visualized on routine staining and documented as biofilms by periodic acid Schiff and Congo red stains. (Figure 1). The bacteria can be seen with gram stain and can be recovered by routine cultures.

The biofilms themselves consisted of extracellular polysaccharides enclosing DNA, staphylococcal organisms, water channels, and amyloid fibers [4]. The staphylococci produce these biofilms in response to the salt and water present in the sweat ducts [5]. The “curli” fibers associated with the amyloid attract activated Toll-like receptor 2 (TLR2) initiates the MyD88 pathway in an attempt to destroy the gram positive staphylococci [6]. TLR 2 also activates the PAR 2 (proteinase activated receptor 2) pathway that leads to the initial symptom of pruritus in the disease [7,8]. The MyD88 pathway

generates NFκB and TNFα, and TNFα is the strongest stimulant for producing spongiosis [9].

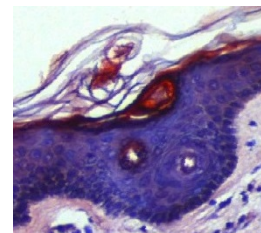


Figure 1: In the sweat duct within the stratum corneum, occlusions are noted. Congo red stains the amyloid that forms the infrastructure of biofilm; biofilm ductal occlusion is the signature finding of eczema in all its presentations. 40X.

Eczema has been called the “itch” that rashes, [10] and all the foregoing (occluded ducts, biofilms, and TLR2) lead to that “itch”. Recent work suggests that once the basement membrane is breached, the adaptive immune system (especially IL 31) enters the picture and creates even more intense itching [11]. Consequently, both arms of the immune system are involved in this autoimmune disease: the innate arm is first and begins in the epidermis, and the adaptive is second and begins in the dermis.

Eczema has been postulated to be a double-hit phenomenon with the filaggrin gene (or other genes yielding a defective *stratum corneum*) representing the genetic component and the biofilm-producing staphylococci the environmental hit [12].

Many different presentations of eczema exist and sometimes overlap. The traditional, largely age dependent atopic dermatitis presentations of facial extensor, flexural, and nummular all show occluded ducts and activation of the innate immune system. Similarly,

dyshidrotic eczema, and the recently described lichen planus-like eczema also show those signature findings [12,13].

Surprisingly, seborrheic dermatitis, axillary granular parakeratosis, and tinea pedis have shown occluded ducts with the biofilm generated by staphylococci and TLR2 activation [14]. The main difference in these diseases, when compared to atopic dermatitis, was the *stratum corneum* was rendered defective not by a gene as in the more familiar presentations of eczema, but by yeasts in seborrheic dermatitis, granules in granular parakeratosis, and dermatophytes in tinea pedis [14].

Occluded ducts are also a feature of Meyerson's nevus and Doucas Kapetanakis pigmented purpuric dermatosis [12]. Meyerson's nevus is a melanocytic nevus with a halo of eczema surrounding it. Doucas Kapetanakis disease is pigmented purpuric dermatosis combined with eczema. It is also known as "itching" purpura. Both these disease are supposed to have eczema as a component of their pathogenesis, and, in fact, they both display the ductal occlusions that now, more fully, define the disease.

It was Sulzberger in 1947 who saw the occluded duct in eczema [15], and it was he who championed calling eczema atopic dermatitis [16]. He did this in an attempt to simplify the diagnosis because of the multiplicity of names extant at that time. It is therefore with some trepidation that we propose the following for all the diseases listed in Table 1 with occluded eccrine sweat ducts as the underlying pathological finding of each.

Name	Presentation
Atopic eczema	facial extensor and flexural
Nummular eczema	coin-shaped lesions
Dyshidrotic eczema	hands and feet
Lichen planus-like eczema	purple papular rash
Seborrheic eczema	face and scalp
Granular parakeratotic eczema	axillae (and other sites)
Mycotic eczema	tinea pedis
Juvenile plantar eczema	childhood foot disease
Pigmented purpuric eczema	Doucas Kepetanakis
Nevoid eczema	Meyerson's nevus

Table 1: Showing occluded eccrine sweat ducts as the underlying pathological finding of each.

Pityriasis alba could possibly be included as facial eczema but most already consider it associated with eczema. It has its own distinctive clinical presentation and is unlikely to be mistakenly identified.

Regarding the genetic "hit" in the double-hit phenomenon: with care taken to treat the *stratum corneum* very kindly, the treatment with topical corticoids is more easily and more rapidly effective [12]. The subsequent prevention of the disease with exceedingly gentle skin care (minimal to no soap, no scrubbing, less frequent bathing, and more moisturizing) is remarkable. All caregivers have to be involved with this approach, but it is apparent this is most beneficial [12]. Those that eschew this approach very frequently have continuing troublesome disease. Also, of note, is this is a way to counteract the

impact of the "genetic" side of the disease, which is a "rare" opportunity indeed. Bleach baths, or the use of bleach containing gel, may be considered along with the aforementioned. Bleach is a biofilm dispersing agent which also is capable of killing planktonic (free floating) microbes [12]. Petrolatum itself, previously thought to be inert, has recently been shown to have antimicrobial capability [17].

The addition of oral antibiotics is fraught with difficulty because all the staphylococci are multidrug resistant and 60% are MRSA or MRSE [2]. Other antibacterial substances such as silver as in silver sulfadiazine, iodinated compounds, and zinc containing products may also have a place in the topical therapeutic armamentarium. The administration of antimetabolites, or immunosuppressives, or biologics would only be considered as a last resort [12].

We have presented a modest reclassification of eczema based on the signature pathology of occluded sweat ducts. We have also included some therapeutic maneuvers to counteract this pathology and lead both to clinical improvement and prevention of this disease in all its forms.

References

1. Haque MS, Hailu T, Pritchett E, Cusack CA, Allen HB (2013) The Oldest New Finding in Atopic Dermatitis. *JAMA Dermatol* 149: 436-438.
2. Allen HB, Vaze ND, Choi C, Hailu T, Tulbert BH, et al. The Presence and Impact of Biofilm-Producing Staphylococci in Atopic Dermatitis. *JAMA Dermatol*. 2014; 150: 260-265.
3. Holzle E, Kligman AM (1978) The pathogenesis of miliaria rubra. Role of resident microflora. *Br J Dermatol* 99: 117-137.
4. Branda SS, Vik S, Friedman L, Kolter R (2005) Biofilms: the matrix revisited. *Trends Microbiol* 13: 20-26.
5. Chaieb K, Zmantar T, Souiden Y, Mahdouani K, Bakhrouf A (2011) XTT assay for evaluating the effect of alcohols, hydrogen peroxide and benzalkonium chloride on biofilm formation of Staphylococcus epidermidis. *Microb Pathog* 50: 1-5.
6. Tükel C, Wilson RP, Nishimori JH, Pezeshki M, Chromy BA, et al. (2009) Response to amyloids of microbial and host origin are mediated through Toll-like Receptor 2. *Cell Host Microbe* 6: 45-53.
7. Strober W, Murray PJ, Kitani A, Watanabe T (2006) Signaling pathways and molecular interactions of NOD1 and NOD2. *Nat Rev Immunol* 6: 9-20.
8. Lee SE, Jeong SK, Lee SH. Protease and protease-activated receptor-2 signaling in the pathogenesis of atopic dermatitis. *Yonsei Med J* 2010; 51:808-822.
9. Kerstan A, Brocker EB, Trautmann A (2011) Decisive role of tumor necrosis factor- α for spongiosis formation in acute eczematous dermatitis. *Arch Dermatol Res* 303: 651-658.
10. Boguniewicz M (2005) Atopic dermatitis: beyond the itch that rashes. *Immunol Allergy Clin North Am* 25: 333-351.
11. Sonkoly E, Muller A, Lauerma AI, Pivarcsi A, Soto H, et al. (2006) IL-31: a new link between T cells and pruritis in atopic skin inflammation. *J Allergy Clin Immunol* 117: 411-417.
12. Allen HB (2014) *The Etiology of Atopic Dermatitis*. London, Springer.
13. Allen HB, Jones NP, Bowen SE (2008) Lichenoid and other clinical presentations of atopic dermatitis in an inner city practice. *J Am Acad Derm* 58: 503-504.
14. Herbert A, Dasgupta TS, Todd SP, Cusack CA, Joshi S (2015) Eccrine sweat duct occlusion by Staphylococcal-derived biofilms: an unexpected signature finding of eczema in dermatologic diseases. *J Clin Exp Dermatol Res* 6: 6.
15. Sulzberger MB, Hermann F, Zak FG (1947) Studies of sweating. I. Preliminary report with particular emphasis on a sweat retention syndrome. *J Invest Dermatol* 9: 221-242

16. Wise F, Sulzberger MB (1993) Footnote on problem of eczema, neurodermatitis and lichenification. In: Wise F, Sulzberger MB (eds). *The 1933 Year Book of Dermatology and Syphilology*. The Year Book Publishers, Chicago, IL :pp38-39.
17. Czarnowicki T, Malajian D, Khattri S, da Rosa JC, Dutt R, et al. (2015) Petrolatum: Barrier repair and antimicrobial responses underlying the inert moisturizer. *J Allergy Clin Immunol* 30: 01194-X.