

Sacroiliac joint pain: a comprehensive review of epidemiology, diagnosis and treatment

Expert Rev. Neurother. 13(1), 99–116 (2013)

Steven P Cohen*^{1,2},
Yian Chen³ and
Nathan J Neufeld⁴

¹Pain Medicine Division, Department of Anesthesiology and Critical Care Medicine, Johns Hopkins School of Medicine, Baltimore, MD, USA

²Walter Reed National Military Medical Center, Uniformed Services University of the Health Sciences, Bethesda, MD, USA

³Johns Hopkins School of Medicine, Baltimore, MD, USA

⁴Departments of Anesthesiology and Critical Care Medicine, and Physical Medicine and Rehabilitation, Johns Hopkins School of Medicine, Baltimore, MD, USA

*Author for correspondence:
scohen40@jhmi.edu

Sacroiliac joint (SIJ) pain is an underappreciated source of mechanical low back pain, affecting between 15 and 30% of individuals with chronic, nonradicular pain. Predisposing factors for SIJ pain include true and apparent leg length discrepancy, older age, inflammatory arthritis, previous spine surgery, pregnancy and trauma. Compared with facet-mediated and discogenic low back pain, individuals with SIJ pain are more likely to report a specific inciting event, and experience unilateral pain below L5. Owing in part to its size and heterogeneity, the pain referral patterns of the SIJ are extremely variable. Although no single physical examination or historical feature can reliably identify a painful SIJ, studies suggest that a battery of three or more provocation tests can predict response to diagnostic blocks. Evidence supports both intra- and extra-articular causes for SIJ pain, with clinical studies demonstrating intermediate-term benefit for both intra- and extra-articular steroid injections. In those who fail to experience sustained relief from SIJ injections, radiofrequency denervation may provide significant relief lasting up to 1 year. This review covers all aspects of SIJ pain, with the treatment section being primarily focused on procedural interventions.

KEYWORDS: clinical diagnosis • diagnostic block • low back pain • radiofrequency • review • sacroiliac joint

Sacroiliac joint (SIJ) pain is a common, yet underappreciated cause of chronic low back pain (LBP). In part because of its size and heterogeneity, there are myriad ways in which SIJ pain can present, which makes the diagnosis challenging. An understanding of the anatomy, clinical presentation, diagnostic dilemmas and treatment options can enhance the likelihood of an accurate diagnosis and optimize outcomes.

Functional anatomy

The SIJ is a true diarthrodial joint, consisting of two surfaces held together by fibrous capsule and enjoined with synovial fluid. The average surface area has been estimated to be approximately 17.5 cm², although there is significant variability between individuals regarding the shape and size [1,2]. The sacral and ilial surfaces of the joint are covered with hyaline and fibrocartilage, respectively, and have rough and coarse textures believed to be due to physiological adaptation to stress [3].

SIJs must support the upper body and dampen the impact of ambulation; ligaments that limit the mobility of the joint also provide it with strength. These include the anterior SI ligament, dorsal SI ligament, sacrospinous ligament, sacrotuberous ligament and interosseus ligaments [4]. Together, from a functional standpoint, they prevent separation of the joint and movement of the pelvis along the various axes of the sacrum. Ultimately, these ligaments act together to maintain bracing when weight is transferred from the torso to lower extremities [5]. They work in concert with muscular and fascial components, including the thoracolumbar fascia, gluteus maximus, piriformis and latissimus dorsi [6], lending support and permitting movement. Harrison *et al.* concluded that joint motion was probably limited to translational and rotational motions along 6 degrees of freedom [4]. Walker summarized prior studies from the 19th and 20th centuries, finding mean rotation ranged between 1 and 12°, and mean translation ranged between 3 and 16 mm, with the

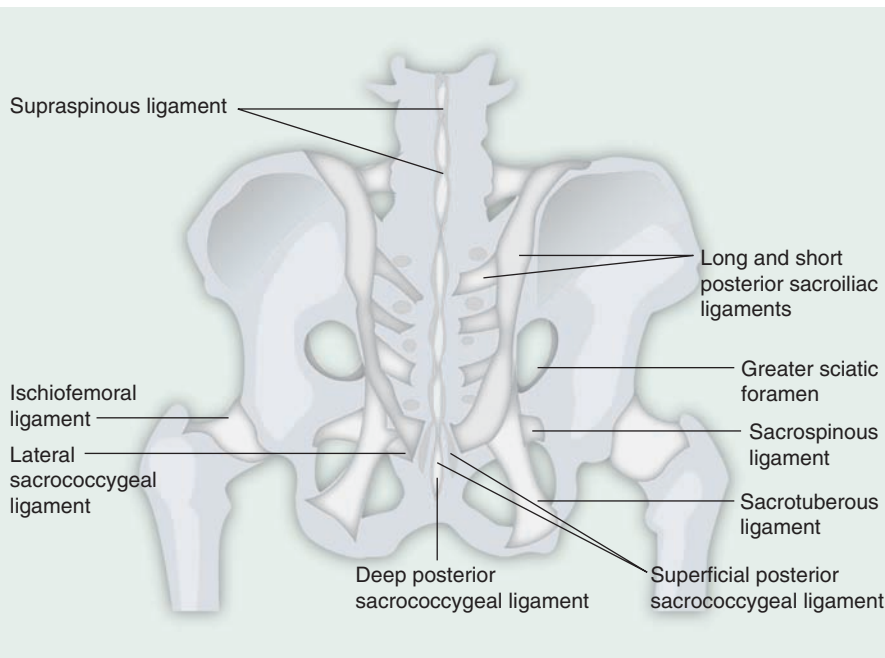


Figure 1. Posterior view of the articulations and associated ligaments of the sacroiliac joint and surrounding structures.

Drawing by Jee Hyun Kim. Adapted from [9].

caveat that measurements differed based on patient positions [7]. In a more recent *in vivo* analysis, Stuesson *et al.* reported even smaller degrees of movements in all planes (mean rotation 2.5°, mean translation 0.7 mm), with no differences found between symptomatic and asymptomatic joints [8]. This led the authors to conclude that 3D motion analysis is not a useful test in most individuals for identifying a painful SIJ(s). In summary, SIJ motion

is limited, with the primary function being supportive. possibly L4 [6,11]. Older literature cites contributions from the superior gluteal and obturator nerves (FIGURES 1 & 2) [12].

Prevalence

The prevalence of SIJ dysfunction has been mainly studied in populations of patients presenting with nonspecific LBP, with research groups using different selection criteria, different injection methods and different criteria to define a positive response. Not surprisingly, this has led to a wide range of prevalence rates. In general, SIJ pain has a bimodal distribution, with higher prevalence rates occurring in younger athletes and the elderly [13,14]. Studies using lower analgesic thresholds (i.e., $\geq 50\%$) tend to report only slightly higher prevalence rates than those using more stringent cutoff thresholds (80%). However, using 'double' or 'confirmatory' blocks in an attempt to reduce the false-positive rate significantly lowers the estimated prevalence rates compared with studies using uncontrolled blocks, from 32–36 to 15–21% [15].

In one of the earliest studies, Schwarzer *et al.* estimated the prevalence rates of patients presenting with LBP below L5–S1 ($n = 43$) using three different criteria [16]. They found a prevalence rate of 30% based solely on the analgesic response ($\geq 75\%$) to a single lidocaine block. When the criteria were tightened to pain relief and a ventral

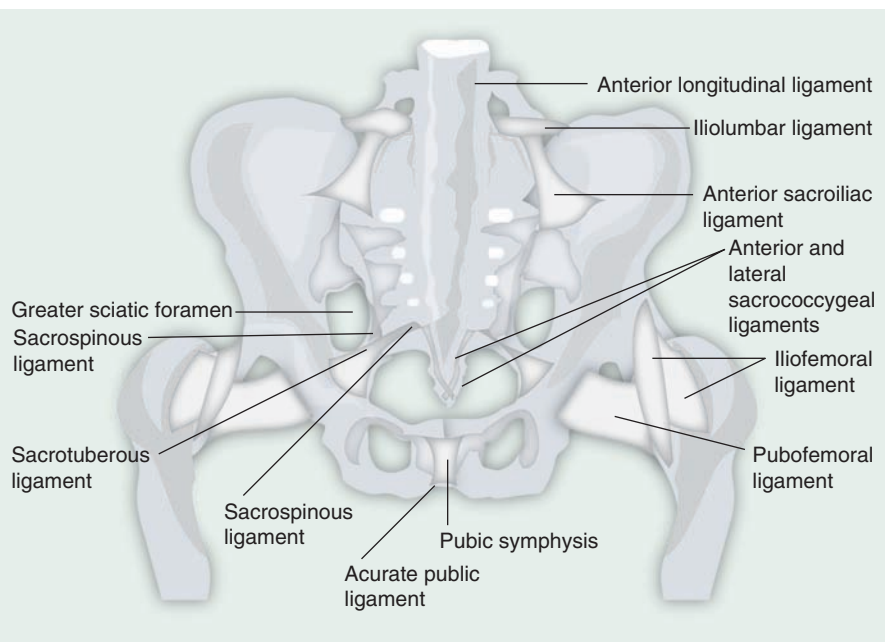


Figure 2. Anterior view of the articulations and associated ligaments of the sacroiliac joint and surrounding structures.

Drawing by Jee Hyun Kim. Adapted from [9].

capsular tear on computed tomography (CT) imaging, the prevalence rate declined to 21%. Using the combination of analgesic response, imaging abnormalities and concordant pain provocation as criteria, the prevalence rate decreased to 16%. Maigne *et al.* reported an 18.5% prevalence rate in 54 patients who failed epidural steroid and facet injections, using an analgesic response to a preliminary screening block with lidocaine followed by a confirmatory block with bupivacaine [17]. Irwin *et al.* found a 26.6% prevalence rate in a retrospective review of 158 patients with LBP and/or leg pain receiving initial and confirmatory injections with lidocaine and bupivacaine, respectively [18]. Manchikanti *et al.* reported a substantially lower prevalence rate of 10% in 20 patients who underwent double confirmatory blocks, reasoning that their lower positive rate may have been because they focused on a less targeted patient population [19]. In summary, although there is some variation in reported prevalence rates depending on the sample population and diagnostic criteria, it can be concluded that the SIJ represents a major cause of mechanical LBP in patients of all ages (TABLE 1).

Etiology

The mechanism of injury to the SIJ may best be described as a combination of axial loading and rotation. Immunohistological studies have demonstrated nociceptors to be present throughout

the joint capsule, ligaments and to a lesser extent subchondral bone, suggesting that injury to any of the surrounding structures can be a source of pain [20,21]. Bolstering this assertion is the observation that clinical studies have documented pain provocation in asymptomatic volunteers and patients using both capsular distension and ligamentous probing [22,23]. Among intra-articular (IA) etiologies, arthritis and spondyloarthropathies are the two most common causes, though the latter may also be associated with extra-articular (EA) pathology [24,25]. For EA etiologies, ligamentous and muscular injuries and enthesopathy are likely the most frequent sources.

Numerous factors can predispose patients to SIJ pain. These include true and apparent leg length discrepancies, transitional anatomy, gait and biomechanical abnormalities, persistent strain/low-grade trauma (e.g., jogging), scoliosis, pregnancy and spine surgery [9]. Pregnancy can result in SIJ pain by virtue of weight gain, exaggerated lordotic posture, third-trimester hormone-induced ligamentous relaxation and the pelvic trauma associated with parturition. In a large-scale study by Ostgaard *et al.* (n = 855), the authors found a 49% 9-month period prevalence rate for LBP among pregnant women, with SIJ pain comprising a majority of cases [26]. In a more recent cohort study involving 313 pregnant women between 12 and 18 weeks gestation, Gutke *et al.* found that 62% (n = 194) reported back pain [27]. Among these, 54% had pelvic girdle pain situated around the SIJ(s), 17%

Table 1. Studies evaluating prevalence rates of sacroiliac joint pain.

Study (year)	Subjects	Interventions	Diagnostic criteria	Results	Ref.
Maigne <i>et al.</i> (1996)	54 patients with chronic unilateral LBP with or without radiation to posterior thigh	Intra-articular blocks using 2 ml of lidocaine and bupivacaine on separate occasions. The authors avoided anesthetizing periarticular ligaments	≥75% pain relief, with the bupivacaine block lasting ≥2 h	Prevalence rate 18.5% False-positive rate 17%	[17]
Manchikanti <i>et al.</i> (2001)	20 patients with chronic LBP without neurological deficits	Intra-articular blocks with unspecified volume of lidocaine and bupivacaine on separate occasions	Not noted	Prevalence rate 10% False-positive rate 20%	[19]
Irwin <i>et al.</i> (2007)	158 patients with chronic LBP with or without lower extremity pain	Intra-articular blocks with 2 ml of lidocaine and 2 ml bupivacaine and steroid on separate occasions	≥70% pain relief, with the bupivacaine block lasting ≥4 h	Prevalence rate 27% False-positive rate 43%	[18]
Laslett <i>et al.</i> (2005)	48 patients with buttock pain, with or without lumbar or lower extremity symptoms, without signs of nerve root compression	Intra-articular blocks with <1.5 ml of lidocaine + steroid and bupivacaine on separate occasions	≥80% pain relief with lidocaine and bupivacaine	Prevalence rate 26% False-positive rate 0%	[45]
van der Wurff <i>et al.</i> (2006)	60 patients with chronic LBP below L5 with or without lower extremity symptoms, without neurological symptoms	Intra-articular blocks with 2 ml lidocaine and bupivacaine on separate occasions	≥50% pain relief with lidocaine and bupivacaine, with the bupivacaine block lasting ≥4 h	Prevalence rate 45% False-positive rate 12%	[46]
Liliang <i>et al.</i> (2011)	52 patients with previous spine fusion and pain below L5	Intra-articular blocks with 2 ml of lidocaine or bupivacaine + steroid on separate occasions	>75% pain relief lasting 1–4 h. Those who had 1 positive and 1 negative block underwent 3rd injection	Prevalence rate 40% False-positive rate 27%	[132]

LBP: Low back pain.

reported predominantly lumbar pain and the remainder (29%) experienced combination pelvic girdle and lumbar pain. True and functional leg length discrepancies can cause pain as a result of increased stress and abnormal force vectors on the ipsilateral lower extremity [28]. Friberg found that individuals with chronic LBP were significantly more likely (75 vs 43.5%) to have a leg length discrepancy of ≥ 5 mm than a matched cohort of asymptomatic controls [29]. Spine surgery is a very common, yet underappreciated source of SIJ pain, especially operations involving fusion to the sacrum. Ivanov *et al.* used simulated surgical procedures and a finite elemental spine-pelvis model to assess angular motion and stress across the SIJ following spinal fusion [30]. They found increased SIJ stress after surgery, which was least following L4–5 fusion and greatest after L4–S1 fusion. These results are consistent with those of Ha *et al.*, who compared pre- and postsurgical CT scans in 32 patients who underwent spinal fusions at different levels with those of 34 matched controls [31]. The authors reported a nearly twofold increase in SIJ degeneration in the fusion group compared with the control patients (75 vs 38.2%), with the highest incidence occurring in those with fusions extending to the sacrum. Iliac crest bone graft procurement can also result in disruption of the ligamentous and synovial portions of the SIJ [32]. These findings are consistent with prevalence studies reporting that SIJ pain occurs in between 32 and 61% of patients after fusion [33,34].

SIJ pain is more likely to ensue following an inciting event than facetogenic and discogenic pain, which tend to be more insidious in onset. Studies have shown that between 40 and 50% of patients with injection-confirmed SIJ pain can identify a specific precipitating event. In descending order, the most frequent antecedents for SIJ pain are motor vehicle collisions, falls, repetitive stress and pregnancy [16,35,36].

Clinical findings

Pain patterns

The characteristics of SI-based pain vary from patient to patient, rendering diagnosis difficult in the clinical setting. Because of its size and heterogeneity, pain referral patterns in SIJ pain are very variable. The magnitude of this variation can be gleaned from the multitude of studies that attempt to correlate pain referral patterns with either the reference standard of SIJ block, or pain provocation with physical maneuvers. Studies have descriptively and experimentally attempted to map the pain patterns associated with the SIJ. Fortin *et al.* challenged SIJs in asymptomatic volunteers by injecting contrast and lidocaine in an attempt to identify an SI pain pattern, generating a composite map on the patients' buttocks, inferior from the posterior inferior iliac spine [22]. These findings were later confirmed in a clinical study that found that those with buttock pain extending into the posterolateral thigh experienced pain with SIJ provocation and had negative facet blocks and discography [37]. Other investigators have also found buttock pain extending into the posterolateral thigh to be the most typical referral pattern. Two studies found the SIJs to be the most likely source of pain when the worst area was located within 10 cm of the posterior superior iliac spine [37,38]. Slipman *et al.* mapped out pain referral patterns by characterizing the

distribution patterns in 50 patients who obtained $\geq 80\%$ pain relief following single SIJ blocks: 94% reported buttock pain, 72% lumbar pain, 50% experienced pain extending into the lower extremity, 28% had pain below the knee, and groin pain was reported in 14% of individuals [39]. The widespread variability in this study may also be partially attributed to the observation that the greater the intensity of mechanical spinal pain, the more distal in the extremities it is referred. Depalma *et al.* [13] and Laslett [40] have found that individuals with SIJ pain are more likely to report lateral pain, rather than central pain. A cross-sectional prevalence study by Schwarzer *et al.* found that the only pain referral pattern that could reliably distinguish SIJ pain from other forms of LBP was radiation into the groin [16]. Young *et al.* found pain arising from sitting, unilateral pain and absence of lumbar pain were the most reliable means to distinguish SI pain from facetogenic and discogenic pain (TABLE 2) [41].

Physical examination findings

There is disagreement regarding the value of physical examination techniques in diagnosing SIJ dysfunction. Dreyfuss *et al.* reported that neither medical history nor physical examination maneuvers were reliable in the diagnosis of SIJ pain, using response to a joint block as the reference standard [42]. Slipman *et al.* reported a 60% positive predictive value for response to a single SIJ injection in 50 patients selected based on ≥ 3 provocation maneuvers and concluded that provocative tests should not be utilized as the sole criteria for diagnosis [43]. However, several other investigators have found that utilizing a battery of provocation tests may be useful in identifying a painful SIJ. In a double-blind, placebo-controlled study performed in 40 patients, Broadhurst and Bond reported that Patrick's, posterior shear and resisted abduction tests had sensitivities ranging between 77 and 87%, with each having 100% specificity [44]. In a blinded validity study performed in 48 patients, Laslett *et al.* reported that the presence of three of six provocation tests had 94% sensitivity and 78% specificity in predicting a positive response to a single diagnostic SIJ injection [45]. van der Wurff *et al.* [46] reported similar findings to those of Laslett *et al.* [45], finding that the presence of three of five positive provocation tests in 60 patients resulted in 85% sensitivity and 79% specificity using double confirmatory blocks as the diagnostic standard. Previous research has found provocation tests to be more reliable than tests measuring motion for identifying a painful SIJ [47,48]. In a recent systematic review by Szadek *et al.*, the authors concluded that three positive provocation tests had significant discriminative power (diagnostic odds ratio: 17.16) for diagnosing SIJ pain using the reference standard of two positive blocks [49]. In summary, the presence of three or more positive provocative tests appears to have reasonable sensitivity and specificity in identifying those individuals who will positively respond to diagnostic SIJ injections (TABLE 3).

Diagnostic imaging

A number of diagnostic imaging studies have been used to investigate SIJ pain with varying success. CT is a rapid test often considered to be the gold standard for identifying bony pathology.

Table 2. Studies evaluating physical findings in sacroiliac joint pain.

Study (year)	Patients	Findings suggestive of SI joint pain	Ref.
Fortin <i>et al.</i> (1994)	10 volunteers and 16 patients with SI joint pain	Point of maximum discomfort within 10 cm caudal and 3 cm lateral to PSIS	[22,37]
Murakami <i>et al.</i> (2008)	38 responders to periarticular injections	Point of maximum discomfort within 3 cm from PSIS	[38]
Schwarzer <i>et al.</i> (1995)	43 patients with axial LBP	Radiation to groin	[16]
Dreyfuss <i>et al.</i> (1996)	85 patients with axial LBP	None	[42]
Slipman <i>et al.</i> (2000)	50 patients with axial LBP	94% had buttock, 72% lumbar, 28% lower leg and 14% groin pain	[39]
van der Wurff <i>et al.</i> (2006)	60 patients with axial LBP	None	[46]
Jung <i>et al.</i> (2007)	160 patients with SI joint arthropathies	Buttock pain alone, extending into posterolateral thigh, or into groin	[133]
Laslett <i>et al.</i> (2003)	48 patients with axial LBP	Non-centralization or peripheralization of pain.	[134]
Depalma <i>et al.</i> (2011)	127 responders to IA SI joint blocks	Lateral midline pain	[13]
Young <i>et al.</i> (2003)	102 patients with nonradicular LBP	Pain rising from sitting, non-midline pain below L5	[41]
Liliang <i>et al.</i> (2011)	130 patients evaluated for SI joint pain after fusion	Unilateral pain, ≥ 3 provocative maneuvers, postoperative pain different than preoperative pain	[132]
Ostgaard <i>et al.</i> (1991)	855 pregnant women	Pain in the pubic symphysis	[26]
Laplante <i>et al.</i> (2012)	153 patients with axial LBP	None	[14]

IA: Intra-articular; LBP: Low back pain; PSIS: Posterior superior iliac spine; SI: Sacroiliac.

In a retrospective study performed in 112 patients (62 of whom had injection-confirmed SIJ pain), Elgafy *et al.* found that CT was associated with a 57.5% sensitivity and 69% specificity using diagnostic blocks as the reference standard [50]. Radionuclide bone scanning has also been investigated in comparison with anesthetic blocks but has been reported to have low sensitivity. Slipman *et al.* [51] found 100% specificity but only 13% sensitivity for radionuclide imaging in 50 patients who underwent diagnostic SIJ injections, while Maigne *et al.* [52] reported 46.1% sensitivity and 89.5% specificity in a cohort of 32 patients. These low sensitivities suggest that radionuclide imaging is a poor screening tool for SIJ pain. MRI has been reported to be effective in detecting early spondyloarthropathic SIJ pathologies with a sensitivity

exceeding 90% but is not useful in identifying noninflammatory conditions (TABLE 4) [53].

Treatment options

Conservative management

Although much of the literature regarding therapeutic options has focused on interventional approaches to SIJ pain, conservative management can provide a viable early option with fewer risks.

When evaluating physical therapy and rehabilitation studies, it is important to note the distinction between pain and biomechanical problems and strength and flexibility deficits, as the latter do not necessarily result in pain, and pain is not always accompanied by objective findings in tests designed to measure

Table 3. Predictive value of provocation testing for sacroiliac joint pain.

Study (year)	Sensitivity	Specificity (%)	Number of provocation tests	Ref.
van der Wurff <i>et al.</i> (2006)	85%	79	3 out of 5	[46]
Stanford and Burnham (2010)	82%	57	3 out of 6	[135]
Laslett <i>et al.</i> (2005)	94%	78	3 out of 6	[45]
Young <i>et al.</i> (2003)	Phi coefficient 0.6, effect size 0.36	Not reported	3 out of 5	[41]
Broadhurst and Bond (1998)	Range of 77–87% for each test	100 for each test	3	[44]
Liliang <i>et al.</i> (2011)	$p = 0.02$ to distinguish from <4 positive tests	Not reported	4 out of 6	[132]
Slipman <i>et al.</i> (1998)	Not reported	Positive predictive value 60	3 out of 6	[43]
Laslett <i>et al.</i> (2003)	91%	78, increased to 87 when patients whose pain 'peripheralized' or 'centralized' were excluded	3 out of 5	[134]

Table 4. Imaging and diagnosis.

Imaging modality	Accuracy
CT scan	Good for already established bone changes. Does not detect inflammation. 58% sensitive and 69% specific in identifying symptomatic joint
MRI	Treatment of choice. STIR and contrast-enhanced superior. 85% sensitive for active sacroiliitis
Bone scans	Low sensitivity, high specificity (>90%)
X-rays	Very low sensitivity, high specificity
Ultrasound	May be used to detect posterior ligamentous pathology. Can be useful in pregnant women

STIR: Short TI inversion recovery MRI.

biomechanical abnormalities and strength and flexibility limitations. Nevertheless, strength and flexibility training can be applied to correct the maladaptive biomechanical imbalance(s) associated with injury that can worsen the injury and prevent return to normal activities [54]. Most physical therapy tends to be focused on core strengthening [55], with many studies conducted in peri- and postpartum women who routinely have SIJ dysfunction. There have been efforts to stabilize and rehabilitate the pelvic joint through the use of devices such as pelvic belts in peripartum women [56]. One study evaluating three different physical therapy treatments in pregnant women diagnosed with SIJ pain based on provocation maneuvers, found no difference between use of a nonelastic SI belts, home exercise and a structured clinical exercise program, with all groups demonstrating improvement between 38 weeks gestation and 12 months postpartum [57]. Ideally, the use of a physical rehabilitation or exercise program designed to alleviate pain and correct biomechanical deficiencies should be individually tailored based on clinical findings, physical capacity and anticipated compliance [58].

Alternative treatments

Manual medicine

Manipulation (manual therapy, osteopathic manual treatment, chiropractic adjustments) has been shown in uncontrolled or poorly controlled studies to result in significant clinical improvement of pain originating from the SIJ [59–62]. However, these studies have been performed using differing techniques and methodology [9], and a well-designed cohort study failed to show an association between spinal manipulation success and the presence of a host of SIJ provocation maneuvers [63]. One comparative study found the combination of high-velocity, low-amplitude SIJ and lumbar manipulation to be superior to SIJ manipulation alone [64]. SIJ bony asymmetries have been clinically shown in uncontrolled studies to resolve with manipulation [60,65]; however, a study by Tullberg *et al.* [66] using roentgen stereophotogrammetric analysis while standing showed no change in SIJ bony positioning after manipulation, and an earlier study demonstrated no significant correlation between ‘joint motion’ and response to diagnostic blocks [42]. There are reports of improved tone and reduction in pain involving SIJ-related soft tissues after manipulation, namely,

the quadriceps [67], abdominal musculature [68] and hamstrings [65,69]. Despite the anecdotal nature of these reports, the low risks associated with these noninterventional techniques warrant their consideration by trained professionals [70].

Prolotherapy

Prolotherapy (also known as proliferative therapy) involves the injection of otherwise nonpharmacological and nonactive irritant solutions such as dextrose and platelet-rich plasma into the body, usually around tendons or ligaments, in an attempt to strengthen connective tissue and relieve musculoskeletal pain. It is hypothesized to work by initiating an inflammatory process that results in enhanced blood flow and accelerated tissue repair. In the only randomized study evaluating prolotherapy for injection-confirmed SIJ pain, Kim *et al.* compared up to 4 bi-weekly IA dextrose 25% injections to steroids [71]. Although no differences in short-term outcomes were noted with both the groups significantly improving at 2 weeks, at 15 months post-treatment, 58.7% of patients who received prolotherapy continued to experience a positive outcome versus 10.2% in the IA steroid group. An observational study by Cusi *et al.* evaluating three injections of hypertonic dextrose into the SIJ ligaments reported similarly auspicious outcomes, with success rates of 76, 76 and 32% at 3-, 12- and 24-month follow-up visits, respectively [72]. Despite these results, the absence of placebo-controlled studies evaluating prolotherapy for SIJ pain, and the negative results in high-quality, controlled studies for back pain in general [73], warrant caution when interpreting the results.

Interventional treatment

Nerve blocks

In deciding to initiate interventional treatment options, it is important to consider the clinical evidence supporting a putative diagnosis, the evidence supporting the treatment and any anatomical considerations that may affect the decision-making process (e.g., spondyloarthropathy or multiple previously failed interventions) [74]. SIJ pain disproportionately affects the elderly, who tend to present with bilateral pain and have IA pathology (i.e., arthritis), and young, active people who have are more likely to present with unilateral pain caused by involvement of the soft tissue structures (i.e., ligaments and muscles) that comprise the SI articulation (i.e., EA pathology). Histological studies demonstrate nociceptive innervation in the SIJ capsule, surrounding ligaments and subchondral bone [20,21]. Depending on the patient, both IA and EA injections may provide benefit.

EA steroid injections

There are two controlled trials evaluating EA injections, both by the same group of investigators [24,25]. In the first study, 20 patients with seronegative spondyloarthropathy were randomized to receive single peri-articular injections with 3 ml of steroid and local anesthetic, or the same volume of saline and local anesthetic [24]. At 2-month follow-up, those in the treatment group fared better than those in the control group on pain and provocative examination maneuvers. In the second study, Luukkainen *et al.*

randomized 24 patients with nonspondyloarthropathic SIJ pain to the same injection scheme [25]. At 1-month follow-up, those who received steroids experienced less pain than those who received local anesthetic mixed with saline.

In a non-randomized, comparative effectiveness study, Murakami *et al.* compared IA and EA injections in 50 patients with pain in the SIJ region and three positive provocative tests [75]. Patients received either IA lidocaine, or EA injections based on pain provocation with hypertonic saline, and were assessed 5 min after the injection with range of motion exercises. The authors reported that all patients in the EA group experienced improvement versus nine out of 25 in the IA group [75]. In a study by Borowsky and Fagen, the authors retrospectively compared the outcomes of 80 patients who received IA SIJ blocks to 40 patients who underwent combination IA and EA blocks to include the lateral branches and posterior SI ligaments [76]. At 3 weeks (42.5 vs 27.5%) and 3 months (31.25 vs 12.5%), those in the combination group were more likely to experience $\geq 50\%$ pain relief than those who received only IA injections. The main limitations to all of these studies are that none prescreened patients with diagnostic blocks, the short-term follow-ups and the lack of data evaluating functional capacity.

IA steroid injections

The evidence supporting IA injections is weaker than that for EA injections but still argues in favor of an effect. A prospective investigation by Fischer *et al.* found CT-guided IA steroids to be an effective long-term (mean duration of benefit: 12 months) treatment in 56 children with juvenile spondyloarthropathy who failed to respond to NSAIDs [77]. Hanly *et al.* compared the response of IA steroids in 13 patients with inflammatory spondyloarthropathy and MRI evidence of sacroiliitis to that in six patients devoid of radiological evidence of SIJ inflammation (mechanical back pain group) [78]. Both the groups demonstrated significant improvements in pain scores and function most prominent between 1 and 3 months, with no differences noted between groups. In the only controlled study evaluating IA steroid injections, Maugars *et al.* randomized ten patients with spondyloarthropathy and sacroiliitis (13 injected joints) to receive either IA steroids or saline [79]. At 1-month follow-up, five of six steroid-injected joints improved by $\geq 70\%$ versus 0 out of 7 in the control group. Six of the seven saline-injected groups were then injected with steroids. Overall, 87.5% (12 out of 14) injected joints were considered to respond positively at 1 month. At 3 and 6 months, success rates declined to 62 and 58%, respectively.

One possibility that has been entertained is that advanced imaging capable of detecting inflammation, such as single photon emission CT or radionuclide bone scanning, may be able to identify a subgroup of patients likely to respond to IA steroid injections [80]. Although no study has evaluated the ability of these diagnostic tools for SIJ pain, researchers have found a positive association between positive single photon emission CT scans and response to steroids injected into facet joints [81,82]. Overall, there is moderate evidence supporting IA steroid injections for

spondyloarthropathy, and anecdotal evidence for a beneficial effect in nonspondyloarthropathy SIJ pain. Despite positive results being reported for blind injections [83], a study by Rosenberg *et al.* found that only 22% of nonradiologically (i.e., landmark) guided SI injections extended into the joint space [84].

Other IA injection therapy

Investigators have made several attempts to prolong the intrinsic short-term relief obtained with corticosteroid injections. Theoretically, an IA injection of a neurolytic agent that diffuses throughout the entire joint should provide long-standing relief for those individuals suffering from IA SIJ pain. Ward *et al.* reported a median 20.5 weeks pain relief in nine out of ten patients who obtained good but short-term relief with IA steroid injections who were subsequently treated with IA phenol [85]. However, the high percentage of tears in the ventral capsule [16], and the high frequency with which the injectate spreads into the epidural space or sacral foramina [84] render this a high-risk procedure that is rarely performed clinically.

Since the SIJ is a synovial joint, and controlled studies for knee, hip and other forms of osteoarthritis have demonstrated intermediate-term benefit with hyaluronic acid [86,87], some have postulated that viscosupplementation might be effective in a subgroup of patients with degenerative SIJ arthritis. Srejec *et al.* reported 12–16 months of significant pain relief in four patients with SIJ pain who underwent a series of three IA injections with hyaluronic acid [88]. Three of these patients presented with postsurgical SIJ pain, which is frequently accompanied by degenerative changes in the SIJ [30,31], while one suffered from severe osteoarthritis of the spine. However, the treatment effect size for hyaluronic acid is considered to be modest at best, and the treatment is likely to benefit only those individuals suffering from degenerative SIJ osteoarthritis.

Radiofrequency denervation

First described as a treatment for spinal pain in the early 1970s [89], radiofrequency (RF) lesioning of the lateral branch nerves innervating the SIJ has been used for over 10 years, with almost universally positive results. But whereas controlled and uncontrolled studies have demonstrated benefit, none have compared RF denervation to more conservative therapy. The best candidates for SIJ denervation are those who have obtained effective but short-term relief with SIJ blocks, and because the nerves amenable to lesioning arise from the dorsal rami, those with pain arising from the posterior joint. Dreyfuss *et al.* performed an elegant randomized, double-blind study in 20 pain-free volunteers to assess the innervation pattern of the lateral branch nerves [90]. They found that multisite lateral branch blocks blocked ligamentous probing in 70% of cases, but 86% of the time individuals retained the ability to perceive capsular distension. This suggests that lateral branch RF denervation should be more effective in alleviating EA SIJ pain and that either lateral branch or EA blocks would serve as better predictive tools than IA injections for RF denervation response, though the latter contention has yet to be evaluated in clinical trials.

Patient selection

The reasons for interventional treatment failure can be divided into three main categories, which are outlined in TABLE 5. These include poor patient selection, inaccurate diagnosis, and technical treatment failures. Few studies have examined the factors affecting SIJ RF denervation success. In a multicenter study by Cohen *et al.*, higher preprocedure pain scores (i.e., greater disease burden), regular opioid use and older age were associated with treatment failure [36]. These results are consistent with other RF studies suggesting opioid use and greater disease burden can predispose patients toward treatment failure [91]. The most probable reason as to why younger patients experienced higher success rates is that they are more likely to have EA SIJ pathology (i.e., ligaments), which includes the pain-generating structures innervated by lateral branches.

A great deal of literature has been devoted to properly selecting patients for RF denervation procedures. Several investigators have advocated using double blocks to identify a painful SIJ since single blocks are associated with a high false-positive rate of around 20% [15]. All of these studies used comparative local anesthetic blocks, arbitrarily defining a false-positive block as a positive response to a screening block and a negative response to a confirmatory block. However, it is likely that at least some of negative confirmatory blocks actually represent false-negative blocks. Reasons for false-negative blocks can include failure to anesthetize the parts of the SIJ responsible for pain, and failure of the patient to discount 'procedure-related pain'. A multicenter study by Cohen *et al.* evaluating predictors of SIJ RF denervation outcomes found no difference in success rates when only one block, or more than one block was used [36]. In a randomized, comparative cost-effectiveness study comparing zero, one and two blocks before lumbar facet RF denervation, whereas two blocks was associated with the highest RF denervation success rate, the highest overall success rate and lowest cost per effective procedure was noted in the zero-block group [92]. Reasons for this finding, which is supported by theoretical computations [93], include the absence of false-negative blocks and the high placebo response rates for procedures [94].

Since the lateral branches amenable to denervation innervate the posterior ligaments but not the capsule or ventral supporting structures, one might surmise that performing lateral branch screening blocks could improve outcomes. But whereas all studies that performed lateral branch blocks achieved high success rates [95-97], studies that have utilized SIJ blocks without lateral branch blocks have reported equally positive outcomes.

Another area of controversy is the ideal cutoff threshold used to designate an SIJ as 'positive'. For facet blocks, the two most commonly used thresholds are ≥ 50 and $\geq 80\%$ pain relief. In the only study comparing the treatment results between cutoff thresholds of 50 and 80% for SIJ pain, no difference was found between RF denervation outcomes [36]. Similarly, no differences for cervical and lumbar facet RF denervation outcomes have been noted when 50 and 80% cutoff thresholds were compared [91,98]. The results for RF denervation are consistent with other treatments that have found no differences in outcomes between using 50% thresholds for screening procedures and more stringent reference standards (TABLE 6) [99,100].

Types of RF denervation

Conventional RF

As alluded to earlier, not all people have innervation from L4, L5 and S4, and the decision to select which nerves to target should be based on individual anatomy and clinical presentation (i.e., S4 when the foramen lies at a level parallel or above the lower portion of the SIJ or the patient has distal radiation, and perhaps L4 in individuals with sacralization of L5 or concomitant lumbar pain). Multiple uncontrolled studies utilizing different selection criteria, targeting different nerves, and employing various criteria for success, follow-up periods and techniques, have reported excellent success rates using conventional RF lesioning [101-103]. However, no controlled studies have been published evaluating conventional RF denervation. There are two retrospective comparative studies that have compared conventional to cooled RF, which reported conflicting results. In a study by Cohen *et al.* [36] involving 77 patients with injection-confirmed SIJ pain, a trend was noted whereby those individuals who underwent cooled RF had better outcomes. In contrast, a recent study by Cheng *et al.* performed in 88 patients showed no significant advantage for cooled over conventional RF [104].

The main limitation to conventional RF is that the small lesions created (approximately 4 mm in horizontal diameter) translate to a higher likelihood of missing nociceptive input, as the lateral branches converging on the foramina are not visible with imaging techniques. Anatomical studies have found that the number and location of the lateral branches vary significantly from patient-to-patient, side-to-side and level-to-level. In light of the widespread variability in nerve location, we generally insert curved electrodes at cephalad angles to maximize the surface area of the active tips that are in contact with bone – similar to what is generally recommended for lumbar facet joint RF denervation [105].

Because of the small lesion size, multiple lesions need to be created around each foramen to interrupt all or most of the nociceptive input transmitted from the SIJ. Another technique often used to amplify lesion size is fluid modulation (i.e., injecting fluid before lesioning), which likely acts via alterations in thermal and electrical conductivity properties [106,107].

Table 5. Reasons for interventional treatment failure.

Patient selection	Inaccurate diagnosis	Technical failure
Extensive disease burden	False-positive block	Poor lesion placement
Secondary gain	Ventral or intra-articular SI joint pain	Procedural complication
Social factors	Coexisting pain generators	
High-dose opioid therapy		
Coexisting psychiatric illness		

SI: Sacroiliac.

Local anesthetic has been shown to enhance lesion diameter by approximately 50% and has the additional benefit of diminishing procedure-related pain. We generally mix 2% lidocaine with a small dose of steroid before initiating RF since the latter has also been shown to reduce the incidence of neuritis [108].

Bipolar RF

In bipolar RF, a second electrode is placed in close proximity to the first so that the current flows between the two electrodes to create a continuous lesion. Several investigators have studied the morphology of bipolar lesions using various mediums, from animal tissue to egg white. Pino *et al.* examined bipolar RF lesion patterns in egg white by heating 22-gauge electrodes in parallel [109]. They reported that the optimum contiguous 'strip' lesion occurred when the electrodes were placed 6 mm apart. Kang *et al.* performed a similar study in egg white using water-cooled bipolar RF, a technique permitting larger overall lesions through prevention of tissue charring [110]. The authors reported that the largest contiguous strip lesion was created when the leads were placed 24 mm apart. Cosman and Gonzalez performed a series of experiments in various types of animal tissue, concluding that orientation, spacing, lesion time, electrode length and diameter and tip temperature can all affect lesion formation [111]. When considering these studies, one must recognize that egg white, or even homogenous *ex vivo* animal tissue, does not necessarily simulate conditions in heterogeneous human SI tissue.

In one of the earliest studies evaluating SIJ denervation, Ferrante *et al.* conducted a retrospective study in 33 patients in which bipolar electrodes were sequentially placed within 1 cm of each other along the posteroinferior margin of the joint, permitting lesions to form in strips [112]. They reported a 36.4% success rate at 6-month follow-up based upon $\geq 50\%$ decrease in visual analog scale pain scores. The low success rate is not surprising, considering this IA technique denervated only a small portion of the posterior joint.

The conceptual appeal of bipolar RF denervation lies in its ability to maximize lesion size by use of an enclosed electrical circuit, so that the placement of electrodes close to the foramen where the lateral branches converge can theoretically interrupt all nociceptive input. In a small observation study involving nine patients who had experienced $\geq 50\%$ pain relief following SIJ and lateral branch nerve blocks, Burnham and Yasui created bipolar strip lesions by sequentially leapfrogging 20-gauge electrodes around the S1–3 foramina [96]. They reported a successful outcome in 89% of subjects, with two-thirds continuing to experience meaningful relief 1 year after treatment.

Cooled RF ablation

In comparison to conventional RF, cooled RF is a relatively new technique, having been adapted from use in tissue ablation used to treat tumors and cardiac arrhythmias [113–116]. The primary feature of cooled RF is the internally cooled, large-bore electrodes. Using irrigation-cooled electrodes allows the surrounding tissues to slowly heat to neuroablative temperatures while maintaining the directly adjacent tissue at a temperature that prevents tissue

Table 6. Causes of intra-articular and extra-articular sacroiliac joint pain.

Intra-articular pain	Extra-articular pain
Arthritis	Ligamentous injury
Spondyloarthropathy	Bone fractures
Malignancies	Malignancies
Trauma	Myofascial pain
Infection	Enthesopathy
Cystic disease	Trauma Pregnancy

charring, allowing for greater lesion expansion. The ablation diameter (twofold increase over conventional RF), depth (≥ 3 cm distal to the active tip) and area (eightfold increase) are therefore increased substantially, promoting an increased likelihood of successful neurotomy and pain resolution. Placing cooled electrodes strategically around the sacral foramina (i.e., 1:30, 3:30 and 5:30 on the face of a clock for right-sided lesions) should theoretically result in a continuous geometric strip lesion that completely severs all nociceptive input from the SIJ.

Probe tip placement is similar to conventional RF, though the technique needs to be adjusted somewhat. The electrodes do not need to be inserted in a cephalo-caudal plane to maximize lesion area but instead can be placed directly perpendicular to the sacrum, thereby causing less tissue trauma. Because the ablated area extends distal to the electrode tip, greater lesion depth is obtained. In order to ensure that the temperature within the sacral foramen does not exceed 45°C , for safety purposes the electrodes need to be placed at a greater distance (≥ 7 mm) from the foramina. Additionally, sensory stimulation is unnecessary due to the fact that strategically placed electrodes should theoretically create a continuous lesion that precludes missing individual lateral branches.

Both controlled and uncontrolled studies support the use of cooled RF in SIJ pain [97,117,118]. In a randomized, placebo-controlled study conducted in 28 patients, Cohen *et al.* found that 64 and 57% of patients who underwent L4–S3 or 4 denervation after a positive IA injection experienced $\geq 50\%$ pain relief at their 3 and 6-month follow-up visits, respectively, with comparable improvements in function and medication reduction [118]. In an open-label crossover arm, a slightly lower proportion of patients experienced relief using conventional RF. In the subjects who experienced a successful outcome, the median duration of benefit was approximately 8 months.

Patel *et al.* performed a randomized cooled RF placebo-controlled study on 51 patients [97]. Inclusion criteria were failure to experience long-term relief with conservative measures including IA injections, and two positive L5 dorsal ramus and S1–3 lateral branch blocks. The patients were randomized in a 2:1 ratio to receive either cooled or sham RF of L5–S3, respectively. They found statistically significant improvements in subjective pain, physical function, disability and quality of life at 3-month follow-up, with 47% of treatment patients experiencing a positive

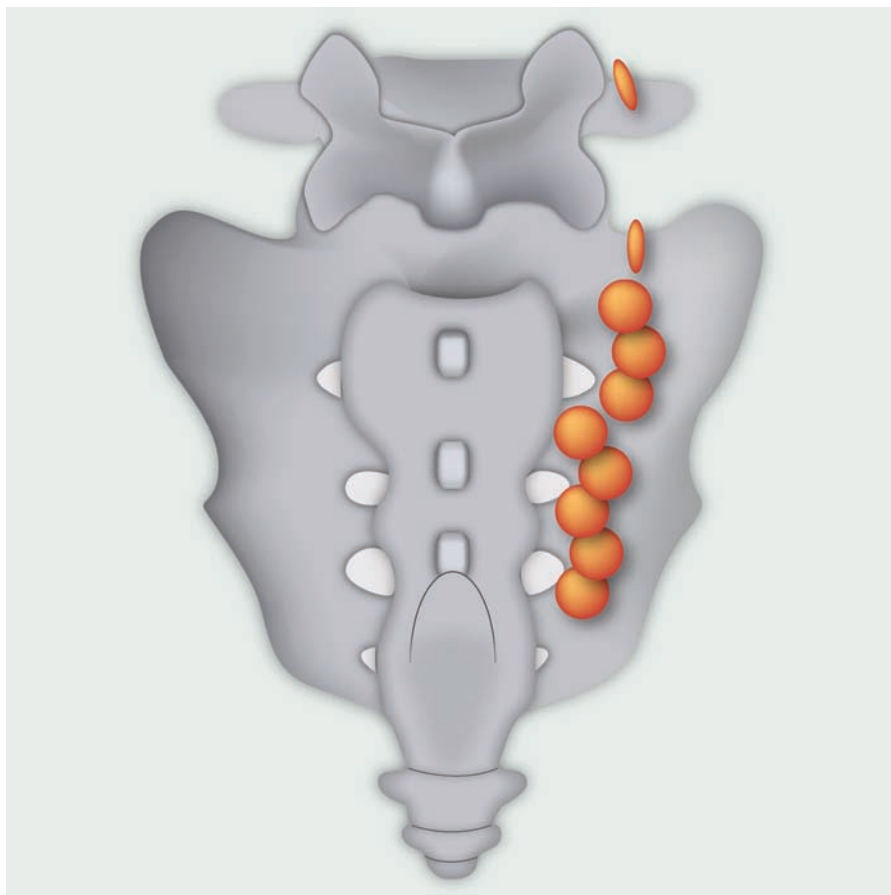


Figure 3. Schematic diagram depicting target points with anticipated lesions for right-sided conventional radiofrequency of L4 and L5 and cooled-probe S1–S3 radiofrequency denervation.

Adapted from [118].

outcome ($\geq 50\%$ decrease in pain with comparable improvements in either SF-36 bodily pain or functional capacity) versus 12% in the control group. At 6 and 9 months post-treatment, 38

least 3 months. The main problem with this technique is that it leaves a majority of the nerve supply, and large areas of tissue, physiologically intact.

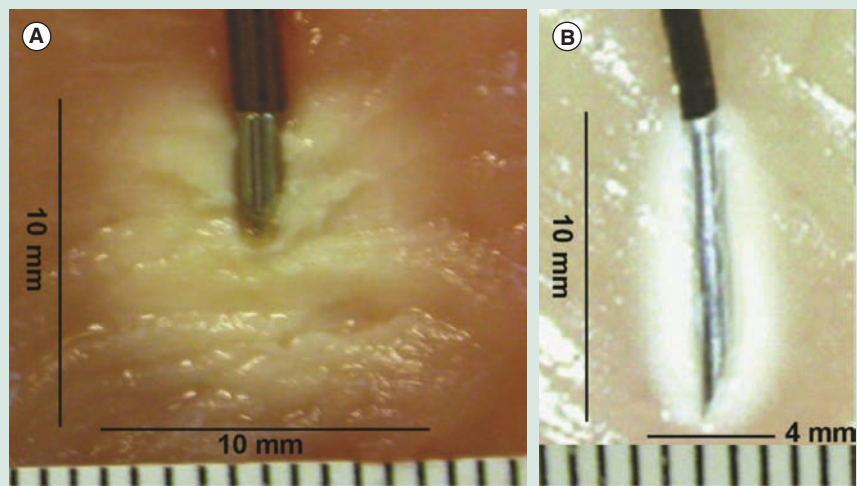


Figure 4. Difference in lesion size between (A) cooled and (B) conventional radiofrequency probes in chicken meat. Each small line represents a distance of 1 mm.

Adapted from [118].

and 59% of treatment patients continued to have a positive outcome.

Although the use of techniques aimed at amplifying lesion size has considerable appeal for the SIJ wherein the number and location of the nerves transmitting pain signals vary considerably, they are not devoid of drawbacks. Disadvantages of cooled RF include the greater expense, longer lesioning time and larger electrode size, which enhances the risk of bleeding and procedure-related pain. In view of the fact that the larger lesions are more likely to capture superficial branches, there is also a higher incidence of cutaneous paresthesias (FIGURES 3 & 4).

Combination ligamentous and neural RF ablation

Similar to SIJ blocks, attempts have been made to address multiple sources of SIJ pain simultaneously with RF denervation. In an observational study by Gevargez *et al.*, the authors used CT guidance to lesion the L5 dorsal ramus and create three lesions in the posterior interosseous ligaments, in 38 patients with signs and symptoms consistent with SIJ pain who positively responded to intra-ligamentous injections with definite but temporary pain relief [119]. A total of 65% of patients reported substantial pain relief lasting at

Pulsed RF

Pulsed RF (PRF) is a non-neuroablative technique whose conceptual appeal is to effect pain relief without injuring nerves. Unlike conventional or cooled RF which severs nerves resulting in Wallerian degeneration, PRF acts via the creation of an electrical field, thereby inhibiting the transmission of pain-transmitting A-delta and C-fibers, and possibly by enhancing descending modulatory systems [120,121]. Therefore, the primary indication for PRF is neuropathic pain, in which violation of the nerve architecture can conceivably exacerbate the underlying pain condition.

There is only one uncontrolled study evaluating PRF for SIJ pain [122]. In a small prospective observational study conducted in 22 patients who obtained short-term

benefit following SIJ blocks, 73% obtained at least 50% pain relief and improvement in quality of life, with the median duration of benefit being 20 weeks in the responders. However, two randomized studies comparing conventional denervation to PRF in individuals with facetogenic pain both found conventional RF to be superior [123,124]. In summary, there is scant evidence for the use of PRF as a treatment for SIJ pain (TABLE 7).

Complications of RF ablation

Serious complications from neuroablative procedures are rare. Postprocedure numbness and tingling are more common than for facet denervation, affecting up to 20% of individuals, and are believed to be due to the severing of cutaneous sensory branches. This is rarely bothersome. The prophylactic administration of steroids has been shown in a randomized study to reduce the incidence of medial branch neuritis, though this has not been formally studied for SIJ pain [108]. Bleeding and infection are inherent risks of any percutaneous procedure, though the incidence is very low. Misplaced electrodes can result in the ablation of sacral spinal nerves leading to incontinence, worsening pain or lower extremity weakness. This can be prevented by the use of 'finder' needles placed into the foramina to ensure that the active electrode tip is a safe distance. When intravenous agents are administered, sedation protocols should be implemented.

Cryoanalgesia

Cryoanalgesia works by inducing ice crystal formation that damages the vasonervorum, leading to severe endoneurial edema and disruption of neural transmission. In comparison to RF denervation, the main advantages of cryoanalgesia are a larger lesion size, and the fact that it leaves the myelin sheath and endoneurium intact. Disadvantages include a relatively shorter duration of benefit and a possibly higher risk of bleeding and nerve injury. Currently, there are no published studies evaluating cryoanalgesia for SIJ pain.

Other treatments

Neuromodulation

Spinal cord and peripheral nerve stimulation are generally acknowledged to be more effective for neuropathic, than nociceptive pain. There is currently only anecdotal evidence supporting neuromodulation for SIJ, with one investigator reporting good results with S3 stimulation [125] and another report touting benefit for S1 stimulation [126].

Surgical intervention for SIJ pain

For nearly 100 years, surgical intervention has been offered to patients whose symptoms are refractory to conservative management and nerve blocks. Most of the studies involve surgical fusion of the SIJ and involve relatively small cohorts of patients. A number have focused upon surgical intervention for SI dislocation or fracture. Dabiezis *et al.* described 11 patients with mainly trauma-related SIJ disruption or fracture who received joint reduction and stabilization with compression rods [127]. Although they followed their patients for an average of 26.1 months, their data are mostly limited to the technical aspects of surgery and

do not detail patient outcome, except for noting that several patients had residual pain while one had extension of preoperative peroneal nerve palsy. Simpson *et al.* examined two different surgical approaches to pelvic stabilization in a series of patients with mainly trauma-related SIJ disruption, but did not include detailed outcome readouts from a clinical/functional standpoint [128].

Interventions have also been used for non-traumatic SIJ pain. Waisbrod *et al.* reviewed 22 surgeries over a 3.5-year period, defining 'satisfaction' as indicative of at least 50% reduction of pain, no need for analgesics, and continuation of preoperative occupation [129]. They reported that 11 patients described satisfactory results, and after excluding patients for psychosomatic pain, concluded it was associated with a 70% success rate. Buchowski *et al.* described a series of 20 patients who received SIJ arthrodesis after failing conventional management, assessing their outcomes using pre- and postoperative assessments with validated instruments such as the SF-36 Health Survey as well as radiographic and clinical data [130]. In the 15 patients who returned clinical outcome surveys, statistically significant changes were noted in most categories of the SF-36, and for satisfaction, neurogenic symptoms and functional capacity. The analysis of outcomes is confounded by the 25% of patients who failed to respond to the survey. More recently, Schütz and Grob reported on a cohort of 17 patients with chronic lower back pain (12 idiopathic, five traumatic) who had clinical signs and symptoms consistent with SIJ pain and a positive response to local anesthetic blocks, who underwent bilateral SIJ fusion [131]. Their results were not encouraging. A total of 82% of patients were unsatisfied and perhaps more concerning, 65% required reoperation. The caveats for this study include the disparate inclusion criteria and technical challenges of achieving complete fusion in SIJs. Ultimately, surgical studies share certain confounding factors, such as an inability to blind patients and variability in operative technique. In summary, whereas surgery appears to be clearly indicated for fracture or dislocation, its applicability to degenerative disease is less clear.

Conclusion

SIJ pain is an underappreciated source of mechanical LBP, affecting up to 30% of individuals with chronic, nonradicular pain. Whereas a combination of three or more provocation maneuvers contain greater than 75% sensitivity and specificity according to some studies for identifying a painful SIJ, the reference standard for diagnosis remains low-volume anesthetic blocks. Uncontrolled blocks are associated with a high false-positive rate, but using controlled blocks increases the likelihood for a false-negative result and has not been shown to improve treatment outcomes. Although anecdotal evidence suggests that conservative and alternative therapies may benefit a subset of patients with biomechanical or soft-tissue abnormalities, there are no studies evaluating these treatments in patients with injection-confirmed SIJ pain. Until such time as high quality RCTs are performed this cohort, the benefit of these less expensive and invasive options will remain unknown. Both IA and EA steroid injections may provide short-term relief in a subset of patients with active inflammation, but

Table 7. Radiofrequency ablation studies.

Study (year)	Study design	Patients (n)	SI joint blocks	Cutoff threshold (%)	Lateral branch blocks	Nerves targeted	RF technique	Follow-up (months)	Success rate (%)	Ref.
Ferrante <i>et al.</i> (2001)	Retrospective	33	n = 1, 2 ml + steroid	Not noted	No	Intra-articular	Leapfrog bipolar	6	36	[112]
Gevargez <i>et al.</i> (2002)	Prospective, observational	38	n ≥ 1, 2 ml + steroid	Not noted	No	CT: guided, L5 + SI ligaments	Conventional	3	66	[119]
Cohen and Abdi (2003)	Retrospective	9	n = 1, volume not noted	80 for SI, 50 for LBP	1	L4–S3/4	Conventional	9	89	[95]
Y'in <i>et al.</i> (2003)	Retrospective	14	n = 2, 5 ml + steroid, extra-articular	70	No	L5, S1, ± S2 and S3	Conventional	6	64	[102]
Buijs <i>et al.</i> (2004)	Observational	38	n = 1, volume not noted	50	No	L4–S3 or S1–3	Conventional	4	67	[103]
Burnham and Yasui (2007)	Prospective, observational	9	n > 1, 2 ml + steroid	50	1 at 4 sites	L5–S3	Bipolar leapfrog	12	89	[96]
Vallejo <i>et al.</i> (2006)	Prospective, observational	22	n > 1, 2 ml + steroid	75	No	L4–S2	Pulsed	≥10 weeks	55	[122]
Kapural <i>et al.</i> (2008)	Retrospective	26	n = 2, 3 ml + steroid	50	No	L5–S3	Cooled	3–4	69	[117]
Cohen <i>et al.</i> (2008)	Randomized, controlled	28	n = 1, 2 ml + steroid	50	1	L4–S3/4	Cooled	6	57	[118]
Karaman <i>et al.</i> (2011)	Prospective, observational	15	n = 2, 2 ml	75	No	L5–S3	Cooled	6	80	[136]
Speldewinde (2011)	Prospective, observational	20	n = 2, volume not noted	80	No	L5–S3	Conventional	≥2	80	[137]
Patel <i>et al.</i> (2012)	Randomized, controlled	51	n ≥ 1, volume not noted. Used intra- and extra-articular	75 for lateral branch blocks	2	L5–S3	Cooled	9	59	[97]
Cheng <i>et al.</i> (2012)	Retrospective	88	n = 2, 3 ml + steroid	50	No	L4–S3	Cooled, conventional	≥6	50–60 at 6 months, 40 at 9 months	[104]

CT: Computed tomography; RF: Radiofrequency; SI: Sacroiliac.

their long-term effectiveness remains unproven. In those individuals who obtain significant but transient relief with SIJ injections, RF ablation of the lower lumbar dorsal rami and S1–3(4) lateral branches has been shown to provide pain relief lasting up to 1 year.

Expert commentary

SIJ pain remains a significant challenge to clinicians, which stems in part from the inherent difficulties surrounding diagnosis, the heterogenous nature of the disorder, and the technical obstacles involved in the treatment. Diagnostic injections are widely considered the reference standard for identifying a painful joint, but in the absence of any confirmatory means for diagnosis, the accuracy of injections can never be truly known. Whereas the use of the ‘double-block’ paradigm may reduce the ‘false-positive’ rate, they inevitably result in more ‘false-negatives’, the consequences of which may be more serious (i.e., misdiagnosing a treatable condition) than treating patients without the index condition. Currently, there are no well-designed studies evaluating conservative therapies. Steroid injections may provide temporary relief to a subset of individuals with pain resulting from active inflammation, with stronger evidence supporting EA than IA blocks. In those individuals who respond with significant albeit temporary relief from blocks, RF denervation has been shown in controlled studies to provide between 6 months and 1-year of relief. Whereas the theoretical benefit of RF techniques that result in enhanced lesion size (e.g., cooled or bipolar lesioning) is compelling for a condition in which the number and location of nociceptive nerve fibers vary from patient-to-patient, side-to-side and level-to-level, controlled studies are needed to confirm this.

Five-year view

In recent years, our appreciation of the SIJ as a potential pain generator has significantly grown, encompassing nearly all allied

health, medical and surgical specialties that treat this condition. Yet, there is still considerable room for improvement in our knowledge regarding the mechanisms of injury, improvement in diagnosis and refinements in treatment. With regards to the former, increased use of cadaveric experiments, computer-simulation models and possibly ethical animal studies might shed light on how an SIJ becomes painful. Currently, the analgesic response to SIJ blocks performed with local anesthetic is considered the reference standard for diagnosis, with many individuals advocating the use of multiple injections to ‘increase accuracy’. However, a balance needs to be struck regarding the benefits of increased specificity engendered by multiple injections, and the costs that result from the inevitable diminished sensitivity associated with this paradigm. For treatments, there is a glaring absence of well-designed, controlled studies for noninterventional treatments, and only a paucity of studies lacking long-term follow-up and secondary measures of improvement (e.g., function) evaluating steroid injections. The evidence is somewhat stronger for RF denervation, though studies evaluating conventional denervation (which is less expensive and easier to perform than cooled or bipolar RF lesioning) against sham procedures and other types of denervation are desperately needed. Finally, the development of SIJ phenotypes, which take into account demographic variables, clinical features (e.g., pain descriptions and radiation patterns), and possibly simple experimental responses, may someday enhance diagnostic accuracy and improve treatment outcomes.

Financial & competing interests disclosure

The authors have no relevant affiliations or financial involvement with any organization or entity with a financial interest in or financial conflict with the subject matter or materials discussed in the manuscript. This includes employment, consultancies, honoraria, stock ownership or options, expert testimony, grants or patents received or pending, or royalties.

No writing assistance was utilized in the production of this manuscript.

Key issues

- Sacroiliac joint (SIJ) pain may account for between 15 and 30% of nonradicular low back pain (LBP).
- The SIJ is a major cause of LBP at any age but is more common in the elderly and younger active people.
- A good physical exam is likely to demonstrate non-central, unilateral LBP without radiculopathy.
- There is a high degree of accuracy for diagnosing sacroiliac pain with three or more provocation tests of the SIJ; however, diagnostic blocks are the reference standard for identifying a painful joint(s).
- Various pain generators surrounding the SIJ complex may need to be treated to maximize success, suggesting multimodal treatment is ideal.
- Treatment of SIJ pain should be individualized based on diagnostic tests and proper patient selection.
- Both intra- and extra-articular steroid injections may provide intermediate-term relief depending on the pain generator.
- Radiofrequency has proven to be a successful treatment for posterior SIJ pain.

References

Papers of special note have been highlighted as:

• of interest

•• of considerable interest

1 Bernard T, Cassidy J. *The Sacroiliac Joint Syndrome: Pathophysiology, Diagnosis, and*

Management. The Adult Spine: Principles and Practice. Raven Press Ltd, New York, NY, USA, 2107–2130 (1991).

2 Vleeming A, Stoecart R, Volkers AC, Snijders CJ. Relation between form and function in the sacroiliac joint. Part I:

Clinical anatomical aspects. *Spine* 15(2), 130–132 (1990).

3 McLauchlan GJ, Gardner DL. Sacral and iliac articular cartilage thickness and cellularity: relationship to subchondral bone end-plate thickness and cancellous

- bone density. *Rheumatology (Oxford)* 41(4), 375–380 (2002).
- 4 Harrison DE, Harrison DD, Troyanovich SJ. The sacroiliac joint: a review of anatomy and biomechanics with clinical implications. *J. Manipulative Physiol. Ther.* 20(9), 607–617 (1997).
 - 5 Willard F. The anatomy of the lumbosacral connection. The anatomy of the lumbosacral connection. In: *Spine: State of the Art Reviews*. Hanley & Belfus, PA, USA, 333 (1995).
 - 6 Forst SL, Wheeler MT, Fortin JD, Vilensky JA. The sacroiliac joint: anatomy, physiology and clinical significance. *Pain Physician* 9(1), 61–67 (2006).
 - 7 Walker JM. The sacroiliac joint: a critical review. *Phys. Ther.* 72(12), 903–916 (1992).
 - 8 Stuessen B, Selvik G, Udén A. Movements of the sacroiliac joints. A roentgen stereophotogrammetric analysis. *Spine* 14(2), 162–165 (1989).
 - 9 Cohen SP. Sacroiliac joint pain: a comprehensive review of anatomy, diagnosis, and treatment. *Anesth. Analg.* 101(5), 1440–1453 (2005).
 - 10 McGrath MC, Zhang M. Lateral branches of dorsal sacral nerve plexus and the long posterior sacroiliac ligament. *Surg. Radiol. Anat.* 27(4), 327–330 (2005).
 - 11 Nakagawa T. [Study on the distribution of nerve filaments over the iliosacral joint and its adjacent region in the Japanese]. *Nippon. Seikeigeka Gakkai Zasshi* 40(4), 419–430 (1966).
 - 12 Solonen KA. The sacroiliac joint in the light of anatomical, roentgenological and clinical studies. *Acta Orthop. Scand. Suppl.* 27, 1–127 (1957).
 - 13 Depalma MJ, Ketchum JM, Trussell BS, Saullo TR, Slipman CW. Does the location of low back pain predict its source? *PM R.* 3(1), 33–39 (2011).
 - 14 Laplante BL, Ketchum JM, Saullo TR, DePalma MJ. Multivariable analysis of the relationship between pain referral patterns and the source of chronic low back pain. *Pain Physician* 15(2), 171–178 (2012).
 - 15 Simopoulos TT, Manchikanti L, Singh V *et al.* A systematic evaluation of prevalence and diagnostic accuracy of sacroiliac joint interventions. *Pain Physician* 15(3), 305–344 (2012).
 - 16 Schwarzer AC, Aprill CN, Bogduk N. The sacroiliac joint in chronic low back pain. *Spine* 20(1), 31–37 (1995).
 - **One of the earliest studies to determine that history and physical examination are unreliable in identifying a painful sacroiliac joint.**
 - 17 Maigne JY, Aivaliklis A, Pfefer F. Results of sacroiliac joint double block and value of sacroiliac pain provocation tests in 54 patients with low back pain. *Spine* 21(16), 1889–1892 (1996).
 - **First study to use ‘double blocks’ to estimate the prevalence of sacroiliac joint pain.**
 - 18 Irwin RW, Watson T, Minick RP, Ambrosius WT. Age, body mass index, and gender differences in sacroiliac joint pathology. *Am. J. Phys. Med. Rehabil.* 86(1), 37–44 (2007).
 - 19 Manchikanti L, Singh V, Pampati V *et al.* Evaluation of the relative contributions of various structures in chronic low back pain. *Pain Physician* 4(4), 308–316 (2001).
 - 20 Szadek KM, Hoogland PV, Zuurmond WW, de Lange JJ, Perez RS. Nociceptive nerve fibers in the sacroiliac joint in humans. *Reg. Anesth. Pain Med.* 33(1), 36–43 (2008).
 - 21 Szadek KM, Hoogland PV, Zuurmond WW, De Lange JJ, Perez RS. Possible nociceptive structures in the sacroiliac joint cartilage: an immunohistochemical study. *Clin. Anat.* 23(2), 192–198 (2010).
 - 22 Fortin JD, Dwyer AP, West S, Pier J. Sacroiliac joint: pain referral maps upon applying a new injection/arthrography technique. Part I: asymptomatic volunteers. *Spine* 19(13), 1475–1482 (1994).
 - 23 Dreyfuss P, Snyder BD, Park K, Willard F, Carreiro J, Bogduk N. The ability of single site, single depth sacral lateral branch blocks to anesthetize the sacroiliac joint complex. *Pain Med.* 9(7), 844–850 (2008).
 - 24 Luukkainen R, Nissilä M, Asikainen E *et al.* Periarticular corticosteroid treatment of the sacroiliac joint in patients with seronegative spondylarthropathy. *Clin. Exp. Rheumatol.* 17(1), 88–90 (1999).
 - 25 Luukkainen RK, Wennerstrand PV, Kautiainen HH, Sanila MT, Asikainen EL. Efficacy of periarticular corticosteroid treatment of the sacroiliac joint in non-spondylarthropathic patients with chronic low back pain in the region of the sacroiliac joint. *Clin. Exp. Rheumatol.* 20(1), 52–54 (2002).
 - **Established the efficacy of extra-articular injections for sacroiliac joint pain. Limited by short follow-up period.**
 - 26 Ostgaard HC, Andersson GB, Karlsson K. Prevalence of back pain in pregnancy. *Spine* 16(5), 549–552 (1991).
 - 27 Gutke A, Ostgaard HC, Oberg B. Pelvic girdle pain and lumbar pain in pregnancy: a cohort study of the consequences in terms of health and functioning. *Spine* 31(5), 149–155 (2006).
 - 28 Timgren J, Soynila S. Reversible pelvic asymmetry: an overlooked syndrome manifesting as scoliosis, apparent leg-length difference, and neurologic symptoms. *J. Manipulative Physiol. Ther.* 29(7), 561–565 (2006).
 - 29 Friberg O. Clinical symptoms and biomechanics of lumbar spine and hip joint in leg length inequality. *Spine* 8(6), 643–651 (1983).
 - 30 Ivanov AA, Kiapour A, Ebraheim NA, Goel V. Lumbar fusion leads to increases in angular motion and stress across sacroiliac joint: a finite element study. *Spine* 34(5), 162–169 (2009).
 - 31 Ha KY, Lee JS, Kim KW. Degeneration of sacroiliac joint after instrumented lumbar or lumbosacral fusion: a prospective cohort study over five-year follow-up. *Spine* 33(11), 1192–1198 (2008).
 - **Five-year cohort study demonstrating that the rate of sacroiliac joint degeneration significantly increases following spinal fusion.**
 - 32 Ebraheim NA, Elgafy H, Semaan HB. Computed tomographic findings in patients with persistent sacroiliac pain after posterior iliac graft harvesting. *Spine* 25(16), 2047–2051 (2010).
 - 33 Maigne JY, Planchon CA. Sacroiliac joint pain after lumbar fusion. A study with anesthetic blocks. *Eur. Spine J.* 14(7), 654–658 (2005).
 - 34 Katz V, Schofferman J, Reynolds J. The sacroiliac joint: a potential cause of pain after lumbar fusion to the sacrum. *J. Spinal Disord. Tech.* 16(1), 96–99 (2003).
 - 35 Chou LH, Slipman CW, Bhagia SM *et al.* Inciting events initiating injection-proven sacroiliac joint syndrome. *Pain Med.* 5(1), 26–32 (2004).
 - 36 Cohen SP, Strassels SA, Kurihara C *et al.* Outcome predictors for sacroiliac joint (lateral branch) radiofrequency denervation. *Reg. Anesth. Pain Med.* 34(3), 206–214 (2009).
 - **Study identified predictors of treatment outcome following sacroiliac joint radiofrequency denervation.**

- 37 Fortin JD, Aprill CN, Ponthieux B, Pier J. Sacroiliac joint: pain referral maps upon applying a new injection/arthrography technique. Part II: Clinical evaluation. *Spine* 19(13), 1483–1489 (1994).
- 38 Murakami E, Aizawa T, Noguchi K, Kanno H, Okuno H, Uozumi H. Diagram specific to sacroiliac joint pain site indicated by one-finger test. *J. Orthop. Sci.* 13(6), 492–497 (2008).
- 39 Slipman CW, Jackson HB, Lipetz JS, Chan KT, Lenrow D, Vresilovic EJ. Sacroiliac joint pain referral zones. *Arch. Phys. Med. Rehabil.* 81(3), 334–338 (2000).
- 40 Laslett M. Evidence-based diagnosis and treatment of the painful sacroiliac joint. *J. Man. Manip. Ther.* 16(3), 142–152 (2008).
- 41 Young S, Aprill C, Laslett M. Correlation of clinical examination characteristics with three sources of chronic low back pain. *Spine J.* 3(6), 460–465 (2003).
- 42 Dreyfuss P, Michaelsen M, Pauza K, McLarty J, Bogduk N. The value of medical history and physical examination in diagnosing sacroiliac joint pain. *Spine* 21(22), 2594–2602 (1996).
- 43 Slipman CW, Sterenfeld EB, Chou LH, Herzog R, Vresilovic E. The predictive value of provocative sacroiliac joint stress maneuvers in the diagnosis of sacroiliac joint syndrome. *Arch. Phys. Med. Rehabil.* 79(3), 288–292 (1998).
- 44 Broadhurst NA, Bond MJ. Pain provocation tests for the assessment of sacroiliac joint dysfunction. *J. Spinal Disord.* 11(4), 341–345 (1998).
- 45 Laslett M, Aprill CN, McDonald B, Young SB. Diagnosis of sacroiliac joint pain: validity of individual provocation tests and composites of tests. *Man. Ther.* 10(3), 207–218 (2005).
- 46 van der Wurff P, Buijs EJ, Groen GJ. A multitest regimen of pain provocation tests as an aid to reduce unnecessary minimally invasive sacroiliac joint procedures. *Arch. Phys. Med. Rehabil.* 87(1), 10–14 (2006).
- 47 van der Wurff P, Hagmeijer RH, Meyne W. Clinical tests of the sacroiliac joint. A systematic methodological review. Part 1: reliability. *Man. Ther.* 5(1), 30–36 (2000).
- 48 Laslett M, Williams M. The reliability of selected pain provocation tests for sacroiliac joint pathology. *Spine* 19(11), 1243–1249 (1994).
- 49 Szadek KM, van der Wurff P, van Tulder MW, Zuurmond WW, Perez RS. Diagnostic validity of criteria for sacroiliac joint pain: a systematic review. *J. Pain* 10(4), 354–368 (2009).
- **Excellent systematic review on the value of provocation tests for identifying a painful sacroiliac joint.**
- 50 Elgafy H, Semaan HB, Ebraheim NA, Coombs RJ. Computed tomography findings in patients with sacroiliac pain. *Clin. Orthop. Relat. Res.* 382, 112–118 (2001).
- 51 Slipman CW, Sterenfeld EB, Chou LH, Herzog R, Vresilovic E. The value of radionuclide imaging in the diagnosis of sacroiliac joint syndrome. *Spine* 21(19), 2251–2254 (1996).
- 52 Maigne JY, Boulahdour H, Chatellier G. Value of quantitative radionuclide bone scanning in the diagnosis of sacroiliac joint syndrome in 32 patients with low back pain. *Eur. Spine J.* 7(4), 328–331 (1998).
- 53 Puhakka KB, Jurik AG, Schiøttz-Christensen B *et al.* MRI abnormalities of sacroiliac joints in early spondylarthropathy: a 1-year follow-up study. *Scand. J. Rheumatol.* 33(5), 332–338 (2004).
- 54 Prather H, Hunt D. Conservative management of low back pain, part I. Sacroiliac joint pain. *Dis. Mon.* 50(12), 670–683 (2004).
- 55 Mens JM, Snijders CJ, Stam HJ. Diagonal trunk muscle exercises in peripartum pelvic pain: a randomized clinical trial. *Phys. Ther.* 80(12), 1164–1173 (2000).
- 56 Vleeming A, Buyruk HM, Stoeckart R, Karamursel S, Snijders CJ. An integrated therapy for peripartum pelvic instability: a study of the biomechanical effects of pelvic belts. *Am. J. Obstet. Gynecol.* 166(4), 1243–1247 (1992).
- 57 Nilsson-Wikmar L, Holm K, Oijerstedt R, Harms-Ringdahl K. Effect of three different physical therapy treatments on pain and activity in pregnant women with pelvic girdle pain: a randomized clinical trial with 3, 6, and 12 months follow-up postpartum. *Spine* 30(8), 850–856 (2005).
- 58 Stuge B, Holm I, Vøllestad N. To treat or not to treat postpartum pelvic girdle pain with stabilizing exercises? *Man. Ther.* 11(4), 337–343 (2006).
- 59 Delitto A, Cibulka MT, Erhard RE, Bowling RW, Tenhula JA. Evidence for use of an extension-mobilization category in acute low back syndrome: a prescriptive validation pilot study. *Phys. Ther.* 73(4), 216–222; discussion 223 (1993).
- 60 Daly JM, Frame PS, Rapoza PA. Sacroiliac subluxation: a common, treatable cause of low-back pain in pregnancy. *Fam. Pract. Res. J.* 11(2), 149–159 (1991).
- 61 Dontigny RL. Dysfunction of the sacroiliac joint and its treatment*. *J. Orthop. Sports Phys. Ther.* 1(1), 23–35 (1979).
- 62 Wreje U, Nordgren B, Aberg H. Treatment of pelvic joint dysfunction in primary care – a controlled study. *Scand. J. Prim. Health Care* 10(4), 310–315 (1992).
- 63 Flynn T, Fritz J, Whitman J *et al.* A clinical prediction rule for classifying patients with low back pain who demonstrate short-term improvement with spinal manipulation. *Spine* 27(24), 2835–2843 (2002).
- 64 Kamali F, Shokri E. The effect of two manipulative therapy techniques and their outcome in patients with sacroiliac joint syndrome. *J. Bodyw. Mov. Ther.* 16(1), 29–35 (2012).
- 65 Cibulka MT, Delitto A, Koldehoff RM. Changes in innominate tilt after manipulation of the sacroiliac joint in patients with low back pain. An experimental study. *Phys. Ther.* 68(9), 1359–1363 (1988).
- 66 Tullberg T, Blomberg S, Branth B, Johnsson R. Manipulation does not alter the position of the sacroiliac joint. A roentgen stereophotogrammetric analysis. *Spine* 23(10), 1124–1128; discussion 1129 (1998).
- 67 Suter E, McMorland G, Herzog W, Bray R. Decrease in quadriceps inhibition after sacroiliac joint manipulation in patients with anterior knee pain. *J. Manipulative Physiol. Ther.* 22(3), 149–153 (1999).
- 68 Marshall P, Murphy B. The effect of sacroiliac joint manipulation on feed-forward activation times of the deep abdominal musculature. *J. Manipulative Physiol. Ther.* 29(3), 196–202 (2006).
- 69 Cibulka MT, Rose SJ, Delitto A, Sinacore DR. Hamstring muscle strain treated by mobilizing the sacroiliac joint. *Phys. Ther.* 66(8), 1220–1223 (1986).
- 70 Neufeld NJ, Jones JM. Osteopathic medicine in musculoskeletal conditions (Chapter 7). In: *Physical Medicine and Rehabilitation Pocket Companion*. Gonzalez-Fernandez M, Friedman JD (Eds). Demos Medical Publishing, New York, NY, USA (2011).
- 71 Kim WM, Lee HG, Jeong CW, Kim CM, Yoon MH. A randomized controlled trial of intra-articular prolotherapy versus steroid injection for sacroiliac joint pain. *J. Altern. Complement. Med.* 16(12), 1285–1290 (2010).
- 72 Cusi M, Saunders J, Hungerford B, Wisbey-Roth T, Lucas P, Wilson S. The

- use of prolotherapy in the sacroiliac joint. *Br. J. Sports Med.* 44(2), 100–104 (2010).
- 73 Dagenais S, Yelland MJ, Del Mar C, Schoene ML. Prolotherapy injections for chronic low-back pain. *Cochrane Database Syst. Rev.* 2, CD004059 (2007).
- 74 Boswell MV, Trescot AM, Datta S *et al.*; American Society of Interventional Pain Physicians. Interventional techniques: evidence-based practice guidelines in the management of chronic spinal pain. *Pain Physician* 10(1), 7–111 (2007).
- 75 Murakami E, Tanaka Y, Aizawa T, Ishizuka M, Kokubun S. Effect of periarticular and intraarticular lidocaine injections for sacroiliac joint pain: prospective comparative study. *J. Orthop. Sci.* 12(3), 274–280 (2007).
- 76 Borowsky CD, Fagen G. Sources of sacroiliac region pain: insights gained from a study comparing standard intra-articular injection with a technique combining intra- and peri-articular injection. *Arch. Phys. Med. Rehabil.* 89(11), 2048–2056 (2008).
- 77 Fischer T, Biedermann T, Hermann KG *et al.* [Sacroiliitis in children with spondyloarthritis: therapeutic effect of CT-Guided intra-articular corticosteroid injection]. *Rofö.* 175(6), 814–821 (2003).
- 78 Hanly JG, Mitchell M, MacMillan L, Mosher D, Sutton E. Efficacy of sacroiliac corticosteroid injections in patients with inflammatory spondyloarthritis: results of a 6 month controlled study. *J. Rheumatol.* 27(3), 719–722 (2000).
- 79 Maugars Y, Mathis C, Berthelot JM, Charlier C, Prost A. Assessment of the efficacy of sacroiliac corticosteroid injections in spondylarthropathies: a double-blind study. *Br. J. Rheumatol.* 35(8), 767–770 (1996).
- **Only controlled study to evaluate intra-articular steroid injections. Limited by short follow-up period.**
- 80 Makki D, Khazim R, Zaidan AA, Ravi K, Toma T. Single photon emission computerized tomography (SPECT) scan-positive facet joints and other spinal structures in a hospital-wide population with spinal pain. *Spine J.* 10(1), 58–62 (2010).
- 81 Pneumaticos SG, Chatziioannou SN, Hipp JA, Moore WH, Esses SI. Low back pain: prediction of short-term outcome of facet joint injection with bone scintigraphy. *Radiology* 238(2), 693–698 (2006).
- 82 Dolan AL, Ryan PJ, Arden NK *et al.* The value of SPECT scans in identifying back pain likely to benefit from facet joint injection. *Br. J. Rheumatol.* 35(12), 1269–1273 (1996).
- 83 Sadreddini S, Noshad H, Molaeefard M, Ardalan MR, Ghojzadeh M, Shakouri SK. Unguided sacroiliac injection: effect on refractory buttock pain in patients with spondyloarthropathies. *Presse Med.* 38(5), 710–716 (2009).
- 84 Rosenberg JM, Quint TJ, de Rosayro AM. Computerized tomographic localization of clinically-guided sacroiliac joint injections. *Clin. J. Pain* 16(1), 18–21 (2000).
- **Demonstrates the inherent inaccuracy of blinded sacroiliac joint injections.**
- 85 Ward S, Jenson M, Royal MA, Movva V, Bhakta B, Gunyea I. Fluoroscopy-guided sacroiliac joint injections with phenol ablation for persistent sacroiliitis: a case series. *Pain Prac.* 2(4), 332–335 (2002).
- 86 Petrella RJ, DiSilvestro MD, Hildebrand C. Effects of hyaluronate sodium on pain and physical functioning in osteoarthritis of the knee: a randomized, double-blind, placebo-controlled clinical trial. *Arch. Intern. Med.* 162(3), 292–298 (2002).
- 87 Colen S, Haverkamp D, Mulier M, van den Bekerom MP. Hyaluronic acid for the treatment of osteoarthritis in all joints except the knee: what is the current evidence? *BioDrugs* 26(2), 101–112 (2012).
- 88 Srejjc U, Calvillo O, Kabakibou K. Viscosupplementation: a new concept in the treatment of sacroiliac joint syndrome: a preliminary report of four cases. *Reg. Anesth. Pain Med.* 24(1), 84–88 (1999).
- 89 Shealy CN. Percutaneous radiofrequency denervation of spinal facets. Treatment for chronic back pain and sciatica. *J. Neurosurg.* 43(4), 448–451 (1975).
- 90 Dreyfuss P, Henning T, Malladi N, Goldstein B, Bogduk N. The ability of multi-site, multi-depth sacral lateral branch blocks to anesthetize the sacroiliac joint complex. *Pain Med.* 10(4), 679–688 (2009).
- **Established that the lateral branches amenable to radiofrequency denervation innervate the surrounding posterior ligaments, but not the joint capsule. This study also showed that injecting local anesthetic at different depths is the only reliable way to anesthetize these nerves.**
- 91 Cohen SP, Hurley RW, Christo PJ, Winkley J, Mohiuddin MM, Stojanovic MP. Clinical predictors of success and failure for lumbar facet radiofrequency denervation. *Clin. J. Pain* 23(1), 45–52 (2007).
- 92 Cohen SP, Williams KA, Kurihara C *et al.* Multicenter, randomized, comparative cost-effectiveness study comparing 0, 1, and 2 diagnostic medial branch (facet joint nerve) block treatment paradigms before lumbar facet radiofrequency denervation. *Anesthesiology* 113(2), 395–405 (2010).
- 93 Bogduk N, Holmes S. Controlled zygapophysial joint blocks: the travesty of cost-effectiveness. *Pain Med.* 1(1), 24–34 (2000).
- 94 Kaptchuk TJ, Stason WB, Davis RB *et al.* Sham device v inert pill: randomised controlled trial of two placebo treatments. *BMJ* 332(7538), 391–397 (2006).
- 95 Cohen SP, Abdi S. Lateral branch blocks as a treatment for sacroiliac joint pain: a pilot study. *Reg. Anesth. Pain Med.* 28(2), 113–119 (2003).
- 96 Burnham RS, Yasui Y. An alternate method of radiofrequency neurotomy of the sacroiliac joint: a pilot study of the effect on pain, function, and satisfaction. *Reg. Anesth. Pain Med.* 32(1), 12–19 (2007).
- 97 Patel N, Gross A, Brown L, Gekht G. A randomized, placebo-controlled study to assess the efficacy of lateral branch neurotomy for chronic sacroiliac joint pain. *Pain Med.* 13(3), 383–398 (2012).
- 98 Cohen SP, Bajwa ZH, Kraemer JJ *et al.* Factors predicting success and failure for cervical facet radiofrequency denervation: a multicenter analysis. *Reg. Anesth. Pain Med.* 32(6), 495–503 (2007).
- 99 Williams KA, Gonzalez-Fernandez M, Hamzehzadeh S *et al.* A multicenter analysis evaluating factors associated with spinal cord stimulation outcome in chronic pain patients. *Pain Med.* 12(8), 1142–1153 (2011).
- 100 Huang JH, Galvagno SM Jr, Hameed M *et al.* Occipital nerve pulsed radiofrequency treatment: a multicenter study evaluating predictors of outcome. *Pain Med.* 13(4), 489–497 (2012).
- 101 Aydin SM, Gharibo CG, Mehnert M, Stitik TP. The role of radiofrequency ablation for sacroiliac joint pain: a meta-analysis. *PM R.* 2(9), 842–851 (2010).
- 102 Yin W, Willard F, Carreiro J, Dreyfuss P. Sensory stimulation-guided sacroiliac joint radiofrequency neurotomy: technique based on neuroanatomy of the dorsal sacral plexus. *Spine* 28(20), 2419–2425 (2003).
- 103 Buijs E, Kamphuis E, Groen G. Radiofrequency treatment of sacroiliac joint-related pain aimed at the first three sacral dorsal

- rami: a minimal approach. *The Pain Clinic* 16(2), 139–146 (2004).
- 104 Cheng J, Pope JE, Dalton JE, Cheng O, Bensitel A. Comparative outcomes of cooled versus traditional radiofrequency ablation of the lateral branches for sacroiliac joint pain. *Clin. J. Pain* doi:10.1097/AJP.0b013e3182490a17 (2012) (Epub ahead of print).
- 105 Lau P, Mercer S, Govind J, Bogduk N. The surgical anatomy of lumbar medial branch neurotomy (facet denervation). *Pain Med.* 5(3), 289–298 (2004).
- 106 Bruners P, Müller H, Günther RW, Schmitz-Rode T, Mahnken AH. Fluid-modulated bipolar radiofrequency ablation: an *ex vivo* evaluation study. *Acta Radiol.* 49(3), 258–266 (2008).
- 107 Provenzano DA, Lassila HC, Somers D. The effect of fluid injection on lesion size during radiofrequency treatment. *Reg. Anesth. Pain Med.* 35(4), 338–342 (2010).
- 108 Dobrogowski J, Wrzosek A, Wordliczek J. Radiofrequency denervation with or without addition of pentoxifylline or methylprednisolone for chronic lumbar zygapophysial joint pain. *Pharmacol. Rep.* 57(4), 475–480 (2005).
- 109 Pino CA, Hoefl MA, Hofsess C, Rathmell JP. Morphologic analysis of bipolar radiofrequency lesions: implications for treatment of the sacroiliac joint. *Reg. Anesth. Pain Med.* 30(4), 335–338 (2005).
- 110 Kang SS, Park JC, Yoon YJ, Shin KM. Morphologic analysis of water-cooled bipolar radiofrequency lesions on egg white *in Vitro*. *Korean J. Pain* 25(3), 151–154 (2012).
- 111 Cosman ER Jr, Gonzalez CD. Bipolar radiofrequency lesion geometry: implications for palisade treatment of sacroiliac joint pain. *Pain Pract.* 11(1), 3–22 (2011).
- Excellent review on the geometry of bipolar radiofrequency lesions and how they are affected by altering different variables.
- 112 Ferrante FM, King LF, Roche EA *et al.* Radiofrequency sacroiliac joint denervation for sacroiliac syndrome. *Reg. Anesth. Pain Med.* 26(2), 137–142 (2001).
- 113 Lorentzen T. A cooled needle electrode for radiofrequency tissue ablation: thermodynamic aspects of improved performance compared with conventional needle design. *Acad. Radiol.* 3(7), 556–563 (1996).
- 114 Solbiati L, Goldberg SN, Ierace T *et al.* Hepatic metastases: percutaneous radio-frequency ablation with cooled-tip electrodes. *Radiology* 205(2), 367–373 (1997).
- 115 Goldberg SN, Gazelle GS, Solbiati L, Rittman WJ, Mueller PR. Radiofrequency tissue ablation: increased lesion diameter with a perfusion electrode. *Acad. Radiol.* 3(8), 636–644 (1996).
- 116 Delacretaz E, Stevenson WG, Winters GL *et al.* Ablation of ventricular tachycardia with a saline-cooled radiofrequency catheter: anatomic and histologic characteristics of the lesions in humans. *J. Cardiovasc. Electrophysiol.* 10(6), 860–865 (1999).
- 117 Kapural L, Nageeb F, Kapural M, Cata JP, Narouze S, Mekhail N. Cooled radiofrequency system for the treatment of chronic pain from sacroiliitis: the first case-series. *Pain Pract.* 8(5), 348–354 (2008).
- 118 Cohen SP, Hurley RW, Buckenmaier CC 3rd, Kurihara C, Morlando B, Dragovich A. Randomized placebo-controlled study evaluating lateral branch radiofrequency denervation for sacroiliac joint pain. *Anesthesiology* 109(2), 279–288 (2008).
- First study evaluating cooled radiofrequency denervation for sacroiliac joint pain, and first controlled study evaluating any radiofrequency technique against sham denervation.
- 119 Gevargiz A, Groenemeyer D, Schirp S, Braun M. CT-guided percutaneous radiofrequency denervation of the sacroiliac joint. *Eur. Radiol.* 12(6), 1360–1365 (2002).
- 120 Chua NH, Vissers KC, Sluijter ME. Pulsed radiofrequency treatment in interventional pain management: mechanisms and potential indications—a review. *Acta Neurochir. (Wien.)* 153(4), 763–771 (2011).
- 121 Hagiwara S, Iwasaka H, Takeshima N, Noguchi T. Mechanisms of analgesic action of pulsed radiofrequency on adjuvant-induced pain in the rat: roles of descending adrenergic and serotonergic systems. *Eur. J. Pain* 13(3), 249–252 (2009).
- 122 Vallejo R, Benyamin RM, Kramer J, Stanton G, Joseph NJ. Pulsed radiofrequency denervation for the treatment of sacroiliac joint syndrome. *Pain Med.* 7(5), 429–434 (2006).
- 123 Kroll HR, Kim D, Danic MJ, Sankey SS, Gariwala M, Brown M. A randomized, double-blind, prospective study comparing the efficacy of continuous versus pulsed radiofrequency in the treatment of lumbar facet syndrome. *J. Clin. Anesth.* 20(7), 534–537 (2008).
- 124 Tekin I, Mirzai H, Ok G, Erbuyun K, Vatansever D. A comparison of conventional and pulsed radiofrequency denervation in the treatment of chronic facet joint pain. *Clin. J. Pain* 23(6), 524–529 (2007).
- 125 Calvillo O, Esses SI, Ponder C, D’Agostino C, Tanhui E. Neuroaugmentation in the management of sacroiliac joint pain: report of two cases. *Spine* 23(9), 1069–1072 (1998).
- 126 Kim YH, Moon DE. Sacral nerve stimulation for the treatment of sacroiliac joint dysfunction: A case report. *Neuromodulation* 13(4), 306–310 (2010).
- 127 Dabiezies EJ, Millet CW, Murphy CP, Acker JH, Robicheaux RE, D’Ambrosia RD. Stabilization of sacroiliac joint disruption with threaded compression rods. *Clin. Orthop. Relat. Res.* 246, 165–171 (1989).
- 128 Simpson LA, Waddell JP, Leighton RK, Kellam JF, Tile M. Anterior approach and stabilization of the disrupted sacroiliac joint. *J. Trauma* 27(12), 1332–1339 (1987).
- 129 Waisbrod H, Krainick JU, Gerbershagen HU. Sacroiliac joint arthrodesis for chronic lower back pain. *Arch. Orthop. Trauma. Surg.* 106(4), 238–240 (1987).
- 130 Buchowski JM, Kebaish KM, Sinkov V, Cohen DB, Sieber AN, Kostuik JP. Functional and radiographic outcome of sacroiliac arthrodesis for the disorders of the sacroiliac joint. *Spine J.* 5(5), 520–528; discussion 529 (2005).
- 131 Schütz U, Grob D. Poor outcome following bilateral sacroiliac joint fusion for degenerative sacroiliac joint syndrome. *Acta Orthop. Belg.* 72(3), 296–308 (2006).
- 132 Liliang PC, Lu K, Liang CL, Tsai YD, Wang KW, Chen HJ. Sacroiliac joint pain after lumbar and lumbosacral fusion: Findings using dual sacroiliac joint blocks. *Pain Med.* 91(4), 1283–1285 (2011).
- 133 Jung JH, Kim HI, Shin DA *et al.* Usefulness of pain distribution pattern assessment in decision-making for the patients with lumbar zygapophysial and sacroiliac joint arthropathy. *J. Korean Med. Sci.* 22(6), 1048–1054 (2007).

- 134 Laslett M, Young SB, Aprill CN, McDonald B. Diagnosing painful sacroiliac joints: a validity study of a McKenzie evaluation and sacroiliac provocation tests. *Aust. J. Physiother.* 49(2), 89–97 (2003).
- 135 Stanford G, Burnham RS. Is it useful to repeat sacroiliac joint provocative tests post-block? *Pain Med.* 11(12), 1774–1776 (2010).
- 136 Karaman H, Kavak GO, Tüfek A *et al.* Cooled radiofrequency application for treatment of sacroiliac joint pain. *Acta Neurochir. (Wien.)* 153(7), 1461–1468 (2011).
- 137 Speldewinde GC. Outcomes of percutaneous zygapophysial and sacroiliac joint neurotomy in a community setting. *Pain Med.* 12(2), 209–218 (2011).