

Antibiotic-Induced Neurotoxicity

Shamik Bhattacharyya · Ryan Darby · Aaron L. Berkowitz

© Springer Science+Business Media New York 2014

Abstract Antibiotic neurotoxicity is rare but can cause significant morbidity when it occurs. The risk of antibiotic neurotoxicity appears to be highest in patients who are older, have impaired renal function, or have preexisting neurologic conditions. This review describes the clinical features of the most common antibiotic toxicities affecting the nervous system: seizures, encephalopathy, optic neuropathy, peripheral neuropathy, and exacerbation of myasthenia gravis.

Keywords Neurotoxicity · Antibiotics · Seizures · Encephalopathy · Neuropathy · Myasthenia gravis

Introduction

Antibiotics can cause a variety of adverse effects on the nervous system, including seizures, encephalopathy, optic neuropathy, peripheral neuropathy, and exacerbation of myasthenia gravis. Since antibiotics are commonly prescribed and neurotoxicity is often reversible if identified early, providers should be aware of the clinical symptoms and signs associated with neurotoxicity. Here, we review the clinical features and management of some of the major categories of antibiotic neurotoxicity.

Shamik Bhattacharyya and Ryan Darby contributed equally to the work.

This article is part of the Topical Collection on *Central Nervous System Infections*

S. Bhattacharyya · R. Darby
Department of Neurology, Massachusetts General Hospital, 55 Fruit Street, Boston, MA, USA

S. Bhattacharyya (✉) · R. Darby · A. L. Berkowitz
Department of Neurology, Brigham & Women's Hospital, 75 Francis Street, Boston, MA, USA
e-mail: sbhattacharyya3@partners.org

Seizures

Penicillins, cephalosporins, carbapenems, and fluoroquinolones are the antibiotic classes most commonly associated with seizures. Other antibiotics that have been associated with seizures include metronidazole when taken for prolonged periods [1] and isoniazid when taken in overdose [2]. β -Lactam antibiotics and fluoroquinolones are thought to provoke seizures through inhibitory effects on gamma-aminobutyric acid (GABA) transmission [3, 4]. Since GABA is the primary inhibitory neurotransmitter of the central nervous system, interference with GABA results in predisposition toward excitatory neurotransmission, which can lead to seizures.

Antibiotic-associated seizures are rare, with incidence ranging from 0.04 % for cephalosporins to 0.1–0.5 % with fluoroquinolones [5–7]. However, seizures may occur in up to 20 % of patients with underlying structural brain lesions and renal dysfunction who are treated with imipenem [8]. There are also differences in seizure incidence among individual antibiotics within a class. Seizures have been observed with ciprofloxacin more commonly than with levofloxacin (0.5 % vs. 0.1 %) [6, 7], and the risk may be higher with imipenem than with other carbapenems [9]. Risk factors for antibiotic-induced seizures include renal insufficiency, age greater than 50, use of higher than recommended doses, and alteration of the blood-brain barrier allowing for increased concentration of the antibiotic in the brain (e.g., due to brain tumor or during cardiopulmonary bypass) [10, 11].

Both tonic-clonic and nonconvulsive seizures have been reported with antibiotic neurotoxicity. While tonic-clonic seizures are clinically evident, nonconvulsive seizures manifest as alterations in consciousness ranging from encephalopathy to coma, with electroencephalography (EEG) showing electrographic seizures [12]. Up to 8 % of comatose patients may be experiencing nonconvulsive seizures [13]. Therefore,

EEG monitoring should be considered in patients with alteration in cognition following initiation of antibiotic therapy. The prognostic significance and appropriate management of nonconvulsive seizures, however, remain unclear [14].

In patients with severe renal failure who develop antibiotic-induced seizures, dialysis may be necessary to remove the antibiotic. Status epilepticus from antibiotic toxicity should be managed as in other circumstances. Since antibiotic-induced seizures are acute symptomatic (provoked) seizures, long-term antiepileptic therapy is generally not necessary. Short-term treatment with antiepileptic drugs may be warranted if seizures are recurrent. After an antibiotic-induced seizure, it is unknown whether patients have an increased risk of seizures with other drugs in the same antibiotic class.

Antibiotic-Antiepileptic Interactions

Antibiotics can alter the serum concentrations of antiepileptics, resulting in seizures or antiepileptic drug toxicity. Signs of antiepileptic drug toxicity include encephalopathy, nystagmus, imbalance, and/or ataxia. While the possible pharmacologic interactions between antibiotics and antiepileptics are numerous, only a few are clinically significant. One of the more commonly reported significant interactions is a marked reduction in serum valproic acid concentration following carbapenem administration, which can lead to seizures in epileptic patients. Mechanisms of this interaction include decreased intestinal transport of valproic acid and sequestration of valproic acid in erythrocytes [15]. Serum valproic acid concentration has been reported to fall by as much as 66 % in the presence of meropenem, though the degree of change is highly variable [16]. Animal data suggest that imipenem likely has the same effect [17]. Carbapenems should therefore ideally be avoided in patients receiving valproic acid. If carbapenems are essential for a particular infection in a patient on valproic acid therapy, serum valproic acid levels should be followed closely, and an additional antiepileptic medication could be considered if therapeutic levels of valproic acid are difficult to maintain.

Antibiotic-antiepileptic combinations that have been reported to increase antiepileptic drugs to toxic levels include chloramphenicol with phenytoin [18] and clarithromycin [19], erythromycin [20], or isoniazid with carbamazepine [21].

Given potential interactions between antiepileptics and antibiotics, a serum antiepileptic drug level should be drawn at the time of initiation of antibiotic therapy, and the patient should be closely monitored for seizures or antiepileptic drug toxicity. The development of either warrants a repeat serum antiepileptic drug level to compare with the initial level.

Encephalopathy

Common symptoms of encephalopathy include confusion, somnolence, agitation, psychosis, and/or hallucinations, all of which may wax and wane. Encephalopathy is one of the most commonly occurring neuropsychological conditions in the hospital, occurring in 10 % of medically ill patients and in about 60–80 % of patients in medical intensive care units [22]. While the differential diagnosis of acute encephalopathy is broad in hospitalized patients, antibiotics may cause or contribute to encephalopathy through direct toxic effects or by causing nonconvulsive seizures that present as altered mental status (see “Seizures”). The antibiotics most commonly associated with encephalopathy are metronidazole, fluoroquinolones, macrolides, and β -lactams (particularly cephalosporins). Antibiotic-induced encephalopathy has also been reported in association with gentamicin [23], linezolid [24], and trimethoprim-sulfamethoxazole [25, 26]. Renal failure, especially acute renal failure, is a risk factor for the development of encephalopathy with fluoroquinolones and β -lactams, although cases of antibiotic-induced encephalopathy have been reported in patients with normal renal function with both antibiotic classes [27]. Other risk factors for the development of antibiotic-induced encephalopathy include older age and premorbid neurological impairment [27]. The rate of cross-reactivity between different antibiotics within the same class is unknown. Encephalopathy is usually reversible after cessation of the inciting antibiotic.

Certain classes of antibiotics have been associated with particular constellations of central neurotoxic symptoms beyond encephalopathy. Metronidazole neurotoxicity most commonly causes cerebellar signs (ataxia, gait disturbance, nystagmus), though these are accompanied by encephalopathy in about one third of cases [28]. A characteristic MRI pattern including T2 hyperintensities in the dentate nuclei of the cerebellum and/or splenium of the corpus callosum is present in nearly 90 % of cases of metronidazole neurotoxicity (Fig. 1) [28]. Clarithromycin neurotoxicity commonly causes psychiatric symptoms such as mania and hallucinations [29].

Optic Neuropathy

Optic neuropathy caused by antibiotics generally presents as painless, progressive, symmetric visual loss with decrease in color vision (especially red-green discrimination) [30]. Visual field testing typically reveals centrocecal defects (loss of vision between the point of fixation and blind spot) and/or bitemporal defects (loss of bilateral peripheral vision) [31]. The antibiotics most frequently associated with optic neuropathy are ethambutol and linezolid, although individual case reports have described optic neuropathy with other antibiotics including ciprofloxacin [32], levofloxacin [33],

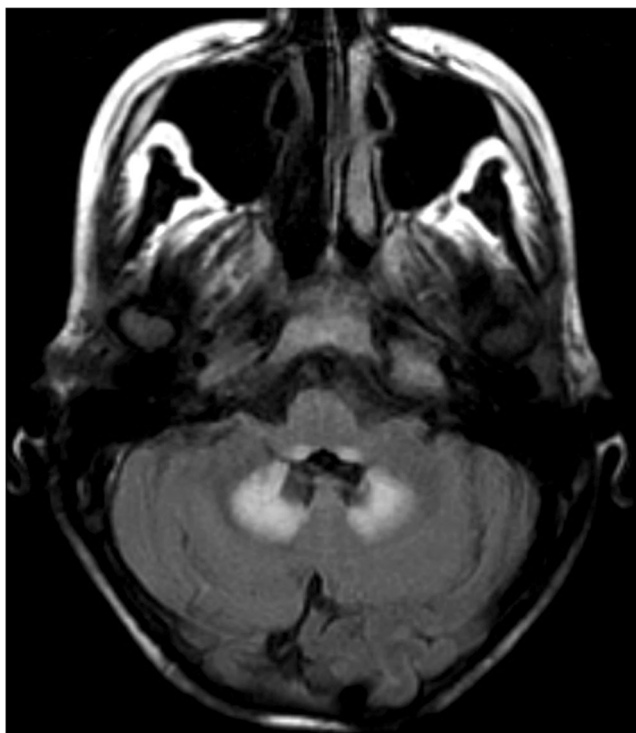


Fig. 1 T2/FLAIR-weighted MRI of the brain shows hyperintensities in the dorsal medulla and in the dentate nuclei of the cerebellum in a patient taking metronidazole (500 mg every 8 h for 4 weeks) who developed ataxia, slurred speech, and bilateral dysmetria

chloramphenicol [34], metronidazole [35], sulfonamides [30], isoniazid [30], and streptomycin [30].

Ethambutol is estimated to cause optic neuropathy in 1 % of patients taking standard doses (15 mg/kg/day), but in as many 50 % in patients taking doses in excess of 60 mg/kg/day [36]. Optic neuropathy is thought to be secondary to ethambutol-induced mitochondrial dysfunction [30, 36], and pathology has demonstrated demyelinating lesions in the optic nerve and chiasm [37]. Risk factors for developing optic neuropathy due to ethambutol include older age, hypertension, renal disease, prolonged duration of therapy (greater than 2 months), and higher doses (above 15–20 mg/kg/day) [30, 31, 36]. Patients who require ethambutol for prolonged periods should undergo a screening ophthalmological examination prior to initiation of therapy and follow-up examinations every 1 to 3 months (though practice varies across centers) to test for subclinical development of visual dysfunction [36]. If optic neuropathy develops, ethambutol should ideally be discontinued in favor of an alternative antibiotic. Vision loss is generally reversible, although permanent visual loss may occur after prolonged treatment [36, 38].

Like ethambutol, linezolid is also thought to cause optic neuropathy through mitochondrial toxicity [39]. Duration of use is a significant risk factor, and most reported cases are in patients taking linezolid for longer than 1 month [36, 40]. The incidence of linezolid-induced optic neuropathy is unclear

since data have primarily been reported in case reports and series. Cessation of linezolid generally results in recovery of vision [36].

Peripheral Neuropathy

Peripheral neuropathy can be classified pathophysiologically (i.e., as axonal, demyelinating, or a combination of the two), by symptom type (i.e., sensory, motor, sensorimotor, autonomic), or by the type of nerve fiber affected (i.e., large fiber versus small fiber). Symptoms of peripheral neuropathy can include sensory changes (e.g., numbness, pain, paresthesias), weakness, and/or autonomic dysfunction (e.g., orthostatic hypotension, altered sweating, bladder dysfunction, gastroparesis). Examination typically shows sensory loss in one or more modalities (light touch, pain, proprioception, and/or vibration), diminished or absent reflexes, and/or weakness. Imbalance, Romberg sign, and incoordination (sensory ataxia) may be present if proprioception is severely impaired. Axonal neuropathies usually present in a length-dependent fashion, with the feet affected first and the hands becoming symptomatic only after the neuropathy has involved the lower extremities to the level of the mid-calves. In demyelinating neuropathies, both upper and lower extremities may be affected both proximally and distally at presentation. This clinical distinction between axonal (length-dependent) and demyelinating (non-length-dependent) patterns of neuropathy aids in the initial differential diagnosis since toxic (e.g., medications and heavy metals) and metabolic etiologies (e.g., diabetes and B₁₂ deficiency) generally cause axonal neuropathies, whereas immune-mediated (e.g., chronic inflammatory demyelinating polyneuropathy [CIDP] and most paraprotein-associated neuropathies) and infectious (e.g., leprosy) neuropathies are predominantly demyelinating, although exceptions to these general principles exist. Hereditary neuropathies also occur (e.g., Charcot-Marie-Tooth) and may be demyelinating or axonal.

The antibiotics most commonly associated with peripheral neuropathy are metronidazole, linezolid, and dapsone, though neuropathy has also been described in patients taking chloramphenicol, chloroquine, ethambutol, fluoroquinolones, isoniazid, nitrofurantoin, and sulfasalazine [41, 42]. The mechanism of antibiotic-induced neuropathy is thought in most cases to be axonal injury caused by effects on DNA repair, cell metabolism, and mitochondrial function [43].

Antibiotic-induced peripheral neuropathies are most commonly length-dependent sensorimotor neuropathies, although autonomic neuropathy has been reported with metronidazole [44], pure motor neuropathy with dapsone [45], and optic neuropathy with linezolid (see “[Optic Neuropathy](#)”) [46]. The majority of cases of antibiotic-induced peripheral

neuropathy occur in patients with prolonged antibiotic exposure (i.e., months in duration) with incidence reported to be as high as 50 % in patients with long-term use of metronidazole [47] or linezolid [48]. In most patients, recovery occurs over weeks to months after cessation of antibiotics, although neuropathy may rarely persist [49–51]. In some patients, the neuropathy may continue to progress for several weeks following discontinuation of antibiotics before beginning to improve, a phenomenon referred to as “coasting” [43, 52].

Antibiotic-Induced Exacerbation of Myasthenia Gravis

Myasthenia gravis (MG) is an autoimmune disorder in which antibodies against postsynaptic receptors at the neuromuscular junction cause fluctuating weakness in ocular, bulbar, proximal limb, and respiratory muscles. Symptoms include diplopia, ptosis, dysarthria, dysphagia, and proximal limb weakness, all of which may become more prominent at the end of the day or after activity. The majority of patients have measurable serum antibodies against the acetylcholine receptor (AChR) or, less commonly, the muscle-specific receptor tyrosine kinase (MuSK), and 10–15 % will have thymomas [53]. Electromyogram (EMG) demonstrates decrement in amplitude of compound motor action potentials (CMAP) with repetitive stimulation and increased jitter (variability of the interval between muscle potentials) with single muscle fiber EMG.

Exacerbations of myasthenic symptoms range from mild to severe, with severe cases leading to respiratory failure requiring ventilatory support referred to as myasthenic crises. Flares of MG can be triggered by infections, surgery, and medications. The medications known to trigger MG exacerbations include antibiotics, antiarrhythmic agents, immunosuppressive agents, anticonvulsants, and anticholinergic medications [54]. The antibiotics most commonly reported to precipitate flares of MG are aminoglycosides, fluoroquinolones, and macrolides [55–61]. Individual case reports have described MG exacerbations with clindamycin, colistin, tetracyclines, ampicillin, imipenem, and paramixin B [54, 62]. The proposed mechanisms of antibiotic-induced exacerbations of MG include presynaptic interactions with voltage-gated calcium channels and calcium-sensitive receptors as well as postsynaptic interactions with acetylcholine receptors [63–67].

Aminoglycosides, fluoroquinolones, and macrolides should therefore ideally be avoided in patients with MG. If one or more of these antimicrobial agents is necessary for treatment of a particular infection in a patient with MG, patients should be monitored closely for any worsening MG-related symptoms (e.g., weakness, dysarthria, dysphagia, shortness of breath).

Conclusion

Onset of new neurologic symptoms or signs after the initiation of antibiotics should raise suspicion for potential antibiotic neurotoxicity. Careful selection of antibiotics and dosages is essential in older patients, as well as in patients with renal insufficiency, epilepsy, or myasthenia gravis in order to prevent avoidable iatrogenic neurologic complications. If patients in these at-risk populations are infected with organisms requiring a specific antibiotic regimen that has been associated with neurotoxicity, appropriate monitoring should be initiated to facilitate early identification of neurotoxicity. Such monitoring may include long-term EEG monitoring in hospitalized patients who develop encephalopathy after initiation of antibiotics, serum antiepileptic drug concentrations in patients with epilepsy taking antiepileptic medications initiated on antibiotics, and serial ophthalmologic examinations in patients receiving antibiotics known to cause optic neuropathy. Given that antibiotic neurotoxicity is likely under-recognized, continued reporting is essential to understand more fully which patients are at the highest risk for neurologic complications of antibiotic therapy.

Compliance with Ethics Guidelines

Conflict of Interest Ryan Darby and Shamik Bhattacharyya have no conflict of interest relevant to the manuscript. Dr. Berkowitz has no conflicts of interests relevant to the manuscript, but receives royalties from *Clinical Pathophysiology Made Ridiculously Simple* (Medmaster) and *The Improvising Mind* (Oxford).

Human and Animal Rights and Informed Consent This article does not contain any studies with human or animal subjects performed by the author.

References

1. Frytak S, Moertel CH, Childs DS. Neurologic toxicity associated with high-dose metronidazole therapy. *Ann Intern Med.* 1978;88: 361–2.
2. Maw G, Aitken P. Isoniazid overdose: a case series, literature review and survey of antidote availability. *Clin Drug Investig.* 2003;23:479–85.
3. Grøndahl TO, Langmoen IA. Epileptogenic effect of antibiotic drugs. *J Neurosurg.* 1993;78:938–43.
4. Lode H. Potential interactions of the extended-spectrum fluoroquinolones with the CNS. *Drug Saf Int J Med Toxicol Drug Exp.* 1999;21:123–35.
5. Linden P. Safety profile of meropenem: an updated review of over 6, 000 patients treated with meropenem. *Drug Saf Int J Med Toxicol Drug Exp.* 2007;30:657–68.
6. Arcieri GM, Becker N, Esposito B, Griffith E, Heyd A, Neumann C, et al. Safety of intravenous ciprofloxacin. A review. *Am J Med.* 1989;87:92S–7S.
7. Yagawa K. Latest industry information on the safety profile of levofloxacin in Japan. *Chemotherapy.* 2001;47 Suppl 3:38–43. *discussion 44–48.*

8. Moellering Jr RC, Eliopoulos GM, Sentochnik DE. The carbapenems: new broad spectrum beta-lactam antibiotics. *J Antimicrob Chemother.* 1989;24(Suppl A):1–7.
9. Cannon JP, Lee TA, Clark NM, Setlak P, Grim SA. The risk of seizures among the carbapenems: a meta-analysis. *J Antimicrob Chemother* 2014
10. Schliamser SE, Cars O, Norrby SR. Neurotoxicity of beta-lactam antibiotics: predisposing factors and pathogenesis. *J Antimicrob Chemother.* 1991;27:405–25.
11. Lerner PI, Smith H, Weinstein L. Penicillin neurotoxicity. *Ann N Y Acad Sci.* 1967;145:310–8.
12. Chang Y-M. Cefepime-induced nonconvulsive status epilepticus as a cause of confusion in an elderly patient: a case report. *J Formos Med Assoc Taiwan Yi Zhi* 2013
13. Towne AR, Waterhouse EJ, Boggs JG, Gamett LK, Brown AJ, Smith JR, et al. Prevalence of nonconvulsive status epilepticus in comatose patients. *Neurology.* 2000;54:340–5.
14. Holtkamp M, Meierkord H. Nonconvulsive status epilepticus: a diagnostic and therapeutic challenge in the intensive care setting. *Ther Adv Neurol Disord.* 2011;4:169–81.
15. Mancl EE, Gidal BE. The effect of carbapenem antibiotics on plasma concentrations of valproic acid. *Ann Pharmacother.* 2009;43:2082–7.
16. Spriet I, Goyens J, Meersseman W, Wilmer A, Willems L, Van Paesschen W. Interaction between valproate and meropenem: a retrospective study. *Ann Pharmacother.* 2007;41:1130–6.
17. Gu J, Huang Y. Effect of concomitant administration of meropenem and valproic acid in an elderly Chinese patient. *Am J Geriatr Pharmacother.* 2009;7:26–33.
18. Rose JQ, Choi HK, Schentag JJ, Kinkel WR, Jusko WJ. Intoxication caused by interaction of chloramphenicol and phenytoin. *J Am Med Assoc.* 1977;237:2630–1.
19. O'Connor NK, Fris J. Clarithromycin-carbamazepine interaction in a clinical setting. *J Am Board Fam Pract.* 1994;7:489–92.
20. Tagawa T, Mimaki T, Ono J, Tanaka J, Suzuki Y, Itagaki T, et al. Erythromycin-induced carbamazepine intoxication in two epileptic children. *Jpn J Psychiatr Neurol.* 1989;43:513–4.
21. Block SH. Carbamazepine-isoniazid interaction. *Pediatrics.* 1982;69:494–5.
22. Maldonado JR. Delirium in the acute care setting: characteristics, diagnosis and treatment. *Crit Care Clin.* 2008;24:657–722. vii.
23. Bischoff A, Meier C, Roth F. Gentamicin neurotoxicity (polyneuropathy–encephalopathy). *Schweiz Med Wochenschr.* 1977;107:3–8.
24. Fletcher J, Aykroyd LE, Feucht EC, Curtis JM. Early onset probable linezolid-induced encephalopathy. *J Neurol.* 2010;257:433–5.
25. Saidinejad M, Ewald MB, Shannon MW. Transient psychosis in an immune-competent patient after oral trimethoprim-sulfamethoxazole administration. *Pediatrics.* 2005;115:e739–741.
26. Cooper GS, Blades EW, Remler BF, Salata RA, Bennert KW, Jacobs GH. Central nervous system Whipple's disease: relapse during therapy with trimethoprim-sulfamethoxazole and remission with cefixime. *Gastroenterology.* 1994;106:782–6.
27. Grill MF, Maganti RK. Neurotoxic effects associated with antibiotic use: management considerations. *Br J Clin Pharmacol.* 2011;72:381–93.
28. Kuriyama A, Jackson JL, Doi A, Kamiya T. Metronidazole-induced central nervous system toxicity: a systematic review. *Clin Neuropharmacol.* 2011;34:241–7.
29. Bandettini di Poggio M, Anfosso S, Audenino D, Primavera A. Clarithromycin-induced neurotoxicity in adults. *J Clin Neurosci Off J Neurosurg Soc Australas.* 2011;18:313–8.
30. Sharma P, Sharma R. Toxic optic neuropathy. *Indian J Ophthalmol.* 2011;59:137–41.
31. Melamud A, Kosmorsky GS, Lee MS. Ocular ethambutol toxicity. *Mayo Clin Proc.* 2003;78:1409–11.
32. Samarakoon N, Harrisberg B, Ell J. Ciprofloxacin-induced toxic optic neuropathy. *Clin Exp Ophthalmol.* 2007;35:102–4.
33. Das S, Mondal S. Oral levofloxacin-induced optic neuritis progressing in loss of vision. *Ther Drug Monit.* 2012;34:124–5.
34. Godel V, Nemet P, Lazar M. Chloramphenicol optic neuropathy. *Arch Ophthalmol.* 1980;98:1417–21.
35. McGrath NM, Kent-Smith B, Sharp DM. Reversible optic neuropathy due to metronidazole. *Clin Exp Ophthalmol.* 2007;35:585–6.
36. Van Stavern GP. Metabolic, hereditary, traumatic, and neoplastic optic neuropathies. *Continuum (Minneapolis Minn).* 2014;20:877–906.
37. Lessell S. Histopathology of experimental ethambutol intoxication. *Invest Ophthalmol Vis Sci.* 1976;15:765–9.
38. Choi SY, Hwang JM. Optic neuropathy associated with ethambutol in Koreans. *Korean J Ophthalmol.* 1997;11:106–10.
39. Javaheri M, Khurana RN, O'hearn TM, Lai MM, Sadun AA. Linezolid-induced optic neuropathy: a mitochondrial disorder? *Br J Ophthalmol.* 2007;91:111–5.
40. Rucker JC, Hamilton SR, Bardenstein D, Isada CM, Lee MS. Linezolid-associated toxic optic neuropathy. *Neurology.* 2006;66:595–8.
41. Weimer LH, Sachdev N. Update on medication-induced peripheral neuropathy. *Curr Neurol Neurosci Rep.* 2009;9:69–75.
42. Manji H. Drug-induced neuropathies. *Handb Clin Neurol.* 2013;115:729–42.
43. Pratt RW, Weimer LH. Medication and toxin-induced peripheral neuropathy. *Semin Neurol.* 2005;25:204–16.
44. Hobson-Webb LD, Roach ES, Donofrio PD. Metronidazole: newly recognized cause of autonomic neuropathy. *J Child Neurol.* 2006;21:429–31.
45. Saqueton AC, Lorincz AL, Vick NA, Hamer RD. Dapsone and peripheral motor neuropathy. *Arch Dermatol.* 1969;100:214–7.
46. Narita M, Tsuji BT, Yu VL. Linezolid-associated peripheral and optic neuropathy, lactic acidosis, and serotonin syndrome. *Pharmacotherapy.* 2007;27:1189–97.
47. Carroll MW, Jeon D, Mount JM, Lee JD, Jeong YJ, Zia N, et al. Efficacy and safety of metronidazole for pulmonary multidrug-resistant tuberculosis. *Antimicrob Agents Chemother.* 2013;57:3903–9.
48. Sotgiu G, Centis R, D'Ambrosio L, Alffenaar J-WC, Anger HA, Caminero JA, et al. Efficacy, safety and tolerability of linezolid containing regimens in treating MDR-TB and XDR-TB: systematic review and meta-analysis. *Eur Respir J.* 2012;40:1430–42.
49. Boyce EG, Cookson ET, Bond WS. Persistent metronidazole-induced peripheral neuropathy. *DICP Ann Pharmacother.* 1990;24:19–21.
50. Bressler AM, Zimmer SM, Gilmore JL, Somani J. Peripheral neuropathy associated with prolonged use of linezolid. *Lancet Infect Dis.* 2004;4:528–31.
51. Rhodes LE, Coleman MD, Lewis-Jones MS. Dapsone-induced motor peripheral neuropathy in pemphigus foliaceus. *Clin Exp Dermatol.* 1995;20:155–6.
52. Dalakas MC. Peripheral neuropathy and antiretroviral drugs. *J Peripher Nerv Syst.* 2001;6:14–20.
53. Meriglioli MN, Sanders DB. Autoimmune myasthenia gravis: emerging clinical and biological heterogeneity. *Lancet Neurol.* 2009;8:475–90.
54. Wittbrodt ET. Drugs and myasthenia gravis. An update. *Arch Intern Med.* 1997;157:399–408.
55. Hokkanen E. Antibiotics in myasthenia gravis. *Br Med J.* 1964;1:1111–2.
56. Hokkanen E. The aggravating effect of some antibiotics on the neuromuscular blockade in myasthenia gravis. *Acta Neurol Scand.* 1964;40:346–52.
57. Jones SC, Sorbello A, Boucher RM. Fluoroquinolone-associated myasthenia gravis exacerbation: evaluation of postmarketing reports from the US FDA adverse event reporting system and a literature review. *Drug Saf Int J Med Toxicol Drug Exp.* 2011;34:839–47.
58. Pradhan S, Pardasani V, Ramteke K. Azithromycin-induced myasthenic crisis: reversibility with calcium gluconate. *Neurol India.* 2009;57:352–3.

59. Pijpers E, van Rijswijk RE, Takx-Köhlen B, Schrey G. A clarithromycin-induced myasthenic syndrome. *Clin Infect Dis Off Publ Infect Dis Soc Am.* 1996;22:175–6.
60. Absher JR, Bale JF. Aggravation of myasthenia gravis by erythromycin. *J Pediatr.* 1991;119:155–6.
61. May EF, Calvert PC. Aggravation of myasthenia gravis by erythromycin. *Ann Neurol.* 1990;28:577–9.
62. Argov Z, Mastaglia FL. Drug therapy: disorders of neuromuscular transmission caused by drugs. *N Engl J Med.* 1979;301:409–13.
63. Dobrev D, Ravens U. Therapeutically relevant concentrations of neomycin selectively inhibit P-type Ca^{2+} channels in rat striatum. *Eur J Pharmacol.* 2003;461:105–11.
64. Harnett MT, Chen W, Smith SM. Calcium-sensing receptor: a high-affinity presynaptic target for aminoglycoside-induced weakness. *Neuropharmacology.* 2009;57:502–5.
65. Sieb JP, Milone M, Engel AG. Effects of the quinoline derivatives quinine, quinidine, and chloroquine on neuromuscular transmission. *Brain Res.* 1996;712:179–89.
66. Sieb JP. Fluoroquinolone antibiotics block neuromuscular transmission. *Neurology.* 1998;50:804–7.
67. Bertrand D, Bertrand S, Neveu E, Fernandes P. Molecular characterization of off-target activities of telithromycin: a potential role for nicotinic acetylcholine receptors. *Antimicrob Agents Chemother.* 2010;54:5399–402.