



Role of Histopathology in The Diagnosis of Nasal Polypoidal Masses

KEYWORDS

Nasal polypoidal masses, histopathology, diagnosis, prospective study

Dr. T. Dinesh Singh

Department of ENT, OHRC, Deccan College of Medical Sciences, Kanchanbagh, Hyderabad

Dr. Kiran Meshram

Kameneni Institute of Medical Sciences, Department of ENT, Narketpally, Hyderabad

Sara Shreen

Teegala Krishna Reddy College of Pharmacy, Meerpet, Hyderabad

Nazima Begum

CLRD, Deccan College of Medical Sciences, Hyderabad

Sandeep K Vishwakarma

CLRD, Deccan College of Medical Sciences, Hyderabad

Dr. Aleem A Khan

CLRD, Deccan College of Medical Sciences, Hyderabad

ABSTRACT Nasal polyps were first described more than 2500 years ago and comprise the most common group of mass lesion encountered in the nose. The word polyp comes from Greek although it was subsequently latinized and means many footed (polypous). Oedematous, hypertrophied and sagged masses of nasal mucous membrane covered with columnar and ciliated epithelium are called nasal polyp. They may be solitary or multiple, pedunculate or sessile, unilateral or bilateral. Polyps were recognized as projection of mucous membrane developing in association with chronic rhinitis, sinusitis, but more especially with allergic disease and polypoid benign and malignant neoplasm. For the reason it becomes important that all polyps and polypoidal lesions of nose should be submitted for histopathological examinations. Therefore, types of polyps, their histomorphology, etiopathogenesis, and the contribution of allergy, bacterial infection and other causes of formation of polyps will need to be evaluated.

Introduction

Nasal polyps were first described more than 2500 years ago and comprise the most common group of mass lesion encountered in the nose. Oedematous, hypertrophied and sagged masses of nasal mucous membrane covered with columnar and ciliated epithelium are called nasal polyp. They may be solitary or multiple, pedunculate or sessile, unilateral or bilateral. Polyps were recognized as projection of mucous membrane developing in association with chronic rhinitis, sinusitis, but more especially with allergic disease and polypoid benign and malignant neoplasm. For the reason it becomes important that all polyps and polypoidal lesions of nose should be submitted for histopathological examinations (Chaturvedi et al. 1986). There are 4 major forms of the Nasal polyps such as

Non-neoplastic lesions: Ethmoidal polypi, Antchoanal polyp, Hypertropic polyp, Rhinosporidiosis. Fungal Granuloma, Meningocele, Encephalocele, Glioma

Neoplastic benign tumors: Everted papilloma, Bleeding polypus of septum, Angioma of the sinuses, Nasopharyngeal angiofibroma, Fibroma, Ossifying fibroma, Leiomyoma, Schwannoma, Osteoma, Chondroma, Fibrous dysplasia

Neoplastic intermediate tumors: Inverted papilloma, Cylindric cell papilloma, Haemangio pericytoma, Meningioma, Oncocytoma

Neoplastic malignant tumors: Basal cell carcinoma, Squamous cell Carcinoma, Tumors of minor salivary glands, Sarcomas, Malignant melanoma, Esthesioneuroblastoma, Lymphoreticular neoplasms, Plasmacytoma, Adenocarcinoma, Undifferentiated carcinoma, Malignant fibrous dysplasia, Malignant neurogenous tumors

These polypoidal masses in the nasal cavity form a complex group of lesions with a wide spectrum of histopatho-

logic features. Polypoidal masses in nose are of soft tissue density, Usually hypodense and are frequently present in the region of middle turbinate. Bony remodeling or attenuation can be differentiated from bony erosion caused by other conditions. Increased density within the soft tissue of polyps may be due to fungal infection. Investigations such as complete blood picture (CBP), complete urine examination, nasal smear, stool test, X-ray, magnetic resonance imaging (MRI) and computed tomography (CT) scan are some of the vital diagnostic tools to define the site and extent of the disease in order to plan treatment. Histopathology plays an important role in the diagnosis and management of patients presenting with polypoidal masses in the nose. This will help to identify exact type of polyps, their histomorphology, etiopathogenesis, and the contribution of allergy, bacterial infection and other causes of formation of polyps (Chu et al. 1999). Hence the present study was aimed to study the incidence of various polypoidal masses in the nose in different age and sex groups, the role of histopathology as a confirmatory diagnostic tool for nasal polypoidal masses and finally the differences between clinical diagnosis and histological diagnosis of nasal polypoidal masses.

Materials and Methods

Patients attending outpatients department in Gandhi Hospital, Hyderabad and Gandhi units of Government ENT Hospital, Hyderabad presenting with nasal polypoidal masses were the source of the present study. The type of study is a prospective study. Informed consent was obtained in every case. Detailed clinical history was taken and through physical examination was done in each case. In some patients, polypoidal masses were sent for histopathological study after polypectomy, while in other cases biopsy of the nasal polypoidal masses was done and sent for histopathological confirmation. The patients treated accordingly after pathological report. Paraffin blocks of the tissues were obtained and routinely processed. Histopatho-

logically sections were cut of 4-6mm thickness on a rotator microtome and were stained by Haematoxyline and Eosin stain. Special stained were undertaken whenever applicable.

Histopathological staining of the sections was performed as using Haematoxyline Eosin (stains nucleus in purple and cytoplasm in pink) and gomori's reticulum (stains reticular fibres in black and nuclei in gray) as per the standard protocols. Melanin bleeding method was performed to identify reduction in melanin.

Observations

Nasal polypoidal masses are commonly encountered in clinical practice. Following were made in this prospective study of 35 cases of nasal polypoidal masses over a period of 2 years from January 2000 to December 2001.

Age Incidence: The majority of cases belonged to age group between 11-20 years and 21-30 years group, youngest patient was 4 years old and oldest patient was 60 years old.

Age (Year)	Sex		Total	Percentage
	Male	Female		
0-10	1	1	2	5.7
11-20	6	6	12	34.2
21-30	7	3	10	28.5
31-40	3	2	05	14.25
41-50	2	2	04	11.4
51-60	1	1	02	5.7
Total	20	15	35	

Sex incidence: Male 20=57%
Females 15=43%

There was a slight male preponderance.

Symptoms: Majority of patients presented with nasal obstruction and nasal discharge.

Symptoms	No. of cases	Percentage
Nasal obstruction	30	85.5
Nasal discharge	18	51.3
Nose mass	3	8.55
Bleeding from nose	1	2.85

Investigation: Routine investigation like CBP, CUE, RBS, Blood Urea, Serum Creatinine, and ECG were done in all cases. X-ray PNS was done for all cases. CT-Scan was done for 22 cases (Fig. 1-4).

Treatment: Surgery was done for all cases.

Surgery	No. of cases	Percentage
Polypectomy	31	88.35
Caldwell-Luc operation	1	2.85
Moure's Lateral Rhinomy	3	8.55

Histopathological Diagnosis: Incidence of disease by histopathological confirmation was follows:

Diagnosis	Males	Females	No. of cases	Percentage
Allergic polyp	6	7	13	37.05
Inflammatory polyp	7	5	12	34.2
Angiofibroma	2	2	4	11.4
Fungal granuloma	2	1	3	8.55
Squamous papilloma	0	1	1	2.85
Inverted papilloma	1	0	1	2.85
Embryonal Rhabdomyosarcoma	1	0	1	2.85
Total no. of cases:	19	16	35	

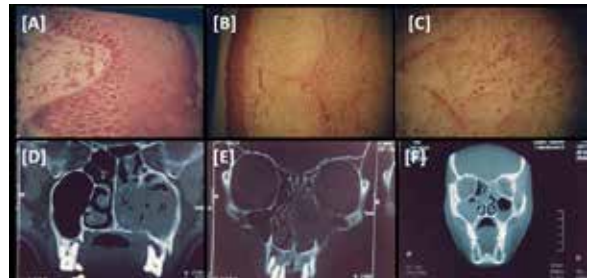


Fig. 1 [A-C] Histopathology of cases 1 to 3 and [D-F] CT scan of cases 4-6

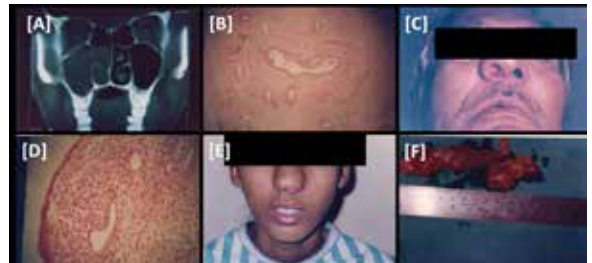


Fig. 2 [A] CT scan of case 7 [B] Histopathology of case 8 [C] Case 10 [D] Histopathology of case 11 [E-F] Case 12

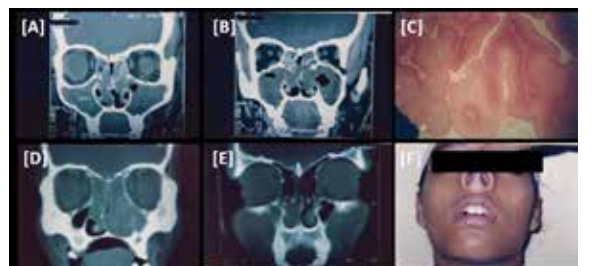


Fig. 3 [A-B] CT scan of cases 13 and 15 [C] Histology of case 16 [D-E] CT scan of cases 18 and 19 [F] Case 21

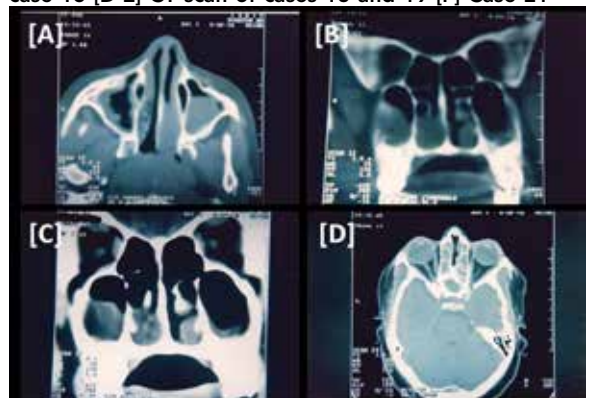


Fig. 4 [A-D] CT scan of cases 22-25

Out of the 35 cases, 13 cases were Allergic polyp, 12 cases were inflammatory polyps and 3 cases were Fungal Granulomas. Rest of the 7 polypoidal masses were Neoplastic lesions, thus depicting the importance of histopathology in the diagnosis of nasal polypoidal masses.

Follow-Up: All patients were followed up for 1 month to 6 months postoperatively. During this period no recurrences were found.

Discussions

Histopathology plays an important role in the diagnosis and management of patients presenting with polypoidal masses in the nose. In this study polyps and nasal polypoidal masses were sent for histopathological study and the diagnosis was confirmed. The study revealed the discrepancy between clinical diagnosis and histological diagnosis. Polypoidal masses in the nasal cavity from a complex group of lesions with a wide spectrum of histopathologic features.

The true nasal polyps are tumors like nonneoplastic polypoidal masses arising from nasal cavity and paranasal sinuses. Two types are encountered-one is associated with nasal allergy with numerous eosinophilic infiltration of the stroma on histopathology and the other is found in relation to chronic naso-sinusoidal infection termed the inflammatory polyp. In our study we have observed 13 cases (37.05%) of Inflammatory polyps. 3 cases (8.55%) of Fungal granulomas were diagnosed on histopathology.

About 90% of the true nasal polyps are stated to be allergic in origin as documented by large number of eosinophils-Openheimer 1979, Drake-Lee 1987, Anjali Dasgupta 1997. We also found majority of nasal polyps (25 cases, 17.25%) to be allergic origin (13 cases, 37.05%) on histopathological examination. They are more common in females. Angiofibroma was the most common benign neoplasm in the study (4 cases, 11.4%) males and Females were equally affected. They were more common in 2nd and 3rd decade. The other benign neoplastic lesion encountered was Squamous papilloma and inverted papilloma. Squamous papilloma was diagnosed in 40 year male as per the previous study by Markov et al. 1999.

The Malignant Neoplastic polypoidal lesion of nose and sinuses constitute an important and varied group. Often too, these lesions simulate the simple nasal polyps or chronic inflammatory diseases and thus delays in diagnosis. Carcinoma is by far the commonest malignant lesions (Anjali Dasgupta-1997; Diamantopoulos-2000). In our study we

encountered 1 case of malignancy, which was diagnosed as embryonal Rhabdomyosarcoma in 4 year old boy. Such malignancies of connective tissue origin are rare but can present as primary polypoidal neoplasm of nose and paranasal sinuses (Kohli, 1988). From our study it is evident that polypoidal masses in the nasal cavity and sinuses form a complex of lesions ranging from the Non-neoplastic inflammatory lesions to the benign and malignant neoplasm, with a spectrum of histopathological findings and affect all ages.

Conclusion

This is a prospective study of nasal polypoidal masses done during the period of two years from January 2000 to December 2001, at Gandhi Hospital, Hyderabad and Government ENT Hospital, Andhra Pradesh.

The polypoidal masses are common in 2nd and 3rd decade

There is a male preponderance.

Most common mode of presentation is nasal obstruction.

Among the nasal polypoidal masses, most common lesion is allergic polyp and inflammatory polyp.

Most of the polypoidal masses in the nose are benign in nature.

Other lesion which mimic nasal polyps were Fungal Granuloma, Angiofibroma, Squamous papilloma, Inverted papilloma and Embryonal Rhabdomyosarcoma.

Most of the patients were operated by polypectomy, three were operated by Moure's lateral rhinotomy approach and one was operated by Caldwell-Luc operation.

Postoperative complications were nil.

Recurrence was not noticed during the follow-up period.

In our study, the occurrence of Malignancy, Inverted papilloma or other clinically significant pathology among the group of patients with otherwise clinically unsuspected histology justifies sending all nasal polyps for routine histopathological examination

All nasal polypoidal masses should be sent for histopathology for conformation of diagnosis.

Acknowledgement: None

Conflict of interest: None

REFERENCE

- Kohli G.S. Histologic & Histochemical study of nasal polyp, Journal of Indian Medical Association, 1988; 29-31. |
- Anjali Das Gupta: Nasal Polyp-Histopathologic spectrum: Indian journal of Otolaryngology & Head and Neck Surgery, 1997; 9(1). |
- Diamantopoulos II, Jones NS, Lowe J: All nasal polyps need histological examination an audit based appraisal of clinical practice: J Laryngology & Otology 2000; 114(10):755-9. |
- Dandapath A. "Nasal polyp clinic histological study" India Journal of Otolaryngology and Head and Neck Surgery, 1993; 12(4):219-223. |
- Chaturvedi VN, Razda RM, Jain SK. A profile of malignant tumors of paranasal sinuses. Indian journal of Cancer, 1986; 23:14. |
- Markov D. Krajina Z. Poje G. Nasal polyps in children. Acta Medical Croatica, 1999; 53(2):97-9. |
- Chu PG, Chang KL, Wu AY, Weiss LM: Nasal glomus tumors: report of two cases with emphasis on immunohistochemical features and differential diagnosis. Human pathology, 1999; 30(10):1259-61. |