



DOI: 10.19187/abc.20174132-36

## Synchronous Idiopathic Granulomatosis Mastitis and Breast Cancer: A Case Report and Review of Literature

 Ahmad Kaviani<sup>a,b</sup>, Sanaz Zand<sup>a,b</sup>, Mojgan Karbakhsh<sup>c</sup>, Farid Azmoudeh Ardalan<sup>d</sup>
<sup>a</sup> Department of Surgery, Tehran University of Medical Sciences, Tehran, Iran

<sup>b</sup> Kaviani Breast Disease Institute, Tehran, Iran

<sup>c</sup> Department of Community and Preventive Medicine, Tehran University of Medical Sciences, Tehran, Iran

<sup>d</sup> Department of Pathology, Tehran University of Medical Sciences, Tehran, Iran

### ARTICLE INFO

**Received:**

13 February 2017

**Revised:**

19 February 2017

**Accepted:**

25 February 2017

**Keywords:**

 Breast cancer,  
 inflammatory disease,  
 idiopathic granulomatosis  
 mastitis (IGM)

### ABSTRACT

**Background:** Idiopathic granulomatous mastitis (IGM) is a rare benign breast disease, which can mimic breast cancer. As the managements of IGM and breast cancer are entirely different and the initial clinical manifestations are similar in several cases, it is very important to differentiate them.

**Case presentation:** We reported a 48-year-old female patient with IGM and breast cancer. She was referred to the outpatient clinic with bilateral large masses and clinical impression of bilateral breast cancer with inflammatory features in the right side. Through pathology, the diagnoses of invasive ductal carcinoma (IDC) for the left breast lesion and IGM for the right breast lesion were confirmed, respectively. Incisional biopsy was performed for the right breast lesion to rule out breast cancer and to make sure of the diagnosis of IGM.

**Conclusion:** To the best of our knowledge, breast cancer and IGM were reported only in two studies. Although IGM is not the underlying cause of breast malignancy, the diagnosis of breast cancer should always be kept in mind. Any other lesions in these patients should be assessed well to rule out breast cancer.

### Introduction

Idiopathic granulomatous mastitis (IGM) is a rare benign condition of the breast, which can mimic breast cancer.<sup>1</sup> The clinical presentation of IGM may range from a mass, thickening, nipple discharge, dimpling to nipple retraction and edema, which are usually accompanied by concurrent inflammatory signs, for instance, redness, peau d'orange, and skin edema. While the therapeutic options for the management of IGM are limited to medical therapy, mainly anti-inflammatory drugs, and no rule is found

for chemotherapy, hormonal therapy, and radiation therapy. Breast cancer is mostly managed by surgery and chemoradiotherapy as well as hormonal therapy. Thus, while the managements of these two diseases are quite different, the initial presentations are identical in most cases; therefore, it is of utmost importance to differentiate IGM from breast cancer.<sup>2</sup> In the present study, a patient with IGM was presented as she was diagnosed with breast cancer, too.

### Case Presentation

A 48-year-old female patient was referred to KBDI (Kaviani Breast Disease Institute) with the chief complains of bilateral large palpable masses in her both breasts and nipple retraction in her right breast during the last four months. She had no history of breast and ovarian cancer in her first and second degree relatives, and there were no important

### Address for correspondence:

Sanaz Zand, M. D.

Address: No 3, Tavaneer Sq., Kaviani Breast Disease Institute, Tehran, 1434888483, Iran

Tel: +98 21 88871785

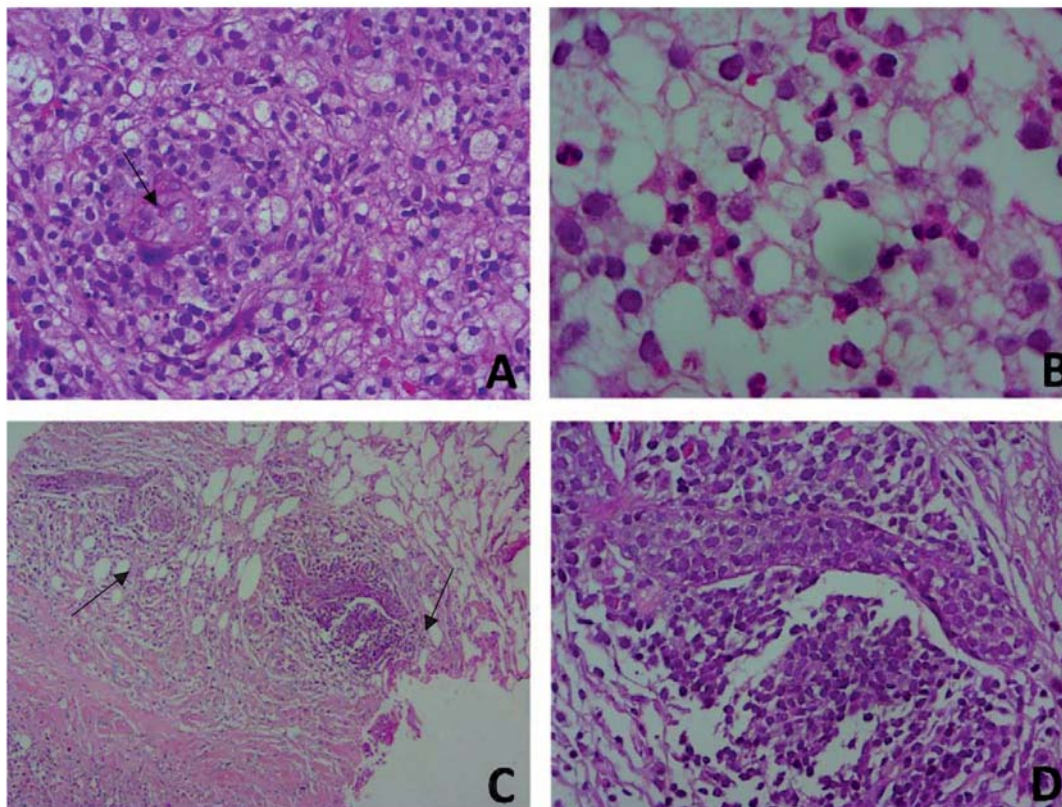
Fax: +98 21 88871698

Email: zand.sanaz1989@gmail.com



Through the physical examination, a 50-mm hard, ill-defined, and fixed-to-skin mass was palpated in her right breast with marked diffused edema, redness, peau d'orange, and nipple retraction in the central part of the same breast. In her contra-lateral breast, there was also a 35-mm hard, ill-defined movable mass in upper central part of the breast. Ultrasonography (US) revealed a large hypo-echoic mass with irregular borders and multiple echogenic foci and inflammatory changes, indicating mastitis, which had been spread between 7 o'clock to 11 o'clock as well as to the subareolar region in right breast. Likewise, right lymphadenopathy with cortical thickening with preserved fatty hilum (the largest lymph node 32\*11mm with 6mm cortical thickening) was reported in US. Moreover, a hypo-echoic speculated mass measuring 30\*50mm with foci of calcification and oval shape lymph node with compressed fatty hilum (16\*9mm) was observed in the left breast and axillary region. Mammography showed distortion and mass-like lesion in both breasts in the context of extremely dense breast; CNB was performed for both masses, and through pathology, the diagnosis of stromal fibrosis, ductal epithelial hyperplasia, and granulomatous inflammation with micro-abscess formation was confirmed for the right breast lesion (figure 1) and invasive ductal carcinoma with the presence of lobular cancerization in left breast mass.

(figure 2). The results of further bacterial (including mycobacterium tuberculosis, etc), and fungal cultures of right breast specimen were negative. Incisional biopsy was performed in the right breast lesion to confirm the diagnosis of IGM and to rule out of the malignancy in the right breast. Metastatic work-up including multi slice CT-scan of thorax , abdomen, pelvic and whole body bone scan were performed and there is no evidences of metastasis in other parts. After the reconfirmation of the diagnosis in open biopsy and based on multidisciplinary team discussion (MDT) recommendation, the treatment was started with neo-adjuvant chemotherapy (Adriamycin, Cyclophosphamide and Docetaxel regimen for 6 courses every 3 weeks). Two weeks after neo-adjuvant chemotherapy, no palpable masses were observed in neither of the breasts and only small thickening in upper central part of the left breast and in upper-medial part of the right breast without edema and peau d' orange were remained. (figure 3) Magnetic resonance imaging (MRI) results showed a single mass measured 20\*12mm without satellite lesions at the end of chemotherapy in left breast. A wire was placed under the guide of mammography to localize the small lesion in order to perform breast conservative therapy. (figure 4) Breast conserving surgery and oncoplastic repair (round block technique) and sentinel lymph node biopsy was performed on the



**Figure 1.** A) Right lesion with IGM Diagnosis. B) Granulomatous Formation. C) Neutrophils Inflammation ( $\times 10$ ). D) Inflammation ( $\times 40$ ).

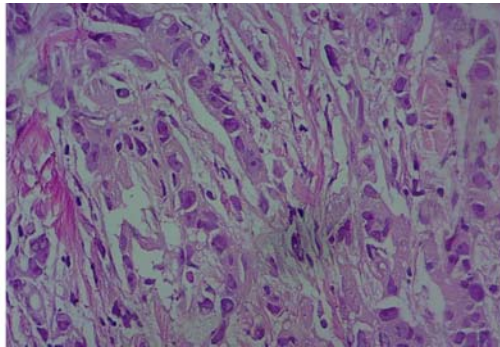


Figure 2. Left lesion – Invasive ductal carcinoma

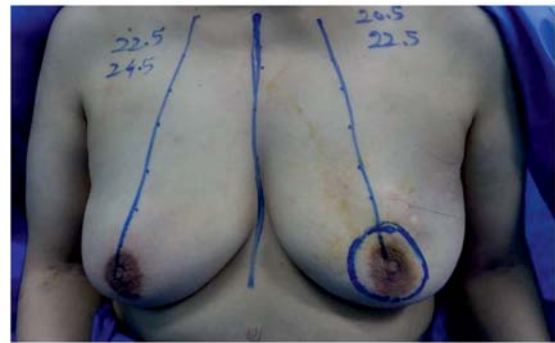

Figure 3. Patient before surgery with wire localization in left breast

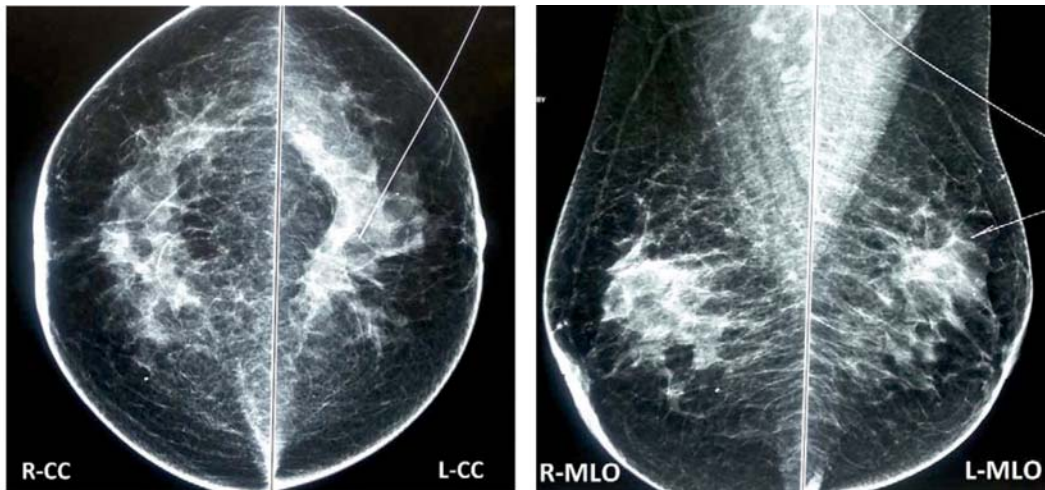


Figure 4. Mammography of both breasts with wire placed for localization of the lesion before surgery: Craniocaudal views (Left), Mediolateral views (Right)

left breast cancer. Pathology results reported the remnant of invasive ductal carcinoma. The treatment was pursued by the radiation therapy and hormonal therapy with Tamoxifen.

### Discussion

IGM was first recognized and described by Kessler and Wolloch in 1972 as a chronic, benign, and rare condition, being able to mimic a variety of inflammatory and malignant diseases of the breast.<sup>3</sup> Although the etiology and pathogenesis of IGM is not completely recognized, several studies have suggested that multiple factors might trigger IGM, including metabolic or hormonal alterations and imbalances (pregnancy, birth, breast-feeding, hyperprolactinemia, oral contraceptive pills,  $\alpha$ 1-antitrypsin deficiency, autoimmune reactions, direct response to trauma, granulomatous inflammation of the some other endocrine glands (e.g. thyroid), smoking, chemical irritation, and unknown microbiological agents).<sup>3-6</sup> The disease often occurs in reproductive ages, particularly in postpartum or breast-feeding periods.<sup>5,7</sup> The case presented in this study had no history of pregnancy and lactation within preceding 10 years; she had only taken oral contraceptives for a short period of time. The other risk factors were all negative in the patient.

The diagnosis of IGM in most of the patients is

challenging and it can be made based on clinical, radiological, and pathological features. Thus, the diagnosis is often accompanied by marked delay. Most of the patients are referred to breast clinics with painful and palpable breast masses, being usually ill-defined and firm. The symptoms often occur unilaterally and they are sometimes concomitant with inflammatory signs and symptoms, such as breast edema, breast erythema, peau d'orange, sinuses tracts, fistula formation, nipple retraction, skin changes, and skin hyperemia.<sup>4,6,7</sup> In most cases, the clinical presentation of IGM mimics breast cancer especially locally advanced or inflammatory breast cancer. Considering the patient presented in this study, the clinical presentation of the disease resembled bilateral breast cancer.

The radiological features of IGM are usually nonspecific and often mimic carcinoma.<sup>8</sup> Focal asymmetric density is the most common finding in mammography, which is similar to the findings of malignancies.<sup>9,10</sup>

The most common findings in ultrasound imaging are parenchymal heterogeneity, irregular hypoechoic mass, and abscess formation.<sup>11</sup> MRI cannot distinguish between IGM and inflammatory carcinoma in many patients.<sup>12</sup> The definitive diagnosis of IGM is determined by histological study.



The radiologic findings in the presented patient were, likewise, in favor of bilateral breast cancer. Nevertheless, to confirm the diagnosis and based on high clinical suspicion, incisional biopsy was performed from the same breast and the diagnosis of IGM was confirmed.

Histologically, IGM is characterized by non-necrotizing granuloma formation with a localized infiltrate of multi-nucleated giant cells and chronic inflammatory picture with epithelioid histiocytes, lymphocytes, plasma cells, and polymorph leukocytes.<sup>5,6</sup> Our patient had bilateral masses, the right-side mass with IGM diagnosis was large, fixed, and ill-defined mass with breast edema and peau d'orange that helped diagnosis clinically alike inflammatory breast cancer; however, in histopathology, it was reported as IGM.

The management of IGM is controversial and ranging from observation (50% of patients healing spontaneously), surgical treatment (wide local excision, incisional biopsy, drainage, mastectomy, etc.), to medical treatment (corticosteroids, Methotrexate, non-steroidal anti-inflammatory drug, immunosuppressive agent, such as Azathioprine, antibiotics, and more recently, rifampin).<sup>6,13-17</sup> We selected observation for the right breast and neo-adjuvant chemotherapy for the left breast cancer.

Importantly, malignancy and all other possible causes of mastitis must be excluded before making the diagnosis of IGM. Once diagnosed, the treatment is often difficult and needs patients' information about the natural history of the disease and takes considerable time. Considering the scientific evidence showing that more than 50 percent of IGM cases are misdiagnosed for breast cancer, histopathological examination should be used for definitive diagnosis.<sup>5,18</sup>

Considering the relationship of breast cancer and mastitis, a cohort study was conducted in Sweden can be mentioned. In this large-scale study, the assessment was performed on 8411 patients with sign and symptoms of mastitis. Among them, 106 women were diagnosed with breast cancer, subsequently. They found no association between breast cancer and inflammatory disease of the breast.<sup>19</sup> There existed no evidence, in which IGM or any other types of mastitis could be considered a risk factor for breast cancer.

To the best of our knowledge, only two studies reported breast cancer and IGM together. In 2013, Limaïem *et al.*<sup>20</sup> presented a case of a 77-year-old female with coexisting lobular granulomatous mastitis and ductal carcinoma in a single lesion. They concluded that it is possible for a patient to have two separate pathologies of breast carcinoma and inflammatory disease of breast simultaneously. They also suggested that dysplasia due to chronic inflammation can cause breast carcinoma. In the patient reported in our study, breast cancer and IGM

were revealed in two separate lesions in different breasts at same time.

In a study conducted by Mazlan *et al.* in 2012,<sup>21</sup> the authors reported a 34-year-old female who had recurrent episodes of IGM and breast abscess in her right breast for 8 years. She was treated by high-dose corticosteroid and antibiotics. Her disease was under good control in this period. Later, she was presented with the progressive loss of vision and, subsequently, the diagnosis of orbital tumor due to distant metastasis of an unknown primary tumor. Consequently, the biopsy of right breast showed infiltrating ductal carcinoma. The authors discussed the possibility of relationship between chronic granulomatous mastitis and malignancy as a risk factor. In our case, breast cancer appeared in contralateral breast in the same time.

In several studies, granulomatous mastitis was presented by multifocal or bilateral lesions.<sup>22,23</sup> When the main lesion is diagnosed as IGM, most of the surgeons consider all the lesions as IGM and do not proceed to have tissue diagnosis for each lesion. The results of the present report showed that it is possible for a patient with bilateral breast lesions to have breast cancer and IGM at the same time.

Although IGM is not the underlying cause of breast malignancy, based on the similar presentation at the first referral and in the follow up visits, the diagnosis of breast cancer should always be kept in mind. Any new lesions in these patients should be evaluated to rule out breast cancer at first and the treatment of IGM can be continued, thereafter.

### Conflict of interest

The authors have no conflict of interest in the content of this article.

### References

1. Ergin AB, Cristofanilli M, Daw H, Tahan G, Gong Y. Recurrent granulomatous mastitis mimicking inflammatory breast cancer. *BMJ Case Rep* 2011; 2011:
2. Lai EC, Chan WC, Ma TK, Tang AP, Poon CS, Leong HT. The role of conservative treatment in idiopathic granulomatous mastitis. *Breast J* 2005; 11(6): 454-6.
3. Kessler E, Wolloch Y. Granulomatous mastitis: a lesion clinically simulating carcinoma. *Am J Clin Pathol* 1972; 58(6): 642-6.
4. Altintoprak F, Kivilcim T, Ozkan OV. Aetiology of idiopathic granulomatous mastitis. *World J Clin Cases* 2014; 2(12): 852-8.
5. Fazio RT, Shah SS, Sandhu NP, Glazebrook KN. Idiopathic granulomatous mastitis: imaging update and review. *Insights Imaging* 2016; 7(4): 531-9.
6. Benson JR, Dumitru D. Idiopathic granulomatous mastitis: presentation, investigation and management. *Future Oncol*



- 2016; 12(11): 1381-94.
7. Pereira FA, Mudgil AV, Macias ES, Karsif K. Idiopathic granulomatous lobular mastitis. *Int J Dermatol* 2012; 51(2): 142-51.
  8. Sripathi S, Ayachit A, Bala A, Kadavigere R, Kumar S. Idiopathic granulomatous mastitis: a diagnostic dilemma for the breast radiologist. *Insights Imaging* 2016; 7(4): 523-9.
  9. Yilmaz E, Lebe B, Usal C, Balci P. Mammographic and sonographic findings in the diagnosis of idiopathic granulomatous mastitis. *Eur Radiol* 2001; 11(11): 2236-40.
  10. Memis A, Bilgen I, Ustun EE, Ozdemir N, Erhan Y, Kapkac M. Granulomatous mastitis: imaging findings with histopathologic correlation. *Clin Radiol* 2002; 57(11): 1001-6.
  11. Kiyak G, Dumlu EG, Kilinc I, Tokac M, Akbaba S, Gurer A, *et al.* Management of idiopathic granulomatous mastitis: dilemmas in diagnosis and treatment. *BMC Surg* 2014; 14: 66.
  12. Rieber A, Tomczak RJ, Mergo PJ, Wenzel V, Zeitler H, Brambs HJ. MRI of the breast in the differential diagnosis of mastitis versus inflammatory carcinoma and follow-up. *J Comput Assist Tomogr* 1997; 21(1): 128-32.
  13. Kaviani A, Noveiry BB, Jamei K, Rabbani A. How to manage idiopathic granulomatous mastitis: suggestion of an algorithm. *Breast J* 2014; 20(1): 110-2.
  14. Mizrakli T, Velidedeoglu M, Yemisen M, Mete B, Kilic F, Yilmaz H, *et al.* Corticosteroid treatment in the management of idiopathic granulomatous mastitis to avoid unnecessary surgery. *Surg Today* 2015; 45(4): 457-65.
  15. Gurleyik G, Aktekin A, Aker F, Karagulle H, Saglamc A. Medical and surgical treatment of idiopathic granulomatous lobular mastitis: a benign inflammatory disease mimicking invasive carcinoma. *J Breast Cancer* 2012; 15(1): 119-23.
  16. Farouk O, Abdelkhalek M, Abdallah A, Shata A, Senbel A, Attia E, *et al.* Rifampicin for Idiopathic Granulomatous Lobular Mastitis: A Promising Alternative for Treatment. *World J Surg* 2017:
  17. Sheybani F, Sarvghad M, Naderi HR, Gharib M. Treatment for and clinical characteristics of granulomatous mastitis. *Obstet Gynecol* 2015; 125(4): 801-7.
  18. Bani-Hani KE, Yaghan RJ, Matalka, II, Shatnawi NJ. Idiopathic granulomatous mastitis: time to avoid unnecessary mastectomies. *Breast J* 2004; 10(4): 318-22.
  19. Lambe M, Johansson AL, Altman D, Eloranta S. Mastitis and the risk of breast cancer. *Epidemiology* 2009; 20(5): 747-51.
  20. Limaiem F, Khadhar A, Hassan F, Bouraoui S, Lahmar A, Mzabi S. Coexistence of lobular granulomatous mastitis and ductal carcinoma: a fortuitous association? *Pathologica* 2013; 105(6): 357-60.
  21. Mazlan L, Suhaimi SN, Jasmin SJ, Latar NH, Adzman S, Muhammad R. Breast carcinoma occurring from chronic granulomatous mastitis. *Malays J Med Sci* 2012; 19(2): 82-5.
  22. Velidedeoglu M, Kilic F, Mete B, Yemisen M, Celik V, Gazioglu E, *et al.* Bilateral idiopathic granulomatous mastitis. *Asian J Surg* 2016; 39(1): 12-20.
  23. Choi SH, Jang KS, Chung MS. Bilateral granulomatous mastitis with a different etiology. *Cancer Biomark* 2015; 15(3): 333-8.