

**INTERCEPTIVE LESS INVASIVE KSHARSUTRA THERAPY IN  
TRANSPHINCTERIC FISTULA IN ANO****\*Dr. Praveen Kumar Choudhary**

Associate Professor, Department of Shalya Tantra A & U Tibbia College, Karol Bagh, New  
Delhi – 110005.

Article Received on  
4 Aug 2015,

Revised on 24 Aug 2015,  
Accepted on 13 Sep 2015

**\*Correspondence for****Author****Dr. Praveen Kumar  
Choudhary**

Associate Professor,  
Department of Shalya  
Tantra A & U Tibbia  
College, Karol Bagh, New  
Delhi – 110005.

[praveensurgeon9@gmail.com](mailto:praveensurgeon9@gmail.com)

**ABSTRACT**

Fistula in ano is a chronic granulation track opens deeply in anal canal or rectum and superficially on the peri-anal skin.<sup>[1]</sup> Park's classification of 1976 gives an accurate anatomical course of fistula in ano and he has classified fistula in 4 types such as intersphincteric, transphincteric, suprasphincteric and extrasphincteric.<sup>[2]</sup> In transphincteric fistula, the fistulous track opens up in to the peri-anal skin after passing through internal and external sphincters both. Usually these fistulae have long tracks even in low anal fistula. Ksharsutra has been emerging as a specialized treatment modality approved and standardized by Indian Council of Medical Research.<sup>[3]</sup> Ksharsutra is a medicated Seton and it is very good to treat high anal complex fistula.<sup>[4]</sup> Transphincteric fistula being a long track fistula causes extended morbidity both in case of surgery and ksharsutra therapy. In the present study, a method

was devised in which the fistula track was intercepted just outside the sphincter complex and the entire track was divided in to sub tracks. The inner track contained sphincters and the outer track contained skin and subcutaneous tissues. The 20 patients were randomly selected, 10 each in group A (control) and group B (treated) group. The group A was managed by conventional therapy and group B was managed by interceptive method. The morbidity and duration of treatment was significantly less in group B. The mean healing time in group B was significantly shorter than group A. It was concluded that the interceptive less invasive ksharsutra therapy is a better alternative of conventional ksharsutra therapy and morbidity, duration of treatment is less. The healing was faster with a fine scar.

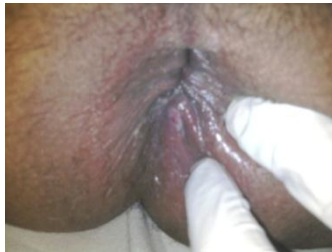**KEYWORDS:** Fistula in ano, Ksharsutra, Interceptive ksharsutra, Transphincteric fistula, Cryptoglandular infection, anal sphincters.

## INTRODUCTION

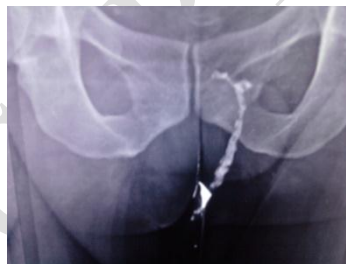Fistula in ano in majority of cases is crypto-glandular in origin.<sup>[5]</sup> Infection of anal glands leads to formation of pus which eventually travels to peri-anal spaces and finally bursts to give rise to fistula in ano. It is known as primary fistula. Around 10 percent of cases may be secondary to diseases such as tuberculosis, malignancies, trauma, surgeries, inflammatory bowel diseases, radiation etc.<sup>[6]</sup> Parks classified the fistula in ano in relation to the sphincters. He divided the fistula in ano in to 4 types

### *Intersphincteric fistula*

It lies between the external and internal sphincters. It may have low and high varieties.



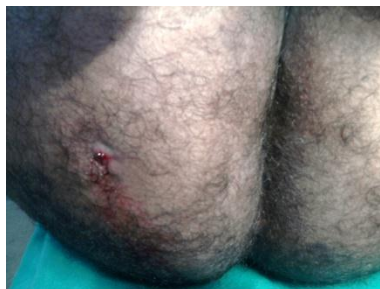*Fig. 1. Intersphincteric fistula post anal.*



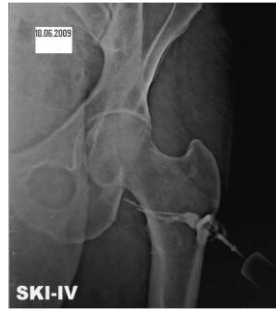*Fig. 2. Fistulogram of intersphincteric fistula.*

### *Transphincteric fistula*

In this variety of fistula, the track crosses both internal and external sphincter before opening in peri-anal skin.



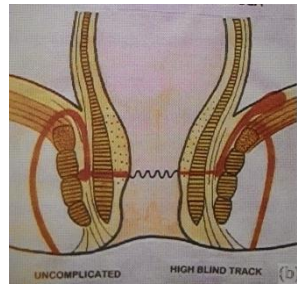
*Fig. 3. Transphincteric fistula with gluteal region opening.*



**Fig. 4** Fistulogram of transphincteric fistula.

### ***Suprasphincteric fistula***

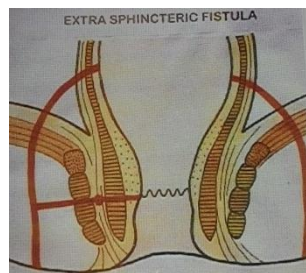
The fistula track passes upwards to puborectalis after crossing intersphincteric plane. It runs laterally over this muscle and downwards between puborectalis and the levator ani in to ischiorectal fossa involving entire sphincter.



**Fig. 5.** Suprasphincteric fistula.

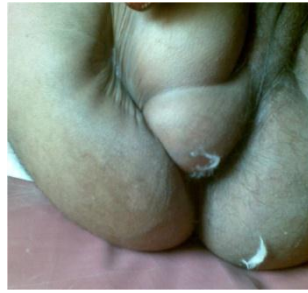### ***Extrasphincteric fistula***

These fistulae open in rectum remaining outside the sphincter complex.



**Fig. 6.** Extrasphincteric fistula in ano.

The treatment of transphincteric fistula is fistulotomy and fistulectomy. However, it carries many risks. The wound is extensive and on healing give bad scar. Moreover, there are fair chances of recurrence.



*Fig. 7. Extensive scar of surgery.*

Though the result of ksharsutra therapy has been excellent, yet there have been many problems associated with the therapy such as longer duration, discomfort in that duration, delayed healing etc.

To minimize these problems interceptive method was adopted.

#### **MATERIAL AND METHODS**

The clinical study was carried out on 20 patients in our hospital from February 2013 to May 2015. The patients were of age group between 25 to 40 years. Patients were divided in to two groups. The patients were allocated in each group one after one randomly. The first patient was allocated in group A and second one in group B and so on. Group A patients were subjected to conventional ksharsutra therapy in which ksharsutra was inserted from external opening to internal opening. Group B patients were subjected to interceptive method.

Inclusion criteria were transphincteric fistula, crypto-glandular infection or primary fistula. The diagnosis criteria were digital examination, bidigital palpation and a MRI examination. Exclusion criteria were fistulae other than transphincteric, secondary fistula or associated with other diseases (tuberculosis, IBD, malignancy etc.)

#### ***Preoperative procedures***

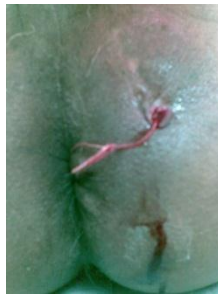The patients were subjected to full history taking, clinical examination, and a MRI examination to demonstrate the course of fistula track. All relevant laboratory investigations such as complete blood count, blood sugar, HIV, HBsAg and HCV were carried out.

#### ***Operative procedure***

Patient was laid down on operation table in lithotomy position. All procedures were carried out under saddle block anaesthesia.

***Group A patients – conventional ksharsutra therapy***

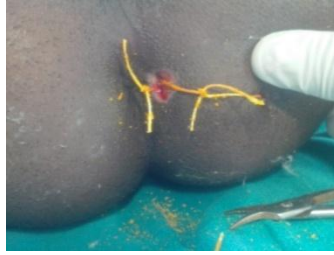After cleaning the peri-anal region, the part was draped. A malleable copper probe was inserted from external opening and guided towards the internal opening without any force. The gloved index finger of other hand is introduced in to the anal canal to feel the internal opening. The tip of the probe was forwarded along the path of least resistance and was guided by the finger inside to reach the lumen of anal canal through the internal opening. The tip of the probe was finally directed to come out of anal orifice. A suitable length of ksharsutra was threaded in to the eye of probe. After that the probe was pulled out through the anal orifice to leave the thread in the fistula track. The two ends of thread were then tied together with a moderate tightness outside anal canal. The wound was dressed.<sup>[7]</sup>



***Fig. 8. Conventional ksharsutra therapy in group A patients.***

***Group B patients – Interceptive ksharsutra therapy***

The patient was laid down after giving saddle block anaesthesia.<sup>[8]</sup> After cleaning and draping, the probing was performed in the same way. The probe was withdrawn from internal opening and finally outside the anal canal. While the probe was in situ, it was palpated just outside the sphincters of anal canal. An incision was given in peri-anal region to intercept the track. The incision was deepened to make a window. The track was isolated and incised. A mosquito forceps was inserted below the track to lift it. Ksharsutra was threaded in to the eye. The probe was gradually pulled through track and when eye came in incised portion the thread was held by the mosquito forceps. The probe was guided outside the anus in same way while pulling the thread in window. Thread was cut in window. Its two portions were tied, one towards anal canal and other away from anal canal. In that way the track was divided in to portions. The wound was dressed.



*Fig 9. Intercepting the fistula track.*

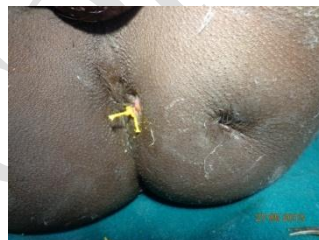#### *Post operative*

The patients were discharged the next day and advised sitz bath. Supportive treatment was advised and ksharsutra was changed at an interval of 7 days. The outer thread in group B patients was removed when wound became dried.

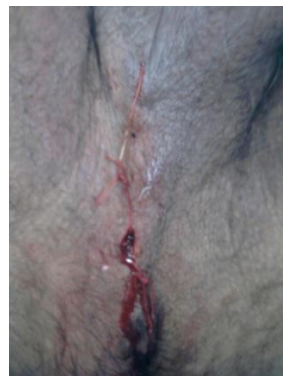#### **RESULTS**

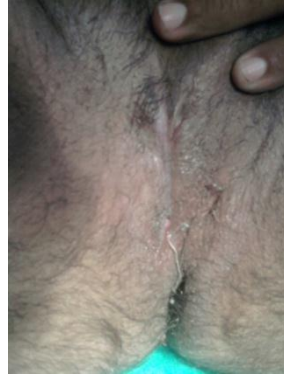The patients were evaluated on some clinical parameters such as duration of therapy, discharge, pain, wound, scar etc. The weekly assessment was recorded on a proforma.

Duration of therapy; hence, morbidity was significantly less in group B patients. The discharge was reduced very early in group B. Wound size was small and scar was significantly less in group B patients. Pain was also less in group B patients.



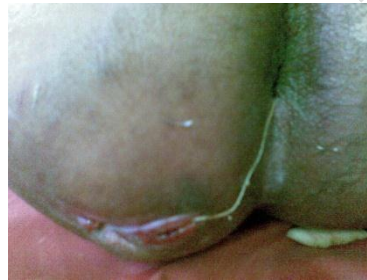*Fig. 10. Healing of the primary wound in interceptive technique.*



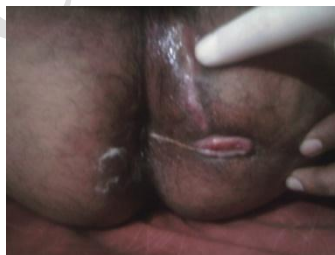

*Fig. 11. Early healing of peripheral wound in interceptive technique.*

Contrary to the interceptive therapy, conventional therapy was associated with morbidity, discharge, wound and large scar. There was need of wound toileting, nursing and modifying lifestyle. Granulation tissue formation was another disadvantage owing to large track.



*Fig. 12. Granulation and discharge from wound even after 3 months of conventional ksharsutra therapy.*



*Fig 13. Condition of wound after 3 months of conventional ksharsutra therapy.*

## DISCUSSION

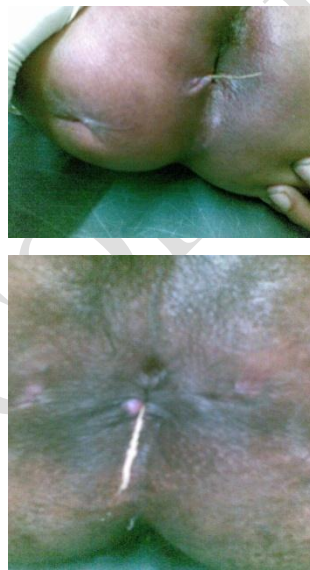Fistulotomy and Fistulectomy have been the treatment of choice for all varieties of fistula in ano.<sup>[9]</sup> Various other treatment modalities have been invented such as video assisted anal fistula treatment, mucous plug, LIFT etc. These treatment modalities cannot claim higher success rate of fistula cure. Ksharsutra, the Ayurvedic medicated Seton has gain popularity because of minimal recurrence rates after the treatment.<sup>[10]</sup> But the main difficulty in

ksharsutra treatment has been its longer duration and morbidity. In long track fistula in ano, the problem has been manifold.

To resolve this issue, it was decided to make the length of the track short and focus on root of infection rather than branches. It was decided to divide the track in two parts – the sphincter complex part and outer part. The track interception method was adopted. Results were encouraging. It was noticed that peripheral part of track became dry after a few sittings. It was boon for the patients.

I decided to carry out study in a particular age group of 25 to 40 years and crypto-glandular infection fistula excluding secondary fistula.

The duration of treatment, discharge, morbidity were significantly less in group B patients. There are a few illustration of interceptive approach.



*Fig. 14. Results of interceptive technique.*

## CONCLUSION

It is well established that ksharsutra is best treatment modality in fistula in ano among all treatment options. It has some problems in transsphincteric fistula in ano such as longer duration of treatment. This issue was taken up and resolved very well by using interceptive approach in fistula track. The results have been satisfactory. It is now the treatment of choice at our centre.



**REFERENCES**

1. Bailey and Love: Disease of rectum and anal canal, 1980.
2. Park A.G., Seitz R.W.: The treatment of fistula in ano, Diseases of colon, rectum, 1976; 19: 487-99.
3. Deshpande P.J. and Pathak S.N.: The treatment of fistula in ano with ksharsutra, Nagarjuna, Jan 1970; 361-367.
4. Chakradatta arshodhikar and Rasatarangini 24/527-30.
5. Mac Coll. I: The comparative anatomy and pathology of anal glands, Ann. R. Coll. Surg. Engl, 40: 36-37
6. Goligher J.C.: Surgery of the anus, rectum and colon, London 5<sup>th</sup> edition, 1984.
7. M. Sahu: A clinical study of Guggulu based ksharsutra in the management of fistula, procedure of primary threading, 1999.
8. Primary anaesthesia: Regional anaesthesia chapter 7.
9. S. Das Text book of Surgery, chapter on rectum and anus disorders.
10. Sharma B.N., Singh K.M., Deshpande P.J.: Concept of bhagandar and principles of its management, D.Ay.M thesis BHU, 1968.