AJRCMB Articles in Press. Published on 23-July-2015 as 10.1165/rcmb.2015-0165OC

Ozone-Induced Type 2 Immunity in Nasal Airways: Development and Lymphoid Cell Dependence in Mice

Chee Bing Ong[1], Kazuyoshi Kumagai[1], Phillip T. Brooks[2], Christina Brandenberger[1], Ryan P. Lewandowski[1], Daven N. Jackson-Humbles[1], Rance Nault[3], Timothy R. Zacharewski[3], James G. Wagner[1], and Jack R. Harkema[1]

[1]Department of Pathobiology and Diagnostic Investigation, Michigan State University (East Lansing, MI), [2]Comparative Medicine and Integrative Biology Program, Michigan State University, [3]Department of Biochemistry and Molecular Biology, Michigan State University

Authors' Contributions: Concept and design—J.R.H.; analysis and interpretation—C.B.O., K.K., P.T.B., C.B., R.P.L., D.N.J., R.N., T.R.Z., J.G.W., and J.R.H.; drafted the manuscript for important intellectual content—K.K. and J.R.H.; revised the manuscript and approved the final version to be published—C.B.O., K.K., P.T.B., C.B., R.P.L., D.N.J., R.N., T.R.Z., J.G.W., and J.R.H.

Corresponding Author: Jack R. Harkema, DVM, PhD, DACVP
University Distinguished Professor
Department of Pathobiology and Diagnostic Investigation
1129 Farm Lane, Room 212
Food Safety and Toxicology Building
Michigan State University
East Lansing, MI 48824

Copyright © 2015 by the American Thoracic Society

517-402-8627

E-mail address: harkemaj@msu.edu

Short Running Title: Ozone Causes Type 2 Immunity in Mouse Nasal Airway

Copyright © 2015 by the American Thoracic Society

AJRCMB Articles in Press. Published on 23-July-2015 as 10.1165/rcmb.2015-0165OC

Abstract

Inhalation exposures to ozone commonly encountered in photochemical smog, cause airway injury and inflammation. Elevated ambient ozone concentrations have been epidemiologically associated with nasal airway activation of neutrophils and eosinophils. In the present study, we elucidated the temporal onset and lymphoid cell dependency of eosinophilic rhinitis and associated epithelial changes in mice repeatedly exposed to ozone. Lymphoid-cell-sufficient, C57BL/6 mice were exposed to 0 or 0.5 ppm ozone for 1, 2, 4, or 9 consecutive weekdays (4 h/day). Lymphoid-cell-deficient, Rag2(-/-)Il2rg(-/-) mice were similarly exposed for 9 weekdays. Nasal tissues were taken at 2 h or 24 h post-exposure for morphometric and gene expression analyses. C57BL/6 mice exposed to ozone for 1 day had acute neutrophilic rhinitis with airway epithelial necrosis and overexpression of mucosal *Ccl2* (*MCP-1*), *Ccl11* (*eotaxin*), *Cxcl1* (*KC*), *Cxcl2* (*MIP-2*), *Hmox1*, *Il1b*, *Il5*, *Il6*, *Il13* and *Tnf* mRNA. In contrast, 9-day-ozone exposure elicited type 2 immune responses in C57BL/6 mice with mucosal mRNA overexpression of *Arg1*, *Ccl8* (*MCP-2*), *Ccl11*, *Chil4* (*Ym2*), *Clca1* (*Gob5*), *Il5*, *Il10*, and *Il13*, increased density of mucosal eosinophils, and nasal epithelial remodeling (e.g., hyperplasia/hypertrophy, mucous cell metaplasia, hyalinosis, and increased YM1/YM2 proteins). Rag2(-/-)Il2rg(-/-) mice exposed to ozone for 9 days, however, had no nasal pathology or overexpression of transcripts related to type 2 immunity. These results provide a plausible paradigm for the activation of eosinophilic inflammation and type 2 immunity found in the nasal airways of nonatopic individuals subjected to episodic exposures to high ambient ozone.

Key Words: Ozone, rhinitis, type 2 immunity, mice

Copyright © 2015 by the American Thoracic Society

Introduction

Ozone (O_3) is a common secondary air pollutant that is formed in the troposphere through the photochemical interaction of nitrogen oxides, volatile organic compounds, and sunlight. Exposures to elevated ambient concentrations of this gaseous oxidant pollutant are associated with increases in both human morbidity and mortality (1, 2), respiratory health effects that include impairment of pulmonary function (3, 4) and exacerbations of chronic respiratory diseases, such as asthma and allergic rhinitis (5, 6). Lim et al. (7) have estimated that approximately 2.5 million disability-adjusted life years were attributable to ambient ozone exposure alone in 2010 worldwide. Unfortunately with predicted future climate changes, ambient ozone concentrations will likely increase rather than decline, resulting in more exposure-related health effects (8, 9).

High levels of ozone also cause airway epithelial injury and inflammation in the upper and lower respiratory tract of laboratory animals (10-14) and human subjects (15-20). The magnitude of ozone-induced airway epithelial injury (e.g., cell necrosis and loss of airway cilia) and acute inflammation (e.g., influx of neutrophils) are exposure- (concentration, duration, frequency) and species-dependent. For example, it takes approximately 4 to 5 times the concentration of ozone to induce pulmonary inflammation in rodents that is equivalent to that documented in exercising human subjects under similar controlled exposure conditions (21).

Long-term ozone exposures cause marked remodeling of the airway epithelium lining nasal and pulmonary airways in rats (22-24) and nonhuman primates (10, 11). Remodeling of nasal airway epithelium is characterized by hyperplasia/hypertrophy and mucous cell metaplasia, and is most

Copyright © 2015 by the American Thoracic Society

AJRCMB Articles in Press. Published on 23-July-2015 as 10.1165/rcmb.2015-0165OC

severe in the proximal portions of the nasal passages. At these intranasal locations, the airways are normally lined by pseudostratified epithelium that contains sparse numbers of ciliated cells and goblet cells, and is principally composed of non-ciliated, cuboidal and basal cells (i.e., nasal transitional epithelium) (25).

Rapidly after ozone-induced injury of nasal epithelium, there is an acute influx of neutrophils in the nasal mucosa of rats (14, 26), nonhuman primates (27, 28), and human subjects (19, 29). Elevated levels of neutrophil chemotactic factors, such as chemokine (C-X-C motif) ligand (CXCL) 8 (alternatively known as IL-8) in humans (30) and CXCL2 (also known as macrophage inflammatory protein 2 or MIP-2) in mice (31) are also measured in airway lining fluid after acute ozone exposures. On the other hand, the nasal inflammatory cell and cytokine responses to more long-term exposures (e.g., repeated daily exposures for weeks or months) have not been thoroughly characterized. Interestingly, epidemiological studies have reported associations of elevated ambient ozone concentrations with increases in eosinophil-derived proteins in nasal lavage or urine of atopic and nonatopic children, supporting the hypothesis that elevated ambient ozone exposures may be directly associated with eosinophilic inflammation in the airways (32-35).

To further elucidate granulocyte responses to repeated daily exposures to ozone, we designed the present study to examine the nasal airways of mice that received daily ozone exposures for 1, 2, 4, or 9 consecutive weekdays. We report the quantitative pathology that occurs in nasal airways with increasing daily exposures to ozone, along with exposure-related mRNA expression changes in nasal mucosa (Study 1). We found that mice repeatedly exposed to ozone develop

Copyright © 2015 by the American Thoracic Society

type 2 immune responses in their nasal airways without any previous or concurrent inhalation exposures to an aeroallergen. Based on our initial findings, we further explored the role of lymphoid cells in the development of eosinophilic rhinitis and nasal epithelial remodeling (Study 2). We further found that the nasal lesions caused by 9 days of ozone exposure were lymphoid cell dependent.

Materials and Methods

Animals. Male C57BL/6 mice (6–8 weeks of age; 12 mice/group; Charles River Laboratories, Portage, MI) were used to determine the development of ozone-induced rhinitis over 9 days of exposure (Study 1). Male C57BL/6 and Rag2(-/-)Il2rg(-/-) mice (8 weeks of age; 12 mice/group; Taconic, Hudson, NY) were used to determine the lymphoid cell dependency of ozone-induced nasal lesions after 9 days of exposure (Study 2).

Inhalation Exposures. After an acclimatization period for one week, mice were exposed to filtered air (air controls) or 0.5 ppm ozone in the whole-body ozone chambers for 1, 2, 4 or 9 consecutive weekdays (4 h/day, 5 days/week, n = 12/group). Ozone was generated with an OREC Model O3VI-O ozonizer (Ozone Research and Equipment Corp., Phoenix, AZ). The chamber ozone concentration was monitored throughout the exposure with Dasibi 1003 AH ozone monitors (Dasibi Environment Corp., Glendale, CA).

Histopathology. Heads from mice designated for histopathology (n = 6/group) were collected 2 h or 24 h after the single exposure or 24 h after the end of exposure. After fixation and decalcification, the nasal cavity was sectioned at T1–T4 (Figure E1) (25). Paraffin sections were stained with Alcian Blue (pH 2.5)/Periodic Acid Schiff (AB/PAS) as well as hematoxylin and

Copyright © 2015 by the American Thoracic Society

AJRCMB Articles in Press. Published on 23-July-2015 as 10.1165/rcmb.2015-0165OC

eosin (H&E). Sections were immunostained with antibodies specific for major basic protein (MBP) (clone MT-14.7, Mayo Clinic, Scottsdale, AZ) to identify eosinophils, Ly-6B.2 alloantigen (clone 7/4, AbD Serotec, Raleigh, NC) to identify neutrophils, and chitinase-like 3 (CHIL3 or YM1)/chitinase-like 4 (CHIL4 or YM2) (kindly provided from Dr. Shioko Kimura of National Cancer Institute, Bethesda, MD) (36).

Nasal Morphometry. Tissue sections were digitized with a slide scanner (VS110, Olympus America, Center Valley, PA). The nasal mucosa lining the lateral wall in T1 was evaluated via morphometric methods using the newCAST software (VisioPharm, Hoersholm, Denmark). Morphometric methods were used to measure the density of neutrophils and eosinophils in the nasal mucosa, thickness and epithelial cell density of nasal airway epithelium, and intraepithelial density of mucosubstances and YM1/YM2 proteins.

Quantitative Real-time Polymerase Chain Reaction (RT-PCR). The nasal cavities from mice designated for gene expression analysis (n = 6/group) were immersed in RNAlater (SigmaAldrich, St.Louis, MO) at the time of necropsy and stored in the solution at -20ºC until further processing. Nasal mucosa lining the nasoturbinates, maxilloturbinates, and lateral walls from the proximal aspects between T1 and T2 were excised. Total RNA isolation and cDNA synthesis were performed as described previously (37). Quantitative RT-PCR was performed using ABI PRISM 7900 HT Sequence Detection using Taqman Gene Expression Assay reagents (Applied Biosystems, Foster City, CA). The data were relatively quantified using the ΔΔCT method normalized to *Rn18s*, *Gapdh*, and *Actb*.

Copyright © 2015 by the American Thoracic Society

Statistical Analysis. A Grubbs outlier test was performed on morphometric data. Two group comparisons were performed by a Student's or Welch's t-test. Multiple comparisons were performed using a one-way analysis of variance (ANOVA) followed by a Dunnett's test, or a one-way ANOVA on ranks followed by a Dunn's test. Significance was assigned to p values ≤ 0.05.

Results

Study 1. Nasal Inflammatory and Epithelial Lesions over 9 Days of Ozone Exposure. Mice exposed to ozone had nasal histopathology that was restricted to the mucosa lining the lateral meatus in the proximal portion of each nasal passage (T1 section; Figure E1). The morphologic character of ozone-induced lesions changed over the course of the 9 days of exposure (Figures 1 and 2). Two h after a single exposure to ozone, there was a strong influx of neutrophils in the lamina propria of the nasal mucosa (Figure 1). There were focal areas of vacuolar degeneration, necrosis and exfoliation of predominantly widely scattered ciliated cells in the nasal transitional epithelium lining the proximal lateral wall and lateral surfaces of the naso- and maxillo-turbinates.

By 24 h after the single day of ozone exposure, neutrophilic influx had attenuated along with the degenerative and necrotizing epithelial lesions. After 2 and 4 days of ozone exposure, the neutrophilic infiltration had waned considerably with the mucosal density of neutrophils being statistically similar to that of air control mice (Figure 1). The nasal transitional epithelium of mice exposed to ozone for 2 or 4 days contained few, if any, degenerating or necrotic epithelial cells and was characterized by a thin, more basophilic, reparative epithelium (Figure 1).

Copyright © 2015 by the American Thoracic Society

AJRCMB Articles in Press. Published on 23-July-2015 as 10.1165/rcmb.2015-0165OC

After 9 days exposure to ozone, mice had a marked inflammatory cell influx composed predominantly of eosinophils (Figure 1). Approximately 6% of the nasal mucosa lining the lateral wall in 9-day ozone exposed mice was infiltrated with eosinophils, compared to less than 1 % in air control (Figure 1). With this longer ozone exposure, the nasal epithelium was also thicker (Figure 1) due to hyperplasia and hypertrophy of epithelial cells (conspicuously more and larger apical cells, as well as more basal cells). Eosinophilic, hyaline globules were also conspicuous in the cytoplasm of some of the nonciliated cells (i.e., epithelial hyalinosis).

Few to no AB/PAS-positive mucous cells were present in mice exposed to filtered air or ozone for only 1, 2 or 4 days (Figure 2). Thickened nasal epithelium in mice exposed to ozone for 9 days contained increased numbers of AB/PAS-stained mucous cells (i.e., mucous cell metaplasia) with a significant increase in the density of intraepithelial mucosubstances, as compared to air control (Figure 2).

YM1/YM2 proteins in the nasal epithelium of air control mice were minimal and limited to the apical surface of ciliated cells (Figure 2). In contrast, there was marked YM1/YM2 proteins throughout the hyperplastic/hypertrophic nasal transitional epithelium of 9-day ozone exposed mice (Figure 2). YM1/YM2 proteins were cytoplasmically located in both apical and basal epithelial cells (ciliated and nonciliated) and larger amounts were associated with the hyaline globules. Morphometrically, there was markedly more intraepithelial YM1/YM2 in 9-day ozone exposed mice compared to air control (Figure 2).

Study 1. Ozone-induced Changes in Nasal mRNA Expression over 9 Days of Exposure.

Copyright © 2015 by the American Thoracic Society

Fold increases of nasal mucosal mRNA in ozone-exposed mice relative to air-exposed mice changed dramatically with increasing days of ozone exposure (Figure 3 and Table E1). Two h after ozone exposure there were statistically significant increases in mRNA expression of *chemokine* (*C-C motif*) *ligand* 2 (*Ccl2*), *Cxcl1*, *Cxcl2*, *heme oxygenase 1* (*Hmox1*), *Il1b*, *Il6*, and *tumor necrosis factor* (*Tnf*). In addition, *Il1b* and *Cxcl2* mRNA was overexpressed 24 h after 1 day exposure of ozone and 24 h after 1 day and 2 days exposure of ozone, respectively.

Over-expression of these acute inflammatory transcripts was, however, lost with repeated ozone exposures.

In contrast, 9 days of exposure to ozone caused a marked overexpression of another cluster of transcripts including *arginase 1* (*Arg1*), *Ccl8*, *Ccl11*, *Chil4*, *chloride channel calcium activated 1* (*Clca1*), *Il5*, *Il10*, and *Il13*, respectively. Significant overexpression, but at lower relative fold increases of mRNA, was also found 24 h after 2 and 4 days of exposure for *Arg1* and *Ccl8,* and 1, 2, and 4 days of exposure for *Chil4* and *Clca1*. Interestingly, we found significant mRNA overexpression for *Il5 and Il13* at all examined time points after exposure (i.e., 2 and 24 h after 1 day of exposure and 24 h after 1, 2 and 4 days of exposure). A significant overexpression of *mucin 5*, *subtypes A and C*, *tracheobronchial/gastric* (*Muc5ac*) transcript was also detected 24 h after 1 day of ozone exposure.

Study 2. No Ozone-induced Nasal Lesions in Lymphoid Cell-deficient Mice after 9 Days of Exposure.

We further explored the role of lymphoid cells in the pathogenesis of ozone-induced eosinophilic rhinitis and nasal epithelial remodelling in C57BL/6 and Rag2(-/-)Il2rg(-/-) mice after 9 days of

Copyright © 2015 by the American Thoracic Society

AJRCMB Articles in Press. Published on 23-July-2015 as 10.1165/rcmb.2015-0165OC

ozone exposure. The nasal lesions in C57BL/6 mice exposed to ozone for 9 days were comparable to those in Study 1 (Figures 1 and 4). These mice also had significantly greater total epithelial cell densities (i.e., epithelial nuclear profiles per length of basal lamina) as compared to their respective air-exposed control mice. In contrast, ozone-exposed Rag2(-/-)Il2rg(-/-) mice had no nasal inflammatory or epithelial lesions (Figure 4).

Study 2: No Ozone-induced Changes in Nasal mRNA Expression of Lymphoid Cell-deficient Mice after 9 Days of Exposure.

Marked overexpression of these transcripts related to tissue recruitment and persistence of eosinophils (*Ccl11, Il5*), mucous cell metaplasia (*Il13, Muc5ac*) and mucus hypersecretion (*Clca1*) were found in the nasal mucosa of the C57BL/6 mice after 9 days of ozone exposure (Figure 5). Conversely, no relative fold increases in these transcripts were found in the Rag2(-/-)Il2rg(-/-) mice exposed to ozone. Likewise, relative fold increases of mRNA for *Arg1*, *Ccl8*, *Chil4*, *Il10*, and *Muc5b* were present in the nasal mucosa of ozone-exposed C57BL/6 mice, but not in ozone-exposed Rag2(-/-)Il2rg(-/-) mice (Table E2).

Discussion

The principal focus of the present study was to better understand the inflammatory cell and cytokine responses to repeated exposures to ozone in the nasal airways of mice. In this regard, two novel findings were uncovered. The first finding was that ozone-induced nasal inflammation switches from a predominantly neutrophilic to an eosinophilic rhinitis with increasing days of exposure. The onset of eosinophilic rhinitis after 9 days of ozone exposure was associated with epithelial remodeling that was characterized by hyperplasia/hypertrophy,

Copyright © 2015 by the American Thoracic Society

mucous cell metaplasia, hyalinosis and cytoplasmic expression of YM1/YM2. These later inflammatory and epithelial responses to continued daily exposure were preceded by, or concomitant with, an overexpression of type 2 cytokine mRNA (e.g., *Il5, Il13*) and other transcripts associated with airway mucus hypersecretion and mucous cell metaplasia (i.e., *Clca1, Muc5ac*), and YM2 protein production (i.e., *Chil4*). Our second major finding was that both nasal inflammatory and epithelial lesions after 9 days of ozone exposure were lymphoid cell dependent.

Eosinophilic rhinitis is more commonly associated with nasal allergy that affects 15–30% of patients in the United States (38). Allergic rhinitis is initiated by IgE-mediated reactions to inhaled allergens (aeroallergens), like house dust mite antigen, and has a type 2 cytokine profile (39). Though ozone is not considered an aeroallergen, exposure to this irritating gaseous air pollutant has been reported to exacerbate or trigger pre-existing allergic airway diseases such as allergic rhinitis and asthma in laboratory animals (40-42) and humans (43, 44). In the current study, we similarly found that ozone-exposed mice, without pre-existing allergic airway disease, develop eosinophilic inflammation in the nasal airways after repeated daily exposure. This provides for the first time an experimental animal model to further elucidate the underlying mechanisms and potential therapeutic interventions for ozone-induced eosinophil airway inflammation in humans.

Recent studies have suggested new roles for eosinophils in both health and disease, which include a modulating role in tissue remodeling and in the resolution of acute neutrophilic inflammation (45). For example, Jacobsen et al. (46), by using eosinophil-deficient mice, have

Copyright © 2015 by the American Thoracic Society

AJRCMB Articles in Press. Published on 23-July-2015 as 10.1165/rcmb.2015-0165OC

shown that eosinophils are instrumental in blocking allergen-induced recruitment and accumulation of airway neutrophils. They also found that with eosinophil deficiency there was a marked attenuation or loss of allergen-induced increases in type 2 cytokines (e.g., IL-5, IL-13), T cells, and airway mucous cell metaplasia in the lungs. Together these findings demonstrated important eosinophil-dependent immunoregulatory mechanisms in allergic airway disease in mice. In the present study, we observed that the influx of eosinophils in mice coincided with nasal epithelial remodeling, overexpression of type 2 cytokine mRNA, and the resolution of neutrophilic inflammation. Our study, however, was not designed to elucidate the role of eosinophils in the development of other nasal responses to ozone. Future studies will have to be conducted to determine if eosinophils play similar modulating roles in ozone-induced rhinitis as it does in allergen-induced rhinitis or asthma.

We did, however, explore the role of lymphoid cells in the development of ozone-induced eosinophilic rhinitis by comparing the nasal pathology after 9 days of ozone exposure in C57BL/6 mice and Rag2(-/-)Il2rg(-/-) mice. Rag2(-/-)Il2rg(-/-) mice are consequently devoid of all lymphoid cells (i.e., T cells, B cells, and innate lymphoid cells) (47-49). Overexpression of type 2 cytokines and chemokines, eosinophilic infiltration, and epithelial remodelling were completely absent in the nasal mucosa of ozone-exposed Rag2(-/-)Il2rg(-/-) mice. The lack of response in the lymphoid cell depleted mice is most likely due to the absence of cytokine/chemokine responses such as IL-5 and CCL11 and may emanate from Th2 cells or type 2 innate lymphoid cells (ILC2s) (50). It is less likely to be due to a deficiency of eosinophils in Rag2(-/-)Il2rg(-/-) mice, since microscopically the bone marrow in the skull of mice was replete with MBP-positive eosinophils, like that in C57BL/6 mice (Figure E2).

Copyright © 2015 by the American Thoracic Society

Our laboratory has previously reported that mucous cell metaplasia is a prominent cellular change in the nasal transitional epithelium of nonhuman primates (10) and rats (26) after repeated daily exposures to concentrations of ozone, ranging from as low as 0.15 ppm in nonhuman primates and 0.5 ppm in rats. In these species, the histochemically detected onset of mucous cell metaplasia was as early as 4–6 days after the start of the repeated exposures. In rats, increased expression of the mucin gene, *Muc5ac,* was detected in nasal mucosa as early as 24 h after a single 8 h exposure. C57BL/6 mice in the present study had a similar early onset of overexpression for airway mucus-associated genes and mucous cell metaplasia after daily exposures to 0.5 ppm ozone after 1 day or 9 days, respectively. We also found that Rag2(-/-)Il2rg(-/-) mice exposed to ozone clearly lacked mucous cell metaplasia and overexpression of *Clca1* and *Il13* mRNA. IL-13, which can emanate from Th2 cells and ILC2s, has also been shown to induce CLCA1 that mediates mucous cell metaplasia in the pulmonary conducting airways of mice sensitized and challenged with allergen (51). The lack of Th2 cells or ILC2s in the Rag2(-/-)Il2rg(-/-) mice may be responsible for the lack of mucous cell metaplasia in these mice repeatedly exposed to ozone for 9 days.

The current study was also not designed to identify which lymphoid cell type(s) plays a role in ozone-induced development of eosinophilic rhinitis and nasal epithelial remodeling. Since we observed a strong correlation among mRNA overexpression of type 2 cytokines and epithelial factors (e.g., *Clca1*, *Ym2*) and nasal histopathology after the 9 days of ozone exposure, it is likely that Th2 lymphocytes and/or ILC2s, both known to secrete IL-5 and IL-13, play major roles in the pathogenesis of these nasal lesions. The early overexpression of transcripts for *Il5* and *Il13*

Copyright © 2015 by the American Thoracic Society

AJRCMB Articles in Press. Published on 23-July-2015 as 10.1165/rcmb.2015-0165OC

in the nasal mucosa after ozone exposure suggests that ILC2s may play a critical role in this toxicant-induced nasal pathology.

It was interesting, that by light microscopy, lymphocytes (as well as other mononuclear leukocytes) were sparsely seen among the numerous granulocytic neutrophils and eosinophils in the affected nasal mucosa of ozone-exposed C57BL/6 mice, at 1 and 9 days of exposure, respectively. However, prominent focal aggregates of nasal associated lymphoid tissue (NALT) were bilaterally located in the ventral walls at the opening of the nasopharyngeal duct, located in the T3 nasal sections of all C57BL/6 mice. NALT is a normal feature in rodent nasal passages and thought to have an important immune function in regional immune defence of upper airways (25). As expected NALT was absent in the lymphoid cell-depleted Rag2(-/-)Il2rg(-/-) mice (Figure E2).

Unfortunately routine immunohistochemical techniques, using antibodies specific for murine ILC2s (or Th2 lymphocytes), are not yet available for microscopic identification of these lymphoid cells in the nasal mucosa, or any other airway tissues, of this mouse strain. Therefore we were not able to microscopically identify the intranasal location of these cells, and this was a limitation of the present study. Studies are underway, however, to develop a method for identifying ILC2s from distinct locations in the mouse nasal airways using microdissection of mucosal tissue and flow cytometry. This approach has been developed successfully for murine lung tissue and tissues from other organs in the mouse (52), but it has not yet been successfully applied to murine nasal tissue to the best of our knowledge.

Copyright © 2015 by the American Thoracic Society

Hyperplasia (elevated total epithelial cell density) of nasal transitional epithelium, along with mucous cell metaplasia, was a consistent finding in the C57BL/6 mice that received repeated daily exposure to ozone for 9 days. These epithelial lesions were absent in the ozone-exposed Rag2(-/-)Il2rg(-/-) mice. Recent reports in the literature indicate that similar appearing hyperplastic and metaplastic airway epithelium in virus-infected lungs of mice contain unique IL-33 expressing progenitor basal cells that appear to play a novel role in the induction of type 2 immune responses, such as IL-13-dependent mucous cell metaplasia (53). Though still speculative, we cannot rule out the possibility that the ozone-induced nasal epithelium observed in our study may also contain similar IL33 overexpressing progenitor cells that orchestrate type 2 immune responses. Studies are ongoing in our laboratory to immunohistochemically detect IL-33, and other epithelial *alarmin* cytokines (TSLP and IL-25), that are known to initiate ILC2-driven types in the nasal epithelium of mice.

Another conspicuous ozone-induced pathologic feature in C57BL/6 mice, that was absent in Rag2(-/-)Il2rg(-/-) mice, was epithelial hyalinosis, enhanced expression of intraepithelial YM1/YM2 proteins, and *Ym2* mRNA in the nasal mucosa. YM1 and YM2 are chitinase-like proteins that are specific to rodents. Accumulations of YM1/YM2 proteins have been previously reported in nasal olfactory epithelium of mice during regeneration and aging (54), and the overexpression of *Ym1* and *Ym2* has been found in the lungs of mice instilled with diesel exhaust particles (55). Though the biological functions for these unique proteins are not fully elucidated, they are often associated with type 2 immunity, eosinophilic inflammation and tissue remodeling, and preferentially expressed in the epithelium lining proximal airways and alveolar macrophages of mice with allergic airway disease (56). YM1/YM2 proteins have been found to

Copyright © 2015 by the American Thoracic Society

AJRCMB Articles in Press. Published on 23-July-2015 as 10.1165/rcmb.2015-0165OC

be expressed in an IL-13-dependent manner and to enhance secretion of this type 2 cytokine as well as IL-5 (57). Conversely, an in vitro assay using purified protein has demonstrated that YM1/YM2 proteins have little chemotactic activity for eosinophils (58). Therefore, YM1/YM2 proteins might be involved in eosinophilic rhinitis induced by ozone exposure via up regulation of type 2 cytokine production.

In conclusion, the results of this toxicology study in mice indicate that acute exposure to ozone (for 1 or 2days) cause nasal epithelial injury resulting in cell death and neutrophilic rhinitis, while repeated daily exposures to ozone (for 9 days) result in eosinophilic rhinitis and epithelial remodeling that are lymphoid cell dependent. These findings identify a new host response to this commonly encountered oxidant air pollutant, and suggests a novel pathogenic pathway for nasal eosinophilic inflammation that has been found in susceptible human populations living in air-polluted environments (e.g., atopic and nonatopic children living in communities with photochemical smog). The nasal epithelial pathology and mucosal type 2 immunity that we observed in mice after repeated ozone are similar to key allergic host responses observed in children and adults who suffer from eosinophilic rhinitis caused by common aeroallergens (e.g., house dust mite, ragweed pollen), suggesting that long-term ozone exposure, by itself, could cause not only exacerbation of pre-existing allergic rhinitis, but also the development (early onset) of this chronic upper airway disease.

Acknowledgements:

The authors thank Ms. Amy Porter and Ms. Kathy Joseph of the Michigan State University Histopathology Laboratory for their preparation of the histology slides. Special thanks to Dr.

Copyright © 2015 by the American Thoracic Society

Steve Van Dyken at the University of California, San Francisco, Medical Center for his helpful suggestions in the experimental design of this study. This research was supported with funds from the U.S. Environmental Protection Agency's Clean Air Research Center grant RD 83479701.

Conflict of Interest:

The authors declare that they have no conflict of interest.

Copyright © 2015 by the American Thoracic Society

AJRCMB Articles in Press. Published on 23-July-2015 as 10.1165/rcmb.2015-0165OC

References

1. Jerrett M, Burnett RT, Pope CA, 3rd, Ito K, Thurston G, Krewski D, Shi Y, Calle E, Thun M. Long-term ozone exposure and mortality. *N Engl J Med* 2009;360(11):1085-1095.
2. Bell ML, McDermott A, Zeger SL, Samet JM, Dominici F. Ozone and short-term mortality in 95 US urban communities, 1987-2000. *JAMA* 2004;292(19):2372-2378.
3. Brown JS, Bateson TF, McDonnell WF. Effects of exposure to 0.06 ppm ozone on FEV1 in humans: a secondary analysis of existing data. *Environ Health Perspect* 2008;116(8):1023-1026.
4. Kahle JJ, Neas LM, Devlin RB, Case MW, Schmitt MT, Madden MC, Diaz-Sanchez D. Interaction effects of temperature and ozone on lung function and markers of systemic inflammation, coagulation, and fibrinolysis: A crossover study of healthy young volunteers. *Environ Health Perspect* 2015;123(4):310-316.
5. Peden DB. Effect of pollutants in rhinitis. *Curr Allergy Asthma Rep* 2001;1(3):242-246.
6. Guarnieri M, Balmes JR. Outdoor air pollution and asthma. *Lancet* 2014;383(9928):1581-1592.
7. Lim SS, Vos T, Flaxman AD, Danaei G, Shibuya K, Adair-Rohani H, Amann M, Anderson HR, Andrews KG, Aryee M, et al. A comparative risk assessment of burden of disease and injury attributable to 67 risk factors and risk factor clusters in 21 regions, 1990-2010: A systematic analysis for the Global Burden of Disease Study 2010. *Lancet* 2012;380(9859):2224-2260.
8. Chang HH, Zhou J, Fuentes M. Impact of climate change on ambient ozone level and mortality in southeastern United States. *Int J Environ Res Public Health* 2010;7(7):2866-2880.
9. Orru H, Andersson C, Ebi KL, Langner J, Astrom C, Forsberg B. Impact of climate change on ozone-related mortality and morbidity in Europe. *Eur Respir J* 2012;41(2):285-294.
10. Harkema JR, Plopper CG, Hyde DM, St George JA, Dungworth DL. Effects of an ambient level of ozone on primate nasal epithelial mucosubstances. Quantitative histochemistry. *Am J Pathol* 1987;127(1):90-96.
11. Harkema JR, Plopper CG, Hyde DM, St George JA, Wilson DW, Dungworth DL. Response of macaque bronchiolar epithelium to ambient concentrations of ozone. *Am J Pathol* 1993;143(3):857-866.
12. Harkema JR, Wagner JG. Epithelial and inflammatory responses in the airways of laboratory rats coexposed to ozone and biogenic substances: Enhancement of toxicant-induced airway injury. *Exp Toxicol Pathol* 2005;57 Suppl 1:129-141.
13. Hollingsworth JW, 2nd, Cook DN, Brass DM, Walker JK, Morgan DL, Foster WM, Schwartz DA. The role of Toll-like receptor 4 in environmental airway injury in mice. *Am J Respir Crit Care Med* 2004;170(2):126-132.
14. Hotchkiss JA, Harkema JR, Sun JD, Henderson RF. Comparison of acute ozone-induced nasal and pulmonary inflammatory responses in rats. *Toxicol Appl Pharmacol* 1989;98(2):289-302.
15. Aris RM, Christian D, Hearne PQ, Kerr K, Finkbeiner WE, Balmes JR. Ozone-induced airway inflammation in human subjects as determined by airway lavage and biopsy. *Am Rev Respir Dis* 1993;148(5):1363-1372.
16. Devlin RB, McDonnell WF, Mann R, Becker S, House DE, Schreinemachers D, Koren HS. Exposure of humans to ambient levels of ozone for 6.6 hours causes cellular and biochemical changes in the lung. *Am J Respir Cell Mol Biol* 1991;4(1):72-81.

Copyright © 2015 by the American Thoracic Society

17. Devlin RB, McKinnon KP, Noah T, Becker S, Koren HS. Ozone-induced release of cytokines and fibronectin by alveolar macrophages and airway epithelial cells. *Am J Physiol* 1994;266(6 Pt 1):L612-619.
18. Devlin RB, McDonnell WF, Becker S, Madden MC, McGee MP, Perez R, Hatch G, House DE, Koren HS. Time-dependent changes of inflammatory mediators in the lungs of humans exposed to 0.4 ppm ozone for 2 hr: a comparison of mediators found in bronchoalveolar lavage fluid 1 and 18 hr after exposure. *Toxicol Appl Pharmacol* 1996;138(1):176-185.
19. Graham DE, Koren HS. Biomarkers of inflammation in ozone-exposed humans. Comparison of the nasal and bronchoalveolar lavage. *Am Rev Respir Dis* 1990;142(1):152-156.
20. Koren HS, Devlin RB, Graham DE, Mann R, McGee MP, Horstman DH, Kozumbo WJ, Becker S, House DE, McDonnell WF, et al. Ozone-induced inflammation in the lower airways of human subjects. *Am Rev Respir Dis* 1989;139(2):407-415.
21. Hatch GE, Slade R, Harris LP, McDonnell WF, Devlin RB, Koren HS, Costa DL, McKee J. Ozone dose and effect in humans and rats. A comparison using oxygen-18 labeling and bronchoalveolar lavage. *Am J Respir Crit Care Med* 1994;150(3):676-683.
22. Herbert RA, Hailey JR, Grumbein S, Chou BJ, Sills RC, Haseman JK, Goehl T, Miller RA, Roycroft JH, Boorman GA. Two-year and lifetime toxicity and carcinogenicity studies of ozone in B6C3F1 mice. *Toxicol Pathol* 1996;24(5):539-548.
23. Harkema JR, Hotchkiss JA, Griffith WC. Mucous cell metaplasia in rat nasal epithelium after a 20-month exposure to ozone: a morphometric study of epithelial differentiation. *Am J Respir Cell Mol Biol* 1997;16(5):521-530.
24. Harkema JR, Hotchkiss JA, Barr EB, Bennett CB, Gallup M, Lee JK, Basbaum C. Long-lasting effects of chronic ozone exposure on rat nasal epithelium. *Am J Respir Cell Mol Biol* 1999;20(3):517-529.
25. Harkema JR, Carey SA, Wagner JG. The nose revisited: a brief review of the comparative structure, function, and toxicologic pathology of the nasal epithelium. *Toxicol Pathol* 2006;34(3):252-269.
26. Cho HY, Hotchkiss JA, Harkema JR. Inflammatory and epithelial responses during the development of ozone-induced mucous cell metaplasia in the nasal epithelium of rats. *Toxicol Sci* 1999;51(1):135-145.
27. Carey SA, Ballinger CA, Plopper CG, McDonald RJ, Bartolucci AA, Postlethwait EM, Harkema JR. Persistent rhinitis and epithelial remodeling induced by cyclic ozone exposure in the nasal airways of infant monkeys. *Am J Physiol Lung Cell Mol Physiol* 2011;300(2):L242-254.
28. Harkema JR, Plopper CG, Hyde DM, St George JA, Wilson DW, Dungworth DL. Response of the macaque nasal epithelium to ambient levels of ozone. A morphologic and morphometric study of the transitional and respiratory epithelium. *Am J Pathol* 1987;128(1):29-44.
29. Bascom R, Naclerio RM, Fitzgerald TK, Kagey-Sobotka A, Proud D. Effect of ozone inhalation on the response to nasal challenge with antigen of allergic subjects. *Am Rev Respir Dis* 1990;142(3):594-601.
30. Holz O, Jorres RA, Timm P, Mucke M, Richter K, Koschyk S, Magnussen H. Ozone-induced airway inflammatory changes differ between individuals and are reproducible. *Am J Respir Crit Care Med* 1999;159(3):776-784.
31. Zhao Q, Simpson LG, Driscoll KE, Leikauf GD. Chemokine regulation of ozone-induced neutrophil and monocyte inflammation. *Am J Physiol* 1998;274(1 Pt 1):L39-46.

Copyright © 2015 by the American Thoracic Society

AJRCMB Articles in Press. Published on 23-July-2015 as 10.1165/rcmb.2015-0165OC

32. Frischer T, Studnicka M, Halmerbauer G, Horak F, Jr., Gartner C, Tauber E, Koller DY. Ambient ozone exposure is associated with eosinophil activation in healthy children. *Clin Exp Allergy* 2001;31(8):1213-1219.
33. Frischer TM, Kuehr J, Pullwitt A, Meinert R, Forster J, Studnicka M, Koren H. Ambient ozone causes upper airways inflammation in children. *Am Rev Respir Dis* 1993;148(4 Pt 1):961-964.
34. Hiltermann TJ, de Bruijne CR, Stolk J, Zwinderman AH, Spieksma FT, Roemer W, Steerenberg PA, Fischer PH, van Bree L, Hiemstra PS. Effects of photochemical air pollution and allergen exposure on upper respiratory tract inflammation in asthmatics. *Am J Respir Crit Care Med* 1997;156(6):1765-1772.
35. Kopp MV, Ulmer C, Ihorst G, Seydewitz HH, Frischer T, Forster J, Kuehr J. Upper airway inflammation in children exposed to ambient ozone and potential signs of adaptation. *Eur Respir J* 1999;14(4):854-861.
36. Ward JM, Yoon M, Anver MR, Haines DC, Kudo G, Gonzalez FJ, Kimura S. Hyalinosis and Ym1/Ym2 gene expression in the stomach and respiratory tract of 129S4/SvJae and wild-type and CYP1A2-null B6, 129 mice. *Am J Pathol* 2001;158(1):323-332.
37. Brandenberger C, Rowley NL, Jackson-Humbles DN, Zhang Q, Bramble LA, Lewandowski RP, Wagner JG, Chen W, Kaplan BL, Kaminski NE, et al. Engineered silica nanoparticles act as adjuvants to enhance allergic airway disease in mice. *Part Fibre Toxicol* 2013;10(1):26.
38. Salo PM, Calatroni A, Gergen PJ, Hoppin JA, Sever ML, Jaramillo R, Arbes SJ, Jr., Zeldin DC. Allergy-related outcomes in relation to serum IgE: Results from the National Health and Nutrition Examination Survey 2005-2006. *J Allergy Clin Immunol* 2011;127(5):1226-1235 e1227.
39. Wheatley LM, Togias A. Clinical practice. Allergic rhinitis. *N Engl J Med* 2015;372(5):456-463.
40. Wagner JG, Hotchkiss JA, Harkema JR. Enhancement of nasal inflammatory and epithelial responses after ozone and allergen coexposure in Brown Norway rats. *Toxicol Sci* 2002;67(2):284-294.
41. Plopper CG, Smiley-Jewell SM, Miller LA, Fanucchi MV, Evans MJ, Buckpitt AR, Avdalovic M, Gershwin LJ, Joad JP, Kajekar R, et al. Asthma/allergic airways disease: does postnatal exposure to environmental toxicants promote airway pathobiology? *Toxicol Pathol* 2007;35(1):97-110.
42. Schelegle ES, Miller LA, Gershwin LJ, Fanucchi MV, Van Winkle LS, Gerriets JE, Walby WF, Mitchell V, Tarkington BK, Wong VJ, et al. Repeated episodes of ozone inhalation amplifies the effects of allergen sensitization and inhalation on airway immune and structural development in Rhesus monkeys. *Toxicol Appl Pharmacol* 2003;191(1):74-85.
43. Kim BJ, Kwon JW, Seo JH, Kim HB, Lee SY, Park KS, Yu J, Kim HC, Leem JH, Sakong J, et al. Association of ozone exposure with asthma, allergic rhinitis, and allergic sensitization. *Ann Allergy Asthma Immunol* 2011;107(3):214-219 e211.
44. Peden DB, Setzer RW, Jr., Devlin RB. Ozone exposure has both a priming effect on allergen-induced responses and an intrinsic inflammatory action in the nasal airways of perennially allergic asthmatics. *Am J Respir Crit Care Med* 1995;151(5):1336-1345.
45. Furuta GT, Atkins FD, Lee NA, Lee JJ. Changing roles of eosinophils in health and disease. *Ann Allergy Asthma Immunol* 2014;113(1):3-8.

Copyright © 2015 by the American Thoracic Society

46. Jacobsen EA, Ochkur SI, Pero RS, Taranova AG, Protheroe CA, Colbert DC, Lee NA, Lee JJ. Allergic pulmonary inflammation in mice is dependent on eosinophil-induced recruitment of effector T cells. *J Exp Med* 2008;205(3):699-710.
47. Moro K, Yamada T, Tanabe M, Takeuchi T, Ikawa T, Kawamoto H, Furusawa J, Ohtani M, Fujii H, Koyasu S. Innate production of T(H)2 cytokines by adipose tissue-associated c-Kit(+)Sca-1(+) lymphoid cells. *Nature* 2010;463(7280):540-544.
48. Colucci F, Soudais C, Rosmaraki E, Vanes L, Tybulewicz VL, Di Santo JP. Dissecting NK cell development using a novel alymphoid mouse model: Investigating the role of the c-abl proto-oncogene in murine NK cell differentiation. *J Immunol* 1999;162(5):2761-2765.
49. Vonarbourg C, Mortha A, Bui VL, Hernandez PP, Kiss EA, Hoyler T, Flach M, Bengsch B, Thimme R, Holscher C, et al. Regulated expression of nuclear receptor RORγt confers distinct functional fates to NK cell receptor-expressing RORγt(+) innate lymphocytes. *Immunity* 2010;33(5):736-751.
50. Walker JA, Barlow JL, McKenzie AN. Innate lymphoid cells--how did we miss them? *Nat Rev Immunol* 2013;13(2):75-87.
51. Long AJ, Sypek JP, Askew R, Fish SC, Mason LE, Williams CM, Goldman SJ. Gob-5 contributes to goblet cell hyperplasia and modulates pulmonary tissue inflammation. *Am J Respir Cell Mol Biol* 2006;35(3):357-365.
52. Moro K, Ealey KN, Kabata H, Koyasu S. Isolation and analysis of group 2 innate lymphoid cells in mice. *Nat Protoc* 2015;10(5):792-806.
53. Byers DE, Alexander-Brett J, Patel AC, Agapov E, Dang-Vu G, Jin X, Wu K, You Y, Alevy Y, Girard JP, et al. Long-term IL-33-producing epithelial progenitor cells in chronic obstructive lung disease. *J Clin Invest* 2013;123(9):3967-3982.
54. Giannetti N, Moyse E, Ducray A, Bondier JR, Jourdan F, Propper A, Kastner A. Accumulation of Ym1/2 protein in the mouse olfactory epithelium during regeneration and aging. *Neuroscience* 2004;123(4):907-917.
55. Song HM, Jang AS, Ahn MH, Takizawa H, Lee SH, Kwon JH, Lee YM, Rhim TY, Park CS. Ym1 and Ym2 expression in a mouse model exposed to diesel exhaust particles. *Environ Toxicol* 2008;23(1):110-116.
56. Homer RJ, Zhu Z, Cohn L, Lee CG, White WI, Chen S, Elias JA. Differential expression of chitinases identify subsets of murine airway epithelial cells in allergic inflammation. *Am J Physiol Lung Cell Mol Physiol* 2006;291(3):L502-511.
57. Cai Y, Kumar RK, Zhou J, Foster PS, Webb DC. Ym1/2 promotes Th2 cytokine expression by inhibiting 12/15(S)-lipoxygenase: Identification of a novel pathway for regulating allergic inflammation. *J Immunol* 2009;182(9):5393-5399.
58. Webb DC, McKenzie AN, Foster PS. Expression of the Ym2 lectin-binding protein is dependent on interleukin (IL)-4 and IL-13 signal transduction: identification of a novel allergy-associated protein. *J Biol Chem* 2001;276(45):41969-41976.

Copyright © 2015 by the American Thoracic Society

AJRCMB Articles in Press. Published on 23-July-2015 as 10.1165/rcmb.2015-0165OC

Figure Legends

Figure 1. A) Light photomicrographs of nasal mucosa from mice exposed to filtered air for 1 day and sacrificed 24 h (1, 2, 3), ozone for 1 day and sacrificed 2 h (4, 5, 6) or 24 h (7, 8, 9), or ozone for 9 days and sacrificed 24 h post-exposure (10, 11, 12). Tissues were histochemically stained with hematoxylin and eosin (H&E, 1, 4, 7, 10) and immunohistochemically stained for neutrophils (2, 5, 8, 11) or eosinophils (3, 6, 9, 12), and countered stained with hematoxylin. e, nasal transitional epithelium; bv, blood vessel in the lamina propria; g, glands in the lamina propria; b, bone. Arrow in 7, vacuolar degeneration of ciliated epithelial cell; Arrows in 10, hyaline globules in cytoplasm of nonciliated epithelial cells (hyalinosis); Arrows in 2, 5, 8, and 11, neutrophils; Arrows in 3, 6, 9, and 12, eosinophils. B) Morphometric determination of nasal epithelial thickness after 1, 2, 4, and 9 days of ozone exposure. C) Temporal changes in the density of granulocytes (neutrophils and eosinophils) in the nasal mucosa after exposure to ozone. *Significantly different from mice exposed to filtered air for 1 day (2 h and 24 h after exposure), $p \leq 0.05$.

Figure 2. A) Light photomicrographs of nasal mucosa from mice exposed to ozone for 1 (1, 2) or 9 (3, 4) days and sacrificed 24 h post-exposure. Tissues were histochemically stained with Alcian Blue/Periodic Acid Schiff (AB/PAS) for intraepithelial mucosubstances (1, 3) and immunohistochemically for YM1/YM2 chitinase-like proteins (2, 4), and countered stained with hematoxylin. e, nasal transitional epithelium; bv, blood vessel in lamina propria; g, gland in lamina propria; b, bone. Arrows, AB/PAS-stained mucosubstances in 1 and 3. YM1/YM2 protein (brown stain) in 2 and 4. B) Temporal changes in the morphometrically determined amount of intraepithelial mucosubstances in mice exposed to ozone. C) Morphometric measurement of the amount of YM1/YM2 proteins in epithelium of mice exposed to ozone for 1,

Copyright © 2015 by the American Thoracic Society

2, 4, or 9 days. *Significantly different from mice exposed to filtered air for 1 day (2 h and 24 h after exposure), $p \leq 0.05$.

Figure 3. A) Unsupervised hierarchical clustering of ozone-induced fold changes (relative to filtered air controls) in the expression of nasal mucosal mRNA, together with fold changes in the phenotypic expression (morphometrically determined density changes) of neutrophils, eosinophils, mucosubstances, and YM1/YM2 proteins in the nasal mucosa (shown with asterisks). This analysis was performed in the TM4 Multiexperiment Viewer (MeV 4.8.1; http://www.tm4.org) using Pearson correlation metric. B) Temporal fold changes in the expression of mRNA transcripts in the nasal mucosa of mice exposed to ozone for 1, 2, 4, or 9 days. *Statistically different from the respective air control group at each time point, $p \leq 0.05$.

Figure 4. A) Light photomicrographs of nasal mucosa from C57BL/6 (1, 3, 5, 7, 9) and Rag2(-/-)Il2rg(-/-) (2, 4, 6, 8, 10) mice exposed to filtered air (1, 2) or ozone (3, 4, 5, 6, 7, 8, 9, 10) for 9 days. Tissues were histochemically stained with H&E (1, 2, 3, 4) or AB/PAS (9 and 10), and immunhistochemically for eosinophils (5, 6) or YM1/YM2 chitinase-like proteins (7, 8). e, nasal transitional epithelium; bv, blood vessel in lamina propria; g, gland in lamina propria; b, bone. *Inflammatory cell infiltrate in lamina propria; Arrows, YM1/YM2 protein (brown stain) in7 and AB/PAS-stained mucosubstances in 9. B) Morphometrically determined densities of total epithelial cells, eosinophils, YM1/YM2 proteins, and AB/PAS-stained mucosubstances in the nasal epithelium of mice exposed to ozone for 9 days. *Significantly different from mice of the same strain and exposed to filtered air, $p \leq 0.05$.

Copyright © 2015 by the American Thoracic Society

AJRCMB Articles in Press. Published on 23-July-2015 as 10.1165/rcmb.2015-0165OC

1 **Figure 5.** Ozone-induced fold changes in the expression of type 2 immune-related mRNA
2 transcripts in C57BL/6 and Rag2(-/-)Il2rg(-/-) mice, relative to filtered air exposure.
3 *Statistically different from mice of the same strain and exposed to filtered air, $p \leq 0.05$.

Copyright © 2015 by the American Thoracic Society

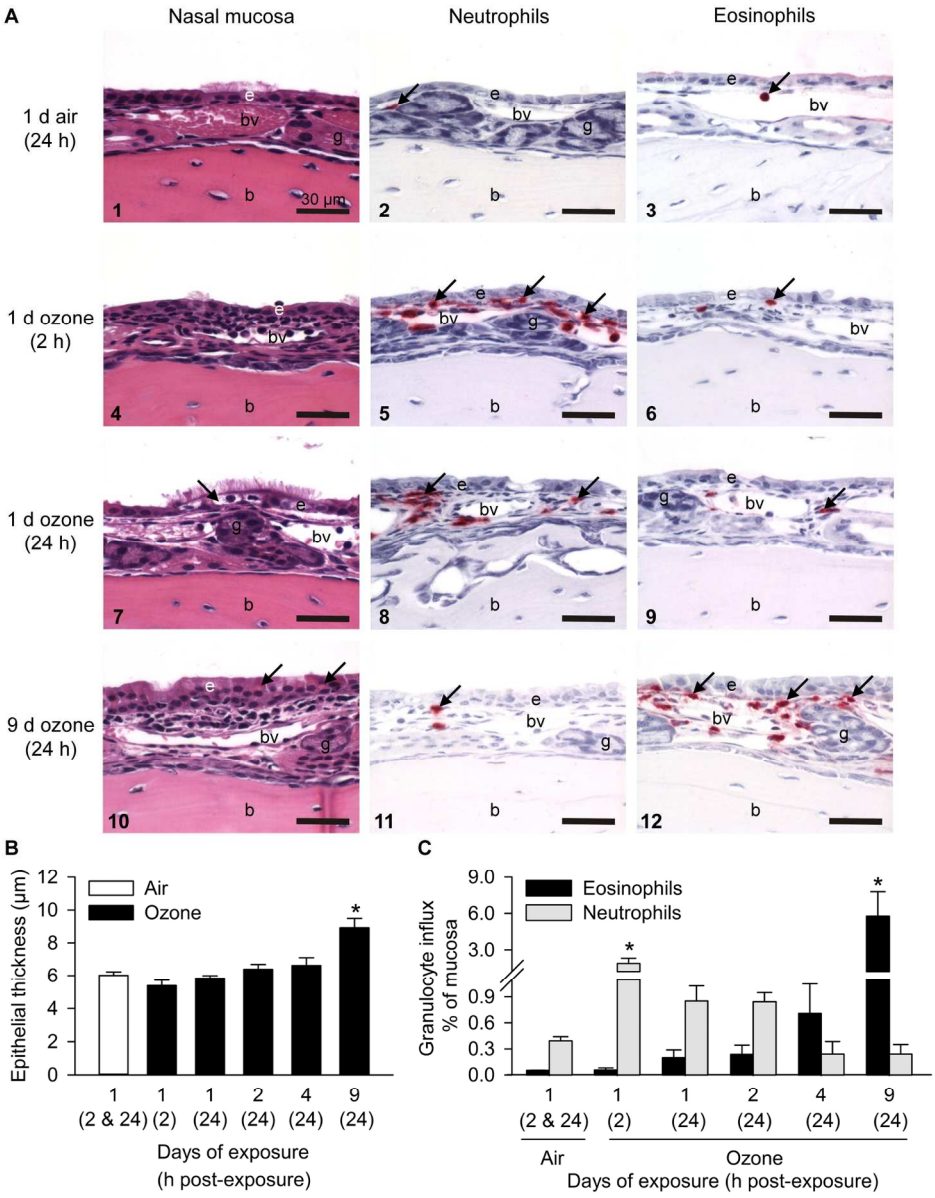

Figure 1
212x271mm (300 x 300 DPI)

Copyright © 2015 by the American Thoracic Society

AJRCMB Articles in Press. Published on 23-July-2015 as 10.1165/rcmb.2015-0165OC

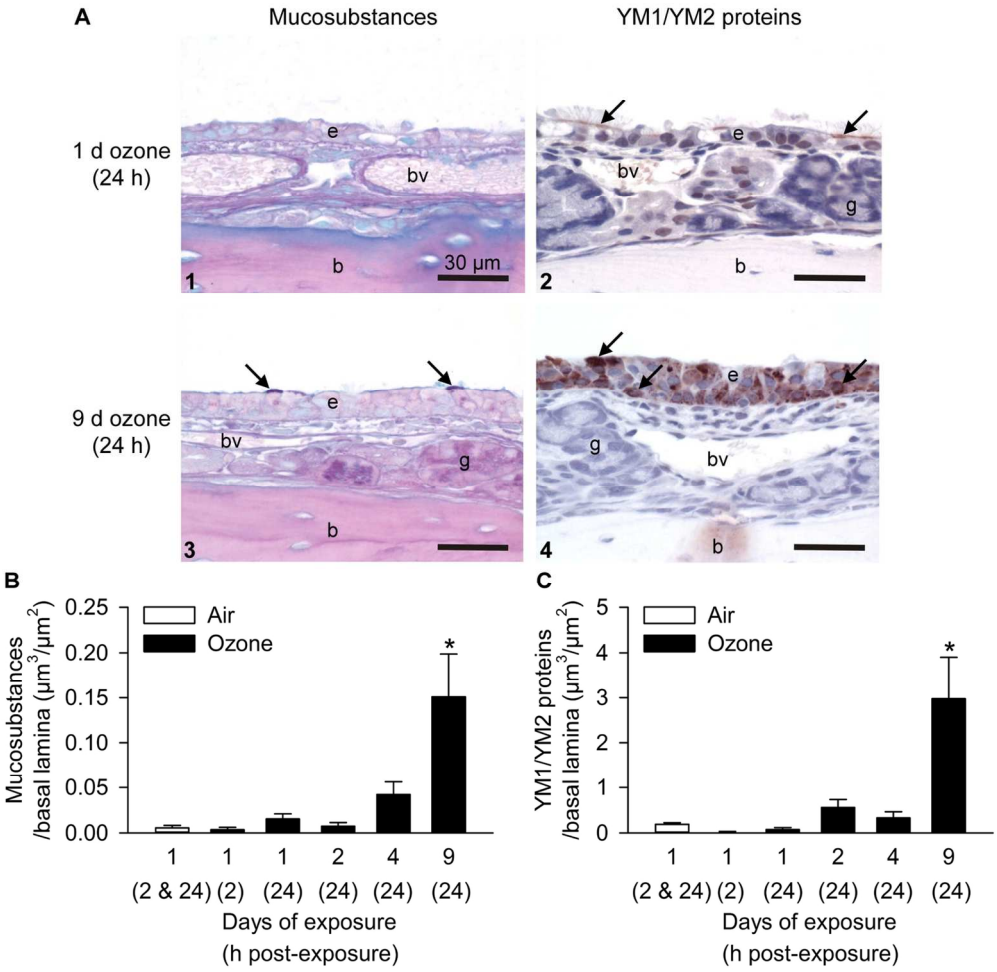

Figure 2
152x147mm (300 x 300 DPI)

Copyright © 2015 by the American Thoracic Society

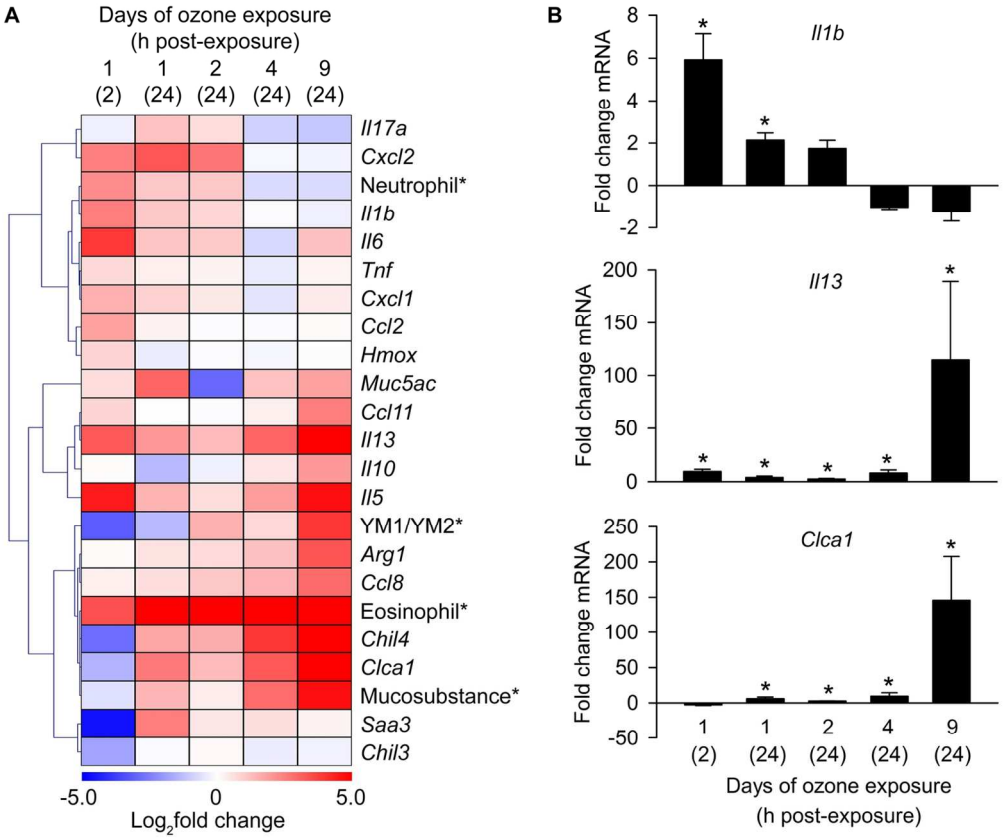

Figure 3
136x113mm (300 x 300 DPI)

Copyright © 2015 by the American Thoracic Society

AJRCMB Articles in Press. Published on 23-July-2015 as 10.1165/rcmb.2015-0165OC

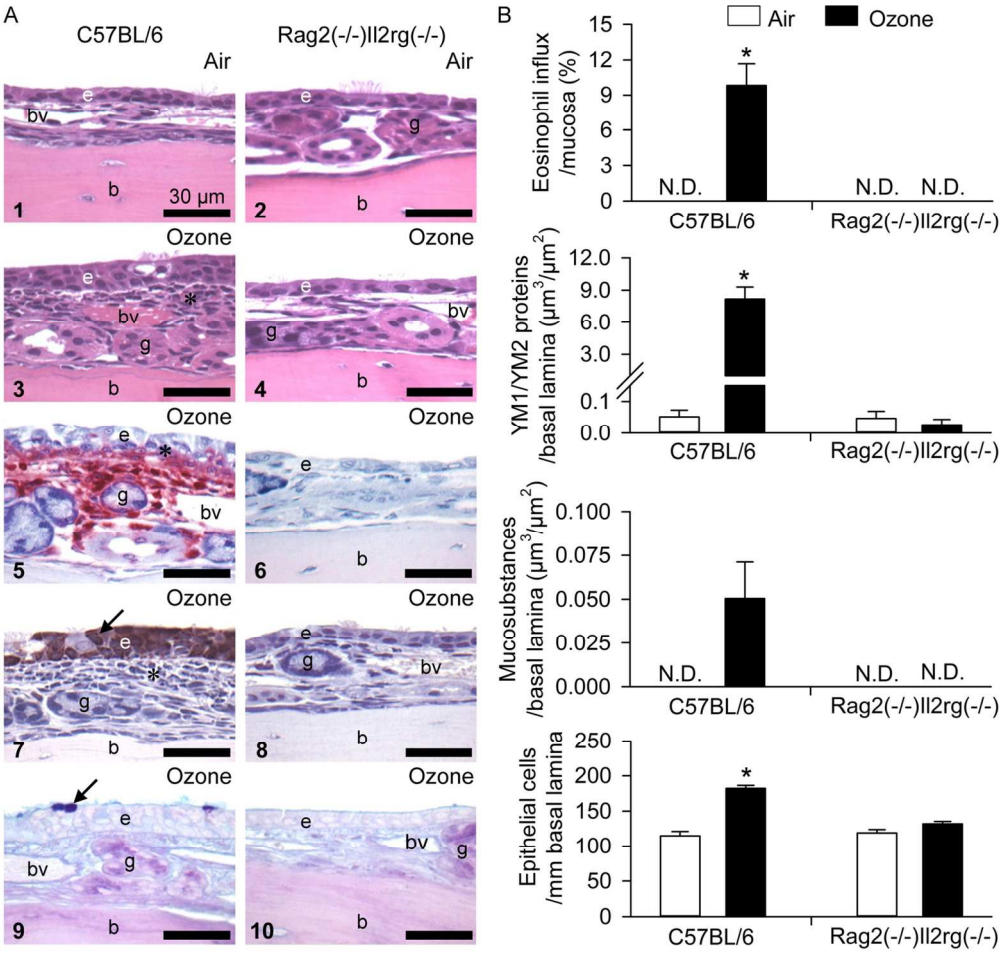

Figure 4
150x142mm (300 x 300 DPI)

Copyright © 2015 by the American Thoracic Society

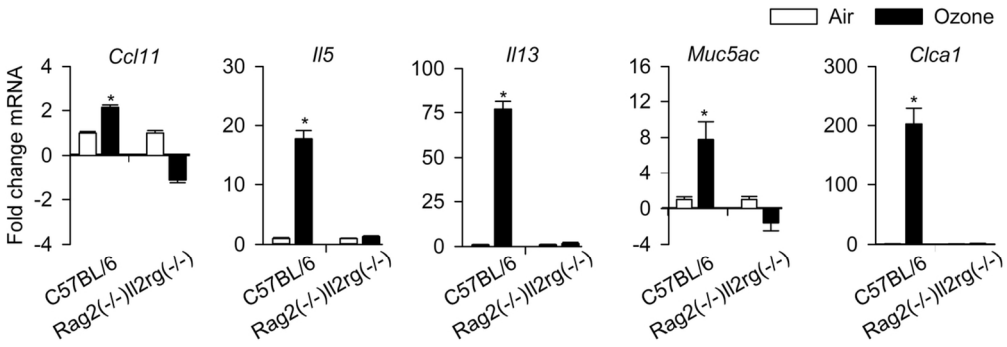

Figure 5
57x19mm (600 x 600 DPI)

Copyright © 2015 by the American Thoracic Society

AJRCMB Articles in Press. Published on 23-July-2015 as 10.1165/rcmb.2015-0165OC

Supplemental Material

Ozone-Induced Type 2 Immunity in Nasal Airways: Development and Lymphoid Cell Dependence in Mice

Chee Bing Ong, Kazuyoshi Kumagai, Phillip T. Brooks, Christina Brandenberger, Ryan P. Lewandowski, Daven N. Jackson-Humbles, Rance Nault, Timothy R. Zacharewski, James G. Wagner, and Jack R. Harkema

Materials and Methods

Animals. All the animals were individually housed in stainless steel wire cages within whole body inhalation exposure chambers (H-1000; Lab Products Marywood, NJ). Mice were provided free access to food (Harlan Teklad Irradiated 8940, Madison, WI) and water, and maintained in Michigan State University (MSU) animal housing facilities accredited by the Association for Assessment and Accreditation of Laboratory Animal Care and according to the National Institutes of Health guidelines as overseen by the MSU Institutional Animal Care and Use Committee. Rooms were maintained at temperatures of 21°C–24°C and relative humidities of 45–70%, with a 12 h light/dark cycle starting at 7:30 A.M.

Inhalation Exposures. In Study 1, ozone chamber concentrations over the 9 days of exposure were 0.517 ± 0.002, 0.498 ± 0.002, 0.493 ± 0.004, and 0.485 ± 0.002 ppm (mean ± standard error of the mean), for 1, 2, 4, and 9 days, respectively. In Study 2, the ozone chamber concentration for the 9-day exposure was 0.481 ± 0.001 ppm. Ozone concentrations in the filtered air chamber were below 0.01 ppm throughout the exposures.

Copyright © 2015 by the American Thoracic Society

Necropsy and Nasal Tissue Preparation for Light Microscopy. All mice were euthanized by exsanguinations via the abdominal aorta under pentobarbital anaesthesia 2 h or 24 h after the single exposure or 24 h after the end of exposures. The head of each mouse was removed from the carcass. After the lower jaw and skin were removed from the head, nasal cavities of mice designated for histopathology and morphometric examination were flushed retrograde through the nasopharyngeal meatus with 10% neutral buffered formalin. The head was then immersed and stored in a large volume of the same fixative prior to decalcification. Before sectioning, the heads were decalcified in 13% formic acid for 7 days.

Immunohistochemistry. For MBP and Ly-6B.2 staining, sections were incubated with 0.04% pepsin solution in 0.2 mol/L hydrochloric acid at 37°C for 20 min. Following protein block by normal goat serum (Vector Laboratories, Burlingame, CA) and endogenous biotin block by avidin D (Vector Laboratories) and d-biotin (SigmaAldrich, St.Louis, MO), the slides were incubated with MBP (2.0 µg/mL) or Ly-6B.2 antibody (0.4 µg/mL) at room temperature for 60 min. The slides were subsequently reacted with a biotinylated rabbit anti-rat antibody, avidin-alkaline phosphatase, and Fast Red (Vector Laboratories). For YM1/YM2 staining, endogenous peroxidase activity was quenched by incubation in 3% hydrogen peroxide/methanol at room temperature for 30 min (no pretreatment was applied). The sections were treated with normal rabbit serum (Vector Laboratories) and then the biotin block reagents. The slides were incubated with YM1/YM2 antibody at dilution of 1:3000 at room temperature for 60 min. The slides were subsequently reacted with a biotinylated goat anti-rabbit antibody, an avidin-horseradish peroxidase, and Nova Red (Vector Laboratories). All sections were counterstained with Mayer's hematoxylin.

Copyright © 2015 by the American Thoracic Society

AJRCMB Articles in Press. Published on 23-July-2015 as 10.1165/rcmb.2015-0165OC

Nasal morphometry. For estimation of neutrophil or eosinophil densities in the nasal mucosa, the number of points hitting areas positive for Ly-6B.2 antibody or MBP antibody, respectively, were counted with a point grid in the sampled images of each mouse. The number of points on the reference space (i.e., mucosal epithelium and lamina propria) was also counted with a point grid. The total number of points was multiplied by the area/point (a/p) for the neutrophil, eosinophil, or reference space to calculate each density. Finally, the percentage of neutrophil- or eosinophil-density per the reference space was calculated and expressed as the percentage of granulocyte influx in the mucosal tissue.

A point intercept grid was placed over the sampled images to estimate density of intraepithelial mucosubstances per underlying basal lamina. Mucus density ($\hat{V}_M$) was calculated by the area/point (a/p) and divided by the total number of points in all images (n) as shown in equation 1 (EQ1) below.

$$\hat{V}_M = \frac{\sum P_M \times a/p}{n} \qquad \text{EQ1}$$

The surface density of the basal lamina ($\hat{S}_{BL}$) in the selected images was estimated by counting the number of intercepts (I) of the line probe with the subepithelial basal lamina of the lateral wall divided by the area per point (a/p) and the number of points in all sampled images (n) as described in equation 2 (EQ2).

$$\hat{S}_{BL} = \frac{2 \times \sum I}{a/p \times n} \qquad \text{EQ2}$$

Copyright © 2015 by the American Thoracic Society

Intraepithelial mucosubstances per basal lamina of lateral wall was then estimated by dividing $\hat{V}_M$ by $\hat{S}_{BL}$. The YM1/YM2 protein in the mucosal epithelium and epithelial thickness were evaluated with the same method and equations as those of mucosubstances. For the estimation of epithelial thickness, both nuclear and cytoplasmic profiles in the hematoxylin and eosin-stained nasal epithelium were counted. Total epithelial numeric cell densities were determined by counting the total number of epithelial nuclear profiles present in the nasal epithelium and dividing this number by the length of the basal lamina. The length of the basal lamina was calculated from the contour length of the digitized image.

Copyright © 2015 by the American Thoracic Society

AJRCMB Articles in Press. Published on 23-July-2015 as 10.1165/rcmb.2015-0165OC

1 **Table E1.** Gene expression profile in nasal mucosa of C57BL/6 mice exposed to ozone for 1, 2, 4 or 9 days.

Gene	2 h (1 day)	24 h (1 day)	2 days	4 days	9 days
Arg1	1.07 ± 0.09	1.49 ± 0.28	**1.68 ± 0.22**	**2.32 ± 0.49**	**10.33 ± 4.02**
Ccl2 (*MCP-1*)	**3.59 ± 0.44**	1.20 ± 0.23	-1.02 ± 0.13	-1.05 ± 0.10	1.09 ± 0.16
Ccl8 (*MCP-2*)	1.27 ± 0.18	1.58 ± 0.34	**2.17 ± 0.38**	**2.81 ± 0.58**	**7.53 ± 2.93**
Ccl11 (*Eotaxin*)	**1.79 ± 0.24**	-1.01 ± 0.12	-1.02 ± 0.07	1.25 ± 0.16	**5.90 ± 2.07**
Chil3 (*Ym1*)	-3.51 ± 0.82	-1.06 ± 0.17	1.10 ± 0.23	-1.27 ± 0.28	-1.18 ± 0.24
Chil4 (*Ym2*)	-7.24 ± 2.20	**3.38 ± 1.40**	**3.06 ± 0.51**	**15.57 ± 9.97**	**431.34 ± 192.17**
Clca1 (*Gob5*)	-2.80 ± 0.88	**6.12 ± 2.29**	**2.54 ± 0.25**	**9.56 ± 4.85**	**145.82 ± 61.93**
Cxcl1 (*KC*)	**2.96 ± 0.45**	1.88 ± 0.55	1.35 ± 0.37	-1.44 ± 0.08	1.34 ± 0.49
Cxcl2 (*MIP-2*)	**5.75 ± 1.61**	**10.04 ± 2.67**	**6.53 ± 2.27**	-1.10 ± 0.24	-1.17 ± 0.57
Hmox1	**1.84 ± 0.25**	-1.29 ± 0.11	-1.04 ± 0.06	-1.12 ± 0.04	1.04 ± 0.10
Ifng	1.34 ± 0.21	1.54 ± 0.47	-1.34 ± 0.20	-1.26 ± 0.10	-1.34 ± 0.26
Il1b	**5.93 ± 1.22**	**2.14 ± 0.34**	1.75 ± 0.38	-1.03 ± 0.09	-1.24 ± 0.44
Il2	N.E.	N.E.	N.E.	1.07 ± 0.23	1.31 ± 0.25
Il4	N.E.	N.E.	N.E.	1.15 ± 0.23	3.62 ± 2.15
Il5	**22.70 ± 5.21**	**2.83 ± 0.59**	**1.60 ± 0.21**	**3.79 ± 1.06**	**26.74 ± 12.71**
Il6	**15.31 ± 3.77**	2.25 ± 0.96	1.80 ± 0.44	-1.66 ± 0.24	2.35 ± 1.17
Il10	1.06 ± 0.14	-2.57 ± 0.29	-1.21 ± 0.13	1.45 ± 0.31	**4.04 ± 1.37**
Il13	**9.63 ± 1.96**	**4.11 ± 1.29**	**2.54 ± 0.55**	**8.11 ± 2.94**	**114.67 ± 74.74**
Muc5ac	1.60 ± 0.97	**8.02 ± 2.73**	-7.76 ± 4.26	2.31 ± 0.83	3.63 ± 1.01
Muc5b	N.E.	N.E.	N.E.	N.E.	N.E.
Saa3	-25.26 ± 6.78	**5.85 ± 3.60**	1.44 ± 0.46	1.56 ± 0.16	1.19 ± 0.39
Tnf	**1.70 ± 0.20**	1.26 ± 0.14	1.18 ± 0.17	-1.33 ± 0.12	1.17 ± 0.21

2 Data are expressed as fold change relative to respective air controls ± SEM (n = 6/group). Genes showing statistical significances (air
3 vs. ozone/timepoint, p values ≤ 0.05) are in bold and underlined. N.E.; not evaluated.

Copyright © 2015 by the American Thoracic Society

4 **Table E2.**Gene expression profile in nasal mucoa of C57BL/6 and Rag2(-/-)Il2rg(-/-) mice
5 exposed to ozone for 9 days.

Gene	C57BL/6, ozone	Rag2(-/-)Il2rg(-/-), ozone
Arg1	**4.78 ± 0.44**	1.26 ± 0.21
Ccl2 (*MCP-1*)	1.00 ± 0.19	-1.70 ± 0.35
Ccl5 (*RANTES*)	-1.06 ± 0.09	-1.72 ± 0.65
Ccl8 (*MCP-2*)	**7.13 ± 1.10**	-1.06 ± 0.28
Ccl11 (*Eotaxin*)	**2.14 ± 0.11**	-1.13 ± 0.12
Chil3 (*Ym1*)	1.42 ± 0.26	-1.40 ± 0.20
Chil4 (*Ym2*)	**193.15 ± 15.72**	**123.35 ± 105.15**
Clca1 (*Gob5*)	**202.65 ± 26.33**	1.62 ± 0.29
Cxcl1 (*KC*)	-1.31 ± 0.44	-2.33 ± 0.31
Cxcl2 (*MIP-2*)	2.74 ± 2.38	-2.69 ± 1.10
Hmox1	**-1.49 ± 0.08**	1.00 ± 0.06
Ifng	N.E.	N.E.
Il1b	1.91 ± 1.02	-1.40 ± 0.35
Il2	1.37 ± 0.28	N.D.
Il4	3.60 ± 0.89	1.03 ± 0.03
Il5	**17.78 ± 1.39**	1.31 ± 0.13
Il6	-1.83 ± 0.46	-1.15 ± 0.22
Il10	**2.78 ± 0.28**	-1.14 ± 0.12
Il13	**76.92 ± 4.33**	1.69 ± 0.65
Muc5ac	**7.78 ± 1.98**	-1.60 ± 0.88
Muc5b	**3.22 ± 0.26**	1.26 ± 0.24
Saa3	1.35 ± 0.82	-1.50 ± 0.56
Tnf	-1.09 ± 0.24	**-3.67 ± 0.84**

6 Data are expressed as fold change relative to respective air controls ± SEM (n = 6/group). Genes
7 showing statistical significances (air vs. ozone/same strain, p values ≤ 0.05) are in bold and
8 underlined. N.D.; not detected. N.E.; not evaluated.

9

Copyright © 2015 by the American Thoracic Society

AJRCMB Articles in Press. Published on 23-July-2015 as 10.1165/rcmb.2015-0165OC

Figure E1. Nasal sections. A) Illustration of the right nasal passage of the mouse with the septum removed exposing the nasal turbinates and lateral wall. The four vertical lines (T1–T4) indicate the sites of transverse tissue blocks that were processed for microscopic examination. The pink shaded region is the location of nasal mucosa that was analyzed for ozone-induced changes (relative to air controls) in mRNA expression of selected inflammatory and epithelial genes. B) Rostral face of T1. Red areas represent the airways lined by nasal mucosa affected by the ozone exposure (i.e., rhinitis and epithelial remodeling). The yellow stippled lines outline the sites used for morphometry. NT, nasoturbinate; MT, maxilloturbinate; HP, hard palate; ET,ethmoid turbinates; OB, olfactory bulb; np, nasopharynx; S, nasal septum; VM, ventral meatus; MM; middle meatus; LM, lateral meatus; NT, nasoturbinate; LW, lateral wall.

Figure E2. A & B) Light photomicrographs of the nasal mucosa lining the ventral lateral aspect of the nasophayngeal meatus in nasal tissue section T3 in a C57BL/6 (A) and Rag2(-/-)Il2rg(-/-) (B) mouse. Nasal associated lymphoid tissue (NALT) is present in the lamina propria (lp) of the C57BL/6 mouse (A), but not in the Rag2(-/-)Il2rg(-/-) mouse (B). Tissues were stained with hematoxylin and eosin. e, nasal respiratory epithelium; b, bone. C & D) Light photomicrographs of bone marrow (BM) containing eosinophils (arrows; red stain) in the nasal septum of the C57BL/6 (C) and the Rag2(-/-)Il2rg(-/-) mouse (D). oe, olfactory epithelium; lp, lamina propria; b, septal bone. Nasal tissue sections in C and D were immunohistochemically stained for eosinophil-specific major basic protein, and counterstained with hematoxylin.

Copyright © 2015 by the American Thoracic Society

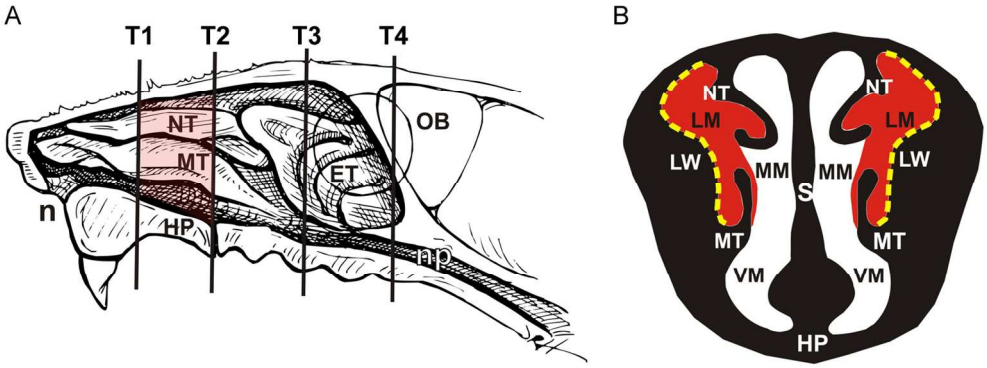

Figure E1
138x50mm (300 x 300 DPI)

Copyright © 2015 by the American Thoracic Society

AJRCMB Articles in Press. Published on 23-July-2015 as 10.1165/rcmb.2015-0165OC

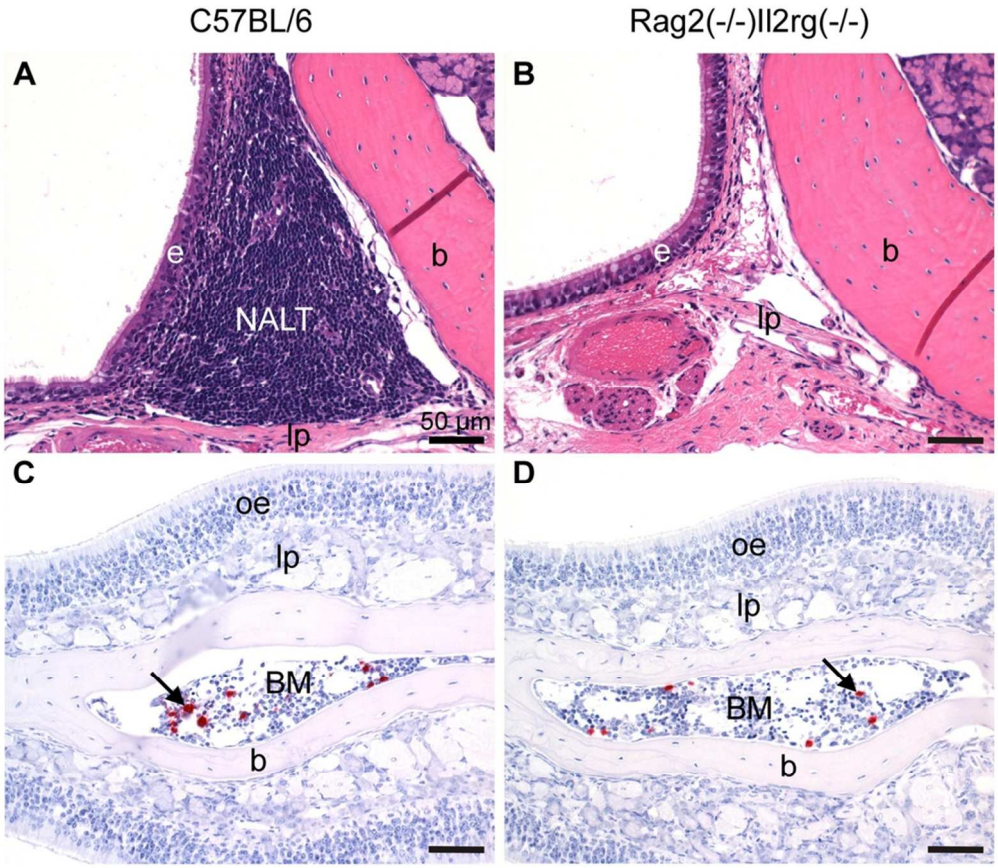

Figure E2
96x84mm (300 x 300 DPI)

Copyright © 2015 by the American Thoracic Society