

Microneedling: A Review and Practical Guide

TINA S. ALSTER, MD* AND PAUL M. GRAHAM, DO†

BACKGROUND Microneedling is a relatively new treatment option in dermatology and has been touted for a broad range of applications including skin rejuvenation, acne scarring, rhytides, surgical scars, dyschromia, melasma, enlarged pores, and transdermal drug delivery. The significant increase in minimally invasive procedures that has been reported over the past several years suggest that microneedling may occupy a specific niche for patients who desire measurable clinical results from treatments with little to no recovery.

OBJECTIVE To review the published medical literature relating to microneedling in dermatology and provide a practical guide for its use in clinical practice.

MATERIALS AND METHODS A thorough literature search of microneedling in dermatology using PubMed was conducted, and all references pertaining to skin scarring and rejuvenation were reviewed. Based on the information presented in these publications and the authors' clinical experience, a microneedling technique is outlined for clinical practice. Pretreatment recommendations, intraoperative technique and treatment end points, and postoperative considerations are outlined.

RESULTS Microneedling produces substantial clinical improvement of scars, striae, and rhytides with expedient recovery and limited side effects. Controlled dermal wounding and stimulation of the wound healing cascade enhances collagen production and is likely responsible for the clinical results obtained.

CONCLUSION Microneedling is a safe, minimally invasive, and effective esthetic treatment for several different dermatologic conditions including acne and other scars, rhytides, and striae. Given its expedient post-treatment recovery, limited side effect profile, and significant clinical results, microneedling is a valuable alternative to more invasive procedures such as laser skin resurfacing and deep chemical peeling.

The authors have indicated no significant interest with commercial supporters.

Microneedling, also known as percutaneous collagen induction therapy, is a relatively new treatment option in dermatology. Although laser skin resurfacing has long been considered the treatment of choice for photoaged and scarred skin,¹ microneedling has recently been touted for a broad range of applications including skin rejuvenation, acne scarring, rhytides, surgical scars, dyschromia, melasma, enlarged pores, and transdermal drug delivery. The reported high efficacy, safety, and minimal post-treatment recovery rates associated with microneedling have increased patient satisfaction and clinician awareness of this popular procedure. According to the American Society of Plastic Surgery, minimally invasive, nonsurgical procedures accounted for approximately 89% of all cosmetic procedures conducted in 2015.² This significant

increase in minimally invasive procedures suggests that microneedling may occupy a specific niche for patients who desire treatments with little to no recovery, while still attaining measurable results. Microneedling has become an integral part of the daily treatment algorithm and has greatly changed the approach to the correction of facial rhytides and acne scarring. This article aims to outline the available published literature on the subject and provide a practical guide for practitioners who are interested in offering this highly effective and safe cosmetic procedure to their patients.

Background and Mechanism of Action

In 1994, Orentreich and Orentreich first described the use of a skin needling procedure using a technique

*Washington Institute of Dermatologic Laser Surgery, Washington, District of Columbia; †Department of Dermatology, St. Joseph Mercy Hospital, Ann Arbor, Michigan

called “subcision” to release fibrous strands responsible for depressed cutaneous scars and rhytides.³ The process involved the insertion and maneuvering of a tri-beveled hypodermic needle into the skin under the cutaneous defects to disrupt the underlying connective tissue that tethered down the skin in these areas.³ Three years later, Camirand and Doucet reported significant improvement in the clinical appearance and texture of surgical scars with needle dermabrasion, a process conducted using a tattoo gun devoid of ink.⁴ It was not until the early 2000s when the first micro-needle stamping device was used to treat facial rhytides and skin laxity. Using the principles outlined by earlier needling pioneers, Fernandes developed a drum-shaped device covered in tiny needles to produce cutaneous microwounds to improve facial rhytides and skin laxity.^{5,6}

Research has been conducted in both animals and humans to elucidate the mechanism by which micro-needling works. It has been hypothesized that the creation of numerous microchannels in atrophic acne scars physically breaks apart the compact collagen bundles in the superficial layer of the dermis while simultaneously inducing the production of new collagen and elastin underneath the scar.^{7,8} For treatment of superficial rhytides, microneedling is believed to work in a similar fashion, relying heavily on the production of new collagen to fill in and elevate the existing furrow. The creation of abundant microwounds directly stimulates the release of various growth factors that play a direct role in collagen and elastin synthesis and deposition within the dermis.⁹

More specifically, the creation of microchannels induces a controlled skin injury with minimal epidermal damage and stimulates the dermal wound healing cascade (inflammation, proliferation, and remodeling) to take place. This leads to the release of platelet-derived growth factor, fibroblast growth factor (FGF), and transforming growth factor alpha and beta (TGF- α and TGF- β).^{10,11} Neovascularization and neocollagenesis occur secondary to fibroblast proliferation and migration.¹² After the cutaneous injury, a fibronectin network is created, providing a matrix for collagen type III deposition, which is eventually replaced by Type I collagen. This transition can occur over weeks

to months, resulting in clinical skin tightening and rhytide reduction.^{6,10} In addition to the increased gene and protein expression for Type I collagen, there is also up-regulation of glycosaminoglycans and various growth factors including vascular endothelial growth factor, FGF-7, and epidermal growth factor.^{10,11} Based on histologic analyses 1 year after a series of microneedling sessions, increased collagen deposition in the reticular dermis with a normal lattice architecture, increased elastic fiber deposition, a thickened epidermis (granular layer hyperplasia), and a normal stratum corneum and rete ridges have been shown.^{13–15} In another study, Aust and colleagues¹¹ demonstrated up-regulation of TGF- β 3 which promotes regeneration and scarless wound healing. The altered ratio after microneedling of TGF- β 3 over TGF- β 1 and TGF- β 2 (the latter being responsible for fibrotic scarring) may partially explain the beneficial basis of this procedure.¹¹

Device Specifics

There are many microneedling devices on the market, each of which creates numerous epidermal and dermal microwounds to stimulate collagen production. A range of fixed needle rollers and electric-powered pen devices with disposable sterile needle tips are available.^{9,16} These devices vary based on the needle length, quantity, diameter, configuration, and material. Manual rollers and electric-powered pens are operated by gliding perpendicularly over the skin surface until fine pinpoint bleeding is achieved.^{9,16–19} Electric pens offer several advantages over roller drum devices including the ability to easily adjust their operating speeds and penetration depths thereby permitting treatment of large surface areas efficiently and at varying needle depths as necessary. The disposable needle tips limit the risk of infection and also permit treatment of small focal lesions such as traumatic scars or upper lip rhytides which would be hard to do to accomplish with a roller drum.

Optimal clinical outcomes are achieved when needle depths are adjusted to the specific skin location (and thickness). For example, thick sebaceous skin will require deeper needle penetration in comparison with thin periocular skin. One study found that needle

penetration depth up to 1.0 mm was consistent with the specific adjustable setting on the electric-powered microneedling device, whereas needle lengths exceeding 1.0 mm (e.g., 1.5 or 2 mm) demonstrated shallower dermal penetration than anticipated.²⁰ An additional study demonstrated that a needle length of 3 mm penetrated to a depth of 1.5 to 2 mm, further supporting that increased needle lengths may be inaccurate to the specific selected depth.¹⁶

Since it is well known that vitamins A and C are vital for production of new collagen and protection of existing collagen,^{6,21,22} it is not surprising that combining microneedling with topical antioxidants have been shown to enhance the regenerative process of microneedling-induced wound healing. Aust and colleagues¹⁰ demonstrated a 140% increase in epidermal thickness after the combination of microneedling and topical vitamin A and C use over a period of 8 weeks (compared to a 22% epidermal thickness increase with topical antioxidant use alone). Pretreatment priming of the skin with antioxidants may also serve to increase gene and protein expression responsible for skin regeneration.¹⁰ Caution is advised with concomitant use of topical products of any type during a microneedling procedure due to the risk of granuloma formation. In a case series published in 2014, 3 patients developed biopsy-proven foreign-body type granulomas after the application of topical vitamin C during microneedling.²³ Subsequent patch testing in these patients demonstrated a positive hypersensitivity to various chemicals within the topical vitamin C formulation.²³

Dermatologic Applications

Microneedling has been extensively studied over the past decade with several published reports describing clinical efficacy, treatment specifics, histologic analyses, and combination therapies.²⁴ The most well-described indications for microneedling in dermatology include acne scarring, periorbital and perioral rhytides, skin laxity, post-traumatic/burn scars, and striae distensae.²⁵

Scars and Striae

More publications have outlined the use of microneedling for acne scarring than for any other skin condition.^{26–28} Clinical improvement of acne scars has

been substantiated by histologic skin changes.

Although various microneedling protocols have been outlined, a series of 3 to 5 treatments at 2- to 4-week intervals typically produce clinical improvements ranging from 50% to 70%.^{29,30} Rolling and boxcar acne scars have been shown to be more effectively treated than ice pick scars.²⁵ Similarly, other types of atrophic scars and burn scar contractures and striae distensae have also been improved with microneedling.^{31–34} Unlike full ablative laser skin resurfacing which is typically limited to treatment of full cosmetic units, it is possible to microneedle discrete areas of scarring without producing lines of demarcation between treated and nontreated areas.

Rhytides and Skin Rejuvenation

Microneedling has been proven effective in the treatment of facial rhytides in multiple publications.^{35–37} Fabbrocini and colleagues demonstrated perioral wrinkle severity improving by 2 points on the Wrinkle Severity Rating Scale after microneedling treatment.³⁵ Significant increases in collagen Type I, III, and VII as well as elevated levels of tropoelastin was reported by El-Domyati et al. after a series of 6 microneedling sessions.³⁶ The amount of dermal collagen was shown to increase with cumulative treatment.³⁶ The reorganization of existing collagen fibers and simultaneous increased production of new structural dermal components after microneedling is believed to be responsible for the observed skin tightening. The resultant increase in both dermal collagen and elastic fibers further supports the mechanism by which rhytides are reduced and softened after a series of microneedling sessions are performed. These findings indicate a lag time of at least 6 to 8 weeks from initiation of treatment to clinically apparent results from dermal collagen production. It has, thus, become the protocol for patients to receive a series of 3 to 6 at biweekly or monthly microneedling sessions to achieve optimal improvement of rhytides and skin rejuvenation.

Treatment Protocol

Because of the slow integration of microneedling in many dermatology practices, the authors sought to increase the awareness of the procedural technique to

increase the popularity of this treatment entity.

Although the microneedling procedure often varies by practitioners, the technique the authors have developed produces substantial clinical results with controlled dermal wounding while stimulating the wound healing cascade necessary for adequate collagen production. The use of an electric-powered microneedling device (e.g., Eclipse or Collagen P.I.N.) with disposable needle tips (containing 12–36 needles), adjustable speeds, and depths of penetration (1–3 mm) is a relatively easy treatment to incorporate into a cosmetic dermatology practice. Although device design varies by manufacturer, all of the available handheld devices work similarly. The treatment protocol can be applied to any electric-powered microneedling device with adjustable depth and speed (Table 1).

Pretreatment Recommendation

All patients may continue the use of any home skin care regimen (including retinoids, antioxidants, and growth factors) up until the time of the procedure. Oral anticoagulants do not need to be discontinued as the risk of uncontrollable bleeding during the

microneedling treatment is negligible. Since the microneedling procedure is often used in combination with other treatments such as injections of hyaluronic acid filler and chemical peels and various dermatologic lasers, no “wash out” period is necessary before initiation of treatment. It is, however, recommended that for same day treatments, the order of treatments be applied from deep to superficial (e.g., injectables before microneedling and/or laser irradiation) to maintain visual landmarks and prevent diffusion of injectables caused by tissue edema or bleeding.

Clinical Assessment

In addition to evaluation of the treatment area(s), a meticulous visual assessment of overall skin quality and texture should be made. A thorough synopsis of the procedure, including the risks, benefits, and alternative treatment options should be discussed with the patient. A consent form should be reviewed in its entirety, leaving time for patient questions before treatment. Photography of treatment areas should be performed before each session to adequately assess clinical progress. Comparison of baseline and post-treatment photographs, as well as clear expectations of the anticipated number treatments, is vital to patient satisfaction and facilitates an appreciation of clinical outcomes.

Treatment Contraindications

Contraindications to microneedling treatment are limited. Contraindications include inflammatory acne, active herpes labialis or other local infection within the treatment area, keloidal predisposition, and immunosuppression.²⁵ In addition, care should be taken with concomitant microneedling near botulinum toxin injection sites to avoid potential unwanted toxin diffusion.

Pretreatment Considerations

Although any skin phototype can be treated, it is recommended that treatment be delayed in patients with a history of recent sun exposure (or who are visibly tanned) until all traces of suntan have faded to avoid post-treatment dyspigmentation. Individuals with a history of oral herpes labialis may be at increased risk

TABLE 1. Microneedling at a Glance

<ul style="list-style-type: none"> ● Treatable conditions: scars (atrophic/burn/other), rhytides, skin laxity, striae ● Contraindications: active infection, acne, keloid predisposition, immunosuppression ● Treatment preparation: mild cleanser, topical 30% lidocaine, hyaluronic acid gel ● Technique <ul style="list-style-type: none"> Perpendicular device placement with manual skin traction for smooth delivery of microneedles Multidirectional placement (cross-hatching) of microneedle passes Use pinpoint bleeding as guide to treatment end point Manual pressure with ice water compresses for hemostasis ● Post-treatment care <ul style="list-style-type: none"> 0–4 h: hyaluronic acid gel 4–72 h: 1% hydrocortisone/nonallergic moisturizer/physical sunblock SPF 30+ 48 h: makeup application 5–7 h: resume active product use ● Side effects: mild erythema, edema, skin flaking × 48–72 h ● Repeat treatments: biweekly to monthly × 3–6 sessions; maintenance (variable)

for viral reactivation during the post-treatment period. In these patients, a 1-week course of oral antiviral therapy as a prophylactic measure (beginning on the day of treatment) is recommended to minimize this complication. In addition, microneedling over any inflammatory acneiform lesions may predispose the patient to the development of bacterial microabscesses or granulomas. As such, avoidance of treatment in patients with active acne or other inflammatory lesions is recommended.

Skin Preparation and Anesthesia

Meticulous skin preparation is important to decrease the risk of superficial skin infections. A gentle skin cleanser to remove makeup and debris from the skin's surface should be used before application of a topical anesthetic cream or gel to the treatment area(s). The authors typically apply a compounded 30% lidocaine cream (nonoccluded) for 20 to 30 minutes which is removed with water-soaked gauze and alcohol prep immediately before the microneedling procedure.

Device Preparation

A handheld microneedling device (e.g., Collagen P.I. N; Induction Therapies, Louisville, KY or Eclipse MicroPen Elite; Eclipse Aesthetics, Dallas, TX) powered by a battery pack or alternating current power cord is used at adjustable depth settings ranging from 0 to 3.0 mm. When used with corded power, the device speed can be adjusted, ranging from 10,250 to 23,750 rpm. With battery power, the device speed is fixed at 13,500 rpm. Sterile disposable needle cartridges (12 array count/32 gauge and 36 array count/30 gauge) can be used to tailor therapy based on the specific treatment location. In general, skin on the forehead, lower eyelids, and nasal bridge are treated with needle depths ranging from 0.5 to 1.0 mm, whereas the cheeks, perioral regions, and scars or striae in various body parts are typically treated with needle depths 1.5 to 3.0 mm. As a general rule of thumb, thicker or more fibrotic skin can be treated with deeper needle depths.

Treatment Technique

Depending on the specific location to be treated, it is often helpful to divide the region into quadrants. For

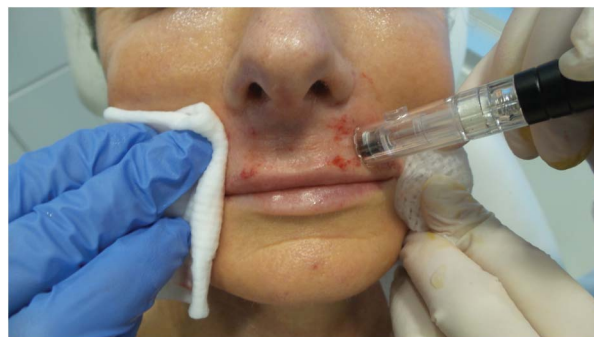

Figure 1. Microneedling device is placed perpendicular to the skin's surface with a thin layer of hyaluronic acid gel. Manual skin traction facilitates smooth gliding of hand-piece and uniform delivery of microneedles across the skin.

example, when treating the perioral region, the left upper, left lower, right upper, and right lower regions can be treated individually for more precise and uniform microneedling coverage. Gentle traction of the skin with one hand while simultaneously lowering the microneedling device perpendicular to the skin with the other hand assists the smooth delivery of microneedles into the skin (Figure 1). It is important to apply sufficient hyaluronic gel (supplied by the device company) on the treatment area surface to facilitate the gliding action of the microneedling device and to prevent untoward injury to the overlying epidermis. The treatment technique involves a combination of horizontal, vertical, and oblique device passes over the treatment areas, repeating approximately 3 to 6 times or until fine pinpoint bleeding is observed (Figure 2). When treating deep rhytides or scars, a "rocking" or

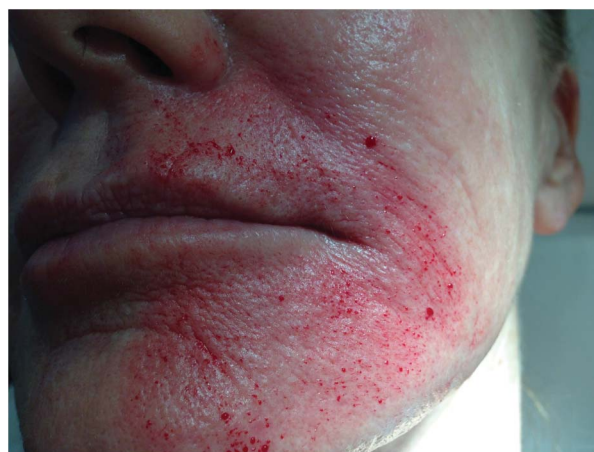

Figure 2. Pinpoint bleeding serves as a guide to indicate treatment end point.

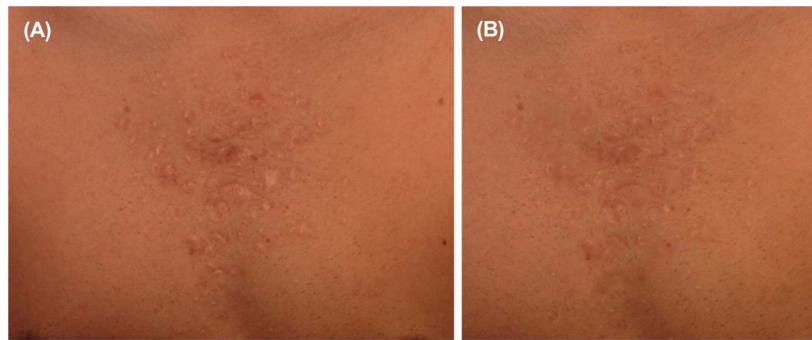


Figure 3. Atrophic acne scars before (A) and after 3 microneedling sessions at monthly intervals in the absence of concomitant treatments (B).

“stamping” technique can be used to increase the density of microneedling channels created. Since needle lengths exceeding 1.0 mm may not penetrate to the corresponding dermal depth, it is useful to use pinpoint bleeding as the clinical end point of treatment.

When the clinical end point of uniform pinpoint bleeding has been achieved, ice water-soaked sterile gauze can be applied to remove excess blood and hyaluronic gel. Treatment can then be pursued in an adjacent treatment area or quadrant. The use of tap water is discouraged because of its possible contamination with pathogenic organisms which could potentially increase the risk of infection in the treatment areas. If any bleeding persists after cleansing the treatment area, gentle pressure with dry sterile gauze should be applied for several minutes. A thin layer of hyaluronic acid gel can then be applied to the treatment region and allowed to dry.

Postprocedure Recommendations

For the first 4 hours after the procedure, the patient is instructed to apply the provided sample of hyaluronic acid gel to the skin. After 4 hours, a 1% hydrocortisone cream or a nonallergenic moisturizing cream can

be applied to the treatment regions 2 to 4 times daily for 2 to 3 days. The use of a nonchemical (or physical) sunblock with SPF 30 or higher is advocated (on top of the moisturizer) during the first post-treatment week. Application of makeup may be resumed 2 days after the procedure and any active skin care products that the patient used pretreatment can be resumed in 5 to 7 days (when all traces of skin erythema have resolved). Microneedling treatment sessions are generally recommended at biweekly to monthly time intervals until the desired clinical results are achieved (Figures 3 and 4). Some patients elect to receive ongoing (single) microneedling treatment sessions on an annual or semiannual basis to maintain and/or enhance their cosmetic outcomes.

Side Effects and Complications

Microneedling is considered a noninvasive esthetic procedure and has a low rate of associated adverse effects. The most common and expected side effects of treatment include mild erythema, localized edema, and skin flaking, which typically resolves within 48 to 72 hours. Pinpoint bleeding is self-limited and resolves within minutes after the procedure with application of gentle manual pressure and ice water-soaked gauze.

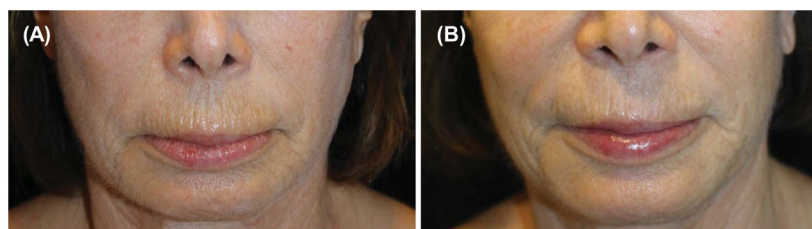


Figure 4. Perioral rhytides before (A) and after 3 microneedling sessions at monthly intervals without other treatment modalities (B).

Dyspigmentation was once a feared complication in darker skin phototypes (Fitzpatrick IV, V, VI), but is rarely seen in the absence of ultraviolet light exposure on microneedled treatment areas. A histologic analysis of skin melanocytes 24 hours after microneedling demonstrated neither change in melanocyte number nor any epidermal disruption.⁷ In a case series published in 2014, 3 patients developed granulomas after the use of topical vitamin C serum during the microneedling session.²³ The use of topical medications with or immediately after a microneedling procedure may increase the incidence of adverse effects because of the creation of channels within the epidermis and dermis that acts as a gateway into the body allowing for the development of an immune response to immunogenic particles.³⁸ It is, thus, imperative to counsel patients on the avoidance of non-prescribed skin care products for the first week after the microneedling procedure as these may potentially induce a local or systemic hypersensitivity reaction. In addition, physicians need to use extreme caution when applying topical agents to the skin immediately after the microneedling session to avoid such complications. More research is needed on transdermal substances and delivery vehicles to help minimize these risks.

Conclusion

From the introduction of microneedling by Orentreich and colleagues³ using the concept of subcision, microneedling quickly morphed into a dynamic procedure using handheld electric-powered devices. Microneedling is a safe, minimally invasive, and effective esthetic treatment modality for numerous dermatologic conditions including acne and other scars, rhytides, and striae. With its fast post-treatment recovery, limited side effect profile, and impressive clinical results, microneedling is a valuable alternative to more invasive procedures such as laser skin resurfacing and deep chemical peeling. In addition, microneedling has demonstrated definitive histologic changes that are directly responsible for the clinical improvement observed.

This manuscript highlights the science behind this promising procedure and provides a simple step-by-step treatment protocol for practical use. Additional long-term studies are needed to determine the duration of

improvement and the ideal treatment parameters to achieve maximum clinical results with minimal recovery.

References

1. Aslam A, Alster TS. Evolution of laser skin resurfacing: from scanning to fractional technology. *Dermatol Surg* 2014;40:1163–72.
2. American Society of Plastic Surgeons. American Society of Plastic Surgeons releases report showing shift in procedures. In: *New Statistics Reflect the Changing Face of Plastic Surgery*. American Society of Plastic Surgeons. Available from: <https://www.plasticsurgery.org/news/press-releases/new-statistics-reflect-the-changing-face-of-plastic-surgery>. Accessed February 2, 2017.
3. Orentreich DS, Orentreich N. Subcutaneous incisionless (subcision) surgery for the correction of depressed scars and wrinkles. *Dermatol Surg* 1995;21:543–9.
4. Camirand A, Doucet J. Needle dermabrasion. *Aesth Plast Surg* 1997; 21:48–51.
5. Fernandes D. Percutaneous collagen induction: an alternative to laser resurfacing. *Aesth Surg J* 2002;22:307–9.
6. Fernandes D. Minimally invasive percutaneous collagen induction. *Oral Maxillofac Surg Clin N Am* 2005;17:51–63.
7. Aust MC, Reimers K, Repenning C, Stahl F, et al. Percutaneous collagen induction: minimally invasive skin rejuvenation without risk of hyperpigmentation—fact or fiction? *Plast Reconstr Surg* 2008;122:1553–63.
8. Fabbrocini G, Gardella N, Monfrecola A, Proietti I, et al. Acne scarring treatment using skin needling. *Clin Exp Dermatol* 2009;34:874–9.
9. Doddaballapur S. Microneedling with dermaroller. *J Cutan Aesthet Surg* 2009;2:110–1.
10. Aust MC, Reimers K, Kaplan HM, Stahl F, et al. Percutaneous collagen induction-regeneration in place of cicatrization? *J Plast Reconstr Aesthet Surg* 2011;64:97–107.
11. Aust MC, Reimers K, Gohritz A, Jahn S, et al. Percutaneous collagen induction. Scarless skin rejuvenation: fact or fiction? *Clin Exp Dermatol* 2010;35:437–9.
12. Falabella AF, Falanga V. Wound healing. In: *The Biology of the Skin*. New York, NY: Parthenon; 2001:281–99.
13. Schwarz M, Laaff H. A prospective controlled assessment of microneedling with the Dermaroller device. *Plast Reconstr Surg* 2011; 127:146e–148e.
14. Aust MC, Knobloch K, Reimers K, Redeker J, et al. Percutaneous collagen induction therapy: an alternative treatment for burn scars. *Burns* 2010;36:836–43.
15. Aust MC, Fernandes D, Kolokythas P, Kaplan HM, et al. Percutaneous collagen induction therapy: an alternative treatment for scars, wrinkles, and skin laxity. *Plast Reconstr Surg* 2008;121:1421–9.
16. Sasaki GH. Micro-needling depth penetration, presence of pigment particles, and fluorescein-stained platelets: clinical usage for aesthetic concerns. *Aesthet Surg J* 2016;37:71–83.
17. Badran MM, Kuntsche J, Fahr A. Skin penetration enhancement by a microneedle device (Dermaroller) in vitro: dependency on needle size and applied formulation. *Eur J Pharm Sci* 2009;36:511–23.
18. Bal SM, Caussin J, Pavel S, Bouwstra JA. In vivo assessment of safety of microneedle arrays in human skin. *Eur J Pharm Sci* 2008;35:193–202.
19. Gupta J, Gill HS, Andrews SN, Prausnitz MR. Kinetics of skin resealing after insertion of microneedles in human subjects. *J Control Release* 2011;154:148–55.

20. Lima EVA, Lima MA, Takano D. Microneedling: experimental study and classification of the resulting injury. *Surg Cosmet Dermatol* 2013;5:110–4.
21. Chapellier B, Mark M, Messaddeq N, Calléja C, et al. Physiological and retinoid-induced proliferations of epidermis basal keratinocytes are differently controlled. *EMBO J* 2002;21:3402–13.
22. Nusgens BV, Humbert P, Rougier A, Colige AC, et al. Topically applied vitamin C enhances the mRNA level of collagens I and III, their processing enzymes and tissue inhibitor of matrix metalloproteinase 1 in the human dermis. *J Invest Dermatol* 2001;116:853–9.
23. Soltani-Arabshahi R, Wong JW, Duffy KL, Powell DL. Facial allergic granulomatous reaction and systemic hypersensitivity associated with microneedle therapy for skin rejuvenation. *JAMA Dermatol* 2014;150:68–72.
24. Hou A, Cohen B, Haimovic A, Elbuluk N. Microneedling: a comprehensive review. *Dermatol Surg* 2016;42:1–19.
25. Singh A, Yadav S. Microneedling: advances and widening horizons. *Indian Dermatol Online J* 2016;7:244–54.
26. Harris AG, Murrell D. Skin needling as a treatment for acne scarring: an up-to-date review of the literature. *Int J Women Dermatol* 2015;1:77–81.
27. El-Domyati M, Barakat M, Awad S, Medhat W, et al. Microneedling therapy for atrophic acne scars: an objective evaluation. *Clin Aest Dermatol* 2015;8:36–42.
28. Fabbrocini G, DeVita V, Monfrecola A, De Padova MP, et al. Percutaneous collagen induction: an effective and safe treatment for post-acne scarring in different skin phototypes. *J Dermatol Treat* 2014;25:147–52.
29. Dogra S, Yadav S, Sarangal R. Microneedling for acne scars in Asian skin type: an effective low cost treatment modality. *J Cosmet Dermatol* 2014;13:180–7.
30. Alam M, Han S, Pongprutthipan M, Disphanurat W, et al. Efficacy of a needling device for the treatment of acne scars: a randomized clinical trial. *JAMA Dermatol* 2014;150:844–9.
31. Cho SB, Lee SJ, Kang JM, Kim YK, et al. The treatment of burn scar-induced contracture with the pinhole method and collagen induction therapy: a case report. *J Eur Acad Dermatol Venerol* 2008;22:513–4.
32. Majid I. Microneedling therapy in atrophic facial scars: an objective assessment. *J Cutan Aesthet Surg* 2009;2:26–30.
33. Aust MC, Knobloch K, Vogt PM. Percutaneous collagen induction therapy as a novel therapeutic option for striae distensae. *Plast Reconstr Surg* 2010;126:219e–220e.
34. Park KY, Kim HK, Kim SE, Kim BJ, et al. Treatment of striae distensae using needling therapy: a pilot study. *Dermatol Surg* 2012;38:1823–8.
35. Fabbrocini G, De Vita V, Pastore F, Annunziata MC, et al. Collagen induction therapy for the treatment of upper lip wrinkles. *J Dermatolog Treat* 2012;23:144–52.
36. El-Domyati M, Barakat M, Awad S, Medhat W, et al. Multiple microneedling sessions for minimally invasive facial rejuvenation: an objective assessment. *Int J Dermatol* 2015;54:1361–9.
37. Lee HJ, Lee EG, Kang S, Sung JH, et al. Efficacy of microneedling plus human stem cell conditioned medium for skin rejuvenation: a randomized, controlled, blinded split-face study. *Ann Dermatol* 2014;26:584–91.
38. Kontochristopoulos G, Kouris A, Platsidaki E, Markantoni V, et al. Combination of microneedling and 10% trichloroacetic acid peels in the management of infraorbital dark circles. *J Cosmet Laser Ther* 2016;18:289–92.

Address correspondence and reprint requests to: Tina S. Alster, MD, Washington Institute of Dermatologic Laser Surgery, 1430 K Street NW, #200, Washington, DC 20005, or e-mail: talster@skinlaser.com