



## Detection Of Some Hormonal And Enzymatic Disorders Associated To Experimentally Iodine Induced Hyperthyroidism.



CrossMark

Doaa S Foda<sup>1\*</sup>, Noha E Ibrahim<sup>2</sup>

<sup>1</sup>Therapeutic Chemistry Department, Pharmaceutical Industries Division, National Research Centre, 33 El Bohouth St., P. O. 12622. Dokki, Giza, Egypt.

<sup>2</sup>Microbial Biotechnology Department, Genetic Engineering and Biotechnology Division, National Research Centre, 33 El Bohouth St., P. O. 12622 Dokki, Giza, Egypt.

### Abstract

This study aimed to observe and report the status and the reaction of the body organs in case of administration of excess iodine. This was achieved by the intraperitoneal injection of KI for female mice. Results showed that the different organs respond to KI administration with different reactions. The thyroid gland expressed a gradual increase in serum thyroid hormones (T4&T3) which was accompanied with a detected significant decrease in serum TSH in addition to an observed histological changes in the thyroid tissue.

Liver was the most apparent organ that was affected by excess KI administration followed by the brain through expressing increasing significant T3 levels in tissues compared to control. On the other hand, the heart and the kidneys tissues displayed non significant decrease in T3 levels. The study evaluated some tissue specific enzymes which showed significant biochemical abnormalities in organs' functions.

Our data detected the features of a subclinical hyperthyroid case and express the initiation of an iodine induced hyperthyroidism pattern.

**Keywords:** Excess KI administration; T3 levels in tissues; Tissues function abnormalities; Subclinical hyperthyroidism.

### 1. Introduction

Ingestion of micronutrients and trace elements is considered an important factor for the maintenance of healthy life. Avoiding excess and deficiency of these elements is a matter of concern for humans and animals [1]. Iodine represents an essential micronutrient for performing thyroid functions which in turn controls all the body tissues metabolism including energy stores, body temperature and maintenance of body organs' functions [2, 3]. Iodine is obtained mainly from sea food, plants and animal products in addition to fortified food, salt and many drugs [4, 5]. It can display a powerful antioxidant role in the body if it is accurately monitored and directed for serving the cells compartments [6].

Both high and low iodine ingestion was reported to cause thyroid dysfunction in vertebrates leading to abnormal thyroid hormones (THs) level in serum [7, 8, 9]. Detecting the serum levels of (THs) during thyroid diseases is a routine test but it does not reflect the thyroid hormones level in various body organs. Local production of thyroid hormones in tissues in

case of insufficiency of (THs) is essential for influencing target genes and is controlled by the interactions between deiodinases enzymes that are responsible for activating and inactivating of (THs) in tissues [10].

Many factors control the action of thyroid hormones on various tissues such as tissue receptors expression, membrane transporters in addition to the activity of the deiodinases enzymes and the genetic and non genetic responses due to the nuclear transcriptions factors that are controlled by the free T3 hormone [11, 12, 13].

One of the diseases that can be caused due to administration of excess iodine is the iodine induced hyperthyroidism (IHH) disease. The disease is caused due to excess iodine intake mainly in iodine deficient areas in spite of the thyroid gland adaption for storing high amounts of iodine for maintenance of (THs) normal levels [14, 5, 15]. Administration of excess iodine is one of the obstacles that face geriatrics and paediatrics due to subjection to daily or promptly supplementation of iodine through food or drugs.

\*Corresponding author e-mail: [d.foda2018@gmail.com](mailto:d.foda2018@gmail.com); (Doaa S Foda).

Receive Date: 16 February 2021, Revise Date: 06 March 2021, Accept Date: 07 March 2021

DOI: 10.21608/EJCHEM.2021.63609.3361

©2021 National Information and Documentation Center (NIDOC)

Elderly population as well as young children can suffer from (IIH) complications and thyroid dysfunction. IIH can be induced also by the intake of high doses of iodine in a short time or by daily doses for a long duration [9, 16, 17]. The disease may lead to many dangerous complications represented in deteriorations in heart and brain tissues.

In spite of the incidence of the disease among different ages in humans, up till now there is no experimental animal model in the laboratory to represent the disease case.

On the other hand, excess iodine intake can also cause iodine induced hypothyroidism disease [18]. Both diseases (hyper- and hypo- thyroidism) can cause enlargement of the thyroid (goiter) [19, 20].

So, this study aimed to observe and record the status of different body organs represented by the thyroid gland, the brain, the heart, the liver and the kidneys during subjection to excess KI administration as a source of iodine in female albino mice and determining the severity of the complications on the short run.

## 2-Materials and methods

### I-Materials

#### 1.Animals

Twenty eight adult female Swiss albino mice weighing about 25-30g were obtained from the animal house unit in the National Research Centre, Giza, Egypt. The animals were housed under standard laboratory conditions (12 h light and 12 h dark) in a room of controlled temperature (24°C) during the experimental period. The mice were provided *ad libitum* with tap water and fed with standard commercial mouse chow.

#### 2. Chemicals and kits

All chemicals used in the experiments were of analytical grade. Potassium iodide (KI) was obtained from El-Gomhorea Company, Egypt.

Thyroid stimulating hormone; (TSH) and thyroid hormones (thyroxine; (T4), and tri-iodothyronin; (T3)) detection kits were purchased from Abia Diagnostic Company, GmbH, Berlin.

Kits used for the quantitative determination of Alkaline phosphatase (ALP), Acid phosphatase (ACP), Alanine aminotransferase (ALT) , Aspartate aminotranferase (AST), Lactate dehydrogenase (LDH), Creatinine, Total antioxidant capacity (TOAC) and Glucose were purchased from Egyptian Company for Biotechnology, Egypt, Biodiagnostic Company and Fisher Diagnostics, USA.

Kits used for the quantitative determination of Troponin I and Angiotensin Converting Enzyme (ACE) were purchased from Roche Diagnostics, GmbH, Germany.

## II- Experimental Methods

### i-Preparing different doses for detecting iodine intolerance in mice.

-In our study, the daily oral KI dose (0.2 mg KI/mouse i.e 0.0002 gram/KI/mouse) used by Vecchiatti *et al* [21] was chosen and was modified as follows:

The dose was multiplied hundred (100) times and was injected intraperitoneally for female mice to obtain maximum KI dose equals 0.02gram/mouse.

-Different doses of KI was prepared and injected intraperitoneally to about 3 female mice for each tested dose to detect the iodine intolerance.

### ii- Experimental dose preparation.

Stock Potassium iodide solution was prepared by dissolving the salt in sterilized water. Potassium iodide solution was injected intraperitoneally at a dose of 0.013 gram KI per mouse three days every week.

### iii-Experimental design

-After one week of acclimation, the animals were divided into two groups.

-The 1<sup>st</sup> group (12 mice) served as a negative control and did not receive any supplementations.

-The 2<sup>nd</sup> group (16 mice) served as the treated group and received KI solution intraperitoneally at a dose of 0.013 gram KI per mouse three times weekly for forty days.

-The mice were dissected and the blood was taken from the retro-orbital plexus of the eyes and centrifuged at 4000 r.p.m. for 10 min obtaining the serum. Serum was stored at -20°C till subjected to the biochemical studies of thyroid hormones and different parameters.

-The thyroid gland was removed and cleaned then was fixed in 10% formalin and was prepared for histological examinations.

### Preparation of tissue homogenates.

-The livers, the brains, the hearts and the kidneys were separated, cleaned and washed in Na Cl solution (0.9%) . The organs were then weighed and homogenized by a using a porcelain mortar. The homogenized organs were centrifuged at 4000 r.p.m. for 10 minutes.

-The supernatant was then separated and was stored at -20 °C till subjected to the biochemical studies of thyroid hormones and different enzymes.

### III- Biochemical analysis

#### -Serum and tissue thyroid Hormones assay.

Thyroid hormones were detected in serum and tissues quantitatively as an immunoassay by ELISA technique using the automated ELISA reader Expert Plus UV, biochrom., G 020151.

TSH was estimated as the method described by Fisher [22]. (T4) and (T3) were detected as shown by Nelson & Wilcox [23] and Ekins [24] respectively.

#### -Serum total antioxidant capacity, glucose and creatinine assays.

Total antioxidant capacity and random glucose were estimated as a quantitative enzymatic colorimetric method in serum according to Koracevic *et al* [25] and Trinder [26] respectively. Serum creatinine was measured quantitatively by a colorimetric method as described by Bartles *et al* [27]. Quantitative determinations were performed by using Shimadzu spectrophotometer, Japan.

#### -Tissue enzymatic studies.

Alanine and aspartate aminotransferases were determined according to the method described by Reitman & Frankel [28]. Alkaline phosphatase was determined as denoted by Thomas [29]. Acid phosphatase was measured according to Kaplan & Pesce [30]. Lactate dehydrogenase was detected as described by Zimmerman & Henery [31]. Troponin I was determined as described by Apple & Wu [32] while the angiotensin converting enzyme was detected according to the method of Tietz [33].

#### IV-Histological studies

Specimens of thyroid gland were taken in a tissue block composed of thyroid gland, trachea and surrounding connective tissue and fixed in 10% formalin and processed for paraffin sections of 4 micron thickness. The sections were stained with Hematoxylin and Eosin. The method was performed as described by Bancroft *et al* [34].

#### V-Statistical analysis

**Table (1): Effect of excess KI administration on serum thyroid hormones and thyroid stimulating hormone.**

	Serum TSH ( $\mu$ IU/ml)	Serum T4 (nmol/l)	Serum T3 (ng/ml)	T3/T4
KI treated group n=8	0.252 $\pm$ 0.11***	47.50 $\pm$ 8.31	1.46 $\pm$ 0.24	0.0321 $\pm$ 0.01
Control n=8	0.842 $\pm$ 0.20	45.33 $\pm$ 1.05	1.24 $\pm$ 0.27	0.028 $\pm$ 0.004
%change compared to control	-70	+ 4.8	+17.7	+11.11

Data represented as mean  $\pm$  S.D. P\*\*\* significant at  $P \leq 0.001$  compared to control group.

**Table (2): Effect of excess KI administration on thyroid hormones in tissue homogenates of different organs.**

	T4 (nmol/g.tissue)		T3 (ng/ g.tissue)	
	KI treated group	Control group	KI treated Group	Control group
brain n=8	0.0165 $\pm$ 0.028	0.05 $\pm$ 0.07	11.6 $\pm$ 0.57*	9.45 $\pm$ 1.41
heart n=6	0.0165 $\pm$ 0.028	ND	9.05 $\pm$ 0.7	9.35 $\pm$ 0.24
Kidney n=8	0.05 $\pm$ 0.086	0.1 $\pm$ 0.141	5.76 $\pm$ 3.09	6.2 $\pm$ 0.49
liver n=8	ND	0.025 $\pm$ 0.035	4 $\pm$ 1.3*	1.8 $\pm$ 1.02

Data represented as mean  $\pm$  S.D, P\* significant  $\leq 0.05$ . P\* significant compared to the corresponding control. ND means non detected.

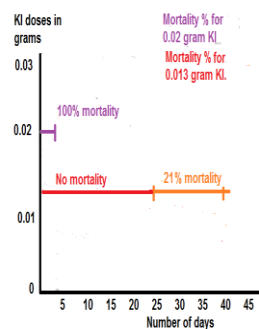
**Table (3): Percent change of T3 level in different tissues.**

Organ	Brain	Heart	Kidney	Liver
% change compared to control	+22.75*	-3.20	-7.09	+122.22*

All values were expressed as the mean  $\pm$  SD. Significant differences between the groups were statistically analyzed using t test. A P value of 0.05 or less was considered statistically significant

### 3-Results

#### I-Iodine intolerance results in mice.



**Figure (1)** represented the effect of different doses of KI showing the iodine intolerance in mice.

Applying the intraperitoneal injection of 0.02 grams per mouse lead to 100% mortality of the mice after three days from the injection.

By decreasing the dose to 0.013gram per mouse, it was observed that mortality percent was null for a duration of twenty five days and then existed again in mice and reached about 21% from the total number of mice in the last fifteen days.

So our choice was directed to the dose of 0.013 gram KI per mouse as it was considered a suitable dose to perform an excess KI administration pattern.

**Table (4): Effect of excess KI administration on some functioning enzymes in tissue homogenates of liver and brain.**

Parameters Groups	ALT in liver homogenate (U/g.tissue)	AST in liver homogenate (U/g.tissue)	ALP in brain homogenate (U/g.tissue)	ACP in brain homogenate (U/g.tissue)
KI treated group. n=5	604.42±18.97*	560.14±3.7	402.50±109.88*	18.75±5.13
Control n=4	558.11±30.27	588.95±41.72	260.0±29.72	19.75±3.59
% Change	+ 8.3	-4.9	+54.80	-5.06

Data represented as mean ±S.D. *P*\* significant at  $P \leq 0.05$  compared to control group.

**Table (5): Effect of excess KI administration on some functioning enzymes in tissue homogenates of heart and kidneys.**

Parameters Groups	LDH in heart homogenate (U/g.tissue)	Troponin I in heart homogenate (ng/g.tissue).	Troponin I in serum (ng/ml).	Angiotensin converting enzyme (ACE) in kidney homogenate (U/g.tissue)
KI treated group. n=5 - 8	46.66±23.62*	Not detected >125	0.1±0.01	270±45.46*
Control n=5 - 8	130.0±13.22	Not detected >125	0.1±0.01	108.75±99.36
% Change	-64.10	-	No change	+148.3

Data represented as mean ±S.D. *P*\* significant at  $P \leq 0.05$  compared to control group.

**Table (6): Effect of excess KI administration on some serum parameters.**

Parameters Groups	Serum TOAC (mM/L)	Random serum glucose (mg/dl)	Serum creatinine mg/dl)
KI treated group n=6	0.163±0.03*	261.72±48.19*	2.66±1.20
Control n=6	0.250±0.05	148.14±7.40	1.60±0.88
%change compared to control	- 34.8	+ 76.6	+66.25

Data represented as mean ±S.D. *P*\* significant at  $P \leq 0.05$  compared to control group.

## II- Biochemical studies

Table (1) showed significant decreasing level of serum TSH (-70%). This decrease was accompanied with a non significant increase in both serum T4 (+4.8) and T3 (+17.7) compared to control.

Table (2) showed the low and non detected levels of T4 in the tissue homogenates of the four organs. On the other hand, there were a great variability in T3 levels among these organs. Significant increase was observed in the liver and the brain homogenates while there was a non significant decrease in heart and kidney tissues in T3 concentration compared to control.

These data were clarified by calculating the percent change in T3 levels for each organ compared to its control as shown in table (3).

Tables (4 &5) showed the onset of all the organs dysfunction at the same time. Two parameters for each organ were tested and compared to their corresponding control. Tissue aminotransferases level in the liver indicated a significant increase in ALT (a specific marker for liver abnormality) by a percent change equal +8.3 and non significant decrease in AST.

In the brain tissue, ALP and ACP were not equally affected. A high significant increase in ALP was observed with a percent change equal +54.80. On the other hand, there was a non significant decrease in ACP.

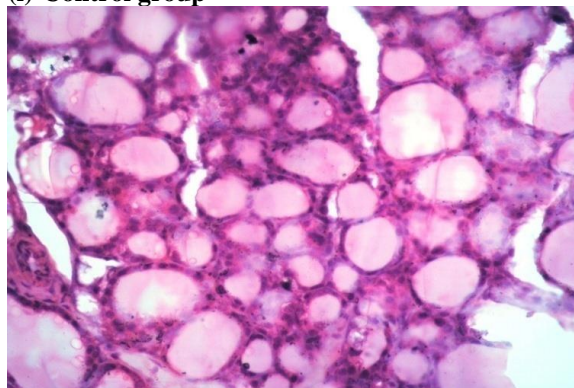
The abnormalities in heart and kidney tissues were shown in table (5). The data showed a significant decrease in LDH level in the heart tissue by a percent change equal -64.10. The study tried to detect troponin I in heart tissue but its level was more than the spectrophotometer limits >125 ng/g.tissue in both cases. So serum levels of troponin I was detected instead, recording no change between the treated and the control groups.

Finally, by observing ACE in kidney tissues, we can deduce the presence of a detectable kidney function abnormality. ACE recorded significant increasing levels in kidney tissues with a percent change equal +148.3 compared to its control.

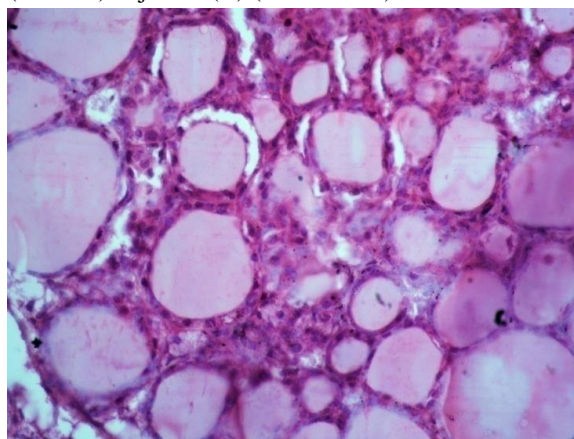
Table (6) showed some affected serum parameters associated with the excess of KI administration. Significant increasing levels were observed in case of random glucose that were accompanied with significant decreasing levels in total antioxidant capacity (TOAC) in the KI injected group compared to control. Non significant increasing creatinine levels were detected in the KI injected group indicating the onset of kidneys' dysfunction.

## III- Histological examinations

### (i)-Control group

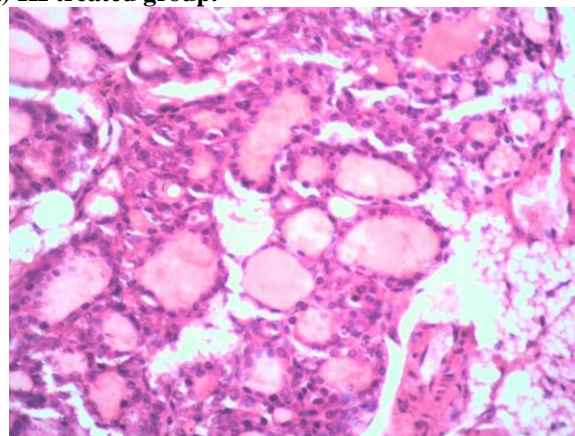


**Figure 2(a)** showing normal histological structure of the thyroid gland follicles appeared with cuboidal lining epithelium (E) surrounding a lumen containing colloid (L). Normal appearance of parafollicular cells (C- cells) adjacent (C) (H&E x 400).

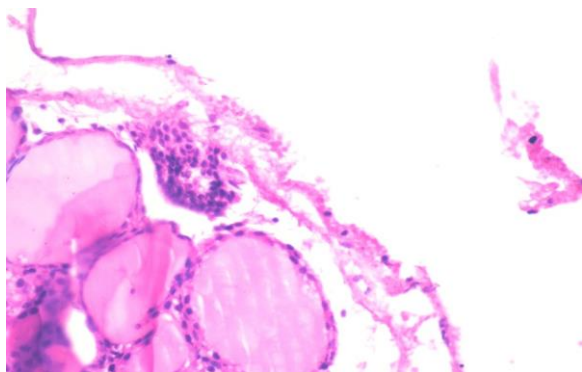


**Figure 2(b)** showing normal thyroid follicles with different volumes (V) (H&E x 400).

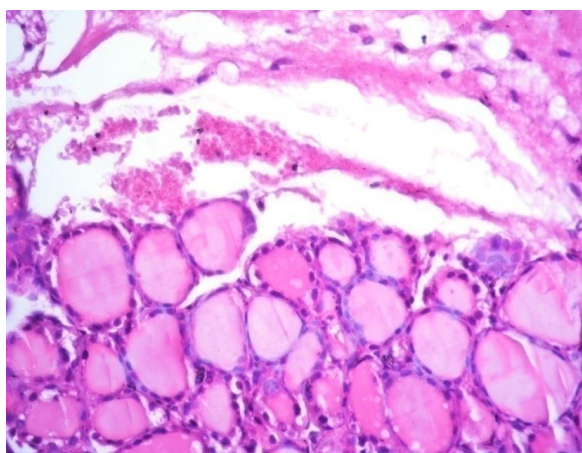
### (ii) KI treated group.



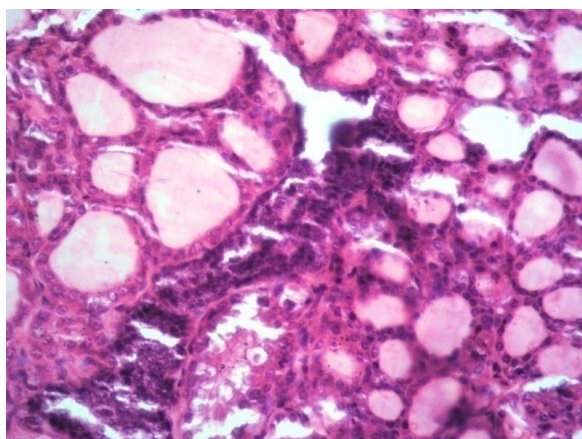
**Figure 3(a)** Thyroid gland revealing some follicular cells appeared necrotic and sloughed (S) and interstitial oedema (O) in between thyroid follicles in KI treated group (H&E x 400).



**Figure 3(b)** showing thyroid gland with sub-capsular focal mononuclear cell aggregations (M) associated with interstitial oedema (O) between thyroid follicles in KI treated group (H&E x 400).



**Figure 3(c)** showing thyroid gland with sub-capsular hemorrhage (H) as well as interstitial oedema (O) in KI treated group (H&E x 400).



**Figure 3(d)** showing thyroid gland revealing proliferation of interstitial C-cells (C) or parafollicular cells in KI treated group (H&E x 400).

#### 4-Discussion

Our study presents the effect of excess iodine intake on body organs by applying the intraperitoneal injection of KI solution to female mice. The results

recorded a significant decrease in serum level of TSH (thyroid stimulating hormone) and a non significant increase in serum T4 (thyroxine) and T3 (tri-iodothyronine) hormones in the KI treated group compared to the control one as shown in table (1).

These data displayed the features of a subclinical hyperthyroidism case (significant decrease in TSH with non significant increase in thyroid hormones) as defined by Palacios *et al* and Wartofsky. They also reported that the iodine containing drugs are considered one of the main causes of the case existence [35, 36].

The histological examinations showed a clear effectiveness of the thyrocytes due to KI injection. Thyroid follicles necrosis were observed besides the presence of oedema, hemorrhage and mononuclear cells infiltration as shown in figures (3a & b& c). Increasing the number of C-cells was also recorded associated to the case (figure 3(d)).

An observed and recorded thyroid hormones (THs) level in tissues during thyroid dysfunction is rarely documented. This is actually referred to the complexity in (THs) synthesis, transport and regulation [37].

In general control cases, T3 hormone concentration level in serum rapidly equilibrate with that are produced in the liver and kidneys and other peripheral tissues except the brain. (THs) takes much longer time to equilibrate with brain cells due to its complex structure and the presence of the blood brain barrier [38].

In our study, it was found that different organs respond to the excess KI administration with different reactions. KI administration was the main cause in exhibiting an elevated levels of serum (THs) which in turn affected the hormonal balance between the serum and the tissues.

The liver was the most affected organ among the tested organs followed by the brain. Both of them expressed increasing significant levels of T3 hormone compared to their controls. On the contrary, the heart and the kidneys displayed a non significant decrease in T3 hormone.

These results can be discussed as follows. Many studies discussed the liver status in case of increased (THs) or in hyperthyroidism in mice [39, 40, 11]. These studies showed the effect of increased (THs) on the (THs) transporters in liver tissue. They reported that there was a decrease in *Mct8* protein expression which has a great effect on T3 efflux from the liver cells and there was an up regulation of *Mct10* to mediate (THs) efflux from liver cells. These findings may interpret the high increase in T3 level in liver homogenate (122%) in our study.

We can say that the observed increase in serum (THs) elicited a change in the liver (THs) transporters expression as an adaptation mechanism against (THs)

increase which in turn lead to increased T3 level in liver tissue.

In case of the brain tissue homogenate, our study recorded a significant increase in T3 level (22%). This increase was considered a controlled and restricted one as the brain cells contains mainly a high autoregulated protective mechanisms against T3 increase that are responsible for maintaining the homeostasis of (THs) between the tissue and the plasma (THs) increase.

There is a coordinated regulation between the activities of DIO2 and DIO3 (type II & type III deiodinase) enzymes in the brain cells to avoid imbalance of (THs) that can cause adverse neurobehavioral effects.

DIO3 is known to inactivate mainly T3 hormone to the metabolite T2 and also is responsible to a lower extent for inactivation of T4 to T3 and rT3. There are many factors in the brain that are responsible for activation of these protective mechanisms such as its onset, duration, tolerance limit and termination which are considered an enigma due to the complexity of the brain structure [41, 42].

In case of heart tissue homogenate, non significant decrease in T3 was observed as shown in table (2). These data did not mean that the heart was not affected by the increased serum (THs) according to the information collected by [43]. They reported that in rodent models there was an increase in the type III deiodinase (DIO3) enzyme in heart tissues during heart disease cases [44, 45]. It was also reported that induction of DIO3 activation in heart failure in rats resulted in a local hypothyroid case [46]. Another reason was responsible for decreasing T3 in cardiac tissues which is the change of certain (THs) transporters expression in the heart tissue as the upregulation of *MCT8* protein expression and down regulation of that of *MCT10* [47].

So we can say that in our study, the heart tissue dealt with the observed increase in serum (THs) with a different defence mechanisms from that found in the liver and the brain. Also we can guess that there was a masked increase in the heart tissue T3. Also we can deduce that the heart was subjected to a gradual hypothyroidism.

Little amount of data were collected about the kidneys and T3 levels. Our study represents a new data for kidneys tissue T3 level during increased serum (THs). The kidneys case may resemble that of the heart case and was subjected to a gradual hypothyroidism.

Our study showed that in spite of the great variability in T3 level displayed among the four organs tissue (increasing or decreasing), there was a detectable abnormality in functional enzyme levels found in these organs. This case indicated the onset of organs dysfunction at the same time as shown in tables (4&5).

The liver tissue homogenate showed an increasing significant level in ALT and non significant decrease in AST. These results are in accordance with Upadhyay *et al* and Luo *et al* [48, 49] who observed the serum liver functions abnormality in rodents during the increase in thyroid hormones or hyperthyroidism.

Increasing serum alkaline phosphatase enzyme (ALP) level is a pathological case indicating for cerebral small vessel disease (cSVD). Many studies denoted the relation between cSVD and atherosclerotic vascular and arterial calcification of the brain which are involved in cerebral microangiopathy [50,51]. Our data showed a significant increase in ALP level in brain homogenate (54.80%) compared to control. It was also observed that there was no change in acid phosphatase enzyme (ACP) level which is considered as a lysosomal enzyme marker for lysosomal system dysfunction in case of Alzheimer's disease [52] and plays a role in regulation of neuronal function by activation of hydrolyzing enzymes in brain homogenate [53].

Few studies investigated the relation between serum lactate dehydrogenase enzyme (LDH) and thyroid dysfunction in humans but there are no available data recorded in animal heart tissue. Increasing serum LDH level was observed in hypothyroidism while decreasing ones were found in hyperthyroidism [54, 55, 56]. These data agreed with our data as there was a significant decrease in LDH level in heart tissue (-64.10 %) during thyroid dysfunction due to excess iodine intake. Also the non changeable serum troponin I can indicate that the heart cells were keeping their integrity [57] and so LDH level may appear decreasing in serum.

Increasing levels of angiotensin converting enzyme (ACE) in kidney tissue and increased serum creatinine are true markers for kidney dysfunction. ACE is one of the components of the rennin-angiotensin system (RAS) that is responsible for controlling kidney functions [58, 59]. ACE is a primary enzyme that converts angiotensin I to angiotensin II in heart and kidneys. The imbalanced activation in the ACE/angiotensin II axis contributes in renal fibrolytic process [60, 61]. Many clinical drugs for renal therapy includes ACE inhibitors and angiotensin II receptors blockers. Narayan *et al* and Kumari *et al* reported that (RAS) is under control of (THs) so accordingly thyroid gland dysfunction can affect ACE concentration [62, 63].

Our data are in accordance with these previous data as there was a significant increase in ACE level in kidney tissue (148.3%).

We can deduce that there are many common features between our data and the complications observed in hyperthyroidism or in the increased thyroid hormones cases. This can be also assured by the results obtained

during determining the serum glucose and TOAC levels.

Hyperthyroidism is almost associated with an increase in oxidative stress due to the higher rate of metabolism caused by the increased T3 level. Also an increasing of glucose level in serum due to hyperthyroidism is responsible for subjection of the body to more free radicals.

These results were observed in our study as there was a significant decrease in serum TOAC as shown in table (6). The data are in accordance with Messarah *et al* and Sarker *et al* [64, 2] who denoted the decreased TOAC in serum of hyperthyroid rats and observing the relation between serum glucose level and TOAC level in iodine excess case in rats.

### 5-Conclusion

-Common aspects were observed between our data and subclinical hyperthyroid case. Accordingly, our study can represent the features of the transitional stage from the normal thyroid stage to the iodine induced hyperthyroidism (IIH) disease.

-Our study also recorded the tissues level of T3 and some associated enzymatic disorders in the different organs clarifying the status of each organ during the existence of a subclinical IIH case.

### Ethical approval.

All the studies were conducted in accordance with the Animal Ethical Committee of the National Research Center, Dokki, Giza, Egypt under the ethics number (18157).

### Conflict of Interest.

The authors declare that they have no conflict of interest.

### Funding.

There are no funders or financial support for this study.

### Acknowledgment.

The authors are grateful to the National Research Centre (NRC) for providing the facilities to establish this research.

### Contributions.

DSF suggested the experimental design, collected the scientific subject, shared in the practical work and wrote the manuscript. NEI collected the chemicals and the scientific subject and shared in the practical work.

### References

1. Skalny AV. Bioelements and bioelementology in pharmacology and nutrition: fundamental and practical aspects. In: Atroshi F, editor. Pharmacology and nutritional intervention in the treatment of disease. Rijeka: InTech; 225-241(2014).
2. Sarker D, Chakraborty A, Saha A and Chandra AK. Iodine in excess in the alterations of carbohydrate and lipid metabolic pattern as well as histomorphometric changes in associated organs. *J Basic Clin Physiol Pharmacol.*, **29**(6):631-643 (2018).
3. Vanderpump M. Thyroid and iodine nutritional status: a UK perspective. *Clin Med.*, **14**(6): 7–11(2014).
4. Leung AM and Braverman LE. Consequences of excess iodine. *Nat Rev Endocrinol.*, **10**(3): 136–142 (2014).
5. Chung HR. Iodine and thyroid function. *Ann pediatr Endocrinol Metab.*, **19** (1): 8-12 (2014).
6. Liu D, Lin X, Yu F, Zhang M, Chen H, Bao W and Wang X. Effects of 3,5-diiodotyrosine and potassium iodide on thyroid function and oxidative stress in iodine-excess Wistar rats. *Biol Trace Elem Res.*, **168**: 447–452 (2015).
7. Burgi H. Iodine excess. *Best Pract Res Clin En.*, **24**:107–115(2010).
8. Goichot B, Caron P, Landron F, and Bouee S. Clinical presentation of hyperthyroidism in a large representative sample of outpatients in France: relationships with age, aetiology and hormonal parameters. *Clin Endocrinol.*, **84**(3): 445-451 (2016).
9. Boelaert K, Torlinska B, Holder RL, and Franklyn JA. Older subjects with hyperthyroidism present with a paucity of symptoms and signs: a large cross-sectional study. *J Clin Endocrinol Metab.*, **95**: 2715–26 (2010).
10. Escobar-Morreale H, Obregón MJ, Escobar del Rey F and Morreale de Escobar G. Tissue-specific patterns of changes in 3,5,3'-triiodo-L-thyronine concentrations in thyroidectomized rats infused with increasing doses of the hormone. Which are the regulatory mechanisms? *Biochimie*, **81**:453-462 (1999).
11. Engels K, Rakov H, Zwanziger D, Moeller LC, Homuth G, Kohrle J, Brix K, and Fuhrer D. Differences in mouse hepatic thyroid hormone transporter expression with age and hyperthyroidism. *Eur Thyroid J.*, **4**(1): 81–86 (2015).
12. Boelen A, Van der Spek AH, Bloise F, De Vries EM, Surovtseva OV, Beeren, MV, Ackermans MT, Kwakkel J, and Fliers E. Tissue thyroid hormone metabolism is differentially regulated during illness in mice. *J Endocrinology.*, **233**: 25–36 (2017).
13. Frohlich E and Wahi R. Microbiota and thyroid interaction in health and disease. *Metabolism*, **30**(8):479-490 (2019).
14. Roti E and Uberti ED. Iodine excess and hyperthyroidism. *Thyroid*, **11**(5): 493-500 (2001).



15. Vasilev R , Vasilleva I, Yugotova N and Troshin E. DAFS-25K impact on cattle's thyroid hormonal status. *BIO web of conferences*, 17, 00214(2020).
16. Leung A and Braverman LE. Iodine-induced thyroid dysfunction. *Curr Opin Endocrinol Diabetes Obes*, **19**(5): 414–419(2012).
17. Sang Z, Chen W, Shen J, Tan L, Zhao N, Liu H, *et al.* Long term exposure to excessive iodine from water is associated with thyroid dysfunction in children. *J Nutr.*, **143**: 2038-43(2013).
18. Calil-Silveira J, Serrano-Nascimento C, Laconca RC, Schmiedecke L, Salgueiro RB, Kondo AK and Nunes MT. Underlying Mechanisms of Pituitary-Thyroid Axis Function Disruption by Chronic Iodine Excess in Rats. *Thyroid*, **26**(10):1488-1498 (2016).
19. Porth CM, Gaspard KJ, and Noble KA. Essentials of pathophysiology: Concepts of altered health states (3rd ed.). Philadelphia, PA: Wolters Kluwer/Lippincott Williams & Wilkins ; (2011).
20. Digeronimo PM and Brandao J. Updates on thyroid disease in rabbits and guinea pigs. *Vet Clin North Am Exot Anim Pract.*, **23**(2):373-381(2020).
21. Vecchiatti SM, Guzzo ML, Caldini EG, Bisi H, Longatto-Filho A and Lin CJ. Iodine increases and predicts incidence of thyroiditis in NOD mice: Histological and ultra-structural study. *Experimental and therapeutic medicine*, **5**: 603-607 (2013).
22. Fisher DA. Physiological variation in thyroid hormones. Physiological and pathological considerations. *Clin Chem.*, **42**:135-139 (1996).
23. Nelson IC and Wilcox RB. Analytical performance of free and total thyroxine assays. *Clin Chem*, **42**(1): 146-154 (1996).
24. Ekins, R. Free hormone assay. *Nucl Med Commun.*, **14**: 676-688(1993).
25. Koracevic D, Koracevic G, Djordjevic V, Andrejevic S and Cosic V. Method for the measurement of antioxidant activity in human fluids. *J Clin Pathol.*, **54**: 356-361(2001).
26. Trinder P. Determination of glucose in blood using glucose oxidase with an alternative oxygen acceptor. *Ann. Clin. Biochem.*, **6**: 24-27(1969).
27. Bartles H, Bohmer M and Heirli C. Serum creatinine determination without protein precipitation. *Clin Chem Acta.*, **37**: 193-7(1972).
28. Reitman S and Frankel, S. A colorimetric method for the determination of serum glutamic oxaloacetic, glutamic pyruvic transaminases. *A J Clinical Pathol.*, **28**, 56-63 (1957).
29. Thomas, L. Clinical Laboratory Diagnostics. 1<sup>ST</sup> edition, Frankfurt; TH Books Verlagsgesellschaft; 136-146 (1998).
30. Kaplan LA and Pesce Aj. Clinical chemistry theory analysis and correlation, C.V. Mosby company, St Louis; 1087(1984).
31. Zimmerman HJ and Henery JB. Clinical enzymology, IN' Clinical diagnosis and management by laboratory methods.16 th .JB Henery, editor, Saunders. Philadelphia; 365-368 (1979).
32. Apple FS and Wu AHB. Myocardial infraction redefined: role of cardiac troponin testing. *Clin.Chem.*, **247**: 377-379 (2001).
33. Tietz NW. Text book of clinical chemistry.W.B. Saunders Co.Philadelphia (1999).
34. Bancroft JD, Stevens AA, and Turner DR. Theory and practice of histological techniques. Forth edition Churchill Livingstone, New York, London, San Francisco, Tokyo (1996).
35. Palacios SS, Pascual-Corrales E and Galofre JC. Management of Subclinical Hyperthyroidism. *Int J Endocrinol Metab.*, **10**(2):490-496 (2012).
36. Wartofsky L. Management of subclinical hyperthyroidism. *J Clin Endocrinol Metab.*, **96**(1):59-61(2011).
37. Cheng SY, Leonard JL and Davis PJ. Molecular aspects of thyroid hormone actions. *Endocr Rev.*, **31**(2): 139–170 (2010).
38. Schroeder AC and Privalsky ML. Thyroid hormones, T3 andT4, in the brain. *Front Endocrin.*, **5**:1-6 (2014).
39. Dumitrescu AM, Liao X-H, Weiss RE, Millen K and Refetoff S. Tissue-specific thyroid hormone deprivation and excess in monocarboxylate transporter (mct) 8-deficient mice. *Endocrinology*, **147**: 4036–4043 (2006).
40. Muller J, Mayerl S, Visser TJ, Darras VM, Boelen A, Frappart L, Mariotta L, Verrey F and Heuer H. Tissue-specific alterations in thyroid hormone homeostasis in combined Mct10 and Mct8 deficiency. *Endocrinology*, **155**:315–325(2014).
41. Kundu S, Pramanik M, Roy S, De J, Biswas A and Ray A.K. Maintenance of brain thyroid hormone level during peripheral hypothyroid condition in adult rat. *Life Sci.*, **79**: 1450-1455 (2006).
42. Kundu S and Ray AK. Thyroid hormone homeostasis in adult mammalian brain: A novel mechanism for functional preservation of cerebral T3 content during initial peripheral hypothyroidism. *Al Ameen J Med Sci.*, **3** (1): 5 - 20 (2010).
43. Janssen R, Muller A and Simonides WS. Cardiac Thyroid Hormone Metabolism and Heart Failure. *Eur Thyroid J.*, **6**: 130–137 (2017).
44. Gereben B, Zeold A, Dentice M, Salvatore D and Bianco AC. Activation and inactivation of thyroid hormone by deiodinases: local action

- with general consequences. *Cell Mol Life Sci.*, **65**: 570–590 (2008).
45. Pol CJ, Muller A and Simonides WS. Cardiomyocyte-specific inactivation of thyroid hormone in pathologic ventricular hypertrophy: an adaptative response or part of the problem? *Heart Fail Rev.*, **15**:133–142. (2010).
  46. Wassen FWJS, Schiel AE, Kuiper GGJM, Kaptein E, Bakker O, Visser TJ, *et al.* Induction of thyroid hormone-degrading deiodinase in cardiac hypertrophy and failure. *Endocrinology*, **143**: 2812–2815 (2002).
  47. Weltman NY, Ojamaa K, Schlenker EH, Chen Y-F, Zucchi R, Saba A, *et al.* Low-dose T3 replacement restores depressed cardiac T3 levels, preserves coronary microvasculature and attenuates cardiac dysfunction in experimental diabetes mellitus. *Mol Med.*, **20**:302–312 (2014).
  48. Upadhyay G, Singh R, Kumar A and Kumar S. Severe hyperthyroidism induces mitochondria mediated apoptosis in rat liver. *Hepatology*, **39**(4): 1120- 1130 (2004).
  49. Luo H, Li X, Xiao S and Zhang X. Effect of Shenmaisanjie capsules on hyperthyroidism-induced liver damage in rat. *Int J Clin Exp Med.*, **10**(8):11903-11911 (2017).
  50. Vidal JS, Sigurdsson S, Jonsdottir MK, Eiriksdottir G, Thorgeirsson G, Kjartansson O, *et al.*, Coronary artery calcium, brain function and structure: the AGES-Reykjavik Study. *Stroke*, **41**(5): 891–7 (2010).
  51. Lee HB, Kim J, Kim SH, Kim S, Kim OJ and Oh SH. Association between serum alkaline phosphatase level and cerebral small vessel disease. *PLoS ONE*, **10**(11): e0143355 (2015).
  52. Hamano T, Gendron TF, Causevic E, Yen SH, Lin WL, Isidoro C and Deture M. Autophagic-lysosomal perturbation enhances tau aggregation in transfectants with induced wild type tau expression. *Eur J Neurosci.*, **27**: 1119–1130 (2008).
  53. Prabha M, Bhavana G, Sunitha P, Channarayappa and Lokesh KN. The role of carboxyl esterase and acid phosphatase in aged and lithium treated rats in regulation of neuronal function. *J Biochem Tech.*, **6**(1): 889-893 (2015).
  54. McGrowder DA, Fraser YP, Gordon L, Crawford TV and Rawlins JM. Serum creatine kinase and lactate dehydrogenase activities in patients with thyroid disorders. *Niger J Clin Pract.*, **14**: 454-9 (2011).
  55. Shanti R, Vijayalakshmi M, and Mahalakshmi R. Creatine kinase & lactate dehydrogenase activity in patients with hypothyroidism. *Int J Clin Biochem Res.*, **4**(2): 182-186 (2017).
  56. Vanangamudi A and Ramanathan D. A comparative study of biochemical markers of myopathy in hypothyroid and euthyroid females. *AJB*, **8**(2), 40-44 (2018).
  57. Undhad VV, Fefar DT, Jivani BM, Gupta H, Ghodasara DJ, Joshi PB, and Prajapati KS. Cardiac troponin; an emerging cardiac biomarker in animal health. *Vet World*, **5** (8): 508-511(2012).
  58. Liu CX, Hu Q, Wang Y, Zhang W, Ma ZY, Feng JB, Wang R., Wang XP, Dong B, Gao, F, Zhang MX and Zhang Y. Angiotensin-converting enzyme (ACE) 2 overexpression ameliorates glomerular injury in a Rat model of diabetic nephropathy: A comparison with ACE inhibition. *Mol Med*, **17**(1-2): 59-69 (2011).
  59. Mizuiri, S., and Ohashi, Y. ACE and ACE2 in kidney disease. *World J Nephrol.*, **4**(1): 74-82 (2015).
  60. Murphy AM, Wong AL and Bezuhly M. Modulation of angiotensin II signaling in the prevention of fibrosis. *Fibrogenesis & Tissue Repair*, **8** (7):1-7 (2015).
  61. Hsieh WY, Chang TH, Chang HF, Chuang WH, Lu LC, Yang CW, Lin CS and Chang CC. Renal chymase-dependent pathway for angiotensin II formation mediated acute kidney injury in a mouse model of aristolochic acid I-induced acute nephropathy. *PLoS ONE*, **14**(1): 1-15(2019).
  62. Narayan SS, Lorenz K, Ukkat J, Hoang-Vu and Trojanowicz B. Angiotensin converting enzyme ACE and ACE2 in thyroid cancer progression. *Neoplasma*, **67**(2):402-409(2020).
  63. Kumari K, Chainy GBN and Subudhi U. Prospective role of thyroid disorders in monitoring COVID-19 pandemic. *Heliyon*, **6**(12) : (2020).
  64. Messarah M, Chouabia A, Klabet F, Abdennour C, Boulakoud MS and El-Feki A. Influence of thyroid dysfunction on liver, lipid peroxidation and antioxidant status in experimental rats. *Exp Toxicol Pathol.*, **62**(3): 301-310 (2010).