

Wnt signaling transcription factors TCF-1 and LEF-1 are upregulated in malignant astrocytic brain tumors

Nives Pećina-Šlaus^{1,2}, Anja Kafka^{1,2}, Davor Tomas^{3,4}, Leon Marković¹,
Petar Krešimir Okštajner¹, Viktorija Sukser¹ and Božo Krušlin^{3,4}

¹Laboratory of Neurooncology, Croatian Institute for Brain Research, School of Medicine University of Zagreb, Zagreb, Croatia, ²Department of Biology, School of Medicine, University of Zagreb, Zagreb, Croatia, ³Department of Pathology, School of Medicine, University of Zagreb, Zagreb, Croatia and ⁴University Hospital "Sisters of Charity", Zagreb, Croatia

Summary. Since the discovery of the TCF/LEF family of transcription factors, their functions have been under intensive investigation in the area of cancer biology. The work presented in this paper focused on the changes in TCF-1 and LEF-1 expression levels in a set of astrocytic brain tumors.

Protein expression was detected using immunohistochemistry and then evaluated by Ellipse software (ViDiTo, Slovakia). Statistical evaluations were performed with the SPSS statistical package, version 14.0 (SPSS Inc., Chicago, IL, USA).

Strong TCF-1 and LEF-1 expression was observed in 51.6% and 71% of glioblastoma samples. Statistical analysis confirmed significant differences in protein expression levels associated to 3 important values, weak expression of TCF-1, weak expression of LEF-1 and strong expression of LEF-1. Analysis of variances performed on the total sample also indicated significant differences in the values of TCF-1 weak ($F=2.804$; $p=0.045$), LEF-1 weak ($F=4.255$; $p=0.008$) and LEF-1 strong ($F=5.498$; $p=0.002$) with regard to malignancy grade. Thus, glioblastomas were characterized by –in relative terms– the lowest values for weak expression of TCF-1 and LEF-1, combined with the highest values of LEF-1 strong expression. The F-ratios for two variables (LEF-1 strong and LEF-1 weak) indicated that differences between astrocytomas (II, III) and glioblastomas were statistically significant ($p<0.02$). Discriminant function analysis further showed that

strong LEF-1 expression alone could discriminate between astrocytomas (II, III) and glioblastomas.

Elevated TCF-1 and LEF-1 expression is characteristic of malignant gliomas. LEF-1, in particular, may serve as a potential marker for malignant transformation.

Key words: Astrocytic brain tumors, Glioblastoma, Transcription factors TCF-1, LEF-1, Wnt signaling

Introduction

The Wnt signaling pathway, which was discovered 30 years ago, has proven to be one of the main cellular pathways dysregulated in tumorigenesis. Mediators of transcription of this pathway are members of TCF/LEF (T-cell factor/lymphoid-enhancer factor) family (Arce et al., 2006; Cadigan and Waterman, 2012) a group of transcription factors which bind to DNA. Since the discovery of the TCF/LEF family, their functions have been under intensive investigation in cancer biology (Novak and Dedhar, 1999; Brantjes et al., 2002; Klaus and Birchmeier, 2008; Shitashige et al., 2008; Pecina-Slaus, 2010; Cadigan and Waterman, 2012). Members of the TCF/LEF family are diverse in both form and function and are comprised of many isoforms generated through alternative splicing and the use of alternative promoters (Wallmen et al., 2012). Nevertheless, they share some characteristics: a beta-catenin binding domain, a High Mobility Group (HMG) box, a Groucho-interaction domain, which has been recently renamed as context dependent regulatory domain (CRD), and a C-

terminal domain (Arce et al., 2006). Their beta-catenin binding domains are composed of 55 amino acids and are located at the N-terminus. The HMG box, which is comprised of 80 amino acids, is located between the N- and C-termini and is the sequence-specific DNA binding domain (van Noort and Clevers, 2002; Ravindranath et al., 2008). Both these structural domains are highly conserved and present in all TCF/LEFs. The Groucho-interaction domain is located between the beta-catenin binding domain and the HMG box (van Noort and Clevers, 2002; Ravindranath et al., 2008; Arce et al., 2009). The function of the C-terminal domain, which is often alternatively spliced, has not yet been identified (Arce et al., 2006).

Different LEFs/TCFs regulate their target genes in different ways. TCF-1 and LEF-1 act as transcriptional activators while TCF-3 acts as a transcriptional repressor. Alternative splicing of TCF-4 results in several isoforms that can act as either transcriptional activators or repressors, depending on the context (Vacik and Lemke, 2011; Hanson et al., 2012).

When the wnt pathway is activated its main effector molecule, beta-catenin, is translocated to the nucleus, subsequently binding to TCF/LEF family members. After this binding a number of promoters of target genes are transcriptionally stimulated, ultimately leading to oncogenic transformation and progression. Beta-catenin can further modulate its transcriptional activity by picking or alternating a nuclear binding partner among TCF/LEF members (Xu and Kimelman, 2007; Sellak et al., 2012).

Astrocytomas are the most common primary brain tumors but despite recent advances on glioma genetics, however, the molecular mechanisms behind their development and progression remain largely unexplained. Wnt signaling is known to play important roles during neurogenesis and embryonic brain formation (Coyle-Rink et al., 2002). Recently, studies have reported that Wnt signaling is also involved in astrocytoma tumorigenesis (Sareddy et al., 2009; Kahlert et al., 2012; Schüle et al., 2012), but little is known about the role of TCF/LEF in malignant astrocytic progression.

The expression pattern of TCF/LEF transcription factors is different in normal as compared to cancer cells. In the present study we wanted to test the hypothesis whether TCF-1 and LEF-1 expression levels positively correlated with malignant astrocytic progression.

Materials and methods

Tumor specimens

Eighty-six astrocytic brain tumor samples were collected from the Ljudevit Jurak Department of Pathology, Sisters of Charity University Hospital in Zagreb, Croatia. The tumors were identified by magnetic resonance imaging in different cerebral regions. Patients

had no family history of brain tumors, and all tumors were studied by pathologists and classified into four grades, according to World Health Organization guidelines (Louis et al., 2007). There were 21 pilocytic astrocytomas (WHO grade I), 19 diffuse (WHO grade II), 15 anaplastic (WHO grade III), and 31 glioblastomas (WHO grade IV). Forty-eight patients were male, and 38 were female. Patient age ranged from 3 to 81 years (mean: 43.86 years; median: 47.00 years). The local Ethical Committee approved our study, and all patients provided informed consent.

Immunohistochemistry

The samples were fixed in formalin, embedded in paraffin, sliced into 4- μ m thick sections, and then fixed onto capillary gap microscope slides (DakoCytomation, Denmark). Sections were immunostained using streptavidin horseradish peroxidase/DAB (EnVision™, Dako REAL™). Briefly, sections were deparaffinized and rehydrated and then microwaved twice for 3 min at 700 W in citrate buffer two times and once for 4 min at 350W to unmask epitopes. To block endogenous peroxidase activity, cells were fixed in methanol with 3% H₂O₂. Non-specific binding was blocked by incubating samples with goat serum for 30 min at 4°C. Next, the primary antibodies, mouse monoclonal anti-human TCF-1 or LEF-1 (1:50; Santa Cruz Biotechnology, US) were applied for 30 min at room temperature. Slides were then washed three times in phosphate-buffered saline (PBS)/goat serum, and secondary LINK antibody was applied for 16 min at room temperature. Slides were again washed three times in PBS/goat serum and were incubated with substrate chromogen solution (EnVision™, Dako REAL™) for 30 seconds.

Negative controls underwent the same staining procedure but without incubating samples with the primary antibodies. The frontal cortex of a normal brain and normal skin, kidneys, and the colon served as positive controls. Antibody labeling was analyzed by three independent and blinded observers using an Olympus BH-2 microscope. No expression or very weak expression was labeled as 0/+, moderate expression as ++, and strong expression as +++. Two hundred cells in a hot spot of each sample were analyzed. For each sample, staining intensity in a well-defined area was also evaluated using Ellipse software (ViDiTo, Slovakia).

Statistical analysis

All individuals were analyzed for the following features: malignancy grade, sex, age, LEF-1 and TCF-1 protein expression intensities. Differences in the values of TCF-1 and LEF-1 expressions (strong, moderate, weak) were tested with ANOVA following Leven's analysis of homogeneity of variance (if significance of Leven's statistic was less than 0.05 the non-parametric Mann-Whitney test was employed). ANOVA was used

TCF-1 and LEF-1 in astrocytic tumors

to determine potential differences in the values of TCF-1 and LEF-1 expression with regard to different age categories, the sexes, and different malignancy grades. Pearson's correlations were also used to assess relationships between the various expressions between TCF-1 and LEF-1.

Additionally, discriminant function analyses were performed to determine whether the values of a single, or combination of analyzed features could be used to determine the most malignant grade. The main advantage of discriminant function analysis is that it reduces subjective judgment as well as the level of expertise and experience needed to determine this. The justification of this premise is that variation in one variable – in this case malignancy grade, can be better assessed when the disease process is considered as a system and analyzed in terms of the factors that are collectively postulated to explain it. Statistical

significance was set at $p < 0.05$. All statistical evaluations were performed with the SPSS statistical package 14.0 (SPSS Inc., Chicago, IL, USA).

Results

The expression of both transcription factors was found to be present in the majority of the analyzed samples and heterogeneously distributed throughout the tumors with nuclear localizations, suggesting increased transcriptional activity. Immunostaining of TCF-1 and LEF-1 proteins is demonstrated in Fig. 1.

At the level of the complete series of astrocytic tumors investigated in this study, our analyses showed that mean values of the complete sample demonstrate strong expression of TCF-1 at slightly less than 12%, slightly less than 33% exhibited a moderate expression, while approximately 55% exhibited weak expression of

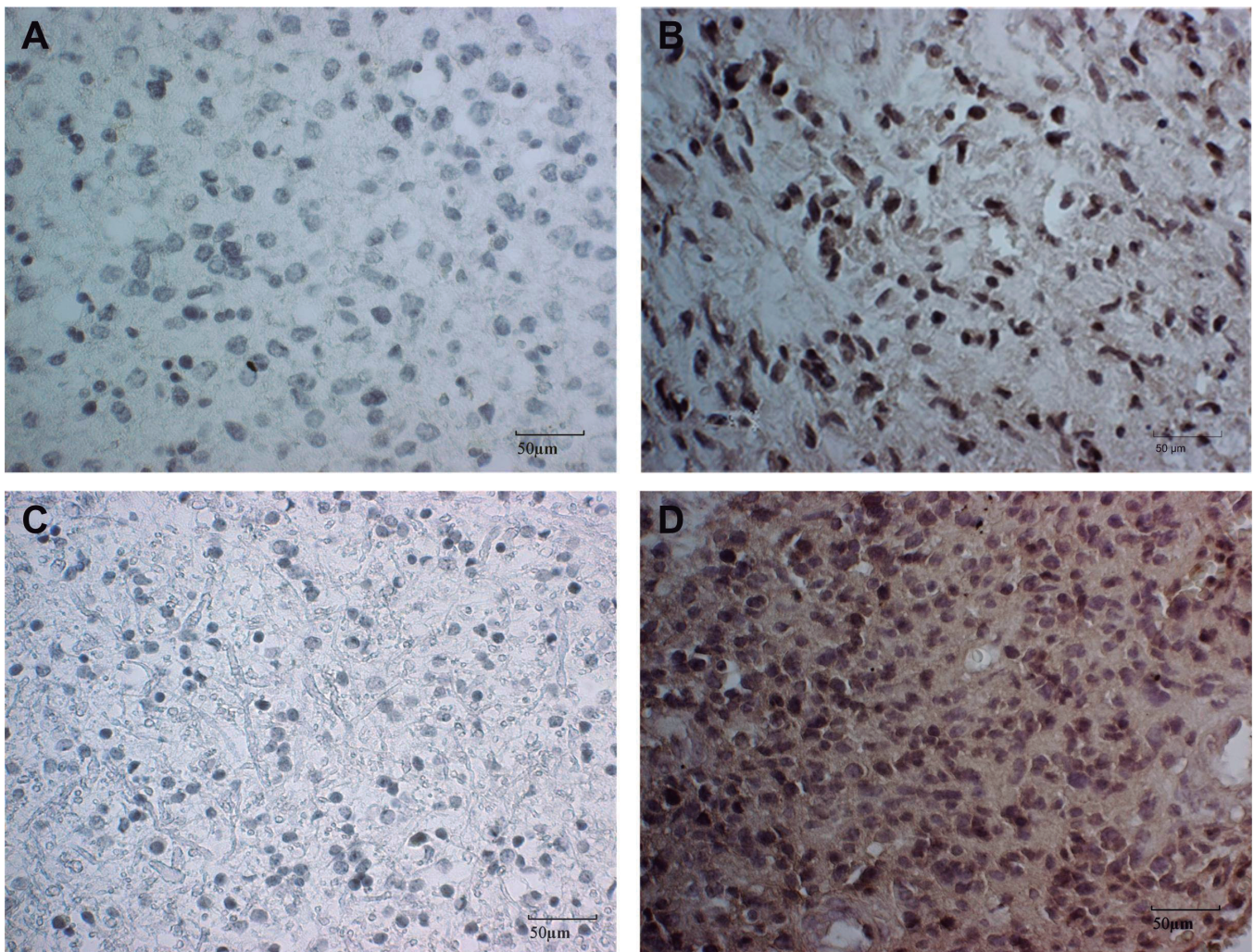


Fig. 1. Characteristic immunohistochemical staining of weak and strong expressions. TCF-1 in astrocytoma II (A) and glioblastoma (B) showing weak (A) and strong (B) expression. LEF-1 in astrocytoma II (C) and glioblastoma (D) showing weak (C) and strong (D) expression. Scale bars 50 µm.

TCF-1 and LEF-1 in astrocytic tumors

this transcription factor. LEF-1 expression was similar with approximately 14%, 33%, and 53% exhibiting strong, moderate, and weak or no expression, respectively.

Additional analyses were performed to determine possible age or sex patterns. As the mean age of our patients was 44 years, two large age categories were compiled, one consisting of individuals younger than 44 years (n=36), and the other of individuals 44 years or older (n=45). ANOVA analysis showed no significant differences between these age subgroups. However, women exhibited significantly higher values of weak expression of LEF-1 when compared to males (F=5.378; sig=0.023), meaning they had significantly less LEF-1 protein than men.

The staining intensity of 200 cells per sample in the hot spot was analyzed using Ellipse software (ViDiTo, Slovakia). Samples were then categorized according to the proportion of cells with a specific staining intensity which mirrors the level of expression of the particular transcription factor. Categories were as follows: I (very strong expression) - >20% strong, >25% moderate, <45% weak or no expression; II (strong expression) -

10-20% strong, >25% moderate, <55% weak or no expression; III (moderate expression) - 5-10% strong, 10-50% moderate, 45-80% weak or no expression; IV (weak expression) - 0-5% strong, 10-50% moderate, >45% weak or no expression; V (very weak expression) -0% strong, <51% moderate, >50% weak or no expression.

Of the total glioblastoma samples, 51.6%, 25.8%, and 23% had strong, moderate, and weak or no TCF-1 expression, respectively. LEF-1 expression was even more distinct with 71% of samples showing very strong LEF-1 expression, 19.4% with moderate and only 9.6% with weak or no protein present. Because pilocytic astrocytomas are clinically, biologically, and histologically distinct from WHO grade II-IV gliomas, they were used as a benign reference. Both TCF-1 and LEF-1 expression in grade I astrocytomas were the opposite of what was observed in glioblastomas (Table 1 and Fig. 2). The expression levels were almost inverted with strong TCF-1 expression in 15.8%, moderate in 21% and, weak or no expression in 63.2%. The results for LEF-1 in astrocytoma I were as follows: strong 22.8%, moderate 9% and, weak or no expression in 68.2%. The results obtained for astrocytoma grade II and grade III are also shown in Table 1. The reversal in TCF-1 and LEF-1 expression levels was immediately apparent in grade II astrocytomas but not as consistent in grade III astrocytomas.

We established a statistically relevant correlation between the intensities of specific measurements of the two expressed proteins. The levels of the two proteins were significantly positively correlated in our total tumor sample when strong or weak expressions were in question.

The expression levels of the two proteins were positively correlated with the histological malignancy. The results obtained on our total sample demonstrate

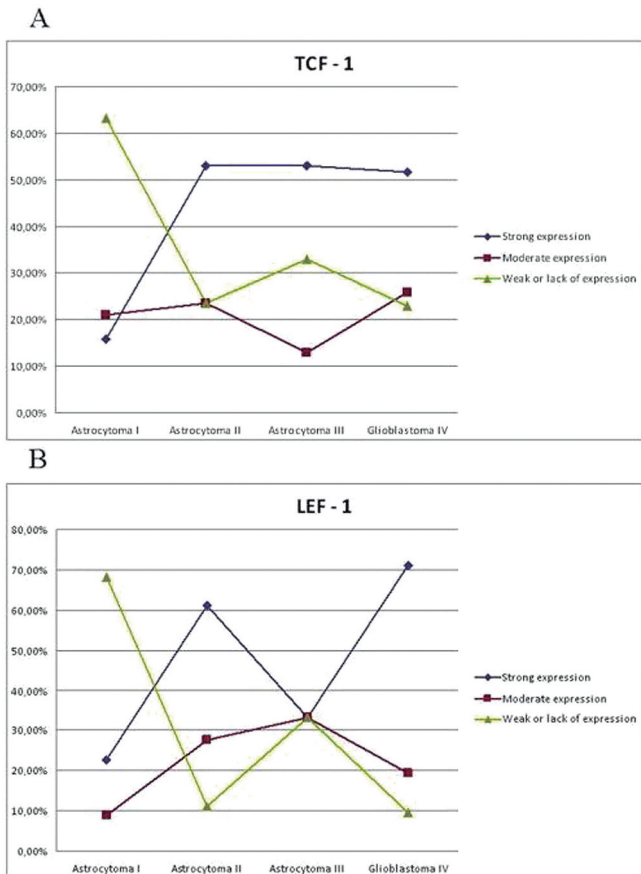


Fig. 2. Graphs illustrating TCF-1 (A) and LEF-1 (B) expression levels in different astrocytoma grades.

Table 1. The percent of expression levels of transcription factors in different astrocytoma grades.

	Strong Expression I, II	Moderate expression III	Weak or lack of expression IV, V
Pilocytic astrocytomas			
TCF-1	15.8%	21%	63.2%
LEF-1	22.8%	9%	68.2%
Diffuse astrocytomas			
TCF-1	53%	23.5%	23.5%
LEF-1	61.1%	27.7%	11.1%
Anaplastic astrocytomas			
TCF-1	53%	13%	33%
LEF-1	33.3%	33.3%	33.3%
Glioblastoma			
TCF-1	51.6%	25.8%	23%
LEF-1	71%	19.4%	9.6%

I, II, III, IV, V denote the categories of immunohistochemical staining as defined in Results.

TCF-1 and LEF-1 in astrocytic tumors

that significant differences in protein expression levels were associated to the values of TCF-1 weak, LEF-1 strong and LEF-1 weak to the malignancy grades.

Analysis of variances performed on the total sample also indicated significant differences in the values of TCF-1 weak ($F=2.804$; $p=0.045$), LEF-1 strong ($F=5.498$; $p=0.002$) and LEF-1 weak ($F=4.255$; $p=0.008$) with regard to malignancy grade. Glioblastomas were characterized by –in relative terms– the lowest values for weak expression of TCF-1 and LEF-1, combined with the highest values of LEF-1 strong, indicating that in this grade strong expression of LEF-1 is present. The opposite was true for the pilocytic astrocytoma, the benign reference, which was characterized by – in relative terms– the highest values of TCF-1 and LEF-1 weak expressions combined with the lowest value of LEF-1 strong expression.

This trend is additionally confirmed by correlation analysis that indicates a strong positive correlation (Pearson's correlation=0.473; $p=0.0001$) between the weakest expression of TCF-1 and LEF-1. Of interest is also the fact that in our dataset the strongest expressions of TCF-1 and LEF-1 were significantly positively correlated (Pearson's correlation=0.451; $p=0.0001$).

As previously mentioned, an additional goal of this study was to determine whether the values of a single or combination of variables can be used to determine the presence of glioblastomas. To this end the collected data were analyzed by unifactorial and multifactorial analyses.

Discriminant function analysis is based on the assumption that astrocytomas and glioblastomas will produce a bimodal curve. To this end we tested the potential dimorphism in our dataset with unifactorial statistics using the Index $M_{\text{astrocytomas}} / M_{\text{glioblastomas}} \times 100$, where $M_{\text{astrocytomas}}$ is the mean value for astrocytomas grades II-III and $M_{\text{glioblastomas}}$ is the average value for glioblastomas. Table 2 shows the descriptive statistics for both groups, including the means and standard deviations, for each variable. As expected, and previously suggested by ANOVA analyses, the index of dimorphism is greater than 100.00 in TCF-1 weak and LEF-1 weak, indicating that in these variables diffuse and anaplastic astrocytomas exhibit

greater values than glioblastomas. More relevant to the success of discriminant function analysis, the F-ratios for two variables (LEF-1 strong and LEF-1 weak) indicate that differences between astrocytomas grades II and III on one side and glioblastomas on the other are either statistically significant ($p<0.02$) or marginally not significant ($p<0.06$).

Once the existence of a significant dimorphism was determined, multifactorial statistics were performed using the stepwise discriminant function procedure. This procedure calculates the pooled within-group covariance matrix, eigenvalues, canonical correlations, Wilk's λ , values of the standardized and unstandardized discriminant function coefficients and group centroids, as well as the accuracy of the functions. The stepwise discriminant function analysis employs a minimum partial F value to enter of 3.84, and a maximum partial F value to remove of 2.71. After analyzing all of the available variables, the discriminant function procedure selected one variable - strong LEF-1 expression, which could discriminate between astrocytomas (II, III) and glioblastomas.

The selected variable with its attending standardized and unstandardized discriminant function coefficients, as well as sectioning and demarking points are presented in Table 3. Standardized coefficients indicate the relative contribution of each variable to the function and are, therefore, in cases when only one variable is selected always equal to 1.00. Unstandardized coefficients are used to calculate discriminant function scores from the raw data. A discriminant score is obtained by multiplying the variable with its unstandardized coefficient and then adding the constant. If the score is greater than the sectioning point (the midpoint between the two group centroids) the individual is considered to have a glioblastoma, while a lower score indicates an astrocytoma. In cases like this, however, when just a single variable is employed it is simpler to compare the value of the analyzed specimen to a demarking point. The demarking point is the simple average of the means for astrocytomas and glioblastomas and in our data set it is 36.72. Therefore, strong LEF-1 expression in 37 or more cells in a sample was classified as a glioblastoma while strong LEF-1 expression in less than 37 cells was

Table 2. Dimorphism and unifactorial statistics of the analyzed variables.

Variable	Astrocytomas II, III (n=32)		Glioblastomas IV (n=31)		Dimorphism	
	Mean	Std. Dev.	Mean	Std. Dev.	Index ¹	F
TCF-1 strong	24.47	18.63	32.13	25.71	76.159	1.842
TCF-1 moderate	78.09	28.47	77.16	30.32	101.205	0.016
TCF-1 weak	124.38	27.76	116.03	63.41	107.196	0.463
LEF-1 strong	27.76	25.18	45.68	28.81	60.771	7.040*
LEF-1 moderate	80.55	31.48	73.13	29.15	110.146	0.953
LEF-1 weak	118.73	33.74	100.61	40.98	118.010	3.745**

¹Index: $M_{\text{astrocytomasII,III}} / M_{\text{glioblastomasIV}} \times 100$; * significant at $P<0.02$, ** significant at $P<0.05$.

Table 3. Standardized and unstandardized discriminant function coefficients and sectioning, and demarking points.

Variable chosen by the stepwise discriminant function	Standardized coefficient	Unstandardized coefficient
LEF-1 strong	1.000	0.037
		Constant = -1.349
	Sectioning point = 0.01	
	Demarking point =astrocytoma II,III >36.72>glioblastoma IV	

II, III, IV denote the WHO grade.

classified as an astrocytoma. Reclassification of the cases using the leave-on-out method shows that the variable LEF-1 strong expression achieves an overall accuracy of 67.2% when differentiating between astrocytomas II and III and glioblastomas (Table 4).

Discussion

When thinking about transcription in Wnt signaling one must consider the fact that it is primarily mediated by the LEF/TCF family of transcription factors. Inside the nucleus the LEF/TCF family of transcription factors creates complex signals that may involve many auxiliary factors in order to mediate activation as well as repression of transcription.

Our results on LEF-1 and TCF-1 transcription factors bring novel insights on wnt transcription regulation in the astrocytic branch of brain tumors. Since the founding members of the TCF/LEF family are TCF-1 and LEF-1 (van Noort and Clevers, 2002; Ravindranath et al. 2008), we aimed to investigate the combination of those proteins in our tumor samples. In the present study we demonstrated that TCF/LEF expression was varied among different astrocytic malignancy grades. The highest malignancy grade was characterized by strong TCF-1 expression in 51.6% of samples and strong LEF-1 expression in 71% of samples. In contrast, benign pilocytic astrocytomas had weak or no TCF-1 and LEF-1 expression in 63.2% and 68.2% of samples, respectively. Statistical analysis additionally confirmed significant differences in protein expression levels associated to 3 important values, TCF-1 weak, LEF-1 weak and LEF-1 strong. Moderate TCF-1 or LEF-1 expressions were not as indicative of malignancy progression. Results from grade II astrocytomas confirmed our results while that of grade III astrocytomas were not as consistent. In addition, in discriminant function analysis, F-ratios for strong and weak LEF-1 expression showed that LEF-1 expression was significantly different between astrocytomas II and III and glioblastomas ($p < 0.02$). Our study also showed that grade I astrocytomas differ from malignant astrocytomas which contributes to their characterization as slow-growing and less aggressive (i.e., non-infiltrative).

Table 4. Accuracy of prediction.

Variable	Astrocytoma II, III		Glioblastoma IV		Average	
	N	%	N	%	N	%
LEF-1 strong	25/33	75.8	18/31	58.1	43/64	67.2

II, III, IV denote the WHO grade.

Our results demonstrated that the expression of wnt transcription factors was inherent to higher grade gliomas. Our understanding of the involvement of LEF-1 and TCF-1 and their interplay in the same patient in this specific tumor type is still rudimentary. Very few studies have investigated the role of the Wnt pathway in human astrocytomas (Sareddy et al., 2009, 2012). Sareddy and coworkers investigated LEF-1 and TCF-4 and demonstrated that both of them were upregulated in astrocytomas and positively correlated with histological malignancy. This is consistent with our findings although the combination of TCF/LEF family members is different. Nevertheless, in their set of 32 astrocytic tumors LEF-1 and TCF-4 exhibited a highly significant positive correlation, which was also the case with our data on LEF-1 and TCF-1 members of this transcription factor family.

Besides TCF-1/LEF-1 roles in colon and colorectal cancer, the status of TCF-1/LEF-1 expression has been reported for several other cancer types, namely renal cell carcinoma, lung adenocarcinoma, breast carcinoma, several specific types of leukemias and lymphomas, and TCF-1 was found to be expressed in melanoma (Nguyen et al., 2005; Ravindranath et al., 2008; Najdi et al., 2011; Nikuseva Martic et al., 2013).

Although our results on LEF-1 and TCF-1 may indicate that all TCF/LEF members have redundant functions enabling one member to replace the job of any other, it has been demonstrated that this is not true. It has been shown that the expression patterns of LEF/TCF loci and isoforms differs in normal human colon in comparison to colon cancer. For example, in normal colon cells, TCF-1 and TCF-4, but not TCF-3 and LEF-1, are expressed (Najdi et al., 2011). In colon cancer TCF-4 is expressed as a full-length form with 2 DNA binding domains, but TCF-1 expression changes from normal circumstances; it is expressed as a different full-length isoform that enables maximum beta-catenin binding and oncogenic effect. As far as LEF-1 expression is concerned in colorectal cancer, its full-length isoform expression emerges. Thus through the oncogenic process, beta-catenin may be able to change protein partners to form strong transcription complexes.

It has been shown on many occasions that the influence of TCF/LEF family members on expression of Wnt target genes is highly dependent on the context. Nevertheless, the role of TCF/LEF members in specific cell types is still unknown, especially their expression

levels in the astrocytic branch of brain tumors. It has been shown that Tcf/Lef genes have tissue-specific expression patterns and that different expression patterns are associated with the tumorigenic transformation.

Considering the fact that beta-catenin associates with TCF/LEF transcription factors when transferred in the nucleus (Daniels and Weis, 2005), it is definitely interesting to investigate the expression patterns of beta-catenin. We have previously investigated beta-catenin expression in neuroepithelial brain tumors, including astrocytic brain tumors (Nikuseva Martic et al., 2010). In that study, we found that beta-catenin was upregulated in 53.1% of our samples. Moreover, beta-catenin accumulated in the nucleus of 59.4% of these tumors (21.4% and 33.3% of which were glioblastomas and astrocytomas, respectively). A paper by Schülle et al. (2012) demonstrates that beta-catenin's expression significantly correlated with higher astrocytoma WHO grade, while Western blot analysis presented by Sareddy et al. (2009) demonstrated that the relative protein levels of beta-catenin were progressively increased from low grade (II) to higher grade (III, IV) astrocytomas.

Our study examined the relationships between TCF-1 and LEF-1 expression in astrocytic brain tumors for the first time. TCF-1 and LEF-1 positivity was not mutually exclusive. Moreover, specific strong ($p=0.0001$) and weak ($p=0.0001$) expression combinations were significantly positively correlated. Recent studies have also demonstrated that Wnt pathway activation depends on the invasive capacity of glioblastoma (Kahlert et al., 2012) and that these invasive properties are derived from oncogenic LEF-1 activity (Liu et al., 2012). LEF-1 belongs to the HMG protein family, which when overexpressed, leads to enhanced tumor invasiveness and induces the epithelial-to-mesenchymal transition in glioblastomas (Kim et al., 2002; Nguyen et al., 2005; Kriegl et al., 2010).

An additional goal of our study was to determine whether a single or combination of variable(s) could be used to determine the presence of glioblastomas. After analyzing all the available variables, strong LEF-1 expression alone emerged as a discriminator between astrocytomas and glioblastomas. Strong LEF-1 expression in 37 or more tumor cells was indicative of a glioblastoma while strong LEF-1 expression in less than 37 tumor cells was indicative of an astrocytoma. This suggests that LEF-1 may serve as a potential marker for malignant transformation. LEF-1 negativity has previously been associated to survival in colorectal cancer patients (Kriegl et al., 2010). This suggests that similar expression patterns between different cancers may exist.

Based on our results, we conclude that astrocytic brain tumors are characterized by elevated TCF-1 and LEF-1 expression. In particular, LEF-1, which was more strongly expressed than TCF-1 in the majority of samples, is characteristic of malignant astrocytic brain tumors.

Acknowledgements. This work was supported by grants 1.2.1.19. University of Zagreb, Croatian Science Foundation and 108-1081870-1905 from the Ministry of Science Sports and Education, Republic of Croatia. We would also like to thank Professor Mario Slaus for his valuable input.

Conflict of interest. The authors declare no conflict of interests.

References

- Arce L., Yokoyama N.N. and Waterman M.L. (2006). Diversity of LEF/TCF action in development and disease. *Oncogene* 25, 7492-7504.
- Arce L., Pate K.T. and Waterman M.L. (2009). Groucho binds two conserved regions of LEF-1 for HDAC-dependent repression. *BMC Cancer* 9, 159.
- Brantjes H., Barker N., van Es J. and Clevers H. (2002). TCF: Lady Justice casting the final verdict on the outcome of Wnt signalling. *Biol. Chem.* 383, 255-261.
- Cadigan K.M. and Waterman M.L. (2012). TCF/LEFs and Wnt signaling in the nucleus. *Cold Spring Harb. Perspect. Biol.* 2012, 4, a007906.
- Coyle-Rink J., Del Valle L., Sweet T., Khalili K. and Amini S. (2002). Developmental expression of Wnt signaling factors in mouse brain. *Cancer Biol. Ther.* 1, 640-645.
- Daniels D.L. and Weis W.I. (2005). β -catenin directly displaces Groucho/TLE repressors from Tcf/Lef in Wnt-mediated transcription activation. *Nat. Struct. Mol. Biol.* 12, 364-371.
- Hanson A.J., Wallace H.A., Freeman T.J., Beauchamp R.D., Lee L.A. and Lee E. (2012). XIAP monoubiquitylates Groucho/TLE to promote canonical Wnt signaling. *Mol. Cell* 45, 619-628.
- Kahlert U.D., Maciaczyk D., Doostkam S., Orr B.A., Simons B., Bogiel T., Reitmeier T., Prinz M., Schubert J., Niedermann G., Brabletz T., Eberhart C.G., Nikkhah G. and Maciaczyk J. (2012). Activation of canonical Wnt/ β -catenin signaling enhances in vitro motility of glioblastoma cells by activation of Zeb1 and other activators of epithelial-to-mesenchymal transition. *Cancer Lett.* 325, 42-53.
- Kim K., Lu Z. and Hay E.D. (2002). Direct evidence for a role of beta-catenin/LEF-1 signaling pathway in induction of EMT. *Cell Biol. Int.* 26, 463-476.
- Klaus A. and Birchmeier W. (2008). Wnt signalling and its impact on development and cancer. *Nat. Rev. Cancer* 8, 8387-8398.
- Kriegl L., Horst D., Reiche J.A., Engel J., Kirchner T. and Jung A. (2010). LEF-1 and TCF4 expression correlate inversely with survival in colorectal cancer. *J. Transl. Med.* 8, 123.
- Liu Y., Yan W., Zhang W., Chen L., You G., Bao Z., Wang Y., Wang H., Kang C. and Jiang T. (2012). MiR-218 reverses high invasiveness of glioblastoma cells by targeting the oncogenic transcription factor LEF1. *Oncol. Rep.* 28, 1013-1021.
- Louis D.N., Ohgaki H., Wiestler O.D., Cavenee W.K., Burger P.C., Jouvet A., Scheithauer B.W. and Kleihues P. (2007). The 2007 WHO classification of tumours of the central nervous system. *Acta Neuropathol.* 114, 97-109.
- Najdi R., Holcombe R.F. and Waterman M.L. (2011). Wnt signaling and colon carcinogenesis: Beyond APC. *J. Carcinog.* 10, 5.
- Nguyen A., Rosner A., Milovanović T., Hope C., Planutis K., Saha B., Chaiwun B., Lin F., Imam S.A., Marsh J.L. and Holcombe R.F. (2005). WNT pathway component LEF1 mediates tumor cell

- invasion and is expressed in human and murine breast cancers lacking ErbB2 (her-2/neu) overexpression. *Int. J. Oncol.* 27, 949-956.
- Nikuseva Martic T., Pecina-Slaus N., Kusec V., Kokotovic T., Musinovic H., Tomas D. and Zeljko M. (2010). Changes of AXIN-1 and β -catenin in neuroepithelial brain tumors. *Pathol. Oncol. Res.* 16, 75-79.
- Nikuseva Martic T., Serman L., Zeljko M., Vidas Z., Gasparov S., Zeljko HM., Kosovic M. and Pecina-Slaus N. (2013). Expression of secreted frizzled-related protein 1 and 3, T-cell factor 1 and lymphoid enhancer factor 1 in clear cell renal cell carcinoma. *Pathol. Oncol. Res.* 19, 545-551.
- Novak A. and Dedhar S. (1999). Signaling through β -catenin and Lef/Tcf. *Cell. Mol. Life Sci.* 56, 523-537.
- Pecina-Slaus N. (2010). Wnt signal transduction pathway and apoptosis: a review. *Cancer Cell Int.* 10, 22.
- Ravindranath A., O'Connell A., Johnston P.G. and El-Tanani M.K. (2008). The role of LEF/TCF factors in neoplastic transformation. *Current Mol. Med.* 8, 38-50.
- Sareddy G.R., Panigrahi M., Challa S., Mahadevan A. and Babu P.P. (2009). Activation of Wnt/ β -catenin/Tcf signaling pathways in human astrocytomas. *Neurochem. Int.* 55, 307-317.
- Sareddy G.R., Geeviman K., Panigrahi M., Challa S., Mahadevan A. and Babu P.P. (2012). Increased beta-catenin/Tcf signaling in pilocytic astrocytomas: a comparative study to distinguish pilocytic astrocytomas from low-grade diffuse astrocytomas. *Neurochem. Res.* 37, 96-104.
- Schüle R., Dictus C., Campos B., Wan F., Felsberg J., Ahmadi R., Centner F.S., Grabe N., Reifenberger G., Bermejo J.L., Unterberg A. and Herold-Mende C. (2012). Potential canonical Wnt pathway activation in high-grade astrocytomas. *ScientificWorldJournal* 2012, 697313.
- Sellak H., Wu S. and Lincoln T.M. (2012). KLF4 and SOX9 transcription factors antagonize β -catenin and inhibit TCF-activity in cancer cells. *Biochim. Biophys. Acta* 1823, 1666-1675.
- Shitashige M., Hirohashi S. and Yamada T. (2008). Wnt signaling inside the nucleus. *Cancer Sci.* 99, 631-637.
- Vacik T. and Lemke G. (2011). Dominant-negative isoforms of Tcf/Lef proteins in development and disease. *Cell Cycle* 10, 4199-4200.
- van Noort M. and Clevers H. (2002). TCF transcription factors, mediators of Wnt-signaling in development and cancer. *Dev. Biol.* 244, 1-8.
- Wallmen B., Schrempp M. and Hecht A. (2012). Intrinsic properties of Tcf1 and Tcf4 splice variants determine cell-type-specific Wnt/ β -catenin target gene expression. *Nucleic Acids Res.* 40, 9455-9469.
- Xu W. and Kimelman D. (2007). Mechanistic insights from structural studies of β -catenin and its binding partners. *J. Cell Sci.* 120, 3337-3343.

Accepted May 23, 2014