

A to Z ORTHODONTICS

Volume: 08

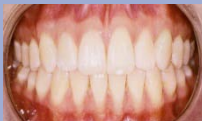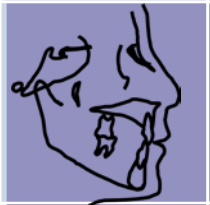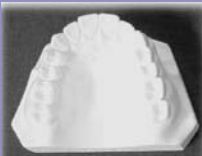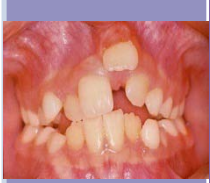CEPHALOMETRY

Dr. Mohammad Khursheed Alam
BDS, PGT, PhD (Japan)

ISBN 978-967-5547-97-3



9 789675 547973



First Published November 2011

© **Dr. Mohammad Khursheed Alam**

© All rights reserved. No part of this publication may be reproduced stored in a retrieval system, or transmitted, in any form or by any means, electronic, mechanical, photocopying, recording or otherwise, without prior permission of author/s or publisher.

ISBN: 978-967-5547-97-3

Correspondance:

Dr. Mohammad Khursheed Alam

Senior Lecturer

Orthodontic Unit

School of Dental Science

Health Campus, Universiti Sains Malaysia.

Email:

dralam@gmail.com

dralam@kk.usm.my

Published by:

PPSP Publication

Jabatan Pendidikan Perubatan, Pusat Pengajian Sains Perubatan,

Universiti Sains Malaysia.

Kubang Kerian, 16150. Kota Bharu, Kelatan.

Published in Malaysia

Contents

1. What is Cephalogram.....	3
2. Equipments / Apparatus.....	3
3. Types of Cephalostat.....	3
4. Materials required for Cephalometric tracing.....	3
5. Standardized procedure.....	3-4
6. Anatomical landmarks use in Cephalometric tracing..	5-6
7. Horizontal and Vertical planes.....	7-8
8. Various Cephalometric analyses.....	8
9. Dental assessments.....	9
10. Registration point.....	9
11. Importance of Cephalometry.....	9-10
12. Short Note on: SNA.....	10
13. Short Note on: SNB.....	11
14. Short Note on: ANB.....	11
15. Short Note on: Interincisal Angle.....	12

Cephalogram

It is a method of assessing the relationship of cranial, facial and dental structures on radiograph which are taken in a standardized manner.

- ❑ Paccini in 1922 published the first paper but
- ❑ Broadbent (USA) and Hofrath (Germany) introduced and popularised it in 1931.
- ❑ Clinical application was done by Down's in 1948.

Equipments / Apparatus

- Head folding device or Cephalostat (Head holder).
- X-ray source
- Cassette holder

There are 2 types of Cephalostat -

1. Broadbent type: 2 X-ray sources and 2 holders. Lateral and posterior anterior x-ray can be done without moving the subject that's why it is more precise.

(Disadvantage: occupies more space and expensive)

2. Highley type: 1 x-ray source and holder. Here subject need to move.

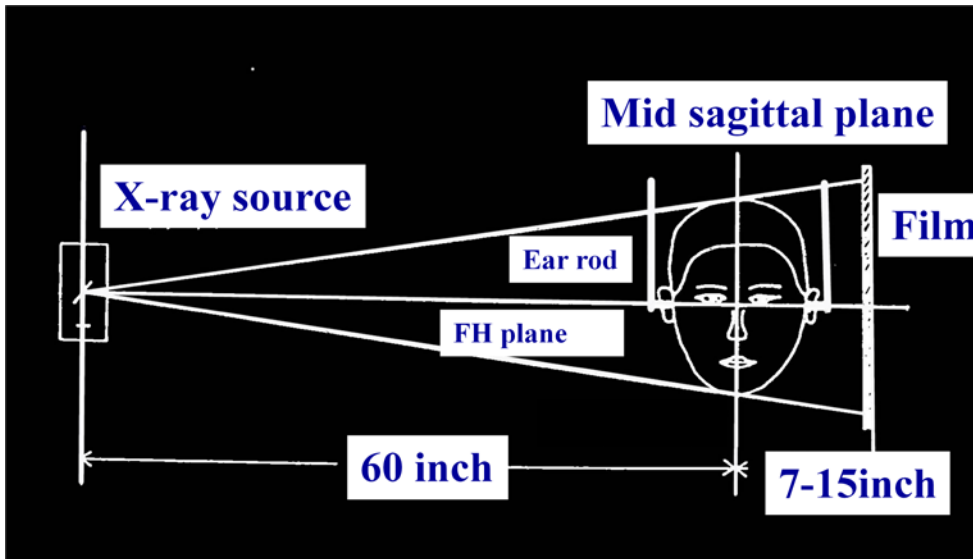
Materials required for Cephalometric tracing

- ❖ *Light box*
- ❖ *X-ray*
- ❖ *Tracing paper*
- ❖ *Geometry Box*
- ❖ *Sharp pencil*
- ❖ *Eraser*
- ❖ *Sharpener*
- ❖ *Hand gloves*

Procedure

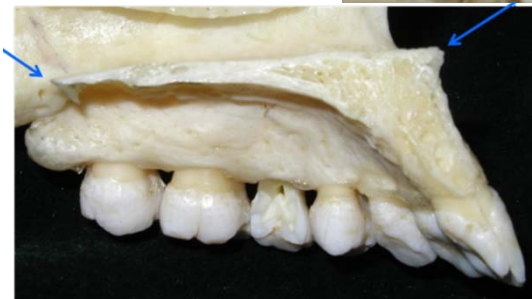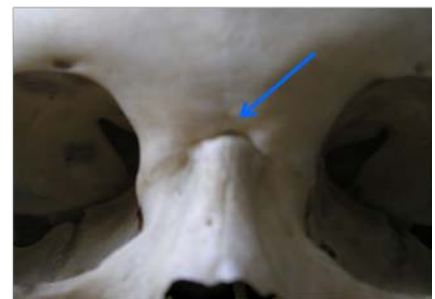
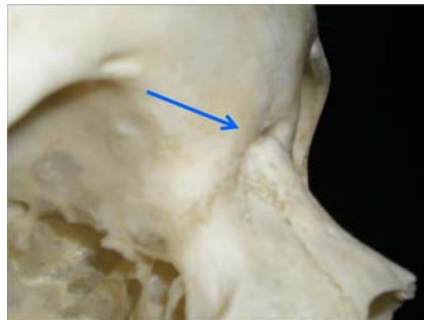
- ✓ Patient's position in such a manner so that the Frankfurt horizontal plane is parallel to the floor.

- ✓ Ear rods should fix the position of the head.
- ✓ Patient is asked to close the mouth to centric occlusion.
- ✓ Vertically the head position is fixed by orbital pointer in the orbitale.
- ✓ The distance from the mid saggital plane of the patient head to the x-ray tube is fixed at 150 cm / 60 inch / 5ft and the distance from the mid saggital plane to the x-ray film vary from 6-7 inch.

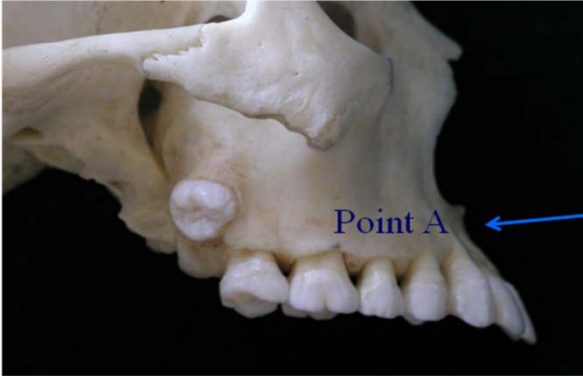


Anatomical landmarks use in lateral view:

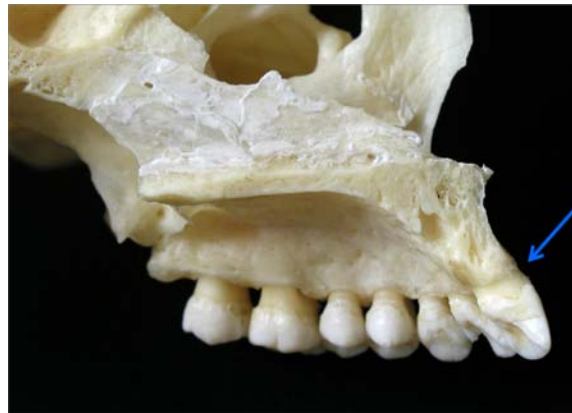- 1. Nasion {N or Na}: the intersection of the internal nasal suture with the naso-frontal suture in the mid-sagittal plane.



- 2. Anterior nasal spine {ANS}: the most anterior point of the maxilla at the level of the palate.
- 3. Posterior nasal spine {PNS}: the tip of the posterior spine of the palatine bone in the hard palate.



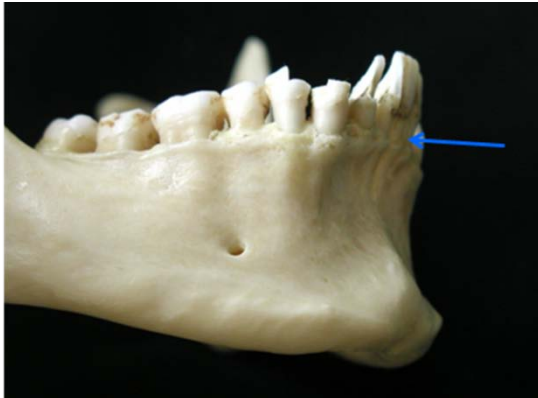
- 4. Superior spinale / point A: the deepest midline point on the premaxilla between ANS and sup. Prosthion.



- 5. Superior prosthion or supradentale: it is the most anterior-inferior point on the maxillary alveolar process. Usually found near the cemento-enamel junction of the maxillary central incisor.

- 6. Inferior prosthion or infradentale {Id}: it is the most anterior-inferior point on the mandibular alveolar process. Usually found near the cemento-enamel junction of the mandibular central incisor.

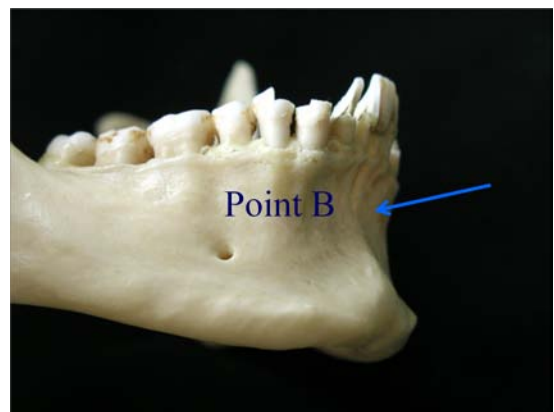
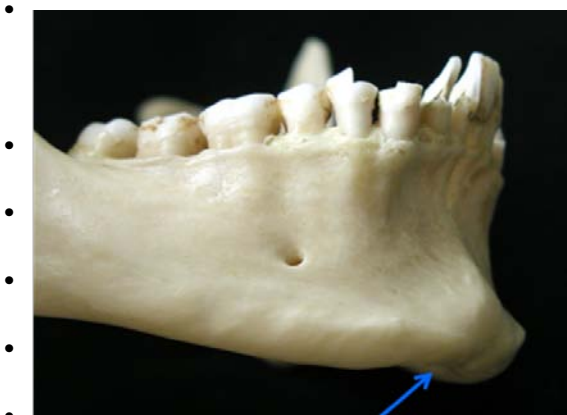- 7. Supramentale or Point B: the most posterior point in the concavity infradentale and pogonion.



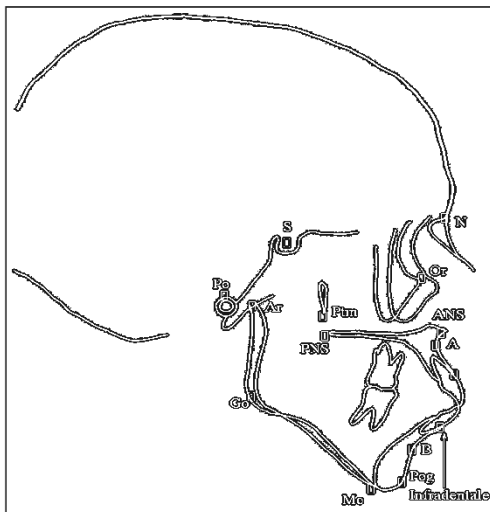
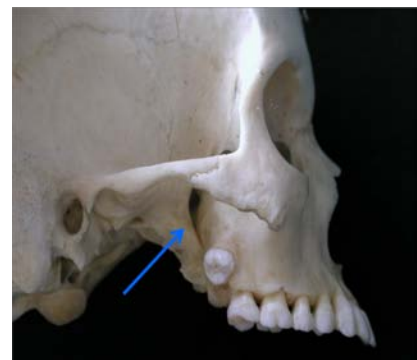
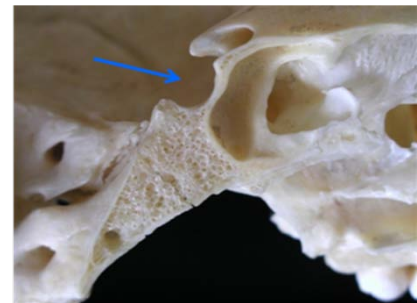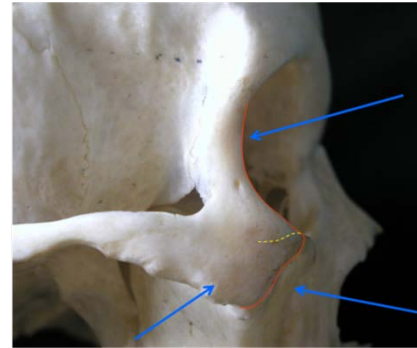
- 8. Pogonion {Pog}: most anterior in the contour of the chin.

- 9. Gnathion {Gn}: the most anterior inferior point on the contour of the chin.

- 10. Menton {Me}: the lower most point on the symphyseal outline on the chin.

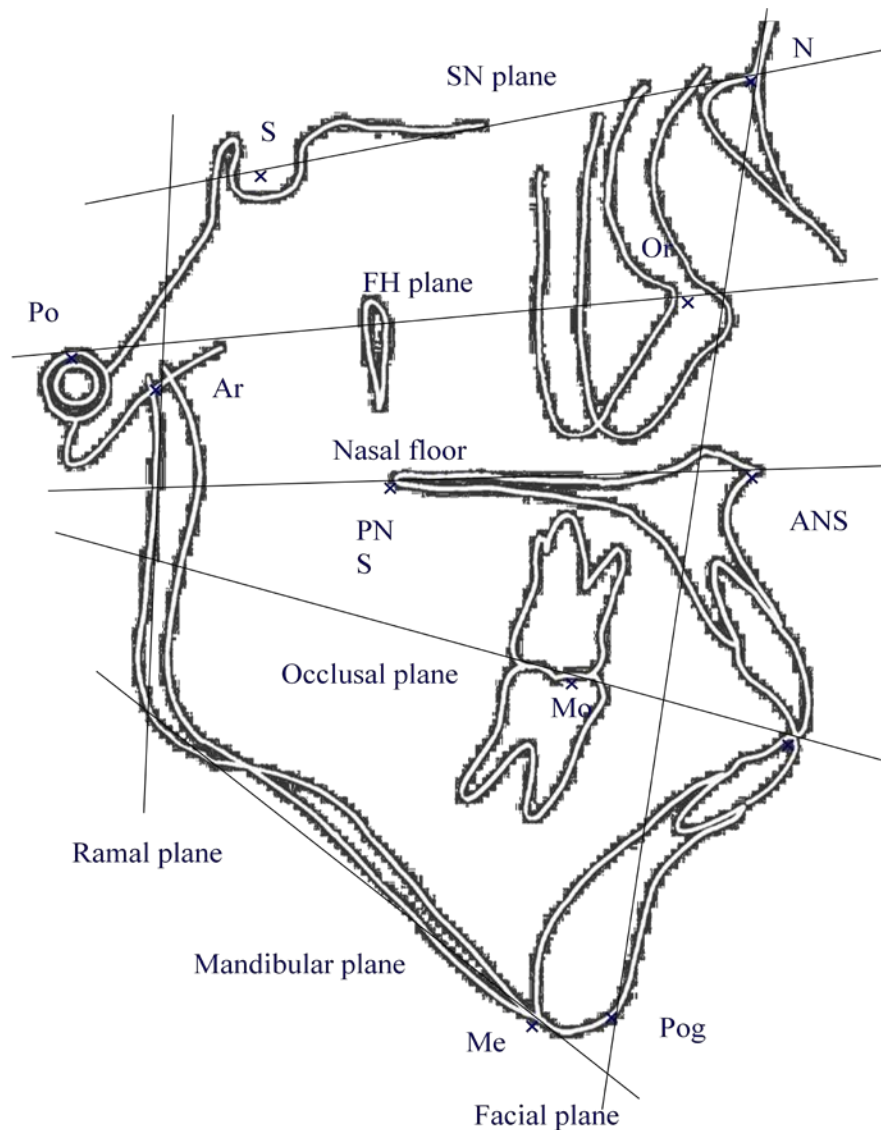


- 11. Gonion {Go}: most posterior inferior point at the angle of the mandible. It is the bisecting of the angle formed by mandibular and ramal plane.
- 12. Orbitale {Or}: the lowest point on the lower margin of the bony orbit.
- 13. Porion {Po}: the midpoint on the upper edge of the external auditory meatus.
- 14. Sella {S}: it is the center of the hypophyseal fossa.
- 15. Condylion: it is most posterior superior point on the condyle of the mandible.
- 16. Basion {Ba}: the lower most point on the anterior margin of the foramen magnum.
- 17. Bolton point {Bo}: the highest point in the upward curvature of the retro-condylar fossa.
- 18: Pterigo maxillary fissure {Ptm}: it is the bilateral tear drop shaped area on radio-lucency, the anterior wall represents the retro molar tuberosity of the maxilla and posterior wall represents the anterior curve of the pterigoid process of the sphenoid bone.
- 19. Key ridge {KR}: it is lowest point on the outline of the zygoma.
- 20. Point D: the center of the cross section of the body of the symphysis.



Horizontal planes:

- 1. FH plane (Frankfurt horizontal plane): this plane drawn from porion to orbitale. The name was given in conference of anthropology held at Frankfurt at the end of 19th century.
- 2. SN plane (Sella nasion plane): SN plane is easiest to establish with minimum error. SN plane represents the anterior cranial base. The cranial base undergoes very little change after the age of 6-7 years. However end point may drift either forward or vertically giving rise to error.



- 3. Palatal or Maxillary plane: it is the plane paralleling the floor of the nose or it is a line passing through the ANS and PNS.

- 4. Occlusal plane: it is the plane passing midway between the cusp tips of the upper and lower first permanent molar and a point bisecting the over bite anteriorly.
- 5. Mandibular plane: the mandibular plane constructed as a tangent to the lower border or it is a plane joining gonion and menton or gonion and gnathion. Any one method should be used consistently.
- 6. Basion nasion plane: it is used in Ricketts analysis.
- 7. Bolton nasion plane: it is a plane joining bolton and nasion.

Vertical planes:

1. Facial plane: it is a plane joining nasion and pogonion
2. Ramal plane: it is a plane joining articulare to gonion.

Various cephalometric analyses:

1. Steiner analysis: SN plane is used as the plane of reference. It is one of the most important analyses. This analysis was developed and promoted by Cecile Steiner in 1950.

2. Down's analysis: FH plane is used as the plane of reference. It was proposed by Down's. This analysis indicates whether the dysplasia is in the facial skeleton or in the dentition or both.

3. Tweed analysis: 3 planes are used in this analysis- a. FH plane, b. Mandibular plane and c. Long axis of lower incisor.

Tweeds findings are A. FMA = 25 degree, B. FMIA = 65 degree and IMPA = 90 degree.

4. Sassouni analysis: this analysis emphasizes vertical and horizontal proportion. Plane are used: a. SN plane, b. FH plane, c. Palatal plane, d. Occlusal plane and e. Mandibular plane. If the plane are nearly parallel so that they converge far behind the face.

5. Wits analysis: it is based on projection of point A and B to Occlusal plane along which the linear difference between these two points is measured. Usually the projection intersects at very nearly the same point. The magnitude of discrepancy in class II can be estimated by how many mm, point A is in front of point B and vice versa for class III.

6. Ricketts analysis

7. Mc'namaras analysis

Dental assessments:

Assessments of upper incisor:

- A. Upper 1/1 to SN plane
- B. Upper 1/1 to FH plane
- C. Upper 1/1 to maxillary plane
- D. Upper 1/1 to NA plane
- E. Upper 1/1 to NA plane in mm (Linear measurement)

If values are average = Average position

If values increase = proclined incisor in relation to particular plane.

If values decrease = retroclined incisor in relation to particular plane.

Assessments of lower incisor:

- A. lower 1/1 to Mandibular plane
- B. lower 1/1 to occlusal plane
- C. lower 1/1 to NB plane
- D. lower 1/1 to NB plane in mm

If values are average = Average position

If values increase = proclined incisor in relation to particular plane.

If values decrease = retroclined incisor in relation to particular plane.

Registration point:

If a perpendicular line is drawn from sella to bolton nasion plane then the midpoint of that perpendicular line is known as registration point.

Importance of Cephalometry

1. for the study of growth and development: Serial radiograph is taken with standardized head position enable the study growth of jaw and dentition.
2. for diagnosis:
 - a. To assess the resting lip posture, position of tongue, soft palate and posterior pharyngeal wall.

- b. To assess the relation of lower lip to upper one.
- c. To assess the adequacy of dental base to accommodate all teeth.
- d. To assess the presence, position and angulations of any unerupted teeth.
- e. To assess any pathology or abnormality of teeth, bone and soft tissue.
- f. To assess the length of incisors and their inclination.
- g. To assess the skeletal pattern.

3. For treatment planning, prediction of growth and

Assessment of prognosis:

- a. Assessment of change in upper and lower angulations and position needed for achieving normal overbite and overjet.
- b. Assessment of the extend of overbite which can be corrected.
- c. For deciding extraction, disimpaction etc.
- d. To assess whether distal movement of buccal teeth possible or not.
- e. Accurate planning before surgical correction.
- f. Assessment of future growth (V.T.O- Visualized treatment objective).

4. for analysis of tooth movement, anchorage control and prognosis of treatment.

5. Final assessment of the case.

SNA ANGLE

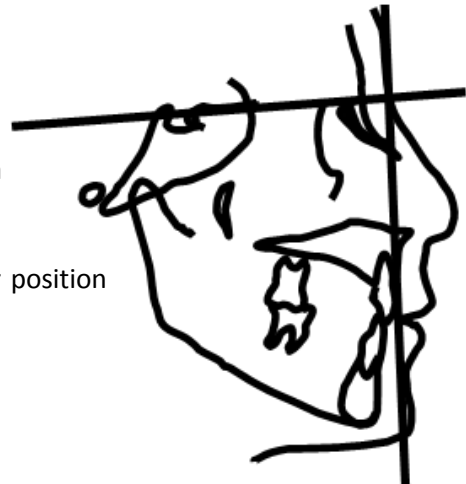
Definition: Angle formed by the intersection of S.N plane and a line joining nasion and point A.

Importance: This angle indicates the relative antero posterior position of the maxilla in relation to the anterior cranial base.

Mean value: 82°

The angle may be

- 1. Normal – Average position of maxilla in relation to the anterior cranial base.
- 2. Increased – Maxilla prognathic (as in class II)
- 3. Decreased – Maxilla retrognathic (as in class III)



SNB ANGLE

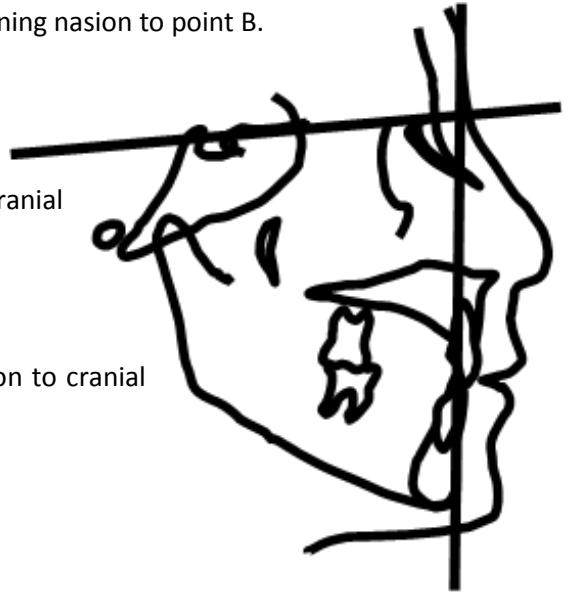
Definition: It is the angle b/w the SN plane and a line joining nasion to point B.

Mean value => 80°

Importance => Indicates the antero posterior positioning of the mandible in relation to the ant. cranial base

The angle may:

1. Normal: Average position of mandible in relation to cranial base.
2. Increased: Mandible prognathic. (class III)
3. Decreased: Mandible retrognathic (class II)



ANB ANGLE

Definition – This angle is formed by the intersection of lines joining nasion to point A and nasion to point B.

Indicates – It denotes the relative position of the maxilla and mandible each other on skeletal bases.

MEAN VALUE

SK Class I – Angle is $2-4^{\circ}$

SK Class II - $>4^{\circ}$

SK Class III - $<2^{\circ}$

Angle May be

1. Average.
2. Increased.
3. Decreased.



INTER INCISAL ANGLE

Definition:

It is the angle formed between the long axis of the upper and lower incisors.

Average value:

Range => between 130° to 150.5°

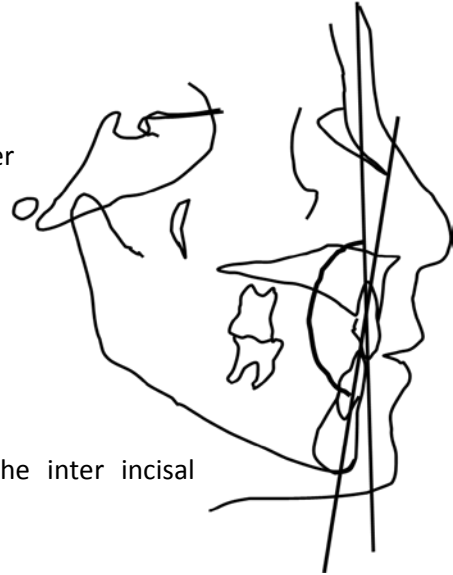
Importance:

The value of this angle helps us to know about the inter incisal relationship.

The angle may be:

1. Average angle => average inclination of incisors.
2. Increased angle => retruded incisor. Class II div 2 case.

Decreased angle => protruded incisors. Class I bi max. Protrusion, Class II div 1 case.



Bibliography:

1. Bhalajhi SI. Orthodontics – The art and science. 4th edition. 2009
2. Gurkeerat Singh. Textbook of orthodontics. 2nd edition. Jaypee, 2007
3. Houston S and Tulley, Textbook of Orthodontics. 2nd Edition. Wright, 1992.
4. Iida J. Lecture/class notes. Professor and chairman, Dept. of Orthodontics, School of dental science, Hokkaido University, Japan.
5. Lamiya C. Lecture/class notes. Ex Associate Professor and chairman, Dept. of Orthodontics, Sapporo Dental College.
6. Laura M. An introduction to Orthodontics. 2nd edition. Oxford University Press, 2001
7. McNamara JA, Brudon, WI. Orthodontics and Dentofacial Orthopedics. 1st edition, Needham Press, Ann Arbor, MI, USA, 2001
8. Mitchel. L. An Introduction to Orthodontics. 3 editions. Oxford University Press. 2007
9. Mohammad EH. Essentials of Orthodontics for dental students. 3rd edition, 2002
10. Proffit WR, Fields HW, Sarver DM. Contemporary Orthodontics. 4th edition, Mosby Inc., St.Louis, MO, USA, 2007
11. Sarver DM, Proffit WR. In TM Graber et al., eds., Orthodontics: Current Principles and Techniques, 4th ed., St. Louis: Elsevier Mosby, 2005
12. Samir E. Bishara. Textbook of Orthodontics. Saunders 978-0721682891, 2002
13. T. M. Graber, R.L. Vanarsdall, Orthodontics, Current Principles and Techniques, "Diagnosis and Treatment Planning in Orthodontics", D. M. Sarver, W.R. Proffit, J. L. Ackerman, Mosby, 2000
14. Thomas M. Graber, Katherine W. L. Vig, Robert L. Vanarsdall Jr. Orthodontics: Current Principles and Techniques. Mosby 9780323026215, 2005
15. William R. Proffit, Raymond P. White, David M. Sarver. Contemporary treatment of dentofacial deformity. Mosby 978-0323016971, 2002
16. William R. Proffit, Henry W. Fields, and David M. Sarver. Contemporary Orthodontics. Mosby 978-0323040464, 2006
17. Yoshiaki S. Lecture/class notes. Associate Professor and chairman, Dept. of Orthodontics, School of dental science, Hokkaido University, Japan.
18. Zakir H. Lecture/class notes. Professor and chairman, Dept. of Orthodontics, Dhaka Dental College and hospital.



Dedicated To

My Mom, Zubaida Shaheen
My Dad, Md. Islam
&
My Only Son
Mohammad Sharjil

Acknowledgments

I wish to acknowledge the expertise and efforts of the various teachers for their help and inspiration:

1. Prof. Iida Junichiro – Chairman, Dept. of Orthodontics, Hokkaido University, Japan.
2. Asso. Prof. Sato yoshiaki –Dept. of Orthodontics, Hokkaido University, Japan.
3. Asst. Prof. Kajii Takashi – Dept. of Orthodontics, Hokkaido University, Japan.
4. Asst. Prof. Yamamoto – Dept. of Orthodontics, Hokkaido University, Japan.
5. Asst. Prof. Kaneko – Dept. of Orthodontics, Hokkaido University, Japan.
6. Asst. Prof. Kusakabe– Dept. of Orthodontics, Hokkaido University, Japan.
7. Asst. Prof. Yamagata– Dept. of Orthodontics, Hokkaido University, Japan.
8. Prof. Amirul Islam – Principal, Bangladesh Dental college
9. Prof. Emadul Haq – Principal City Dental college
10. Prof. Zakir Hossain – Chairman, Dept. of Orthodontics, Dhaka Dental College.
11. Asso. Prof. Lamiya Chowdhury – Chairman, Dept. of Orthodontics, Sapporo Dental College, Dhaka.
12. Late. Asso. Prof. Begum Rokeya – Dhaka Dental College.
13. Asso. Prof. MA Sikder– Chairman, Dept. of Orthodontics, University Dental College, Dhaka.
14. Asso. Prof. Md. Saifuddin Chinu – Chairman, Dept. of Orthodontics, Pioneer Dental College, Dhaka.



Dr. Mohammad Khursheed Alam

has obtained his PhD degree in Orthodontics from Japan in 2008. He worked as Asst. Professor and Head, Orthodontics department, Bangladesh Dental College for 3 years. At the same time he worked as consultant Orthodontist in the Dental office named “Sapporo Dental square”. Since then he has worked in several international projects in the field of Orthodontics. He is the author of more than 50 articles published in reputed journals. He is now working as Senior lecturer in Orthodontic unit, School of Dental Science, Universiti Sains Malaysia.

Volume of this Book has been reviewed by:

Dr. Kathiravan Purmal

BDS (Malaya), DGDP (UK), MFDSRCS (London), MOrth (Malaya), MOrth RCS(Edin), FRACPS.
School of Dental Science, Universiti Sains Malaysia.

Dr Kathiravan Purmal graduated from University Malaya 1993. He has been in private practice for almost 20 years. He is the first locally trained orthodontist in Malaysia with international qualification. He has undergone extensive training in the field of oral and maxillofacial surgery and general dentistry.