

Title	Effects of Anthocyanins in Black Currant on Retinal Blood Flow Circulation of Patients with Normal Tension Glaucoma. A Pilot Study
Author(s)	Ohguro, Ikuyo, Ohguro, Hiroshi, Nakazawa, Mitsuru
Citation	弘前医学. 59, 2007, p.23-32
Issue Date	2007-11-15
URL	http://hdl.handle.net/10129/691
Rights	
Text version	publ isher



<http://repository.ul.hirosaki-u.ac.jp/dspace/>

ORIGINAL ARTICLE

EFFECTS OF ANTHOCYANINS IN BLACK CURRANT ON RETINAL BLOOD FLOW CIRCULATION OF PATIENTS WITH NORMAL TENSION GLAUCOMA. A PILOT STUDY

Ikuyo Ohguro¹⁾, Hiroshi Ohguro¹⁾, and Mitsuru Nakazawa²⁾

Abstract Purpose: To investigate the effects of anthocyanins in black currant on retinal blood flow circulation of patients with normal tension glaucoma (NTG).

Methods: Thirty consecutive patients with NTG were included in this study. They were orally administrated anthocyanins extracted from black currant in tablet form once a day for a 6-month period. Systemic blood pressures, intraocular pressures (IOPs), concentrations of the plasma endothelin-1 (ET-1), blood flows at the neuroretinal rim of the optic nerve head and peripapillary retina, and visual field defects were measured before and just after the administration period.

Results: Our study demonstrated that oral administration of anthocyanins tablets significantly increased the blood flows at both neuroretinal rim of the optic nerve head and peripapillary retina ($p < 0.05$), with no significant changes in mean blood pressures or IOPs. Furthermore, none of the subjects showed progression of their visual field defects. We also demonstrated that the oral administration of anthocyanins tablets significantly increased, and thus normalized the concentrations of plasma ET-1 ($p < 0.05$).

Conclusion: These results suggest that anthocyanins orally administrated might be a safe and valuable choice for neuroprotective treatment of patients with NTG.

Hirosaki Med. J. 59: 23—32, 2007

Key words: anthocyanins; ocular blood flow; neuroprotection; normal tension glaucoma; endothelin-1.

原 著

正常眼圧緑内障患者におけるカシスアントシアニンの網膜血流に対する作用

大 黒 幾 代¹⁾ 大 黒 浩¹⁾ 中 澤 満²⁾

抄録 目的：正常眼圧緑内障患者におけるカシスアントシアニンの網膜血流に対する作用について検討する。

対象と方法：対象は弘前大学医学部附属病院眼科緑内障外来に通院中の正常眼圧緑内障患者 30 名である。カシスアントシアニン錠 (50 mg) を毎日 1 回、6 ヶ月間内服してもらい、血圧、眼圧、血中エンドセリン-1 濃度、視神経乳頭および乳頭周囲網膜の血流量、視野障害の程度について、内服期間前後で比較した。

結果：カシスアントシアニン錠の内服により、視神経乳頭および乳頭周囲網膜の血流量は有意に増加したが ($p < 0.05$)、血圧および眼圧には有意な差はみられなかった。また、内服期間後に視野障害の悪化した症例は 1 例もなかった。さらに、カシスアントシアニン錠の内服により血中エンドセリン-1 濃度は有意に増加 ($p < 0.05$) または正常化された。

結論：今回の結果から、カシスアントシアニンの内服投与は正常眼圧緑内障患者にとって安全かつ神経保護治療の有力な選択肢に成り得る可能性が示唆される。

弘前医学 59: 23—32, 2007

キーワード：アントシアニン；眼血流；神経保護；正常眼圧緑内障；エンドセリン-1.

¹⁾ Department of Ophthalmology, Sapporo Medical University School of Medicine

²⁾ Department of Ophthalmology, Hirosaki University Graduate School of Medicine
Correspondence: I. Ohguro

Received for publication, May 8, 2007

Accepted for publication, August 17, 2007

¹⁾ 札幌医科大学医学部眼科

²⁾ 弘前大学大学院医学研究科眼科

別刷請求先：大黒幾代

平成19年5月8日受付

平成19年8月17日受理

Introduction

Glaucomatous optic neuropathy is recognized as one of the major causes of irreversible blindness worldwide¹. It is well known that elevated intraocular pressure (IOP) is the most important risk factor for glaucomatous optic nerve damage. However, lowering the elevated IOP by medications or surgical interventions is also recognized to be insufficient to prevent the progression of glaucomatous optic neuropathy²⁻⁴. In addition, according to a recent clinical survey conducted in Japan (Tajimi Study)⁵, one has glaucoma for 14 Japanese people above the age of 40, increasing with advancing age, and the commonest type of glaucoma (more than 80% of total glaucoma) is normal tension glaucoma (NTG). These observations suggest that some unknown factors independent of IOP are involved in the etiology of glaucoma.

Retinal and optic blood supply is thought to be a factor causing glaucomatous optic neuropathy, especially in NTG and it is well established that disc hemorrhages are more likely to exist in patients with NTG than in those with primary open angle glaucoma (POAG)⁶. It was also reported that women with collagen disease have a high susceptibility to glaucoma⁷. We have attempted to discover the clinical factors related to glaucoma etiology, and recently found that platelet aggregation ability is remarkably increased in patients with NTG compared with in those with POAG or normal subjects⁸. Furthermore, we also revealed that the concentrations of the plasma endothelin-1 (ET-1), an endogenous peptide with strong vasoconstrictive effect, were significantly lower in patients with NTG (66.9 ± 8.1 years old, 3.34 ± 1.27 pg/ml) than in normal subjects (60.5 ± 5.0 years old, 4.39 ± 1.34 pg/ml)⁹. Taken together, it is suggested that circulatory disturbances at the optic nerve heads are crucially involved in the etiology of NTG.

Anthocyanins are kinds of polyphenols, rich in natural diets such as red wine, cocoa and berries, and are known to have healthy effects¹⁰. The anthocyanins in black currant in particular have been implicated in improvement of visual functions, such as dark adaptation¹¹, transient refractive alternation¹². Matsumoto¹³ reported that significant amounts of anthocyanins were transferred into choroids and retina, and ciliary body after systemic administration of black currant and that anthocyanins components isolated from black currant activated ET-1 receptor (ET_B receptor) distributed in the ciliary smooth muscle and pigment epithelium, resulting in relaxation of the bovine ciliary smooth muscle. These observations suggested that anthocyanins may alter the metabolism of ET-1 through ET-1 receptors, and might affect the hemodynamics of ocular blood flow, causing alternation of blood flow at optic nerve heads.

The aim of this study is to elucidate the effect of orally administered anthocyanins extracted from black currant on glaucomatous optic neuropathy in patients with NTG, by evaluating the changes in concentration of plasma ET-1, blood flow at optic nerve heads and visual field defects.

Subjects and Methods

The present study was approved by the Ethics Committee of the Hirosaki University School of Medicine and written informed consent was obtained from all patients and subjects.

Thirty consecutive patients with NTG were included in this study. Patients with NTG had gonioscopically normal open angles, no history of IOP above 21 mmHg, characteristic nerve fiber layer visual field defects detected by the Humphrey Field Analyzer, program 30-2 (Humphrey Instruments, San Leandro, California, USA), and glaucomatous optic disc changes. The anthocyanin tablet containing 50 mg of anthocyanins extracted from black currant

mentioned as above was orally administrated to every patient once a day (7-9 am) for a 6-month period (from August 2004 to February 2005). Systemic blood pressures, IOPs, concentrations of plasma ET-1, blood flows at the neuroretinal rim of the optic nerve head and peripapillary retina, and visual field defects were measured before and just after the administration period.

Systemic pressures were recorded just before and after measurements of ocular blood flows, and mean blood pressures were calculated according to the formula:

Mean blood pressure = diastolic pressure + 1/3 (systolic pressure - diastolic pressure)

Intraocular pressures were measured with a Goldmann applanation tonometer before, during and just after the administration period, and ocular perfusion pressures (OPPs) were calculated according to the formula:

OPP = 2/3 [diastolic pressure + 1/3 (systolic pressure - diastolic pressure)] - IOP

The subjects were obliged to quietly remain in a sitting position for 30 minutes and their blood samples (5 ml) were taken at the start and the end point of study (9-11 am). Plasma was separated by centrifugation and frozen at -30°C. Prior to measuring the concentration of plasma ET-1, the frozen plasma samples were thawed, and then subjected to Parameter[®] (R&D Systems, Minneapolis, U.S.A.), human ET-1 immunoassay kit. This assay employs the quantitative enzyme immunoassay technique. An antibody specific for ET-1 has been pre-coated onto a microplate. Standards, samples, control and conjugate are pipetted into the wells and any ET-1 present is sandwiched by the immobilized antibody and the enzyme-linked antibody specific for ET-1. Following a wash to remove any unbound substances and/or antibody-enzyme reagents, substrate is added to the wells and color develops in proportion to the amount of ET-1 binding. The color development is stopped and the intensity of the color is

measured by microplate reader.

The blood flows at the neuroretinal rim of the optic nerve head and peripapillary retina were assessed with a commercially available scanning laser Doppler flowmeter (Heidelberg Retina Flowmeter [HRF], Heidelberg Engineering, Heidelberg, Germany) at the start and the end points of the administration period. This is a noninvasive instrument combining both laser Doppler flowmetry with a scanning laser technique. As with the blood sampling, the subjects were obliged to quietly remain in a sitting position for 30 minutes, and then blood flows were assessed (1-3 pm). Briefly, the fundus camera was adjusted until a focused, evenly illuminated, and centered view of the optic nerve head was obtained. The patients were asked to use the fellow eye for fixation and to refrain from movement and blinking during image acquisition. Using a 2.5-degree × 10-degree frame, a total of 20 images were then acquired in one session, focusing on the neuroretinal rim or the superficial retina. All images were reviewed by the same observer (I.O.), and, before data analysis, the best 4 images in terms of focusing, brightness, and absence of movements, were chosen for each session. Full-field perfusion analysis was then performed on each of the 4 chosen images, and mean values of blood flow for the temporal neuroretinal rim of the optic nerve head and the temporal peripapillary retina were obtained in arbitrary units (au). When selecting measuring points, peripapillary chorioretinal atrophy areas were excluded. Fundus photos were used to try to measure exactly the same points as had previously been measured.

Visual field testing was performed with the Humphrey Field Analyzer, program 30-2. All patients were experienced in visual field test, having performed at least 3 in total including 1 test within the last 3 months before the beginning of study and 1 test at the end of study. All visual field tests had fixation losses of less

Table 1. Patient Characteristics

Age (mean \pm S.D.)	66.7 \pm 6.9 yrs (51 ~ 80 yrs)
Sex (M/F)	9/21

Table 2. Effects of anthocyanins administration on systemic blood pressure (mmHg)

	Pre administration		Post administration	
	pre measure BP	post measure BP	pre measure BP	post measure BP
Mean BP	98.5 \pm 12.1	98.3 \pm 11.6	95.8 \pm 10.4	96.3 \pm 14.8

BP; blood pressure
Data are presented as mean \pm S.D.

Table 3. Effects of anthocyanins administration on intraocular pressures and ocular perfusion pressures (mmHg)

	Pre administration	Post administration
IOP (right eye)	13.9 \pm 1.8	13.5 \pm 1.6
IOP (left eye)	13.6 \pm 2.1	13.4 \pm 1.9
OPP (right eye)	52.1 \pm 7.9	50.7 \pm 7.1
OPP (left eye)	52.4 \pm 8.2	50.8 \pm 7.2

IOP; intraocular pressure, OPP; ocular perfusion pressure
Data are presented as mean \pm S.D.

than 25% and false-positive and false-negative errors were less than 25%.

To minimize measurement errors, all measurements except visual field tests and blood flow assessments were taken between 9 and 11 am. In addition, patients were allowed to continue with their prescribed systemic medications as well as their topical anti-glaucoma medications, which may have influenced the ocular blood flow during this prospective study period.

The resultant data were analyzed by paired t-test. Statistical significance was set at $P < 0.05$.

Results

Table 1 summarizes the characteristics of the patients with NTG. Nine were male and 21 were female. Their mean age was 66.7 \pm 6.9 (mean \pm standard deviation [S.D.]) years old, ranging

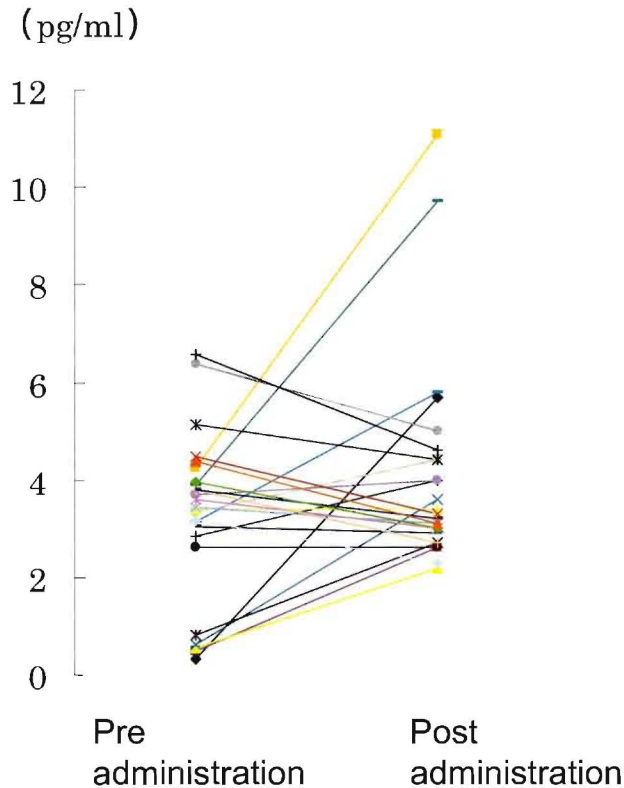
from 51 to 80 years old. Mean blood pressures were not significantly changed before or just after the administration period as well as just before or after measurements of ocular blood flows (Table 2). Intraocular pressure of each patient was stable during the administration period, and IOPs and OPPs were not significantly changed before or just after the administration period (Table 3). The concentrations of the plasma ET-1 were significantly increased from 3.27 \pm 1.67 (mean \pm S.D.) pg/ml to 4.10 \pm 2.14 (mean \pm S.D.) pg/ml before and just after the administration period, respectively ($p < 0.05$) (Table 4 & Figure 1). Two of 30 subjects showed high concentrations of ET-1, 6.56 pg/ml and 6.36 pg/ml, and after the administration period they showed almost normal levels of ET-1, 4.6 pg/ml and 5.0 pg/ml, respectively. Table 5 summarizes

Table 4. Effects of anthocyanins administration on the concentration of plasma ET-1 (pg/ml)

	Pre administration	Post administration
ET-1	3.27 ± 1.67	4.10 ± 2.14*

paired t-test *p < 0.05

Data are presented as mean ± S.D.

**Figure 1** The changes in plasma ET-1 concentrations in patients with NTG by anthocyanins administration.

Each color line represents the change in plasma ET-1 concentration before and just after oral administration of anthocyanins in each patient with NTG.

ET-1: endothelin-1; NTG: normal tension glaucoma

the blood flows at the neuroretinal rim of the optic nerve head and peripapillary retina (all data was presented as mean ± S.D.). At the end of the administration period, the blood flows of the superior and inferior temporal neuroretinal rim of the optic nerve head, and the superior and inferior temporal peripapillary retina in the right eye were significantly increased from 507.7 ± 174.3 , 393.6 ± 138.0 , 457.6 ± 140.6 , 377.0 ± 80.5

to 638.6 ± 191.2 ($p < 0.05$), 582.2 ± 177.8 ($p < 0.01$), 595.1 ± 171.5 ($p < 0.01$), 519.1 ± 130.0 ($p < 0.0005$), respectively. Also in the left eye, the blood flows of the superior and inferior temporal neuroretinal rim of the optic nerve head, and the superior and inferior temporal peripapillary retina were significantly increased from 442.4 ± 214.3 , 466.5 ± 216.3 , 375.0 ± 75.9 , 444.9 ± 100.9 to 662.4 ± 185.3 ($p < 0.0005$), 653.7 ± 260.9

Table 5. Scanning laser Doppler flowmetry measurements of the neuroretinal rim of optic nerve head and peripapillary retina (a.u.)

Right eye	Pre administration	Post administration
Sup. temp. rim	507.7* ± 174.3	638.6* ± 191.2
Inf. temp. rim	393.6** ± 138.0	582.2** ± 177.8
Sup. temp. retina	457.6** ± 140.6	595.1** ± 171.5
Inf. temp. retina	377.0**** ± 80.5	519.1**** ± 130.0
Left eye		
Sup. temp. rim	442.4**** ± 214.3	662.4**** ± 185.3
Inf. temp. rim	466.5**** ± 216.3	653.7**** ± 260.9
Sup. temp. retina	375.0*** ± 75.9	442.2*** ± 80.1
Inf. temp. retina	444.9* ± 100.9	546.9* ± 185.8

paired t-test *p < 0.05. **p < 0.01. *** p < 0.005, ****p < 0.0005

Data are presented as mean ± S.D.

Table 6. Effects of anthocyanins administration on visual field defects (dB)

	Pre administration	Post administration
MD (right eye)	-3.28 ± 4.65	-3.23 ± 4.49
MD (left eye)	-4.51 ± 4.34	-4.32 ± 4.29

MD; mean deviation of visual field
Data are presented as mean ± S.D.

(p < 0.0005), 442.2 ± 80.1 (p < 0.005), 546.9 ± 185.8 (p < 0.05), respectively. Table 6 shows that mean deviation value was not significantly changed before and after the administration period.

Discussion

Several investigators have suggested that disturbance of ocular blood flow may contribute to glaucomatous optic neuropathy in patients with NTG. So far, according to the literature, patients with NTG have had ischemia¹⁴⁾, vascular dysregulation^{15, 16)}, arteriosclerosis¹⁷⁾, high blood viscosity^{18, 19)}, platelet hyper aggregation⁸⁾, vasospasm²⁰⁾, aberrant autoimmunity^{21, 22)}, and abnormal effects of endogenous substances such as glutamate²³⁾, nitric oxide²⁴⁾ and ET-1²⁵⁾. This evidence appears to indicate that the ocular blood flows are reduced in patients with NTG.

In fact, clinical investigators²⁶⁻²⁸⁾ reported

that both neuroretinal rim blood flow and peripapillary retinal blood flow were significantly reduced in patients with NTG as compared with age-matched controls, and that neuroretinal rim blood flow was significantly correlated to deterioration of existing visual field defects. Hafez et al²⁹⁾ evaluated neuroretinal rim blood flow in patients with POAG and ocular hypertension (OH), and demonstrated that the former had significantly lower blood flow in the neuroretinal rim compared with the latter. They also reported that neuroretinal rim blood flow was significantly inversely correlated to increased cup-to-disc ratio (C/D), and that patients with OH showing larger C/D ratios demonstrated significantly lower rim blood flow compared with those showing smaller C/D ratios. They thereby suggested that rim perfusion might be reduced in high-risk patients with OH before the manifestation of visual field

defects.

Recently, several Ca^{2+} channel blockers as drugs for cerebrovascular diseases, including cerebral arteriosclerosis and central nervous system vasospasm, could improve visual field defects in certain patients with NTG³⁰⁻³²⁾. In 1999, Tomita et al³³⁾ showed that intravenously administered nilvadipine, a Ca^{2+} channel blocker, increased blood velocity and blood flow in the optic nerve head, choroid, and retina of rabbits, and also revealed that orally administered nilvadipine increased blood velocity in the optic nerve head of NTG patients. Taken together, it is suggested that some kind of Ca^{2+} channel blockers could increase blood flow in the optic nerve heads and improve visual field defects in certain patients with NTG.

Our study demonstrated that oral administration of anthocyanins tablets significantly increased the blood flows at both neuroretinal rim of the optic nerve head and peripapillary retina, with no significant changes in mean blood pressures, IOPs or OPPs. Moreover, no subjects showed any progression of their visual field defects. These results suggest that ocular blood flow in the patients with NTG had been chronically decreased, and was then improved by the daily oral administration of anthocyanins, which may contribute to the preservation of their visual fields.

It had been reported that the blood flows at the neuroretinal rim of the optic nerve heads and retina were decreasing with advancing age³⁴⁾ and also revealed that the blood flows at neuroretinal rim of glaucoma patients were significantly decreasing with advancing of glaucoma stages²⁸⁾. Accordingly, in a view of management of glaucoma patients during their lifetime, we have to consider the blood flows of optic nerve heads besides their IOPs.

We also demonstrated that the oral administration of anthocyanins tablets significantly increased, and thus normalized,

the concentrations of plasma ET-1. Endothelin-1, discovered by Yanagisawa³⁵⁾ in 1988, is a potent vasoconstrictive peptide produced by vascular endothelial cells. Some investigations in ophthalmology have shown that ET-1 receptors are present in human uveal tissues³⁶⁾, retina and optic nerve head³⁷⁾, suggesting that ET-1 may be implicated in ischemic vascular diseases such as diabetic retinopathy³⁸⁾, retinal vein occlusion and retinal artery occlusion. Regarding the role of ET-1 in NTG, reports on ET-1 levels are conflicting³⁹⁻⁴¹⁾. Although two reports^{39, 40)} showed statistically significant elevation of plasma ET-1 levels in patients with NTG, another report⁴¹⁾ showed only a nonsignificant trend. Previously, we reported⁹⁾ that the concentrations of plasma ET-1 were significantly decreased in patients with NTG compared with those in normal subjects.

In general, it is recognized that if the blood level of any particular substance is chronically low, its receptor will become hypersensitive, and then react excessively in relation to minimum changes in its blood level. Accordingly, we hypothesized that the patients with NTG showed chronically low concentrations of plasma ET-1, and that their receptors of ET-1 then become hypersensitive to ET-1. Under such conditions, excessive vasoconstriction could occur in cases of NTG and continue even with only a little change of plasma ET-1 levels, thereby contributing to ocular blood flow disturbances. Our hypothesis is confirmed by the findings⁴²⁾ that baseline plasma ET-1 levels were similar between patients with glaucoma and control subjects, but that patients with glaucoma had a significant increase in plasma ET-1 after cooling, which was not observed in control subjects.

We do not know why the oral administration of anthocyanins tablets significantly increased or normalized the concentrations of plasma ET-1 in patients with NTG. Regarding the relationship between anthocyanins and ET-1, Matsumoto

reported¹³⁾ that delphinidine-3-rutinoside (D3R), the major anthocyanin component isolated from blackcurrant, produced sustained and progressive relaxation during contraction caused by ET-1 in bovine ciliary smooth muscle, suggesting that D3R possibly activates ET_B receptor to release nitric oxide, thereby causing relaxation of the bovine ciliary smooth muscle. These observations suggest that anthocyanins orally administered may produce some alterations in the ET-1 receptors such as pharmacological reactivity and hypersensitivity, thereby resulting in an increase or normalization of the concentrations of plasma ET-1 in patients with NTG.

The present study demonstrated that oral administration of anthocyanins tablets significantly increased the blood flows at both the neuroretinal rim of the optic nerve head and peripapillary retina, with no significant changes in mean blood pressures, IOPs or OPPs. Furthermore, no subjects showed any progression in their visual field defects. We also demonstrated that the oral administration of anthocyanins tablets significantly increased, and thus normalized the concentrations of plasma ET-1, thereby possibly affecting the ET-1 receptors. These results suggest that oral administration of anthocyanins might be a safe and valuable option for neuroprotective treatment in patients with NTG. Although, the present study is not a double-blind, nor placebo-controlled design. To make sure the effects of anthocyanins in black currant on retinal blood flow circulation of patients with NTG, we are planning a double-blind and placebo-controlled study.

References

- 1) Shields MB. An overview of glaucoma. In: Textbook of glaucoma. 4th ed. Baltimore, Maryland: Williams & Wilkins; 1988,p.1-2.
- 2) The Advanced Glaucoma Intervention Study (AIGIS). The relationship between control of intraocular pressure and visual field deterioration. The AGIS Investigators. *Am J Ophthalmol* 2000;130:429-40.
- 3) Gordon MO, Beiser JA, Brandt JD, Heuer DK, Higginbotham EJ, Johnson CA, Keltner JL, Miller JP, Parrish RK 2nd, Wilson MR, Kass MA. The Ocular Hypertension Treatment Study: baseline factors that predict the onset of primary open-angle glaucoma. *Arch Ophthalmol* 2002;120:714-20.
- 4) Anderson DR, Drance SM, Schulzer M, Collaborative Normal-Tension Glaucoma Study Group. Natural history of normal-tension glaucoma. *Ophthalmology* 2001;108:247-53.
- 5) Iwase A, Suzuki Y, Araie M, Yamamoto T, Abe H, Shirato S, Kuwayama Y, Mishima HK, Shimizu H, Tomita G, Inoue Y, Kitazawa Y, The Tajimi Study Group, Japan Glaucoma Society. The prevalence of primary open-angle glaucoma in Japanese. The Tajimi Study. *Ophthalmology* 2004;111:1641-8.
- 6) Gloster J. Incidence of optic disc haemorrhages in chronic simple glaucoma and ocular hypertension. *Br J Ophthalmol* 1981;65:452-6.
- 7) Yamamoto T, Maeda M, Sawada A, Sugiyama K, Taniguchi T, Kitazawa Y, Oyama Z, Ichihashi N, Takagi H, Kitajima Y. Prevalence of normal-tension glaucoma and primary open-angle glaucoma in patients with collagen diseases. *Jpn J Ophthalmol* 1999;43:539-42.
- 8) Ohguro I, Yamamoto Y, Takeuchi K, Ohguro H, Matsumoto M, Matsushashi H, Nakazawa M. Relation between platelet aggregation rate and pathogenesis of glaucomatous optic neuropathy. *Journal of the Eye* 2005;22:669-72.
- 9) Ohguro I, Ohguro H, Ohkuro H, Nakazawa M. Study of contribution of low level of plasma endothelin-1 concentration to pathogenesis of glaucomatous optic neuropathy. *Hirosaki Med J* 2006;57:59-64.
- 10) Renaud S, de Logeril M. Wine, alcohol, platelets, and the French paradox for coronary heart disease. *LANCET* 1992;339:1523-6.
- 11) Scialdone D. L'Azione delle antocianine sul senso luminoso. *Ann Oftalmol Clin Ocul* 1988;92:43-51.
- 12) Nakaishi H, Matsumoto H, Tominaga S, Hirayama

- M. Effects of blackcurrant anthocyanoides intake on dark adaptation and VDT work-induced transient refractive alternation in healthy humans. *Altern Med Rev* 2000;5:553-62.
- 13) Matsumoto H, Kamm KE, Stull JT, Azuma H. Delphinidine-3-rutiniside relaxes the bovine ciliary smooth muscle through activation of ETB receptor and NO/cGMP pathway. *Exp Eye Res* 2005;80:313-22.
 - 14) Levin LA, Louhab A. Apoptosis of retinal ganglion cells in anterior ischemic optic neuropathy. *Arch Ophthalmol* 1996;114:488-91.
 - 15) Henry E, Newby DE, Webb DJ, O'Brien C. Peripheral endothelial dysfunction in normal pressure glaucoma. *Invest Ophthalmol Vis Sci* 1999;96:1710-4.
 - 16) Findl O, Strenn K, Wolzt M, Menapace R, Vass C, Eichler HG, Schmetterer L. Effects of changes in intraocular pressure on human ocular haemodynamics. *Curr Eye Res* 1997;16:1024-9.
 - 17) Ohguro I, Ishikawa F, Ouguro H, Shimokawa R, Nakazawa M. Arterial sclerosis grade in normal-tension glaucoma patients. *Journal of the Eye* 2004;21:397-400.
 - 18) Breddin HK, Lippold R, Bittner M, Kirchmaier CM, Krzywanek HJ, Michaelis J. Spontaneous platelet aggregation as a predictive risk factor for vascular occlusions in healthy volunteers? Results of the HAPARG study. Haemostatic parameters as risk factors in healthy volunteers. *Atherosclerosis* 1999;144:211-9.
 - 19) Bojic L, Skare LL. Circulating platelet aggregates in glaucoma. *Int Ophthalmol* 1998-1999;22:151-4.
 - 20) Gasser P. Ocular vasospasm: a risk factor in the pathogenesis of low-tension glaucoma. *Int Ophthalmol* 1989;13:281-90.
 - 21) Maruyama I, Ohguro H, Ikeda Y. Retinal ganglion cells recognized by serum autoantibody against γ -enolase found in glaucoma patients. *Invest Ophthalmol Vis Sci* 2000;41:1657-65.
 - 22) Wax MB, Tezel G, Saito I, Gupta RS, Harley JB, Li Z, Romano C. Anti-Ro/SS-A positivity and heat shock protein antibodies in patients with normal-pressure glaucoma. *Am J Ophthalmol* 1998;125:145-57.
 - 23) Dreyer EB, Zurakowski D, Schumer RA, Podos SM, Lipton SA. Elevated glutamate levels in the vitreous body of humans and monkeys with glaucoma. *Arch Ophthalmol* 1996;114:299-305.
 - 24) Neufeld AH, Hernandez R, Gonzalez M. Nitric oxide synthases in the human glaucomatous optic nerve head. *Arch Ophthalmol* 1997;115:497-503.
 - 25) Haefliger IO, Dettman ES, Liu R, Meyer P, Prunte C, Messerli J, Flammer J. Potential role of nitric oxide and endothelin in the pathogenesis of glaucoma. *Surv Ophthalmol* 1999;43 (Suppl 1): S51-8.
 - 26) Logan JF, Rankin SJ, Jackson AJ. Retinal blood flow measurements and neuroretinal rim damage in glaucoma. *Br J Ophthalmol* 2004;88:1049-54.
 - 27) Yaoeda K, Shirakashi M, Fukushima A, Funaki S, Funaki H, Abe H, Tanabe N. Relationship between optic nerve head microcirculation and visual field loss in glaucoma. *Acta Ophthalmol Scand* 2003;81:253-9.
 - 28) Sato EA, Ohtake Y, Shinoda K, Mashima Y, Kimura I. Decreased blood flow at neuroretinal rim of optic nerve head corresponds with visual field deficit in eyes with normal tension glaucoma. *Graefes Arch Clin Exp Ophthalmol* 2006;244:795-801.
 - 29) Hafez AS, Bizzarro RLG, Lesk MR. Evaluation of optic nerve head and peripapillary retinal blood flow in glaucoma patients, ocular hypertensives, and normal subjects. *Am J Ophthalmol* 2003;136:1022-31.
 - 30) Kitazawa Y, Shirai H, Go FJ. The effect of Ca^{2+} -antagonist on visual field in low-tension glaucoma. *Graefe's Arch Clin Exp Ophthalmol* 1989;227:408-12.
 - 31) Netland PA, Chaturvedi N, Dryer EB. Calcium channel blockers in the management of low-tension and open-angle glaucoma. *Am J Ophthalmol* 1993;115:608-13.
 - 32) Sawada A, Kitazawa Y, Yamamoto T, Okabe I, Ichien K. Prevention of visual field defect progression with brovincamine in eyes with normal-tension glaucoma. *Ophthalmology* 1996;103:

- 283-8.
- 33) Tomita K, Araie M, Tamaki Y, Nagahara M, Sugiyama T. Effects of nilvadipine, a calcium antagonist, on rabbit ocular circulation and optic nerve head circulation in NTG subjects. *Invest Ophthalmol Vis Sci* 1999;40:1144-51.
- 34) Embleton SJ, Hosking SL, Roff-Hilton EJ, Cunliffe IA. Effect of senescence on ocular blood flow in the retina, neuroretinal rim and lamina cribrosa, using scanning laser Doppler flowmetry. *Eye* 2002;16:156-62.
- 35) Yanagisawa M, Kurihara H, Kimura S, Tomobe Y, Kobayashi M, Mitsui Y, Yazaki Y, Goto K, Masaki T. A novel potent vasoconstrictor peptide produced by vascular endothelial cells. *Nature* 1988;332:411-5.
- 36) MacCumber MW, D'Anna SA. Endothelin receptor-binding subtypes in the human retina and choroid. *Arch Ophthalmol* 1994;112:1231-5.
- 37) Ripodas A, de Juan JA, Roldan-Pallares M, Bernal R, Moya J, Chao M, Lopez A, Fernandez-Cruz A, Fernandez-Durango R. Localisation of endothelin-1 mRNA expression and immunoreactivity in the retina and optic nerve from human and porcine eye. Evidence for endothelin-1 expression in astrocytes. *Brain Res* 2001;912:137-43.
- 38) Oku H, Kida T, Sugiyama T, Hamada J, Sato B, Ikeda T. Possible involvement of endothelin-1 and nitric oxide in the pathogenesis of proliferative diabetic retinopathy. *Retina* 2001;21:647-51.
- 39) Sugiyama T, Moriya S, Oku H, Azuma I. Association of endothelin-1 with normal tension glaucoma. Clinical and fundamental studies. *Surv Ophthalmol* 1995;39 (Suppl 1):S49-56.
- 40) Cellini M, Possati GL, Profazio V, Sbrocca M, Caramazza N, Caramazza R. Color Doppler imaging and plasma levels of endothelin-1 in low-tension glaucoma. *Acta Ophthalmol Scand* 1997;224 (Suppl):S11-3.
- 41) Kaiser HJ, Flammer J, Wenk M, Luscher T. Endothelin-1 plasma levels in normal-tension glaucoma. Abnormal response to postural changes. *Graefe's Arch Clin Exp Ophthalmol* 1995;233:484-8.
- 42) Nicolela MT, Ferrier SN, Morrison CA, Archibald ML, Levatte TL, Wallace K, Chauhan BC, LeBlanc RP. Effects of cold-induced vasospasm in glaucoma: the role of endothelin-1. *Invest Ophthalmol Vis Sci* 2003;44:2565-72.