

# Hippocampal MRI volumetry in cognitively discordant monozygotic twin pairs

T Järvenpää, M P Laakso, R Rossi, M Koskenvuo, J Kaprio, I Räihä, T Kurki, M Laine, G B Frisoni, J O Rinne

*J Neural Neurosurg Psychiatry* 2004;**75**:116–120

See end of article for authors' affiliations

Correspondence to:  
Dr Juha O Rinne, Turku  
PET Centre, PO Box 52,  
FIN-20521, Turku,  
Finland; juha.rinne@  
pet.tyks.fi

Received 12 February 2003  
In revised form  
26 May 2003  
Accepted 29 May 2003

**Objective:** To investigate whether hippocampal atrophy, a proxy for incipient Alzheimer's disease, can be detected in non-demented monozygotic co-twins of demented twins by using volumetric magnetic resonance imaging (MRI).

**Methods:** Seven pairs of monozygotic female twins discordant for cognitive function (mean (SD) age 75 (4) years), and 10 age and education matched healthy controls (seven women, three men; mean age 73 (3) years) were studied with volumetric MRI.

**Results:** The mean normalised right hippocampal volume was 31% lower ( $p=0.002$ ) in the demented twins, and 6% lower ( $p=0.45$ ) in the non-demented twins than in the controls. In the left hippocampus, the mean normalised volume was 36% lower ( $p<0.001$ ) in the demented twins, and 9% lower ( $p=0.13$ ) in the non-demented twins than in the controls.

**Conclusions:** Significant hippocampal atrophy was detected in the demented twins compared with the controls. This is in line with previous imaging and pathological studies, with hippocampus showing the early changes in Alzheimer's disease. In the non-demented twins, only a minor, non-significant reduction was observed in the hippocampal volumes compared with the controls. This could reflect gene-environment interactions that have protected the non-demented twins longer than their demented co-twins and contributed to the relative preservation of their hippocampal volumes, or it could be a sign of preclinical Alzheimer's disease in the non-demented twins.

It has been suggested that the pathological process in Alzheimer's disease has continued for years or perhaps even decades in the brain before any clinical symptoms become manifest. The medial temporal lobe, especially the entorhinal cortex and hippocampus—which are important for normal memory function—are the regions with the earliest pathological changes in Alzheimer's disease.<sup>1,2</sup> Magnetic resonance imaging (MRI) studies in healthy people at genetic risk for Alzheimer's disease, in people with mild cognitive impairment,<sup>3</sup> or in those with incipient Alzheimer's disease have shown brain changes occurring first in the medial temporal lobe and some also in the lateral temporal cortex in the form of atrophy.<sup>4–8</sup> MRI volumetry of these structures has been shown to have some predictive value in terms of conversion from mild cognitive impairment to Alzheimer's disease.<sup>9–12</sup>

Genetic factors influence the shape and the size of brain structures to a large extent. In particular, previous twin studies have shown that gross brain volume,<sup>13–16</sup> the size of the corpus callosum,<sup>17,18</sup> and the size of the ventricles<sup>18</sup> are highly genetically determined. More variability between twins has been found in the gyral and sulcal patterns.<sup>13,16,19</sup> In one large twin study, only 40% of the variance of hippocampal volume was found to be attributable to genetic influences, while as much as 60% of the variance of the temporal horn, and 80% of the variance of the corpus callosum and intracranial volume were considered to be attributable to genetic influences.<sup>20</sup> The authors suggested that the environment by itself, or gene-environmental interactions, exert greater and longer control in modifying hippocampal size than that of other more genetically determined brain regions.

The concordance rates of Alzheimer's disease are higher in monozygotic than in dizygotic twins,<sup>21–23</sup> although the

unaffected co-twins will not invariably develop Alzheimer's disease. The onset of Alzheimer's disease between those monozygotic co-twins who eventually become concordant has been shown to vary by several years.<sup>22,24,25</sup> Thus in a given discordant monozygotic twin pair, the asymptomatic co-twin could be in the early phase of the disease. Only a few MRI studies have previously been done on monozygotic twins discordant for Alzheimer's disease. These studies have been case reports of a single twin pair,<sup>26–28</sup> with contradictory results with respect to possible hippocampal atrophy in the unaffected co-twin. In this study, our aim was to investigate whether hippocampal atrophy, a proxy for incipient Alzheimer's disease, could be detected in seven non-demented monozygotic co-twins of demented twins, using volumetric MRI.

## METHODS

### Participants Twins

Seven pairs of monozygotic twins were recruited through the Finnish twin cohort, which was compiled from the Central Population Registry of Finland using selection procedures described in detail elsewhere.<sup>29</sup> From this cohort, all 413 monozygotic twin pairs alive in 1999 and aged 65 years and over at that time were asked to participate in a telephone interview, the TELE,<sup>30</sup> which assesses cognitive status. The seven twin pairs of this study were selected so that they were discordant for cognitive function. The discordance was initially based on the TELE score achieved, and was subsequently confirmed by a detailed neuropsychological examination, as described below. All the twin pairs examined were female. In one pair, both co-twins were left handed and in another pair, one co-twin was ambidextrous and the other right handed. In the remaining five pairs, both co-twins were

right handed. The mean (SD) age of the twins was 75 (4) years. The mean mini-mental state examination (MMSE)<sup>31</sup> score of the demented twins was 21.1 (6.0) and that of their non-demented co-twins, 26.0 (2.8). All twins were screened for hypothyroidism and vitamin B-12 deficiency to exclude these conditions as possible causes of dementia.<sup>32</sup> No clinically significant abnormalities that could have affected cognitive function in the twins were found. None of the twins had experienced any serious head trauma, had a history of epilepsy, or had experienced single seizures or episodes of status epilepticus. This was confirmed from the medical records. In the interview with the twins and informants, no history of prolonged febrile convulsions in childhood became apparent. Furthermore, no major depression was detected in any twins, based on the judgement of the clinician or neuropsychologist; possible minor depressive symptoms were not likely to have confounded the neuropsychological test results.

### Confirmation of zygosity and ApoE status

The zygosity was confirmed by DNA extracted from venous blood samples. Ten highly polymorphic genetic markers used by the paternity testing laboratory of the National Public Health Institute were determined, and monozygosity was inferred if no intrapair differences in the markers were observed. Three twin pairs had an ApoE  $\epsilon 4$  allele, with one pair being homozygous for this allele. The remaining four pairs were homozygous for the  $\epsilon 3$  allele.

### Neuropsychological testing

In addition to the initial TELE interview, the twins' cognitive discordance was confirmed with a comprehensive neuropsychological test battery including the Wechsler memory scale-revised (logical memory immediate and delayed, visual reproduction immediate and delayed), Wechsler memory scale (digit span), Wechsler adult intelligence scale-revised (similarities, block design), verbal fluency (animals and letter s), trail making A, and Boston naming test. These tests assess memory, attention, language, psychomotor functions, and visuospatial and visuoconstructive abilities. The results of the above mentioned tests in 113 neurologically healthy elderly Finnish individuals of comparable age were used as reference values.<sup>33</sup> If the individual had a subjective memory complaint, scored at least 1.5 SD under the mean reference value in any memory domain, had normal general cognitive function, and had preservation of the activities of daily living, the criteria for mild cognitive impairment were fulfilled.<sup>3</sup> If the individual showed widespread impairment (scored at least 1.5 SD under the mean reference value in any other cognitive domain in addition to the memory deficit), and had a progressive decline in memory and other cognitive functions over time, the NINCDS-ADRDA criteria for probable Alzheimer's disease were fulfilled.<sup>34</sup> All of the seven twin pairs were cognitively discordant. According to the above mentioned criteria, in four pairs one co-twin was cognitively intact and the other was demented. In two pairs one co-twin was intact, and the other had mild cognitive impairment. In the remaining pair, one co-twin had mild cognitive impairment, and the other was demented. In addition to the above mentioned tests, the twins underwent the Consortium to Establish a Registry for Alzheimer's Disease (CERAD)<sup>35</sup> tests.

### Controls

The control group consisted of 10 healthy volunteers (seven women and three men) with no previous history of neurological or psychiatric diseases. These controls were age and education matched. The duration of education was categorised into four classes ( $\leq 6$  years, 7–9 years, 10–12 years, and  $>12$  years). There was no difference in the

distribution of education between the demented twins and the controls ( $p = 1.00$ , Fisher's exact test), between the non-demented twins and controls ( $p = 1.00$ , Fisher's exact test), or between the demented and non-demented twins ( $p = 0.32$ , McNemar's test). The controls underwent the same neuropsychological examination as the twins. The neuropsychological test scores of the control group were also compared with the reference values of the 113 neurologically healthy elderly Finnish individuals, and after this thorough examination the controls were confirmed as cognitively intact. All controls were right handed. The mean age of the control group was 73 (3) years, and their mean MMSE score was 28.5 (1.1).

Written informed consent was obtained from all participants before the MRI and neuropsychological investigation. The study protocol was approved by the joint ethics committee of the University of Turku and the Turku University Central Hospital.

### MRI

#### MRI scanning

The participants were scanned with a 1.5 Tesla MRI device (three controls with a Siemens Magnetom, Erlangen, Germany; seven controls and all twins with GE Signa, General Electric Medical Systems, Milwaukee, Wisconsin, USA) at the Turku University Central Hospital. For the Siemens' scanner, we used a three dimensional, magnetisation prepared, rapid acquisition gradient echo sequence (time of repetition (TR) 10 ms, time of echo (TE) 4 ms, flip angle  $10^\circ$ , matrix  $256 \times 256$ , one acquisition), which resulted in 128 1.5 mm thick sagittal images with no interslice gap. For Signa, we used three dimensional, fast spoiled, gradient echo sequence (TR 11.3 ms, TE 4.2 ms, flip angle  $20^\circ$ , matrix  $256 \times 256$ , one acquisition), which resulted in 124 1.2 mm thick axial images with no interslice gap.

To measure the hippocampal volumes, the scans were saved on an optical disc and analysed at the Kuopio University Hospital (Kuopio, Finland). First, the scans were reconstructed into 2.0 mm thick contiguous coronal slices oriented perpendicularly to the intercommissural line. The hippocampi were manually traced slice by slice by one person, blinded to the subjects' clinical data, using custom made software for a standard Siemens' work console. The rostral end of the hippocampus, when it first appears below the amygdala, was the anatomical starting point. Tracing of the hippocampus ended posteriorly in the section where the crura of the fornices depart from the lateral wall of the lateral ventricles.

The intraclass correlation coefficient for intrarater reliability was 0.95. The intracranial area on a coronal section at the level of the anterior commissure was measured and used for normalisation of the volumetric data. For data presentation purposes, the volumes reported herein are normalised to the intracranial area according to the formula:  $[\text{volume}/\text{intracranial area}] \times 1000$ .<sup>36</sup>

### Statistical analyses

The results are shown as mean (SD). The equality in the distribution of education between the demented twins and controls, and between the non-demented twins and controls, was tested with Fisher's exact test. McNemar's test was used in the comparison of education between the demented and non-demented twins, as the twins were considered to be correlated (paired) samples. Comparisons between the hippocampal volumes of the demented and non-demented co-twins were done with paired  $t$  tests. Differences in the hippocampal volumes between the demented twins and controls, and between the non-demented twins and controls, were evaluated with two sample  $t$  tests. The associations between the neuropsychological test scores and hippocampal

volumes were analysed with Pearson's correlation coefficients. In all tests, differences were considered significant at a probability (*p*) value of <0.05. Statistical analyses were done with the SAS System for Windows, release 8.02 (SAS Institute, Cary, North Carolina, USA).

## RESULTS

The mean normalised right and left hippocampal volumes in the demented twins, their non-demented co-twins, and the controls are shown in table 1. In the right hippocampus, the mean hippocampal volume was 31% lower in the demented twins ( $t = -3.66$ ,  $df = 15$ ,  $p = 0.002$ ), and 6% lower in the non-demented twins ( $t = -0.77$ ,  $df = 15$ ,  $p = 0.45$ ) than in the controls. When the demented twins were compared with their non-demented co-twins, a significant 27% reduction ( $t = -5.10$ ,  $df = 6$ ,  $p = 0.002$ ) was found in the mean right hippocampal volume. In the left hippocampus, the mean hippocampal volume was 36% lower in the demented twins ( $t = -5.79$ ,  $df = 15$ ,  $p < 0.001$ ), and 9% lower in the non-demented twins ( $t = -1.59$ ,  $df = 15$ ,  $p = 0.13$ ) than in the controls. Here, a significant 29% reduction ( $t = -6.17$ ,  $df = 6$ ,  $p < 0.001$ ) was also found in the demented twins compared with their non-demented co-twins. Figure 1 shows the scatterplots of normalised right and left hippocampal volumes in the three groups. Correlation analysis revealed no significant associations between the hippocampal volumes and MMSE scores, or delayed recall and savings scores of the CERAD tests in the group of the demented twins (Pearson  $r = 0.24-0.66$ ,  $p = 0.10-0.60$ ,  $n = 7$ ).

## DISCUSSION

This is the first volumetric MRI study, to our knowledge, that has been carried out in a group of monozygotic twins discordant for cognitive function. We found the mean normalised right and left hippocampal volumes of the demented twins to be significantly reduced, in a range of 27% to 36% compared with their non-demented co-twins and controls. The non-demented twins showed a 6–9% hippocampal volume loss compared with the controls, which did not reach statistical significance.

Previously, three brain MRI studies have been done on monozygotic twins discordant for Alzheimer's disease, and each study has been a case report based on a single pair. Thus no statistical conclusions could have been drawn from those studies. In a report by Luxenberg *et al* in one male monozygotic twin pair discordant for Alzheimer's disease, MRI of the affected twin showed marked loss of cortical grey matter, enlargement of sulcal spaces, and ventricular dilatation, while MRI in the unaffected co-twin was normal.<sup>27</sup> In neuropsychological tests the affected twin had marked deficits in all areas of cognition, while the unaffected co-twin had milder impairment. Small *et al* studied one female monozygotic twin pair appearing discordant for Alzheimer's disease. MRI showed atrophy in both twins, with larger amounts of sulcal widening, ventricular enlargement, and loss of normal contour of the lateral ventricles in the affected

twin. In neuropsychological tests the affected twin showed extensive deterioration, while her unaffected co-twin had milder cognitive decline.<sup>28</sup> In a study by Geroldi and associates with one female monozygotic twin pair discordant for Alzheimer's disease, the MRI showed medial temporal lobe atrophy only in the affected twin. Cognitive functions were normal in the unaffected co-twin.<sup>26</sup> Thus in these previous twin studies, pathological MRI findings were either accompanied by cognitive impairment, or else no pathological MRI findings were found despite cognitive impairment in the unaffected co-twins. However, in only one study<sup>26</sup> was medial temporal lobe atrophy measured quantitatively, while the other two studies concentrated on visual assessment of cortical atrophy without any focus on the medial temporal lobe. Thus the earliest changes of medial temporal lobe atrophy, before the first signs of cognitive deterioration, might have been missed.

In our study, significant hippocampal atrophy was detected in the demented twins compared with their non-demented co-twins and controls. This is in accordance with previous studies in which MRI volumetry has been shown to be a sensitive means of detecting hippocampal atrophy early in the disease process of Alzheimer's disease, and to differentiate patients with Alzheimer's disease from healthy controls.<sup>36-37</sup> In the non-demented twins in our study only a minor 6–9% reduction in hippocampal volumes was observed compared with the controls. Earlier studies have shown that volumetric MRI measurements of the hippocampus have been 11–15% lower in subjects with mild cognitive impairment than in healthy controls.<sup>38-41</sup> However, all but one of the non-demented twins in our study were diagnosed as being cognitively intact. Thus this is probably the reason why we did not find any significant volume losses in our study, in contrast with those involving subjects with mild cognitive impairment.<sup>38-41</sup>

We did not find any significant differences in mean hippocampal volumes between the non-demented twins and the controls, but issues that should be considered are the relatively small number of twin pairs and the large within-group variation in hippocampal volumes. It is not likely that the two scanners used in this study contributed to the within-group variation, given that all the twin pairs were scanned with the same scanner. In one previous study,<sup>6</sup> co-registered serial MRI showed an accelerated atrophy rate, in comparison with controls, in the medial temporal lobe of presymptomatic subjects who carried a known autosomal dominant mutation leading to early onset Alzheimer's disease. Thus a longitudinal follow up would be needed to show whether the non-demented twins in our study would have a greater atrophy rate than the controls, or whether those who might convert to Alzheimer's disease would have even greater hippocampal atrophy. In our study, the correlations between the cognitive test scores and hippocampal volumes in the demented twins were positive but did not reach statistical significance, unlike in some previous studies on patients with Alzheimer's disease,<sup>42-44</sup> which probably

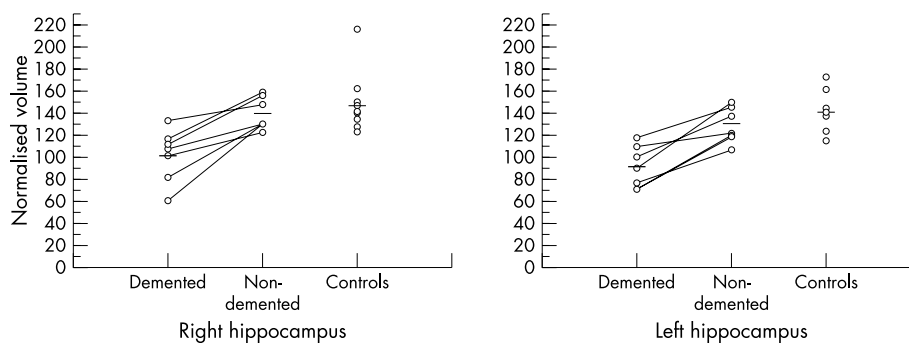
**Table 1** Normalised right and left hippocampal volumes in the demented twins, their non-demented co-twins, and the controls

Hippocampus	Demented twins (n = 7)		Non-demented co-twins (n = 7)		Controls (n = 10)		p Values		
	Volume	%	Volume	%	Volume		Demented v non-demented <sup>1</sup>	Demented v controls <sup>2</sup>	Non-demented v controls <sup>2</sup>
Right	102.4 (23.8)	69	139.4 (14.6)	94	147.8 (26.1)	0.002	0.002	0.45	
Left	90.3 (19.0)	64	127.8 (15.9)	91	140.6 (16.6)	<0.001	<0.001	0.13	

Values are mean (SD). Percentages indicate the proportion of the control mean value.

<sup>1</sup>Statistical method: paired *t* test.

<sup>2</sup>Statistical method: two sample *t* test.



**Figure 1** The scatterplots of normalised volumes ([hippocampal volume/intracranial area]×1000) in the right and left hippocampus in the demented twins, their non-demented co-twins, and the controls. Each twin pair is connected with a line. The horizontal line shows the mean normalised hippocampal volume in each group.

reflects the relatively small sample size in our study. However, hippocampal volume loss is only one marker of cognitive decline and Alzheimer's disease, as memory acquisition may also occur outside hippocampal structures.<sup>45</sup>

In a sizeable twin study,<sup>20</sup> the volume of the hippocampus was found to be less heritable than the other brain structures examined. The authors suggested that environment by itself, or gene–environmental interactions, exert greater and longer control in modifying hippocampal size than that of other, more genetically determined brain regions. Given that the onset of Alzheimer's disease between those monozygotic co-twins who eventually become demented has varied by several years,<sup>22–24–25</sup> it is possible that some of the non-demented twins of our study are in the presymptomatic phase of the disease. However, gene–environment interactions might have protected them longer than their demented co-twins and contributed to the relative preservation of their hippocampal volumes.

## ACKNOWLEDGEMENTS

We thank the nurses of the Department of Public Health, University of Turku, for carrying out the telephone interviews. We are grateful to Anna Häggqvist, Åbo Akademi University, for undertaking the neuropsychological examinations, and to Tero Vahlberg, Department of Biostatistics, University of Turku, for statistical assistance. We thank the personnel of the National Public Health Institute for the zygosity and ApoE genotype determinations. We wish to thank the personnel of the Turku PET Centre and the Department of Radiology for their skilful assistance. Finally, we are thankful to the twin pairs who participated in the examinations. This work was supported by grants from the Päivikki and Sakari Sohlberg Foundation, the Finnish Neurological Foundation, the Finnish Cultural Foundation, the Yrjö Jahnsson Foundation, as well as clinical research grants from the Health Centre of Turku and the Turku University Central Hospital, and EVO grants 5510, 5772722 from the Kuopio University Hospital.

## Authors' affiliations

**T Järvenpää**, Turku PET Centre and Department of Neurology, University of Turku, Turku, Finland

**M Koskenvuo**, Department of Public Health, University of Turku

**T Kurki**, Department of Radiology, University of Turku

**I Riihjä**, Department of Geriatrics, University of Turku, and Turku City Hospital

**J O Rinne**, Turku PET Centre, University of Turku

**M Laine**, Åbo Akademi University, Turku

**M P Laakso**, Department of Neurology and Department of Clinical Radiology, Kuopio University Hospital, Kuopio, Finland

**J Kaprio**, Department of Public Health, University of Helsinki, and

National Public Health Institute, Helsinki, Finland

**R Rossi, G B Frisoni**, Laboratory of Epidemiology and Neuroimaging, IRCCS San Giovanni di Dio – FBF, Brescia, Italy

Competing interests: none declared

## REFERENCES

- 1 Braak H, Braak E. Neuropathological staging of Alzheimer-related changes. *Acta Neuropathol (Berl)* 1991;**82**:239–59.
- 2 Braak H, Braak E, Bohl J. Staging of Alzheimer-related cortical destruction. *Eur Neurol* 1993;**33**:403–8.
- 3 Petersen RC, Stevens JC, Ganguli M, et al. Practice parameter: early detection of dementia: mild cognitive impairment (an evidence-based review). Report of the Quality Standards Subcommittee of the American Academy of Neurology. *Neurology* 2001;**56**:1133–42.
- 4 Dickerson BC, Goncharova I, Sullivan MP, et al. MRI-derived entorhinal and hippocampal atrophy in incipient and very mild Alzheimer's disease. *Neurobiol Aging* 2001;**22**:747–54.
- 5 Krasuski JS, Alexander GE, Horwitz B, et al. Volumes of medial temporal lobe structures in patients with Alzheimer's disease and mild cognitive impairment (and in healthy controls). *Biol Psychiatry* 1998;**43**:60–8.
- 6 Fox NC, Crum WR, Scallan RL, et al. Imaging of onset and progression of Alzheimer's disease with voxel-compression mapping of serial magnetic resonance images. *Lancet* 2001;**358**:201–5.
- 7 Krasuski JS, Alexander GE, Horwitz B, et al. Relation of medial temporal lobe volumes to age and memory function in nondemented adults with Down's syndrome: implications for the prodromal phase of Alzheimer's disease. *Am J Psychiatry* 2002;**159**:74–81.
- 8 Cohen RM, Small C, Lalonde F, et al. Effect of apolipoprotein E genotype on hippocampal volume loss in aging healthy women. *Neurology* 2001;**57**:2223–8.
- 9 Jack CR, Petersen RC, Xu Y, et al. Rates of hippocampal atrophy correlate with change in clinical status in aging and AD. *Neurology* 2000;**55**:484–9.
- 10 Jack CR, Petersen RC, Xu YC, et al. Prediction of AD with MRI-based hippocampal volume in mild cognitive impairment. *Neurology* 1999;**52**:1397–403.
- 11 Killiany RJ, Gomez-Isla T, Moss M, et al. Use of structural magnetic resonance imaging to predict who will get Alzheimer's disease. *Ann Neurol* 2000;**47**:430–9.
- 12 de Leon MJ, Convit A, DeSanti S, et al. Contribution of structural neuroimaging to the early diagnosis of Alzheimer's disease. *Int Psychogeriatr* 1997;**9**(suppl 1):183–90.
- 13 Bartley AJ, Jones DW, Weinberger DR. Genetic variability of human brain size and cortical gyral patterns. *Brain* 1997;**120**:257–69.
- 14 Tramo MJ, Loftus WC, Stukel TA, et al. Brain size, head size, and intelligence quotient in monozygotic twins. *Neurology* 1998;**50**:1246–52.
- 15 Carmelli D, DeCarli C, Swan GE, et al. Evidence for genetic variance in white matter hyperintensity volume in normal elderly male twins. *Stroke* 1998;**29**:1177–81.
- 16 White T, Andreasen NC, Nopoulos P. Brain volumes and surface morphology in monozygotic twins. *Cereb Cortex* 2002;**12**:486–93.
- 17 Oppenheim JS, Skerry JE, Tramo MJ, et al. Magnetic resonance imaging morphology of the corpus callosum in monozygotic twins. *Ann Neurol* 1989;**26**:100–4.
- 18 Pfefferbaum A, Sullivan EV, Swan GE, et al. Brain structure in men remains highly heritable in the seventh and eighth decades of life. *Neurobiol Aging* 2000;**21**:63–74.
- 19 Lohmann G, von Cramon DY, Steinmetz H. Sulcal variability of twins. *Cereb Cortex* 1999;**9**:754–63.
- 20 Sullivan EV, Pfefferbaum A, Swan GE, et al. Heritability of hippocampal size in elderly twin men: equivalent influence from genes and environment. *Hippocampus* 2001;**11**:754–62.
- 21 Breiner JC, Welsh KA, Gau BA, et al. Alzheimer's disease in the National Academy of Sciences-National Research Council Registry of Aging Twin Veterans. III. Detection of cases, longitudinal results, and observations on twin concordance. *Arch Neurol* 1995;**52**:763–71.
- 22 Riihjä I, Kaprio J, Koskenvuo M, et al. Alzheimer's disease in Finnish twins. *Lancet* 1996;**347**:573–8.
- 23 Nee LE, Eldridge R, Sunderland T, et al. Dementia of the Alzheimer type: clinical and family study of 22 twin pairs. *Neurology* 1987;**37**:359–63.
- 24 Cook RH, Schneck SA, Clark DB. Twins with Alzheimer's disease. *Arch Neurol* 1981;**38**:300–1.

- 25 **Zubenko GS**, Ferrell RE. Monozygotic twins concordant for probable Alzheimer disease and increased platelet membrane fluidity. *Am J Med Genet* 1988;**29**:431–6.
- 26 **Geroldi C**, Frisoni GB, Beltramello A, et al. Magnetic resonance and single-photon emission tomography findings in a pair of twins discordant for Alzheimer's disease. *J Neuroimaging* 1996;**6**:76–80.
- 27 **Luxenberg JS**, May C, Haxby JV, et al. Cerebral metabolism, anatomy, and cognition in monozygotic twins discordant for dementia of the Alzheimer type. *J Neurol Neurosurg Psychiatry* 1987;**50**:333–40.
- 28 **Small GW**, Leuchter AF, Mandelkern MA, et al. Clinical, neuroimaging, and environmental risk differences in monozygotic female twins appearing discordant for dementia of the Alzheimer type. *Arch Neurol* 1993;**50**:209–19.
- 29 **Kaprio J**, Sarna S, Koskenvuo M, et al. The Finnish Twin Registry: formation and compilation, questionnaire study, zygosity determination procedures, and research program. *Prog Clin Biol Res* 1978;**24**:179–84.
- 30 **Gatz M**, Reynolds C, Nikolic J, et al. An empirical test of telephone screening to identify potential dementia cases. *Int Psychogeriatr* 1995;**7**:429–38.
- 31 **Folstein MF**, Folstein SE, McHugh PR. "Mini-mental state". A practical method for grading the cognitive state of patients for the clinician. *J Psychiatr Res* 1975;**12**:189–98.
- 32 **Knopman DS**, DeKosky ST, Cummings JL, et al. Practice parameter: diagnosis of dementia (an evidence-based review). Report of the quality standards subcommittee of the American Academy of Neurology. *Neurology* 2001;**56**:1143–53.
- 33 **Ylikoski R**, Ylikoski A, Erkinjuntti T, et al. Differences in neuropsychological functioning associated with age, education, neurological status, and magnetic resonance imaging findings in neurologically healthy elderly individuals. *Appl Neuropsychol* 1998;**5**:1–14.
- 34 **McKhann G**, Drachman D, Folstein M, et al. Clinical diagnosis of Alzheimer's disease: report of the NINCDS-ADRDA work group under the auspices of Department of Health and Human Services task force on Alzheimer's Disease. *Neurology* 1984;**34**:939–44.
- 35 **Welsh KA**, Butters N, Mohs RC, et al. The Consortium to Establish a Registry for Alzheimer's Disease (CERAD). Part V. A normative study of the neuropsychological battery. *Neurology* 1994;**44**:609–14.
- 36 **Laakso MP**, Soininen H, Partanen K, et al. MRI of the hippocampus in Alzheimer's disease: sensitivity, specificity, and analysis of the incorrectly classified subjects. *Neurobiol Aging* 1998;**19**:23–31.
- 37 **Jack CR**, Petersen RC, Xu YC, et al. Medial temporal atrophy on MRI in normal aging and very mild Alzheimer's disease. *Neurology* 1997;**49**:786–94.
- 38 **DeSanti S**, de Leon MJ, Rusinek H, et al. Hippocampal formation glucose metabolism and volume losses in MCI and AD. *Neurobiol Aging* 2001;**22**:529–39.
- 39 **Xu Y**, Jack CR, O'Brien PC, et al. Usefulness of MRI measures of entorhinal cortex versus hippocampus in AD. *Neurology* 2000;**54**:1760–7.
- 40 **Convit A**, de Leon MJ, Tarshish C, et al. Specific hippocampal volume reductions in individuals at risk for Alzheimer's disease. *Neurobiol Aging* 1997;**18**:131–8.
- 41 **Du AT**, Schuff N, Amend D, et al. Magnetic resonance imaging of the entorhinal cortex and hippocampus in mild cognitive impairment and Alzheimer's disease. *J Neurol Neurosurg Psychiatry* 2001;**71**:441–7.
- 42 **Deweert B**, Lehericy S, Pillon B, et al. Memory disorders in probable Alzheimer's disease – the role of hippocampal atrophy as shown with MRI. *J Neurol Neurosurg Psychiatry* 1995;**58**:590–7.
- 43 **Petersen RC**, Jack CR, Xu YC, et al. Memory and MRI-based hippocampal volumes in aging and AD. *Neurology* 2000;**54**:581–7.
- 44 **Laakso MP**, Soininen H, Partanen K, et al. Volumes of hippocampus, amygdala and frontal lobes in the MRI-based diagnosis of early Alzheimer's disease: correlation with memory functions. *J Neural Transm Park Dis Dement Sect* 1995;**9**:73–86.
- 45 **Kelley WM**, Ojemann JG, Wetzel RD, et al. Wada testing reveals frontal lateralization for the memorization of words and faces. *J Cogn Neurosci* 2002;**14**:116–25.

Reference linking to full text  
of more than 200 journals

Toll free links

You can access the FULL TEXT of articles cited in the *Journal of Neurology, Neurosurgery, and Psychiatry* online if the citation is to one of the more than 200 journals hosted by HighWire (<http://highwire.stanford.edu>) without a subscription to that journal. There are also direct links from references to the Medline abstract for other titles.

[www.jnnp.com](http://www.jnnp.com)