

PEDIATRICS®

Magnetoencephalographic Patterns of Epileptiform Activity in Children With Regressive Autism Spectrum Disorders

Jeffrey D. Lewine, Richard Andrews, Michael Chez, Arun-Angelo Patil, Orrin Devinsky, Michael Smith, Andres Kanner, John T. Davis, Michael Funke, Greg Jones, Brian Chong, Sherri Provencal, Michael Weisend, Roland R. Lee, William W. Orrison and Jr, MD

Pediatrics 1999;104:405-418

DOI: 10.1542/peds.104.3.405

This information is current as of January 6, 2005

The online version of this article, along with updated information and services, is located on the World Wide Web at:

<http://www.pediatrics.org/cgi/content/full/104/3/405>

PEDIATRICS is the official journal of the American Academy of Pediatrics. A monthly publication, it has been published continuously since 1948. PEDIATRICS is owned, published, and trademarked by the American Academy of Pediatrics, 141 Northwest Point Boulevard, Elk Grove Village, Illinois, 60007. Copyright © 2004 by the American Academy of Pediatrics. All rights reserved. Print ISSN: 0031-4005. Online ISSN: 1098-4275.

American Academy of Pediatrics

DEDICATED TO THE HEALTH OF ALL CHILDREN™



Magnetoencephalographic Patterns of Epileptiform Activity in Children With Regressive Autism Spectrum Disorders

Jeffrey D. Lewine, PhD*; Richard Andrews, MD†; Michael Chez, MD§; Arun-Angelo Patil, MD||; Orrin Devinsky, MD¶; Michael Smith, MD#; Andres Kanner, MD#; John T. Davis, PhD*; Michael Funke, MD, PhD*; Greg Jones, PhD*; Brian Chong, MD*; Sherri Provencal, MA*; Michael Weisend, PhD**; Roland R. Lee, MD**; and William W. Orrison, Jr, MD*

ABSTRACT. *Background.* One-third of children diagnosed with autism spectrum disorders (ASDs) are reported to have had normal early development followed by an autistic regression between the ages of 2 and 3 years. This clinical profile partly parallels that seen in Landau-Kleffner syndrome (LKS), an acquired language disorder (aphasia) believed to be caused by epileptiform activity. Given the additional observation that one-third of autistic children experience one or more seizures by adolescence, epileptiform activity may play a causal role in some cases of autism.

Objective. To compare and contrast patterns of epileptiform activity in children with autistic regressions versus classic LKS to determine if there is neurobiological overlap between these conditions. It was hypothesized that many children with regressive ASDs would show epileptiform activity in a multifocal pattern that includes the same brain regions implicated in LKS.

Design. Magnetoencephalography (MEG), a noninvasive method for identifying zones of abnormal brain electrophysiology, was used to evaluate patterns of epileptiform activity during stage III sleep in 6 children with classic LKS and 50 children with regressive ASDs with onset between 20 and 36 months of age (16 with autism and 34 with pervasive developmental disorder—not otherwise specified). Whereas 5 of the 6 children with LKS had been previously diagnosed with complex-partial seizures, a clinical seizure disorder had been diagnosed for only 15 of the 50 ASD children. However, all

the children in this study had been reported to occasionally demonstrate unusual behaviors (eg, rapid blinking, holding of the hands to the ears, unprovoked crying episodes, and/or brief staring spells) which, if exhibited by a normal child, might be interpreted as indicative of a subclinical epileptiform condition. MEG data were compared with simultaneously recorded electroencephalography (EEG) data, and with data from previous 1-hour and/or 24-hour clinical EEG, when available. Multipole, spatiotemporal modeling was used to identify sites of origin and propagation for epileptiform transients.

Results. The MEG of all children with LKS showed primary or secondary epileptiform involvement of the left intra/perisylvian region, with all but 1 child showing additional involvement of the right sylvian region. In all cases of LKS, independent epileptiform activity beyond the sylvian region was absent, although propagation of activity to frontal or parietal regions was seen occasionally. MEG identified epileptiform activity in 41 of the 50 (82%) children with ASDs. In contrast, simultaneous EEG revealed epileptiform activity in only 68%. When epileptiform activity was present in the ASDs, the same intra/perisylvian regions seen to be epileptiform in LKS were active in 85% of the cases. Whereas primary activity outside of the sylvian regions was not seen for any of the children with LKS, 75% of the ASD children with epileptiform activity demonstrated additional nonsylvian zones of independent epileptiform activity. Despite the multifocal nature of the epileptiform activity in the ASDs, neurosurgical intervention aimed at control has led to a reduction of autistic features and improvement in language skills in 12 of 18 cases.

Conclusions. This study demonstrates that there is a subset of children with ASDs who demonstrate clinically relevant epileptiform activity during slow-wave sleep, and that this activity may be present even in the absence of a clinical seizure disorder. MEG showed significantly greater sensitivity to this epileptiform activity than simultaneous EEG, 1-hour clinical EEG, and 24-hour clinical EEG. The multifocal epileptiform pattern identified

From the *Department of Radiology, University of Utah, Salt Lake City, Utah; †Ra Neurological, Omaha, Nebraska; §Pediatric Neurology, Lake Forest, Illinois; the ||Department of Neurosurgery, University of Nebraska, Omaha, Nebraska; the ¶Department of Neurology, New York University, New York, New York; the #Epilepsy Program, Rush-Presbyterian St-Luke's Medical Center, Chicago, Illinois; and the **Neuroradiology Section, Veterans Administration Medical Center, Albuquerque, New Mexico.

Received for publication Oct 6, 1998; accepted Mar 16, 1999.

Reprint requests to (J.D.L.) University of Utah, 729 Arapahoe Dr, Salt Lake City, Utah 84108. E-mail: lewine@doug.med.utah.edu

PEDIATRICS (ISSN 0031 4005). Copyright © 1999 by the American Academy of Pediatrics.

by MEG in the ASDs typically includes the same perisylvian brain regions identified as abnormal in LKS. When epileptiform activity is present in the ASDs, therapeutic strategies (antiepileptic drugs, steroids, and even neurosurgery) aimed at its control can lead to a significant improvement in language and autistic features. *Pediatrics* 1999;104:405–418; *autism, pervasive developmental disorder—not otherwise specified, epilepsy, magnetoencephalography, Landau-Kleffner syndrome.*

ABBREVIATIONS. ASD, autism spectrum disorder; PDD-NOS, pervasive developmental disorder—not otherwise specified; LKS, Landau-Kleffner syndrome; EEG, electroencephalography; MSI, magnetic source imaging; MEG, magnetoencephalography; DSM, *Diagnostic and Statistical Manual of Mental Disorders*; BRE, benign rolandic epilepsy; AVM, arteriovenous malformation; MST, multiple subpial transection; CARS, Childhood Autism Rating Scale.

More than 400 000 persons in the United States suffer from autism spectrum disorders (ASDs) (ie, autism, pervasive developmental disorder—not otherwise specified [PDD-NOS], Asperger's syndrome, Rett's syndrome, and disintegrative disorder). Whereas autism was once considered to be a rare condition, it is estimated that the incidence of autistic features may be as high as 1 in 1000 children when the broader spectrum disorders are considered.¹ Autism is characterized by developmental delay, impaired reciprocal social interactions, prevalence of bizarre repetitive behaviors, sensory defensiveness, poor language skills, and anomalous cognitive abilities.

To date, most medical research on autism has focused on specification of its neurobiological correlates and elucidation of contributory genetic, infectious, biochemical, and immunologic factors, and much progress has been made in each of these areas. Whereas autism was once considered to be of psychogenic origin, it is now widely accepted to be a neurobiological condition. Yet, despite elucidations of several interesting correlates of the condition, including neuroimaging and pathology evidence of cerebellar and hippocampal abnormalities,^{2–4} the linkage between these findings and specific symptoms is sketchy and these observations have yet to pave the way toward the development of truly effective medical interventions.

A key observation in support of the neurobiological nature of ASDs has been the high incidence of epilepsy in the autistic population. It is well documented that almost 30% of persons with autism will experience one or more epileptic seizures by adolescence.^{5–9} All types of seizures have been reported in autism. Complex-partial seizures with associated centro-temporal spikes are most common,⁸ although other spike patterns have also been noted.⁹ It is noteworthy that autism is associated with a wide range of distinct neurobiological and genetic conditions, including infantile spasms, tuberous sclerosis, fragile-X, Angelman's syndrome, and untreated phenylketonuria, and an interesting common thread among these conditions is a high incidence of epilepsy.

Despite the frequent association between autism and a seizure disorder, epilepsy is typically dis-

missed as a secondary finding rather than a cardinal characteristic of the condition, especially because clinical seizures are typically not apparent until many years after the onset of autistic features. However, observations of another clinical condition—Landau-Kleffner syndrome (LKS)—suggest that subclinical epileptiform activity may be playing a greater role in the ASDs than previously suspected. LKS is a condition of an acquired developmental aphasia and auditory agnosia.^{10–13} Children with LKS develop normally, but at some time after age 3, there is a rapid loss of receptive and expressive language skills. A defining feature of LKS is that the electroencephalography (EEG) during stage III sleep shows a nearly continuous spike-wave epileptiform pattern, all in the absence of outward signs of a clinical seizure. In fact, only 70% of children with LKS are reported to have had clear clinical seizures at any time.¹³ Awake EEGs are often within normal limits, or they show only diffuse slowing and/or intermittent isolated epileptiform events. The available data are typically interpreted as indicating that it is the sleep epileptiform activity that compromises awake language skills in LKS.

An important parallel between LKS and autism is that nearly one-third of children diagnosed with ASDs are reported to have shown normal development up to 24 to 30 months of age at which time there was a developmental regression or plateau coupled with the onset of autistic behaviors.^{14–17} However, there is a critical difference with respect to the extent of cognitive deficits. In classic LKS, cognitive deficits are language domain specific, whereas in the ASDs, multiple domains of cognitive and social functioning are compromised.

Estimates of subclinical epileptiform abnormalities in the EEGs of children with ASDs range from 13% to 83% of cases studied.¹⁸ This observation, coupled with 1) the clinical parallels between LKS and regressive autism and 2) the LKS observation that nocturnal epileptiform activity can have a significant impact on daytime cognitive functioning, indicates the need for a reevaluation of the role of epileptiform activity in autism. As is the case for LKS, an important factor in the identification of epileptiform activity in autism is recordings during slow-wave sleep. For example, one study found the incidence of epileptiform activity in ASDs to be 27% when reviewing 1-hour routine EEGs, but it was almost 50% when prolonged overnight EEGs were reviewed.¹⁸

In considering the role of epileptiform activity in LKS and regressive ASDs, it would be useful to know the extent to which similar brain regions are implicated in the two conditions. In the study reported herein, it was hypothesized that children with regressive ASDs would show a high incidence of epileptiform activity with involvement of the same brain regions implicated in LKS (to account for language symptoms) plus involvement of additional brain regions (to account for ASD features in other domains). To address this hypothesis, methodology beyond conventional EEG monitoring was required. Epileptiform activity in LKS and autism is typically reported to be maximal in the EEG at central and/or

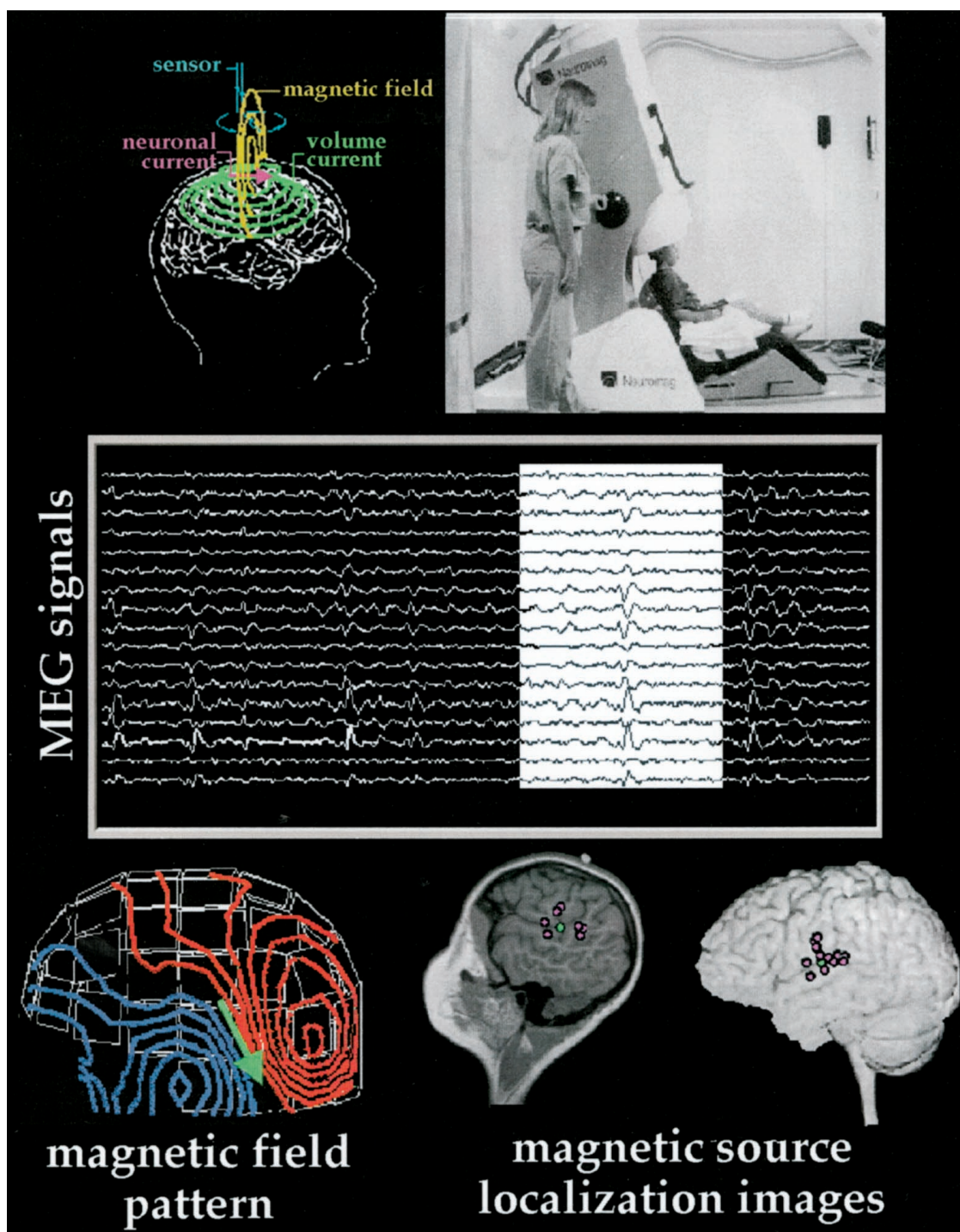


Fig 1. Neuronal currents within the dendrites of pyramidal cells give rise to a surrounding neuromagnetic field that can be measured using a biomagnetometer that contains superconducting wires coupled to superconducting quantum interference devices. The pictured unit has 122 sensors. The output of each sensor is a time-varying waveform showing how the magnetic field fluctuates. Epileptiform events like the one highlighted in white can be seen in the raw magnetoencephalography MEG signals. The associated magnetic field pattern shows flux exiting (red) and entering (blue) the head. Mathematical models are used to localize the source of the activity and to plot the source on spatially aligned magnetic resonance data. The green dot shows the inferred site of origin for the highlighted epileptiform event with purple dots showing sources for other epileptiform events in the raw signal.

temporal scalp electrodes, but more detailed localization of the neuronal sources of this activity is compromised by the variable geometry and electrical conductivity profiles of the brain, cerebrospinal fluid, skull, and scalp. The innovative technique of magnetic source imaging (MSI) offers an attractive alternative to conventional EEG for the purpose of

defining the brain zones of origin of epileptiform activity. MSI involves the combination of functional data from magnetoencephalography (MEG) with structural data from magnetic resonance imaging.^{19–21}

All time-varying electric currents, including those in neurons, produce a surrounding time-varying

TABLE 1. Landau-Kleffner Syndrome

Region	Total			Independent Activity	Propagated	
	#	E%	T%		Heterotopic	Homotopic
Either perisylvian	6	100%	100%	6	0	4
Left perisylvian	6	100%	100%	4	0	2
Right perisylvian	5	84%	84%	3	0	2
Either temporal	0	0%	0%	0	0	0
Left temporal	0	0%	0%	0	0	0
Right temporal	0	0%	0%	0	0	0
Either inferior frontal	2	33%	33%	0	2	0
Left inferior frontal	2	33%	33%	0	2	0
Right inferior frontal	0	0%	0%	0	0	0
Either M/S frontal	0	0%	0%	0	0	0
Left M/S frontal	0	0%	0%	0	0	0
Right M/S frontal	0	0%	0%	0	0	0
Either rolandic	0	0%	0%	0	0	0
Left rolandic	0	0%	0%	0	0	0
Right rolandic	0	0%	0%	0	0	0
Either parietal	0	0%	0%	0	0	0
Left parietal	0	0%	0%	0	0	0
Right parietal	1	17%	17%	0	1	0
Either occipital	0	0%	0%	0	0	0
Left occipital	0	0%	0%	0	0	0
Right occipital	0	0%	0%	0	0	0
Either cingulate	0	0%	0%	0	0	0
Left cingulate	0	0%	0%	0	0	0
Right cingulate	0	0%	0%	0	0	0

This table shows the number of LKS children with epileptiform activity in the identified region (see “Methods”). Percentages (%) are based on the subpopulation of children with epileptiform activity (E%, $N = 6$) and the total number of children in the study (T%, $N = 6$). A region was considered epileptiform if, and only if, at least 5 separate spikes showed source locations in the region. Activity within a region was classified as independently generated (Independent), a reflection of propagation from a heterotopic region within the same or opposite hemisphere (Propagated-heterotopic), or a reflection of transcallosal propagation from the homotopic area in the other hemisphere (Propagated-homotopic). Activity within a region was identified as propagated if epileptiform events arising from the region were consistently preceded by events in a different region, with a time differential of 10 to 40 milliseconds. For example, line eight indicates that 2 children (33% of the 6 children with epileptiform activity and 33% of the total population of 6 children) showed left inferior frontal activity that reflected heterotopic propagation. Abbreviation: M/S, middle and superior frontal gyri.

magnetic field. Neuromagnetic signals pass through the tissues of the body with minimal distortion, and because of biophysical properties, neuromagnetic signals recorded outside of the head selectively reflect intracellular dendritic currents. Consequently, by relatively straightforward mathematical modeling of the spatiotemporal pattern of magnetic activity associated with epileptiform events, it is possible to infer the locations in the brain where epileptiform activity originates, and to define patterns of propagation for the activity. The basic principles of MSI are outlined in Fig 1.

METHODS

Study Participants

Six children in this study had been diagnosed with classic LKS (age range, 5–11 years). As part of the defining diagnostic criteria, all had histories of an acquired aphasia with onset after 3 years of age. In each case, there was evidence of auditory agnosia, with speech and language evaluation performed a few months before the MEG study revealing limited expressive and receptive language functioning that was >2 years below chronologic age. Additional neuropsychologic testing revealed deficits to be specific to the language domain, and none of the LKS children had ever met *Diagnostic and Statistical Manual of Mental Disorders* (DSM) criteria for an ASD. The final diagnostic criteria for LKS was an EEG revealing nearly continuous spike-wave activity during slow-wave sleep. Five of the 6 children with LKS had histories of rare partial complex seizures.

Fifty children in this study (age range, 4–13 years) had been

diagnosed with a regressive ASD before the age of 6 years. Diagnosis had been made by a licensed psychiatrist, neurologist, or psychologist, using DSM-III-R or DSM-IV criteria (depending on the year when the diagnosis was made). Thirty-four children had been diagnosed with PDD-NOS, whereas 16 had been diagnosed with autism. In all cases, parental report indicated normal early development up to 18 to 30 months of age, at which time there was a regression of language, cognitive, and social skills, and the onset of autistic features. At the time of MEG study, all these children still met DSM criteria for an ASD, although for 20 of the cases, the possibility of an LKS variant had been raised by at least one clinician because language dysfunction was considerably more severe than deficits in social or other cognitive domains. Fifteen of the 50 children with regressive ASDs had been diagnosed with a clinical seizure disorder. It should be noted that all the children enrolled in this study had been reported to occasionally demonstrate unusual behavioral episodes including unprovoked blinking, crying, and/or holding of the hands to the ears. In a nonautistic child, these features would often be considered to be suggestive of a possible seizure disorder, but heretofore, most clinicians have considered these behaviors to be an inherent part of the autistic syndrome and not a separate indicator of an epileptiform condition.

Before study, all children had been sleep deprived, and all but 5 were also administered sedatives (chloral hydrate, amytriptyline, or a mixture of demerol, phenergan, and thiorazine supplemented with propofol) to promote stage III sleep.

Protocol

MEG data were collected using multiple placements of a 37-channel biomagnetometer system (Biomagnetic Technologies Inc,

Example of Classic Landau-Kleffner Syndrome

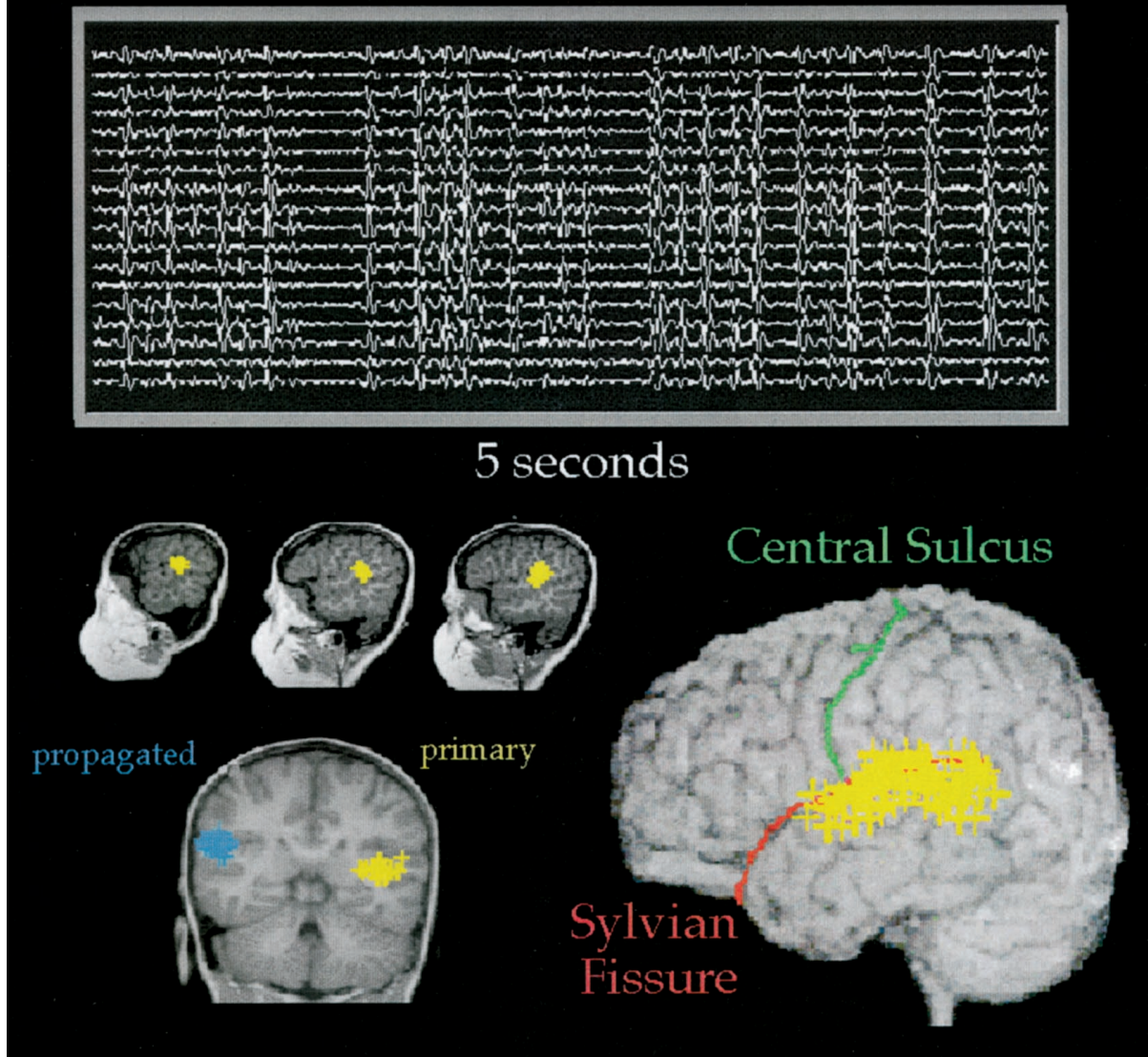


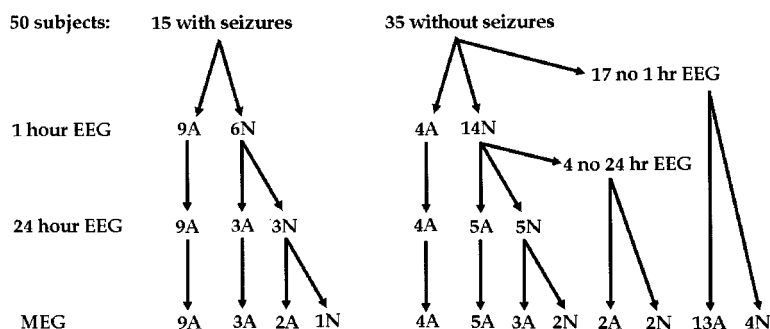
Fig 2. Data are from a 5-year-old boy with classic Landau-Kleffner syndrome. After normal initial development, the child stopped responding to commands at 2.5 years of age. By age 3, he had lost all expressive language except for a few words. Despite intensive behavioral and speech therapy, the child remained without language for the 2.5 years before study. Slow-wave sleep magnetoencephalography and electroencephalograph recordings showed nearly continuous spike-wave activity over the left hemisphere, with delayed (20 millisecond) spread to the right hemisphere. The upper panel shows 5 seconds of magnetoencephalogram data from 18 left temporal sensor locations. The magnetic field pattern associated with each of the 500+ spikes recorded during this examination was highly similar from event-to-event. Dipole modeling indicated >95% of the discharges to have unilateral origin in the upper bank of the left superior temporal gyrus, 1- to 2.5-cm deep into the sylvian plane. Yellow crosses on the spatially aligned magnetic resonance images show, for 40 representative left hemisphere epileptiform discharges, the location of the dipole source that best accounts for the initial magnetic field pattern. More than 80% of the events showed rapid (10 millisecond) propagation to the left lateral neocortical surface (including Wernicke's area and the supramarginal gyrus). In addition, ~50% of the left hemisphere spikes were followed 20 milliseconds later by a right hemisphere spike. Sources (blue crosses) for this transcallosally-mediated activity localized to the right superior temporal gyrus.

San Diego, CA) or more commonly (44 cases), using a whole-head, 122-channel system (Neuromag Ltd, Helsinki, Finland), as pictured in Fig 1. EEG data were collected simultaneous with the MEG using a specially designed electrode cap with a minimum of 19 contacts placed at the standard locations of the International 10–20 system. Forty minutes of sleep activity were recorded and analyzed in all cases. This included 15 minutes or more of slow-wave sleep in all but 6 children who failed to achieve deeper than stage II sleep. Data were collected with a band-pass of 1 to 100 Hz at a digitization rate of 300 Hz.

Data Analysis

The spontaneous electromagnetic data were visually inspected by a trained neurophysiologist, and characterized as within normal limits or as showing rare, intermittent, frequent, bursty, or continuous epileptiform discharges. When epileptiform discharges were identified, they were analyzed using a multiple-dipole, spatiotemporal source modeling algorithm (Neuromag Ltd, Helsinki, Finland). This algorithm provided the spatial location and activation time course for the set of dipole sources that

Fig 3. For children with ASDs, the table shows the number of study participants with normal (N) and abnormal (A) findings for electroencephalography (EEG) and magnetoencephalography (MEG) examinations. For example, of the 15 children with clinical seizures, 6 had normal 1-hour electroencephalographs. All 6 of these children had subsequent 24-hour electroencephalographs which were abnormal for 3 children and normal for 3 children. All children also had magnetoencephalograph examinations which were abnormal for all but 1 child.



best described each epileptiform discharge.^{19–21} The location of each dipole was taken as indicative of the location of the relevant neuronal population, and the point was marked on spatially aligned magnetic resonance images.

Sublobar characterization of the source pattern was then made relative to the following regions: P-sylvian (posterior peri- and intrasylvian regions, including the posterior aspect of the superior temporal gyrus, the intrasylvian opercular surface of the superior temporal gyrus, the supramarginal region, and the parietal operculum above the sylvian plane), temporal (all aspects of the temporal lobe except those included in P-sylvian), inf-frontal (the inferior frontal gyrus and opercular surface into the sylvian plane), M/S-frontal (the middle and superior frontal gyri), perirolandic (including pre- and postcentral gyri), parietal (all aspects of the parietal lobe except those included in P-sylvian and perirolandic), occipital (all aspects of the occipital lobe), and cingulate (all aspects of the cingulate gyrus). A region was considered epileptiform if, and only if, at least five separate spikes showed source locations in the region. Activity within a region was classified as independently generated (independent), a reflection of propagation from a heterotopic region within the same or opposite hemisphere (propagated-heterotopic), or a reflection of transcallosal propagation from the homotopic area in the other hemisphere (propagated-homotopic). Activity within a region was identified as propagated if epileptiform events arising from the region were consistently preceded by events in a different region, with a time differential of 10 to 40 milliseconds.

RESULTS

LKS

All 6 children with classic LKS demonstrated nearly continuous spike wave activity during slow-wave sleep on both MEG and simultaneous EEG. Table 1 summarizes the distribution of active areas as defined by MEG analyses. One child showed unilateral left hemisphere activity, whereas the other 5 showed bilateral epileptiform discharges. In 1 of these cases the activity was clearly independent in each hemisphere. In 2 cases the left hemisphere was significantly more active than the right and each right-sided spike was preceded by a left hemisphere spike. An example data set is shown in Fig 2. The other 2 cases showed the opposite pattern of right-sided dominance. In all cases, sources of primary spikes localized to posterior aspect of the upper bank (opercular surface) of the superior temporal gyrus, 1- to 3-cm deep into the sylvian plane, with additional primary (independent) and/or secondary (propagated) involvement of Wernicke's area and the supramarginal gyrus. In 2 cases, additional propagation of activity was seen to Broca's area. Finally, 1 case with predominantly right hemisphere intrasylvian activity also showed rare propagation of activity to the right superior parietal region. In the cases with just intra/perisylvian involvement, EEG activity was

clearly predominant at centrotemporal leads. However, in the cases with propagation to frontal or parietal sites, the EEG activity was widespread and based on EEG alone, it was not possible to clearly distinguish propagated from primary activity.

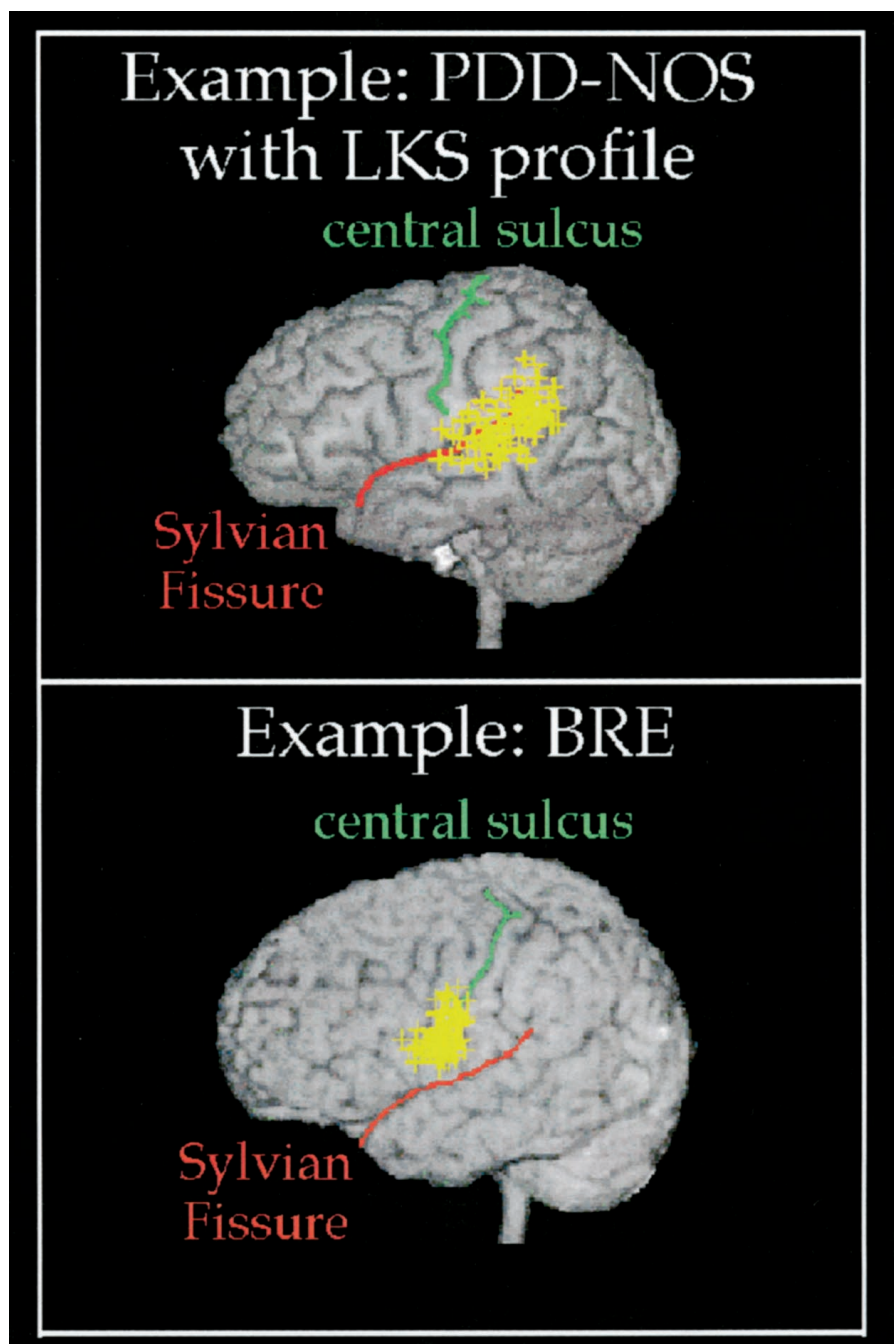
ASDs

Twenty-eight of the 34 (82%) children with PDD-NOS showed epileptiform activity on the MEG, as did 13 of 16 (81%) children with autism. Thus, 41 of 50 children with regressive ASD had definite MEG epileptiform activity, although obvious clinical seizures had been previously reported for only 15 of the 50 children. Figure 3 summarizes the relationship between the MEG and previous EEG findings.

Of the 41 children with abnormal MEG, the simultaneously recorded EEG was abnormal in 34 and normal in 7. The 7 with normal simultaneous EEG included 5 patients with previous normal 24-hour EEG, plus 2 additional patients that had not had any previous EEG examinations. In each case, the dominant site of MEG activity was deep into the sylvian plane. This implies that MEG is more sensitive to intrasylvian activity than EEG, presumably because of the spatial orientation of the relevant neuronal currents (see "Discussion").

Activity profiles for the 41 children with epileptiform MEG ranged from rare to continuous. Ten children showed only rare epileptiform activity (<1 spike/5 minutes of slow-wave sleep), 11 children showed intermittent activity (1 spike/minute), 15 showed frequent spiking (>2 spikes/minute), and 4 children showed rare 5 to 10 second bursts of spikes. One child meeting criteria for PDD-NOS showed a nearly continuous spike-wave activity profile that was almost identical with that seen in classic LKS. This child showed mild to moderate autistic features and developmental delay starting at ~18 months of age. An EEG at age 3 years showed frequent left centrotemporal epileptiform discharges, and was interpreted as indicative of concomitant atypical benign rolandic epilepsy (BRE). A significant language regression commenced at 4.5 years and a follow-up EEG again showed centrotemporal spiking, although this time the activity was nearly continuous. This EEG was interpreted as indicative of LKS, although the presence of significant autistic features in this child is inconsistent with a strict diagnosis of LKS. Si-

Fig 4. Upper panel: surface rendered data set from a 6-year-old female meeting criteria for pervasive developmental disorder-not otherwise specified. An electroencephalograph (EEG) at age 3 showed frequent spike-wave activity in sleep, with a left centrotemporal distribution. Data were initially interpreted as indicative of benign rolandic epilepsy, with some atypical features. At 4.5 years of age there was a severe language regression. EEGs showed nearly continuous spike-wave activity, with the same topography as seen on the EEG at age 3. However, given the existent clinical picture, this time the EEG data were interpreted as consistent with Landau-Kleffner syndrome. Subsequent simultaneous magnetoencephalograph/EEG revealed nearly continuous spike-wave activity in a Landau-Kleffner syndrome pattern with spike sources (yellow crosses) aligning the posterior aspects of the sylvian fissure with involvement of supramarginal regions. This pattern is in marked contrast to that seen in typical benign rolandic epilepsy, as illustrated in the lower panel. Lower panel data are from a 6-year-old female who had experienced occasional nocturnal seizures characterized by lip quivering and speech slurring. Sleep EEG revealed frequent spike-wave activity with a diffuse maxima spanning C3, T3, and F7 electrodes. Simultaneous MEG showed dipolar field patterns for the spikes with sources localizing to the inferior rolandic cortex, just anterior to the central sulcus and superior to the sylvian fissure.



multaneous EEG and MEG examination was performed at 6 years of age. This showed nearly continuous left centrotemporal discharges in slow-wave sleep, with 10% of the spikes showing propagation to the right hemisphere. There were also rare independent right hemisphere discharges. Source modeling showed the left centrotemporal activity to have its origins in posterior perisylvian regions (as is seen in classic LKS), and not in the rolandic area, as is seen in BRE (Fig 4). The propagated right hemisphere activity localized to the right superior temporal plane, as did the independent right hemisphere activity.

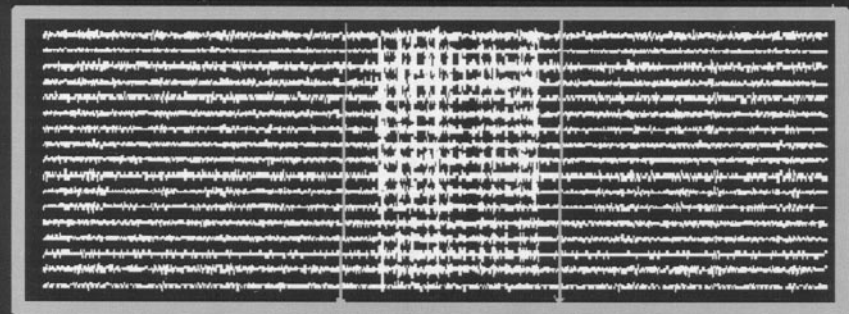
Figure 5 shows data from a 13-year-old autistic male with an intermittent burst profile. For this patient, most of the ongoing background MEG/EEG

activity was essentially normal, but this was disrupted by occasional bursts of epileptic spikes. In this case, the primary event localized to the right superior temporal plane, with subsequent propagation to the left hemisphere.

In addition to clearly epileptiform activity, many children with ASDs ($n = 29$) showed intermittent focal bursts of sharp rhythmic activity (between 8–13 Hz). Sources for this activity colocalized with sources for spikes, and it is presently believed that this activity is epileptiform and represents a burst of rapid spikes with rapid local propagation.

When epileptiform activity was present, intra/perisylvian regions identical with those found for LKS were most commonly implicated as a primary or secondary (propagated) site of activity (35 out of

Example: Autism



20 seconds

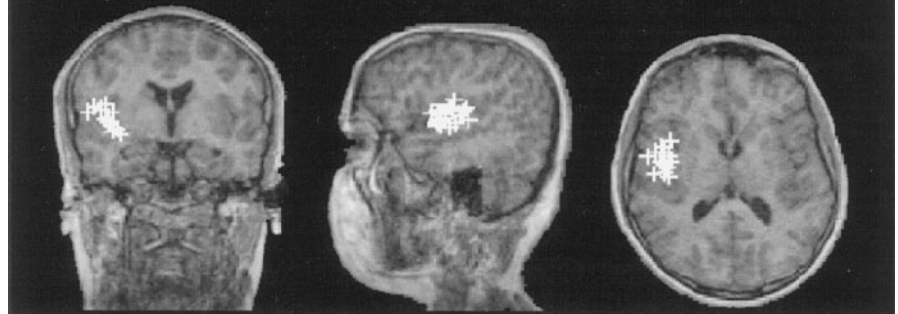


Fig 5. Data are from a 13-year-old autistic male. The upper panel shows 20 seconds of continuous data from 17 right temporal sensor locations. Most of the recorded activity was within normal limits, but as illustrated here, there were intermittent bursts of spike-wave activity. Sources (white crosses) localized to the superior temporal plane of the right hemisphere, in a pattern reminiscent of that seen in children with Landau-Kleffner syndrome.

Example: PDD-NOS

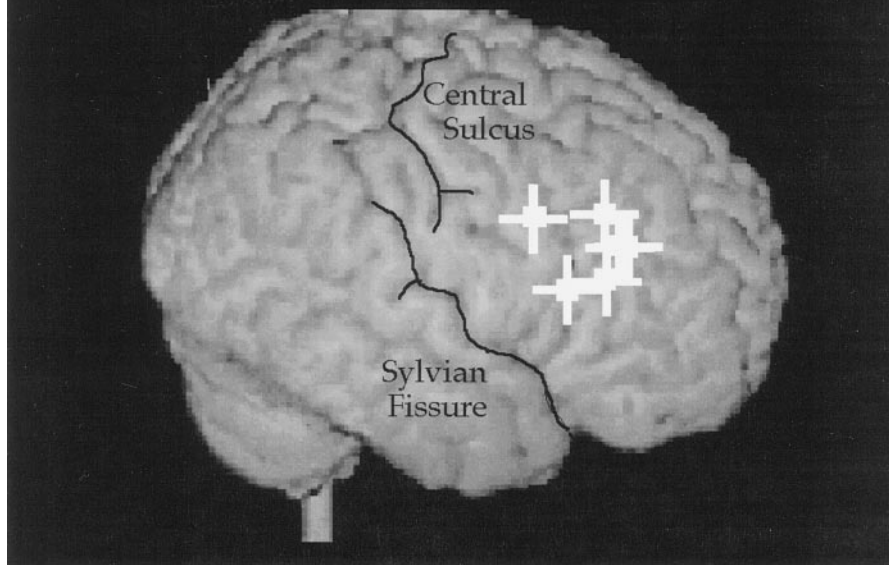
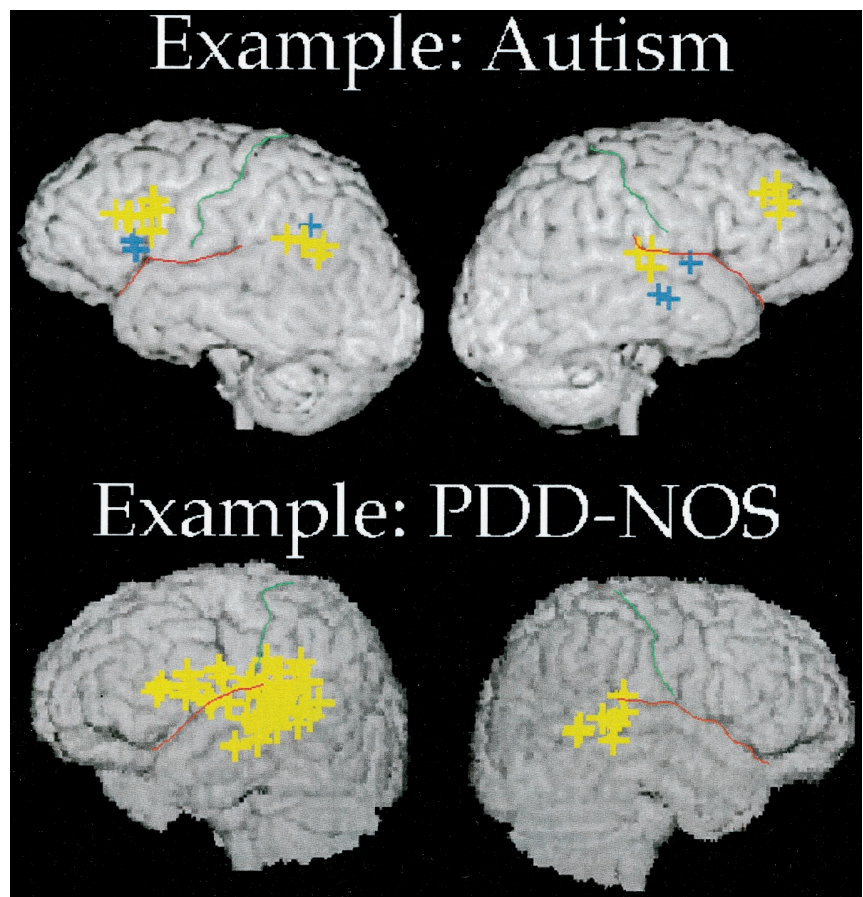


Fig 6. Data are from a 6-year-old male who showed a significant language regression at 24 months. Deficits were mostly restricted to the language domain with some mild pervasive developmental disorder features. Magnetoencephalography showed rare spikes with sources (white crosses) localizing to the right frontal lobe.

41 cases). However, there were a few children ($n = 6$) that did not show any involvement of the sylvian regions (Fig 6). It is noteworthy that in LKS, the primary independent epileptiform activity was typically unifocal (5 of 6 cases) and restricted to the

sylvian region, whereas in the ASDs, epileptiform activity was typically multifocal (31 of 41 cases; Fig 7) with active zones beyond the sylvian region. Table 2 summarizes the activity profiles for the children with ASDs.

Fig 7. Multifocal patterns were seen in 75% of the autism spectrum disorder cases with epileptiform activity. Upper panel data are from a male with a regressive autism syndrome. After normal early development, there was a dramatic regression in language, cognitive, and social skills at age 2 years, with emergence of autistic behaviors. A sleep magnetoencephalograph/electroencephalograph at 6 years of age revealed intermittent epileptiform discharges, with four independent spike foci: 1) left inferior frontal cortex (Broca's area); 2) right mid-inferior frontal cortex; 3) right temporal neocortex; and 4) the left supramarginal region. On occasion, a primary spike in one region was followed 15 to 30 milliseconds later by a secondary/propagated spike in another region. Yellow crosses represent sources of primary spikes whereas blue crosses show locations for propagated spikes. Data in the lower panel are from a female with a history of regression at 2.5 years of age. A sleep magnetoencephalograph/electroencephalograph at 7 years of age revealed relatively frequent spikes seen independently over the two hemispheres. Source modeling showed independent primary sources (yellow crosses) in the right and left perisylvian regions and the right inferior frontal region.



DISCUSSION

Rate of Epileptiform Activity in ASDs

The present study indicates a very high (82%) prevalence of sleep epileptiform activity in the described subpopulation of children with ASDs. In considering the significance of this finding, it is critical to remember that this study focused on a subset of ASD patients with a clear history of regression in language, cognition, and social skills after a period of normal development. The incidence and significance of MEG epileptiform activity in more classic early infantile autism remains to be determined, although in a preliminary (and as yet unpublished) MEG study of 25 children with early-onset (before 18 months) ASDs has revealed sleep epileptiform activity in 70%, with multifocal patterns similar to those seen for ASD children with regression. Even when considering just the select population with a history of regression, the MEG observation of epileptiform abnormalities in 82% of the children is surprisingly high when evaluated within the context of previous EEG studies.^{22,23} For example, Tuchman and Rapin²³ reviewed sleep EEG records from 130 unselected children with regressive ASDs, but only 25% of their study population showed epileptiform activity.

Several factors likely contribute to the higher incidence of epileptiform findings in the present study. One factor is a selection bias in the present study. Thirty-five of the 50 ASD patients in this study had been referred by clinicians who were explicitly suspicious that their patient(s) had some epileptiform

activity. Although clear clinical seizures had been observed in only 15 of the children, all were reported to have had episodes of sudden crying, holding of the ears, and unusual blinking patterns—paroxysmal behaviors that, for a normal child, would be considered as suggestive of an underlying epileptiform condition.

Another factor may have been that most children in this study had been sedated with amytriptiline or demerol, phenergan, and thorazine—medications that have been reported to promote slow-wave sleep and perhaps activate interictal discharges. The possibility for sedative-induced, false-positive readings is therefore present. However, the 24-hour EEG data alone (in the absence of sedation) still suggested a high prevalence of epileptiform activity for the study group.

Unfortunately, we have not been able to evaluate normal control children using the sedative agents used in this study. However, we have collected and examined MEG data from 8 nonautistic children sedated with the same agents. Each of these children had a clear seizure disorder and definitive lesion on magnetic resonance imaging (2 with tumors, 1 with an arteriovenous malformation [AVM], and 5 with cortical dysplasia). One of these children showed no interictal activity, 6 showed focal epileptiform activity only at the lesion site and without propagation to other zones, and only 1 child showed activity beyond the lesion zone. This last child had a parietal AVM and showed activity at the AVM site and also in the

TABLE 2. Regressive Autism Spectrum Disorders, Variable Epileptiform Activity in 41 out of 50 Children

Region	Total			Independent Activity	Propagated	
	#	E%	T%		Heterotopic	Homotopic
Either perisylvian	35	85%	70%	28	7	11
Left perisylvian	29	71%	58%	20	4	5
Right perisylvian	24	56%	48%	21	3	6
Either temporal	8	20%	16%	6	2	1
Left temporal	4	07%	06%	2	1	1
Right temporal	5	12%	10%	4	1	0
Either inferior frontal	23	56%	46%	13	10	1
Left inferior frontal	11	27%	22%	7	4	0
Right inferior frontal	18	43%	36%	11	6	1
Either M/S frontal	9	22%	18%	7	2	1
Left M/S frontal	5	12%	10%	3	1	1
Right M/S frontal	6	15%	12%	5	1	0
Either rolandic	14	34%	28%	11	3	2
Left rolandic	10	24%	20%	8	1	1
Right rolandic	9	22%	18%	6	2	1
Either parietal	16	39%	32%	10	6	1
Left parietal	9	22%	18%	5	3	1
Right parietal	9	22%	18%	6	3	0
Either occipital	5	12%	10%	4	1	1
Left occipital	2	04%	04%	1	0	1
Right occipital	4	07%	08%	3	1	
Either cingulate	4	10%	08%	3	1	0
Left cingulate	3	08%	06%	2	1	0
Right cingulate	1	03%	02%	1	0	0

This table shows the number of ASD children with epileptiform activity in the identified region (see "Methods"). Percentages (%) are based on the subpopulation of ASD children with epileptiform activity (E%, $N = 41$) and the total number of ASD children in the study (T%, $N = 50$). A region was considered epileptiform if, and only if, at least 5 separate spikes showed source locations in the region. Activity within a region was classified as independently generated (Independent), a reflection of propagation from a heterotopic region within the same or opposite hemisphere (Propagated-heterotopic), or a reflection of transcallosal propagation from the homotopic area in the other hemisphere (Propagated-homotopic). Activity within a region was identified as propagated if epileptiform events arising from the region were consistently preceded by events in a different region, with a time differential of 10 to 40 milliseconds.

Abbreviation: M/S, middle and superior frontal gyri.

rolandic area. In no case was sylvian activity seen. Overall, these data demonstrate that the sedative agents per se were unlikely to have induced epileptiform activity at sites not inherently abnormal.

A final factor contributing to the high incidence of epileptiform abnormalities reported here is increased sensitivity of MEG versus EEG in detecting epileptiform activity in this population of children. A total of 29 children had 1-hour and 24-hour EEG evaluations before study with MEG. For these 29 children, 45% had epileptiform activity on 1-hour EEG, 72% showed epileptiform abnormalities on 24-hour EEG, and 90% showed epileptiform abnormalities on MEG. A review of the data indicates that the critical difference between the 1-hour and 24-hour EEG examinations was the recording of activity during slow-wave sleep for the 24-hour EEG. There were 5 ASD cases with a normal 24-hour EEG examination but abnormal MEG. It is noteworthy that for each of these children, the EEG obtained simultaneous with the MEG was also considered normal. Spike activity was clear on MEG, but the simultaneous EEG revealed only low voltage transients that were not obviously epileptiform. In each case, source modeling showed the MEG spikes to have origins in the upper bank (opercular surface) of the superior temporal gyrus, deep into the sylvian fissure, with propagation of activity out to the lateral neocortical surface of the temporal lobe lacking. The apical

dendrites of pyramidal cells aligning the upper bank of the superior temporal gyrus have a tangential orientation relative to the skull. The biophysics of electromagnetic signals are such that current flow in these dendrites generates a significant magnetic signal, but only a very weak electric potential gradient at the scalp surface.^{19,20,24} Overall, the MEG was significantly more sensitive to epileptiform pathophysiology than either 1-hour ($P < .01$) or 24-hour ($P < .05$) EEG.

Distribution of Epileptiform Activity

For all the children with classic LKS, the zone of primary epileptiform involvement was the posterior perisylvian region. In some cases the primary zone was in the left hemisphere, whereas in others it was in the right hemisphere, but in all cases there was clear disruption of the left hemisphere either directly or via transcallosal propagation. This profile of left sylvian involvement in LKS has been reported in several other studies,^{24,25} and this area is known to be a critical aspect of the brain's circuitry for language.

As originally hypothesized, epileptiform activity in the ASDs went beyond that seen in classic LKS. The data suggest that ASD children with epileptiform abnormalities have LKS-like perisylvian activity (which is hypothesized to be associated with the language deficits in autism), plus activity in other regions (which is hypothesized to relate to other

TABLE 3. Surgical Profiles

Patient No.	Sex	Age	Diagnosis	Seizures	Steroids	MEG	Surgery	Months F-U	Improvements
ASD12	M	7	Autism/PDD	No	Major	Left perisylvian Right perisylvian	Left perisylvian Right perisylvian	15	Major: RL, EL, A, EC, B PPVT >2.5 years CARS-9.0
ASD16	M	7	Autism	Yes	Major	Left perisylvian	Left perisylvian Left frontal	14	Moderate: RL, EL, A, EC, B PPVT >2.5 years CARS-8.5
ASD41	M	6	PDD-NOS	No	Major	Left perisylvian Left inferior frontal Right perisylvian	Left perisylvian Left inferior frontal Right perisylvian Right inferior frontal	9	Major: RL, EL, A, EC, B PPVT >2.0 years CARS-7.0
ASD32	F	8	Autism/PDD	No	Major	Left perisylvian Left inferior frontal Right perisylvian	Left perisylvian Left inferior frontal Right perisylvian	12	Major: RL, EL, A, EC, B PPVT >2.0 years CARS-7.0
ASD26	M	6	PDD-NOS	No	Moderate	Left diffuse activity Right perirolandic Right inferior frontal Pariet-occip midline	Left perisylvian Right perirolandic Right inferior frontal Right perisylvian	15	Moderate: RL, EL, A, EC, B PPVT >2.0 years CARS-6.5
ASD20	F	6	PDD-NOS	No	Moderate	Right perisylvian Right temporal	Right perisylvian Right temporal	18	Moderate: RL, EL, A, EC, PPVT ~2.0 years CARS-5.5
ASD28	F	6	PDD-NOS	Yes	Moderate	Left perisylvian	Left perisylvian	15	Moderate: RL, EL, A, EC, B PPVT ~2.0 years CARS-5.5
ASD6	M	6	Autism	No	Mild	Left perisylvian Left inferior frontal Right perisylvian, Right inferior frontal	Left perisylvian Left inferior frontal Right perisylvian Right inferior frontal	7*	Moderate: RL, A, EC, B PPVT >1.0 years CARS-5.0
ASD10	F	7	PDD-NOS	Yes	Not tried	Left temporal Left inferior frontal Left frontal Left perisylvian	Left temporal Left inferior frontal Left frontal + SMA Left perisylvian	12*	Moderate: RL, A, EC, B PPVT >1.5 years CARS-5.0
ASD19	M	8	Autism	No	Moderate	Left perirolandic Right perirolandic Right occipital	Left perirolandic Left perisylvian Right perirolandic Right occipital Right perirolandic	11	Moderate: RL, A, EC, B PPVT not available CARS-4.5
ASD14	F	12	Autism	No	Not tried	Left inferior frontal Left occipital Right perisylvian	Left inferior frontal Left occipital Left perisylvian Right perisylvian	12	Moderate: RL, A, EC PPVT not available CARS-4.5
ASD18	F	7	PDD-NOS	No	Mild	Left perirolandic Left parietal Left inferior frontal Left perisylvian Right diffuse activity	Left perirolandic Left parietal Left inferior frontal	18	Major: RL, EL, A, EC, B PPVT >2.0 years CARS-4.0
ASD9	M	6	PDD-NOS	Yes	Moderate	Right frontal	Right frontal Left frontal	23	Mild: RL, EL, A, EC, B still having seizures PPVT not available CARS-4.0

autistic features). Somewhat unexpectedly, no significant differences were seen in the patterns for PDD-NOS versus autism per se, although the present sample size (especially for the autistic group) may have been too small to reveal such differences, especially given the general complexity of the epileptiform patterns in the ASDs. Studies are presently underway to correlate the distribution of abnormal activity with specific cognitive and behavioral features of autism.

Preliminary analyses suggest an interesting association between frontal lobe findings (especially of the right) with hyperactivity, and parietal lobe findings (especially on the left) with apraxia.

The full extent to which the identified patterns of activity are specific to autism versus the full cadre of other developmental conditions remains to be determined, but with respect to at least some other developmental conditions, specificity seems to be high.

TABLE 3. Continued

Patient No.	Sex	Age	Diagnosis	Seizures	Steroids	MEG	Surgery	Months F-U	Improvements
ASD4	F	6	Autism	No	Mild	Left perisylvian Left inferior frontal Left parietal Left occipital Right inferior frontal Right frontal Right perisylvian	Left perisylvian Left inferior frontal Left parietal Left occipital Right inferior frontal Right frontal Right perisylvian	23	Mild: RL, A, EC, B PPVT not available CARS-4.0
ASD17	M	6	PDD-NOS	Yes	Mild	Left perisylvian Left temporal Left inferior frontal Right perisylvian Right inferior frontal	Left perisylvian Left temporal Left inferior frontal Right perisylvian Right inferior frontal	8*	Mild: RL, A, EC PPVT not available CARS-3.5
ASD23	M	5	Autism	Yes	Mild	Right perirolandic Right perisylvian	Left perisylvian Right perirolandic Right perisylvian	12*	Mild: RL, EC still having seizures PPVT not available CARS-2.0
ASD21	M	8	Autism	Yes	Major	Left perisylvian Left perirolandic Left inferior frontal	Left perisylvian Left perirolandic Left inferior frontal Right frontal	18	Mild: RL, A, EC Initially showed major improvement but regressed-presently PPVT not available CARS-2.0
ASD22	M	5	Autism	No	None	Left perisylvian Right perisylvian Right parietal Right inferior frontal	Left perisylvian Left inferior frontal Right perisylvian Right parietal Right inferior frontal	8*	Mild: A, EC PPVT not available CARS-1.0

This table provides information on each child who underwent surgery. Data include patient number, sex, age, diagnosis, presence of clinical seizures, extent of cognitive improvement with high-dose steroid therapy, location of MEG spikes, region of surgical intervention, months postsurgery at time of follow-up, and the general level of postsurgical improvement with an explicit listing of improved domains (RL, receptive language; EL, expressive language; A, attention; EC, eye contact, B, behavior and social functioning). When available, data are provided on the extent of postsurgical improvement in receptive language performance as assessed via the Peabody Picture Vocabulary Test (PPVT). Postsurgical improvement on the Childhood Autism Rating Scale (CARS) is provided also.

* Indicates that a second surgical procedure was performed because following initial improvements after the first procedure, there was a regression of skills and reemergence of epileptiform activity. Follow-up data are provided relative to the second surgery.

For example, in BRE, our group and others^{24,26,27} have shown dipole sources to localize exclusively to the mid- and inferior perirolandic cortex, without perisylvian involvement (Fig 4). The associated current vectors for the dipoles in BRE are oriented in a horizontal (anterior-posterior) manner, perpendicular to the central sulcus. This is in marked contrast to what is seen for the perisylvian dipoles of both LKS and the ASDs where the current vector is oriented in a vertical (superior-inferior) manner, perpendicular to the sylvian plane. Seven of the ASD children showed evidence of BRE-like dipoles in the inferior precentral region, but in only 1 case was this the dominant site of activity and in all cases there was additional independent perisylvian activity.

In considering the implications of epileptiform activity in the ASDs, it must be noted that the relative import of frequent versus rare activity in a region is uncertain. It has been hypothesized by Morrell and colleagues²⁸ that the mechanism via which epileptiform activity disrupts cognitive functioning in LKS (and putatively in the ASDs) is through disruption of the normal refinement and pruning of synaptic connections. There is a natural tendency to believe that frequent activity should be more disruptive than rare activity, but this is not necessarily the case. There may be a threshold phenomena in which a few epileptiform events is sufficient to disrupt the formation

of correct neural networks, and it makes little difference if the total number of events exceeds this.

Treatment Strategies

Observations that LKS is amenable to some medical interventions raises some hope that amelioration of epileptiform activity in children with ASDs might lead to improved language skills and a reduction in autistic features. During the last 2 decades, three major therapeutic strategies have been developed for children with LKS. The first strategy involves administration of an antiepileptic drug, typically a valproate. Depakote and depakene are generally effective at controlling clinical seizures in LKS, and they may lead to improvements in receptive language. However, their administration rarely leads to significant improvements in expressive language, presumably because these medications often fail to completely eliminate nocturnal epileptiform abnormalities. A second therapeutic strategy for LKS involves administration of daily high dosages of steroids (1–3 mg/kg/d) or weekly pulsed-doses (8–10 mg/kg/wk).^{28–32} Several studies show that steroid therapy is highly effective in providing some degree of recovery of expressive and receptive language skills in more than 50% of children with LKS, but once steroids are discontinued (as dictated by safety

concerns—steroids have many side-effects including significant weight gain and hypertension), language skills often regress. The third therapeutic strategy for LKS involves multiple subpial transections (MST) and small resections in the area of epileptic brain tissue. The multiple subpial transection technique is designed to disrupt the transverse fiber system of the cortex while leaving intact the vertical columnar organization of the cortex. The notion behind the procedure is that elimination of transverse connections disrupts the ability of adjacent cortical columns to synchronize in the generation of an epileptiform spike, but it leaves the dominant functional columnar organization of the cortex relatively unperturbed. Available data indicate that, for >50% of children with a diagnosis of classic LKS, surgical intervention results in excellent outcomes, including achievement of age-appropriate language.^{28,32,33} All 6 children reported in this study have undergone MST surgery. Three of these children now demonstrate age-appropriate language. Two other children have shown significant improvements in receptive and expressive language (although both continue to receive speech and language therapy). Only 1 child has not shown significant postsurgical improvement. This is the child who had shown bilateral and independent left and right hemisphere perisylvian activity. The left hemisphere abnormalities were considerably more severe, and MST surgery was performed only in the left hemisphere. Whereas follow-up EEG indicates that the left hemisphere is no longer epileptiform, there are persistent right hemisphere abnormalities.

Case reports and anecdotal data from several laboratories suggest that treatment of the ASDs with anticonvulsant medication,^{34–38} high dose steroid therapy,^{38,39} or even neurosurgery^{40,41} can lead to improvements in language and autistic behaviors. In the past 2 years, 18 of the ASD children from this MEG study have undergone neurosurgical intervention involving multiple subpial transections with or without small topectomies (<1cm) or gyrectomy (in 2 cases). The basics of the surgical procedures are described by Patil and Andrews.⁴¹ Surgical profiles and results are summarized in Table 3.

In each case, the objective of surgery was to control the epileptiform activity, and neurosurgery was considered only for a child whose cognitive and social functioning had reached a plateau, despite intensive behavioral interventions and extensive anticonvulsant and psychopharmacologic manipulations. Seven of the children that underwent surgery had histories of rare clinical complex-partial seizures, and all had been reported to demonstrate frequent and unusual paroxysmal behaviors (crying, blinking, and ear holding) and occasional staring spells suggestive of subclinical seizures.

Surgery was always guided by extra- and intraoperative electrocorticography, MEG data being used partially to direct subdural grid placement and to indicate areas of likely activity. In all cases, corticography confirmed MEG identified zones as epileptogenic. In 6 cases, additional epileptogenic areas (not identified by either MEG or scalp EEG) were identified during ex-

tended intracranial monitoring. As mentioned previously, most cases showed multilobar and even bihemispheric epileptiform activity. In these cases, surgical intervention was applied at multiple sites.

At present, only short-term (<2 years) follow-up data are available on the surgical cases, but as summarized below, preliminary data encourage the belief that neurosurgical intervention aimed at alleviating epileptiform activity can have a positive impact on the autistic features of some children.

By parental report, 4 children have shown dramatic postsurgical reductions in aberrant autistic behaviors and very major improvements in eye contact, receptive and expressive language skills, and behavior, including social functioning. In the first year after surgery, each of these children showed an increase in performance on the Peabody Picture Vocabulary Test-Revised⁴² of >2 years, and scores on the Childhood Autism Rating Scale⁴³ decreased by an average of 8 points after surgery. It must be noted that, despite these impressive gains, these children are not now normal, epileptiform activity having robbed these children of years of unperturbed cognitive and social development. All the children still meet criteria for an ASD, but the postsurgical symptom profiles are much less severe than the presurgical profiles.

Eight children have shown moderate postsurgical benefits including reduced hyperactivity, improved eye contact, increased social interactions, and improved receptive language skills. Expressive language skills have been slower to develop than receptive language skills, but spontaneous speech is starting to emerge in all but 3 cases. Intermittent problems remain for some, but improvement on the Childhood Autism Rating Scale (CARS) has ranged from 4.0 to 6.5 points.

Six children have shown postsurgical improvement in receptive language and social interactions, but some self-stimulatory behaviors persist and improvement in other domains have been transient. In 4 of these cases, there were significant initial improvements that were followed by a regression at around 6 months after surgery. All these children had complicated multifocal patterns and all have shown some persistent epileptiform activity on follow-up EEG and MEG.

In considering the potential benefits of a surgical option, it is important to note that surgery is not performed in isolation. A strong postsurgical education plan that includes speech, language, occupational, and behavioral therapy is critical. Typically, the postsurgical plan for each child differed little from what was tried before surgery, but after elimination of the epileptiform activity, educational strategies that had been only marginally successful presurgery yielded a major positive impact after surgery.

At present there are insufficient data to indicate which children with ASDs and epileptiform abnormalities are the best surgical candidates, in that good outcomes have been seen even in some very complicated cases. The best outcomes have been in those children responsive to previous steroid therapy and with the focal epileptiform presentations involving only one or two zones in the temporal or frontal lobes, but a failure to respond to steroid and/or a

multilobar, bihemispheric pattern of epileptiform activity is not necessarily a contraindication to surgery.

CONCLUDING REMARKS

In summary, the data indicate that epileptiform abnormalities are found in a significant subpopulation of children with ASDs. Adequate electrophysiologic monitoring during slow-wave sleep is often requisite to identification of this activity, and such monitoring should be an integral part of the clinical work-up of a child with an ASD, especially if there is a history of regression. MEG and 24-hour EEG are significantly more sensitive than 1-hour EEG and they are the strategies of choice. When epileptiform activity is present, medical therapy designed at ameliorating the epileptiform activity may lead to an improvement in autistic features. The precise merits of specific interventions using traditional (anticonvulsant medications) or non-traditional strategies (high dose steroid therapy and neurosurgery) remain to be determined through controlled scientific trials involving blinded pre- and post-treatment assessment of behavioral, cognitive, and psychosocial features, but the available data clearly indicate that epileptiform activity should not be ignored in children with autistic features.

ACKNOWLEDGMENTS

This work was supported by grants from: The March of Dimes Birth Defects Foundation, The National Alliance for Research in Schizophrenia and Depression, Primary Childrens Medical Center Foundation, Picker International, and Biomagnetic Technologies, Inc. The authors are grateful to the technical and administrative staffs of the Magnetic Source Imaging Facilities at the University of Utah and the Albuquerque Veterans Administration Medical Center.

This work is dedicated to the memory of Dr Frank Morrell who pioneered the multiple subpial transection technique which has proven to be pivotal in the treatment of children with acquired aphasic conditions.

REFERENCES

- Bryson SE. Epidemiology of autism: overview and issues outstanding. In: Cohen DJ, Volkmar FR, eds. *Handbook of Autism and Pervasive Developmental Disorders*. 2nd ed. New York, NY: Wiley; 1997:41–46
- Bauman ML, Kemper TL. Histoanatomic observations of the brain in early infantile autism. *Neurology*. 1985;35:866–874
- Bauman ML, Kemper TL. Neuroanatomic observations of the brain in autism. In: Bauman ML, Kemper TL, eds. *The Neurobiology of Autism*. Baltimore, MD: The Johns Hopkins University Press; 1994
- Courchesne E, Yeung-Courchesne R, Press GA, Hesselink JR, Jernigan TL. Hypoplasia of cerebellar vermal lobules VI and VII in autism. *N Engl J Med*. 1988;318:1349–1354
- Deykin EY, MacMahon B. The incidence of seizures among children with autistic symptoms. *Am J Psychiatry*. 1979;136:1310–1312
- Olson I, Steffenburg S, Gillberg C. Epilepsy in autism and autistic-like conditions. *Arch Neurol*. 1988;45:666–668
- Volkman FR, Nelson DS. Seizure disorders in autism. *J Am Acad Child Psychiatry*. 1990;29:127–129
- Tuchman R, Rapin I, Shinnar S. Autistic and dysphasic children: II. Epilepsy. *Pediatrics*. 1991;88:1219–1225
- Nass R, Gross A, Devinsky O. Autism and autistic epileptiform regression with occipital spikes. *Dev Med Child Neurol*. 1998;40:453–458
- Landau WM, Kleffner FR. Syndrome of acquired aphasia and convulsive disorder in children. *Neurology*. 1957;7:523–530
- Deonna TW. Acquired epileptiform aphasia in children (Landau-Kleffner syndrome). *J Clin Neurophysiol*. 1991;8:288–298
- Gordon N. The Landau-Kleffner syndrome: increased understanding. *Brain Dev*. 1997;19:311–316
- Beaumanoir A. The Landau-Kleffner syndrome. In: Roger J, Dravet C, Bureau M, Dreifuss FE, Wolf P. *Epileptic Syndromes In Infancy, Childhood, and Adolescence*. Paris, France: John Libbey Eurotext Ltd; 1985:181–191
- Rogers SJ, DiLalla DL. Age of symptom onset in young children with pervasive developmental disorders. *J Am Acad Child Adolesc Psychiatry*. 1990;29:863–872
- Burack J, Volkmar F. Development of low and high functioning autistic children. *J Child Psychol Psychiatry*. 1992;33:607–616
- Kurita H. Infantile autism with speech loss before thirty months. *J Am Acad Child Psychiatry*. 1985;24:191–196
- Tuchman R, Rapin I, Shinnar S. Autistic and dysphasic children: I. Clinical characteristics. *Pediatrics*. 1991;88:1211–1218
- Tuchman R, Jayakar P, Yaylali I, Villalobos R. Seizures and EEG findings in children with autism spectrum disorders. *CNS Spectrums*. 1997;3:61–70
- Lewine JD, Orrison WW. Magnetoencephalography and magnetic source imaging. In: Orrison WW, Lewine JD, Sanders JA, Hartshorne MF, eds. *Functional Brain Imaging*. St. Louis, MO: Mosby Year Book, Inc; 1995:369–418
- Lewine JD, Orrison WW. Magnetic source imaging. Basic principles and applications in neuroradiology. *Academic Radiology*. 1995;2:436–440
- Lewine JD, Orrison WW. Spike and slow wave localization by magnetoencephalography. *Neuroimaging clinics of North America. Epilepsy*. 1995;5:575–596
- DeMyer MK. Research in infantile autism: a strategy and its results. *Biol Psychiatry*. 1975;10:433
- Tuchman R, Rapin I. Regression in pervasive developmental disorders: seizures and epileptiform electroencephalogram correlates. *Pediatrics*. 1997;99:560–566
- Lewine JD, Morrell F, Orrison WW Jr. Neuromagnetic evaluation of normal and abnormal brain function in epilepsy. *Int J Neuroradiol*. 1995;1:182–198
- Paetau R, Kajola M, Korkman M, et al. Landau-Kleffner syndrome: epileptic activity in the auditory cortex. *Neuroreport*. 1991;2:201–204
- Baumgartner C, Graf M, Doppelbauer A, et al. The functional organization of the interictal spike complex in benign rolandic epilepsy. *Epilepsia*. 1996;37:1164–1174
- Minami T, Gondo K, Yamamoto T, Yanai S, Tasaki K, Ueda K. Magnetoencephalographic analysis of rolandic discharges in benign childhood epilepsy. *Ann Neurol*. 1996;39:326–334
- Morrell F, Whisler WW, Smith MC, et al. Landau-Kleffner syndrome: treatment with multiple sub-pial transection. *Brain*. 1995;118:1529–1546
- Marescaux C, Hirsch E, Finck S, et al. Landau-Kleffner syndrome: a pharmacological study of five cases. *Epilepsia*. 1990;31:768–777
- Lerman P, Lerman-Saige T, Kivity S. Effects of early corticosteroid therapy for Landau-Kleffner syndrome. *Dev Med Child Neurol*. 1991;33:257–260
- Aykut-Bingol C, Arman A, Tokol O. Pulse methylprednisone therapy in Landau-Kleffner syndrome. *J Epilepsy*. 1996;9:189–191
- Sawhney IM, Robertson IJ, Polkey CE, Binnie CD, Elwes RDC. Multiple sub-pial transection: a review of 21 cases. *J Neurol Neurosurg Psychiatry*. 1995;58:344–349
- Smith MC. Multiple sub-pial transection in patients with extratemporal epilepsy. *Epilepsia*. 1998;39:S81–S89
- Gillberg C, Schaumann H. Epilepsy presenting as infantile autism? Two case studies. *Neuropediatrics*. 1983;14:206–212
- Plioplys AV. Autism: electroencephalographic abnormalities and clinical improvement with valproic acid. *Arch Pediatr Adolesc Med*. 1994;34:1107–1111
- Uvebrant P, Bauziene R. Intractable epilepsy in children, the efficacy of lamotrigine treatment, including non-seizure-related benefits. *Neuropediatrics*. 1994;25:284–289
- Childs JA, Blair JL. Valproic acid treatment of epilepsy in autistic twins. *J Neurosci Nursing*. 1977;29:244
- Stefanatos GA, Grover W, Geller E. Case study: corticosteroid treatment of language regression in pervasive developmental disorder. *J Am Acad Child Psychiatry*. 1995;34:1107–1111
- Chez M, Buchanan C, Loeffel M, et al. Practical treatment with pulse dose corticosteroids in pervasive developmental delay or autistic patients with abnormal epileptiform sleep EEG and language delay. In: *Proceedings of the 8th International Child Neurology Conference*. Bologna, Italy: Monduzzi Editors, S.p. A.; 1998:695–698
- Neville BG, Harkness WF, Cross JH, et al. Surgical treatment of severe autistic regression in childhood epilepsy. *Pediatric Neurol*. 1997;16:137–140
- Patil AA, Andrews R. Surgical treatment of autistic epileptiform regression. *J Epilepsy*. 1998;11:368–373
- Dunn L, Dunn L. *Peabody Picture Vocabulary Test-Revised*. Circle Pines, MN: American Guidance Service; 1981
- Schopler E, Reichler RJ, DeVellis RF, Daly K. Toward objective classification of autism. *J Aut Dev Dis*. 1980;10:91

Magnetoencephalographic Patterns of Epileptiform Activity in Children With Regressive Autism Spectrum Disorders

Jeffrey D. Lewine, Richard Andrews, Michael Chez, Arun-Angelo Patil, Orrin Devinsky, Michael Smith, Andres Kanner, John T. Davis, Michael Funke, Greg Jones, Brian Chong, Sherri Provencal, Michael Weisend, Roland R. Lee, William W. Orrison and Jr, MD

Pediatrics 1999;104:405-418

DOI: 10.1542/peds.104.3.405

This information is current as of January 6, 2005

Updated Information & Services	including high-resolution figures, can be found at: http://www.pediatrics.org/cgi/content/full/104/3/405
References	This article cites 37 articles, 9 of which you can access for free at: http://www.pediatrics.org/cgi/content/full/104/3/405#BIBL
Citations	This article has been cited by 2 HighWire-hosted articles: http://www.pediatrics.org/cgi/content/full/104/3/405#otherarticles
Subspecialty Collections	This article, along with others on similar topics, appears in the following collection(s): Neurology & Psychiatry http://www.pediatrics.org/cgi/collection/neurology_and_psy psychiatry
Permissions & Licensing	Information about reproducing this article in parts (figures, tables) or in its entirety can be found online at: http://www.pediatrics.org/misc/Permissions.shtml
Reprints	Information about ordering reprints can be found online: http://www.pediatrics.org/misc/reprints.shtml

American Academy of Pediatrics

DEDICATED TO THE HEALTH OF ALL CHILDREN™

