

THE LANCET

A medical report from the stone age?

L Dorfer M Moser F Bahr K Spindler
E Egarter-Vigl S Guillén G Dohr T Kenner

**Reprinted from THE LANCET Saturday 18 September 1999
Vol. 354 No. 9183 Pages 1023–1025**

Department of medical history

A medical report from the stone age?

L Dorfer, M Moser, F Bahr, K Spindler, E Egarter-Vigl, S Guillén, G Dohr, T Kenner

During the last decades of this century several prehistoric human mummies with well-preserved tattoos have been found in Siberia, Peru, and Chile.^{1,2} Some of the tattoos were obviously decorative, but others were of less aesthetic value and of unknown use.

In the well-preserved mummy of a Scythian horseman (figure 1), there are ornamental and non-ornamental tattoos. The difference in the tattoos is so obvious that there is speculation about a possible therapeutic importance of the ones in the perivertebral and retromalleolar region.³

In 1992, a mummy was discovered in the necropolis of Chiribaya Alta, southern Peru. The mummy had ornamental tattoos depicting stylised apes, birds, and reptiles on the forearms, hands, and lower legs (figure 2, top). There were additional tattoos on the neck and the upper part of the back. They are circular, of simple shape, and remain hidden by the neckhairs and the clothing (figure 2, bottom). The hidden position of these marks points to the possibility that they have therapeutic importance (SG, KS, unpublished observations).

The Tyrolian Iceman,^{4,6} the oldest European mummified human body with tattoos, shows some 15 groups of tattoo-lines on the back and legs. They do not seem to have decorative importance because they have a simple linear geometric shape and are located on the less visible parts of the body. The question arises as to whether they also have medical significance.⁷

One of us (FB) was looking through photographs in the book *The Man in the Ice*⁶ and noticed a striking proximity of some of the tattoo locations to the locations of classical acupuncture points. This initiated our investigation;

we hypothesised that there might have been a medical system similar to acupuncture (Chinese *Zhenjiu*: needling and burning) that was practised in Central Europe 5200 years ago.

In acupuncture, the location of points is defined by a relational measure (the *cun*, Chinese for inch) derived from the anatomy of the patient. The *cun* is defined by the width of the interphalangeal joint of the thumb but can also be determined by a certain fraction of the length of the femur, the tibia, or the radius.⁸ Using these relations and published data of the Iceman,⁹ we calculated that his *cun* was about 22 mm or about an inch. We then converted the morphometric measures of the tattoos¹⁰ to *cun* and overlaid the locations of the tattoos to topographical representations of the Chinese acupuncture points as referenced in acupuncture texts.^{8,11,12} To investigate the in-situ situation in the mummy, one of us (LD), an experienced acupuncturist, subsequently investigated the tattoos morphometrically during a visit to the Iceman in his special chamber at the Prehistoric Museum of Bozen, Bolzano, Italy.

The results are shown in the table. Expert opinions from three acupuncture societies¹³ indicate that nine of the tattoos could be identified as being located directly on or within 6 mm of traditional acupuncture points. Two more tattoos are located on an acupuncture meridian but not close to a point. One tattoo is a local point. Three tattoos are situated between 6 mm and 13 mm from the closest acupuncture points.¹⁴

Figure 3 illustrates some of our findings. The top part of figure 3 shows four tattoo groups on the left side and one on the right side of the dorsal spine. They are close to or lie directly over acupuncture-points of the urinary bladder-meridian. The bottom part of this figure shows one of the tattoo crosses, which is situated behind and above the left lateral malleolus, corresponding to the urinary-bladder 60 acupuncture point.

In acupuncture, needling at specific points modifies the underlying "qi energy" affecting inner organs, pain perception, and inflammatory processes. The traditional points are predominantly located on 12 principal and a few minor meridians. Each meridian corresponds to an organ or organ system. Interestingly, nine of the tattoo-groups are located on the urinary bladder meridian and three on the gall bladder meridian.

There are several types of acupuncture treatment. In the traditional form, classical points are used, and the objective

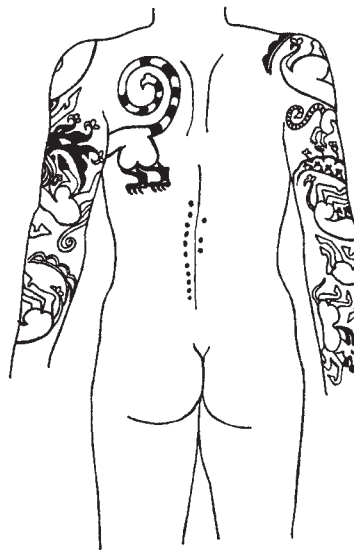


Figure 1: **Back of a well-preserved Scythian mummy**^{4,3}

Shows two types of tattoos: elaborate ornamental tattoos are located on the arms and the upper part of the back, whereas possible therapeutic, non-ornamental tattoos run along the spinal column (figure drawn after ref 3).

Lancet 1999; **354**: 1023–25

Physiological Institute, University of Graz, Austria (L Dorfer MD, M Moser PhD, T Kenner MD); **Austrian Society for Controlled Acupuncture, Graz, Austria** (L Dorfer); **Joanneum Research Institute for Noninvasive Diagnosis, Welz, Austria** (M Moser, T Kenner); **German Academy for Acupuncture and Auriculomedicine, Munich, Germany** (E Bahr MD); **Institute for Pre- and Protohistory, University Innsbruck, Austria** (K Spindler PhD); **Pathological Institute, Bozen/Bolzano, Italy** (E Egarter-Vigl MD); **Centro Mallqui, Ilo, Peru** (S Guillén PhD); and **Institute for Histology and Embryology, University Graz, Austria** (G Dohr MD)

Correspondence to: M Moser, Physiological Institute, University of Graz, A-8010 Graz, Harrachgasse 21, Austria

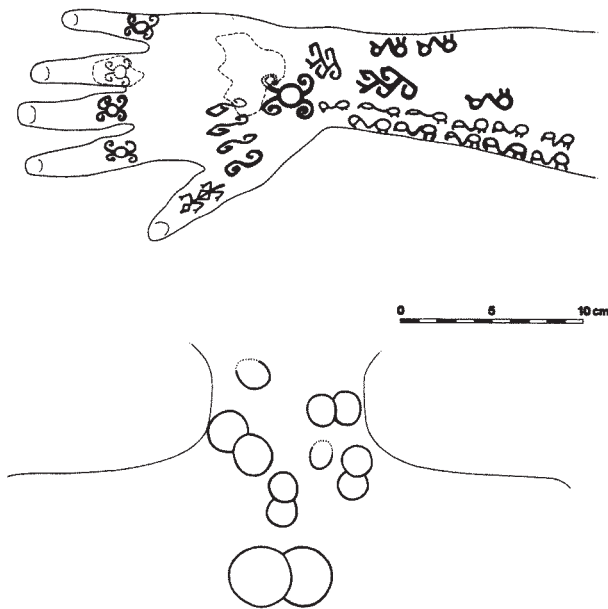


Figure 2: **Tattoos on a mummy found in Chiribaya Alta, southern Peru**

Top, ornamental tattoos on the hand depicting stylised apes, birds and reptiles. Bottom, possible therapeutic tattoos on the same mummy located on the neck and the upper part of the back. Tattoos have simple, circular, partly overlapping forms and would have been hidden by neckhairs and clothing during the lifetime of the bearer. (Both figures drawn by KS, unpublished).

is to restore and maintain a balanced “energy” state in the individual. These classical points may be remote from the diseased site. Another form of treatment involves the application of needles surrounding the symptomatic areas (locus dolendi therapy).

Histological investigations of the Iceman’s tattoos¹⁵ have shown that rounded pigment particles, possibly consisting of charcoal,⁶ were used as a colouring agent. This led to the hypothesis proposed by Capasso¹⁶ that the tattoos were produced by incision of the skin surface followed by the burning of herbal powder in the wound. Van der Velden and colleagues¹⁵ concluded from their histological study that contemporary therapeutic tattoos found in India and Africa were strikingly similar to those of the Iceman. Clearly there is a methodological difference between tattooing and needle acupuncture. However, this difference may be comparable to the difference between applying a pharmacological agent either by injection or by intravenous infusion: the application is different but the idea is the same.

From radiological studies¹⁷ the Iceman had moderate arthrosis in the hip joints, knee joints, ankle joints, and the lumbar spine. Tattoos situated near the affected areas are shown in the table. From our results we conclude that the tribe of the Iceman was familiar with a simple form of locus-dolendi acupuncture as proposed recently.¹⁰

If a modern acupuncturist were to diagnose lumbar arthrosis, points on the urinary-bladder meridian, running from the head along the back to the fifth toe would be punctured. In published work on acupuncture^{8,11,18} the urinary-bladder 60 point is regarded as a “masterpoint for back pain”. On the Iceman, one of the two tattoo-crosses is located on urinary-bladder 60 point behind the lateral malleolus of the ankle (see bottom part of figure 3). As mentioned, nine of the 15 tattoos are located on the urinary bladder meridian. Taken together the tattoos could

be viewed as a medical report from the stone age, or possibly as a guide to self-treatment marking where to puncture, when pains occur. The fact that not randomly selected points, but rather corresponding groups of points were marked by tattoos, seems especially intriguing. From an acupuncturist’s viewpoint, the combination of points selected represents a meaningful therapeutic regimen.¹⁹ Slight differences between the location of some of the tattoo points and classical acupuncture-sites might be explained by twisting of the Iceman’s skin relative to underlying structures that may have occurred during 5000 years in the ice. This is especially obvious in the tattoos on the back (top part of figure 3), which are very likely to have been applied symmetrically to the spine and are partly shifted today out of symmetry according to their location on the twisted body.

There are other tattoo points, which are not addressed in the radiological results. Most are located on the gall bladder, spleen, or liver meridian (see table). These points are used when a patient has abdominal disorders.²⁰ Recent findings revealed numerous eggs of whipworms (*Trichuris trichiura*) in the Iceman’s colon.²¹ This would no doubt have affected his abdominal function as speculated by Capasso.¹⁶ The finding of a remarkable amount of charcoal in the colon of the Iceman²² and the presence of a phytotherapeutic remedy, the woody fruit of *Piptoporus betulinus*,^{6,16} found in the Iceman’s belongings, testify to the Iceman’s abdominal problems.

The above findings provide strong evidence that a form of medical therapeutics, very similar to what we know as Chinese acupuncture, was already in practice 5200 years ago in Central Europe. The permanent tattoos served either as a form of prolonged treatment for the arthrosis

Tattoo location and shape	Acupuncture point	Distance between tattoo and acupuncture point (mm)	Acupuncture points for:	
			Lumbar arthrosis	Abdominal disorders
Left back				
Upper 4 lines*	UB21	4	✓	✓
Upper 3 lines*	UB22	3	✓	✓
Lower 3 lines*	UB23	0†	✓	✓
Lower 4 lines*	UB25	0†	✓	✓
Right back				
4 lines*	UB24	13	(✓)	(✓)
Right leg				
Cross on the knee, medial*	Li8	0†		✓
3 lines, medial	Ki7, SP6	0††	✓	✓
3 lines, frontal*	Local point between GB40 and ST41			
Upper 3 lines, lateral	On GB			(✓)
2 lines, lateral	GB37, but dorsal to fibula	7		(✓)
Lower 3 lines, lateral	GB38, but dorsal to fibula	6		(✓)
Left leg				
7 lines, dorsal	On UB56	2	✓	
3 lines, dorsal	On UB between UB58 and UB59		(✓)	
1 line dorsal	UB59	0†	✓	
Dorsal cross at lateral malleolus*	UB60	4	✓	

*Tattoos near affected area of arthrosis. †Tattoo located directly at acupuncture point. ††Two acupuncture points. ✓=present. GB=gallbladder meridian, Ki=kidney meridian, Li=liver meridian, SP=spleen meridian, ST=stomach meridian, UB=urinary bladder meridian. Tattoos located more than 5 mm distant of a known acupuncture point are in parentheses in the columns “Acupuncture points for:”.

Location of the 15 known present tattoo groups on the Tyrolean Iceman and their corresponding classical acupuncture points^{7,10}

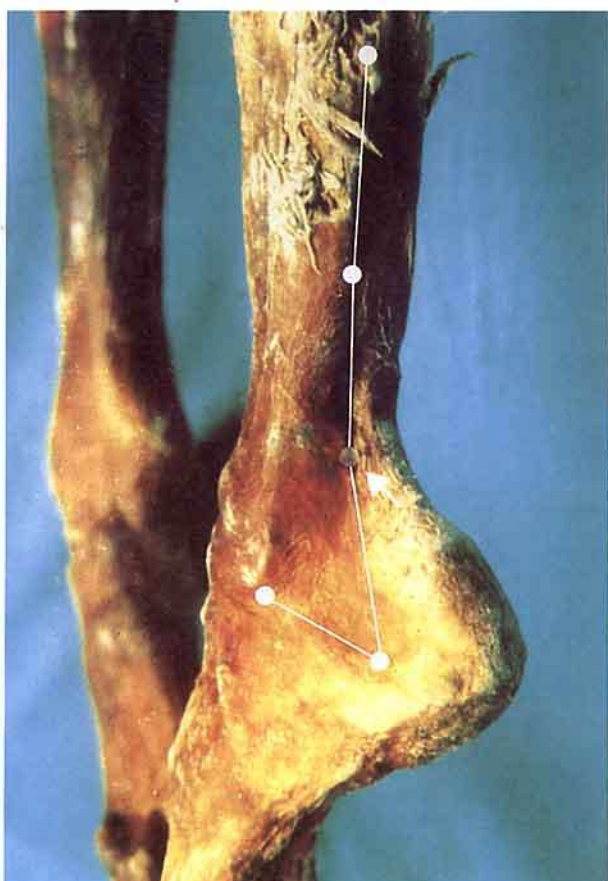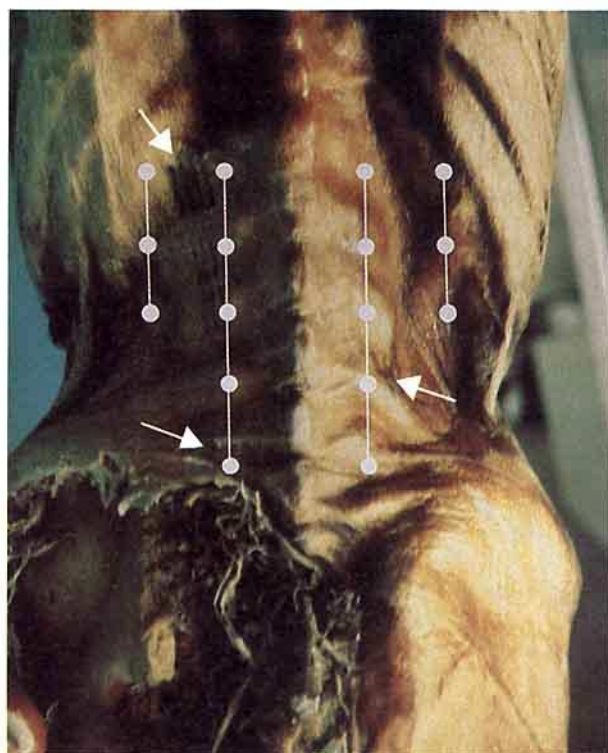


Figure 3: Examples of tattoos on the Tyrolean Iceman

Top, three groups of parallel lines running in longitudinal direction on the left side and one group on the right side of the back (arrows). The groups on the lower left back and on the right side of the spine are barely visible. Bottom, one of the two tattoo crosses found, located above and behind the left, lateral malleolus (arrow).

The course of the urinary-bladder acupuncture meridian and the location of urinary bladder point 60 (central transparent point in lower figure) are overlaid for comparison.

and the abdominal disorders, or as markers for application of acupressure or acupuncture to be applied by a non-medical person. The locations of the tattoos are similar to points used for specific disease states in the traditional Chinese and modern acupuncture treatment.

A treatment modality similar to acupuncture thus appears to have been in use long before its previously known period of use in the medical tradition of ancient China (c 1000 BC, see refs 11, 23). This raises the possibility of acupuncture having originated in the Eurasian continent at least 2000 years earlier than previously recognised.

We thank Dora Hsu and Philip Kilner for essential suggestions concerning the final version of the manuscript.

References

- Rudenko SI. Frozen tombs of Siberia. London: J M Dent & Sons, 1970.
- Allison MJ, Early mummies from coastal Peru and Chile. In: Spindler K, Wilfing H, Rastbichler-Zissernig E, zur Nedden D, Nothdurfter H, eds. *The man in the ice*, vol 3: Human mummies. Vienna, Austria: Springer Verlag, 1996: 125–29.
- Rolle R. Die skythenzeitlichen Mumienfunde von Pazyryk—Frostkonservierte Gräber aus dem Altaigebirge. In: Höpfl F, Platzer W, Spindler K, eds. *Der Mann im Eis*, vol 1. Innsbruck, Austria: Veröffentlichungen der Universität Innsbruck, 1992: 334–58.
- Höpfl F, Platzer W, Spindler K, eds. *Der Mann im Eis* Vol 1. Innsbruck, Austria: Veröffentlichungen der Universität Innsbruck, 1992.
- Seidler H, Bernhard W, Teschler-Nicola M, et al. Some anthropological aspects of the prehistoric Tyrolean Ice Man. *Science* 1992; **258**: 455–57.
- Spindler K. The man in the ice. The preserved body of the Neolithic man reveals the secrets of the Stone age. London: Weidenfeld and Nicolson, 1994.
- Capasso L. A preliminary report on the tattoos of the Val Senales mummy. *J Paleopathol* 1993; **5**: 173–82.
- Essentials of Chinese Acupuncture, compiled by Beijing, Shanghai and Nanjing College of TCM. Beijing: Foreign Languages Press, 1980.
- Bernhard W. Vergleichende Untersuchungen zur Anthropologie des Mannes vom Hauslabjoch. In: Höpfl F, Platzer W, Spindler K, eds. *Der Mann im Eis*. Vol 1. Innsbruck, Austria: Veröffentlichungen der Universität Innsbruck 1992: 163–87.
- Sjøvold T, Bernhard W, Gaber O, Künzel KH, Platzer W, Unterdorfer H. Verteilung und Größe der Tätowierungen am Eismann vom Hauslabjoch. In: Spindler K, Rastbichler-Zissernig E, Wilfing H, Zur Nedden D, Nothdurfter H, eds. *Der Mann im Eis*. Vol 2. Vienna, Austria: Springer Verlag, 1995: 279–86.
- Shanghai College of TCM. *Acupuncture, a comprehensive text*. (O'Connor J, Banský D transl and eds). Seattle: Eastlan, 1996.
- Wertsch G, Schrecke B, Küstner P. *Akupunkturatlas*. Schorndorf, Germany: WBV Biologisch-Medizinische Verlagsgesellschaft, 1996.
- Bahr F, Dorfer L, Suwanda S. Expert opinions on the correspondence of tattoo locations and acupuncture points in the Tyrolean Iceman, 1998.
- Dorfer L, Moser M, Spindler K, Bahr F, Egarter-Vigl E, Dohr G. 5200-year-old acupuncture in Central Europe? *Science* 1998; **282**: 242–43.
- Van der Velden E, Den Dulk L, Leenders H, et al. The decorated body of the man from Hauslabjoch. In: Spindler K, Rastbichler-Zissernig E, Wilfing H, Zur Nedden D, Nothdurfter H, eds. *Der Mann im Eis*. Vol 2. Vienna, Austria: Springer Verlag: 1995: 275–78.
- Capasso L. 5300 years ago, the Ice Man used natural laxatives and antibiotics. *Lancet* 1998; **352**: 9143.
- Zur Nedden D, Wicke K. The Similaun Mummy as observed from the viewpoint of radiological and CT data. In: Höpfl F, Platzer W, Spindler K, eds. *Der Mann im Eis*. Vol 1. Innsbruck, Austria: Veröffentlichungen der Universität Innsbruck, 1992: 131–48.
- Maciocia G. *The foundations of Chinese medicine a comprehensive text for acupuncturists and herbalists*. New York: Churchill Livingstone, 1989.
- Hasenöhr N. Ötzi wurde akupunktiert! *Medical Tribune* 1998; **47**: 10.
- Moser M, Dorfer L, Spindler K, et al. Are Ötzi's tattoos acupuncture? Skin markings on the Tyrolean Iceman may have been treatment for his ills. *Discovering Archaeology* 1999; **1**: 16–17.
- Aspöck H, Auer H, Picher O. *Trichuris trichiura* eggs in the Neolithic glacier mummy from the Alps. *Parasitol Today* 1996; **12**: 255–56.
- Oeggel K. Opening lecture of the Museum of Archeology, Bozen/Bolzano, Italy: 1998.
- Bahr F. *Einführung in die wissenschaftliche Akupunktur*. München: MMV Medizin, 1996.