

# Tissue-specific Characteristics and Requirements for Long-Term Scoliosis Rehabilitation: An ICSB Position Paper

Roger Elmer DC<sup>1</sup>, Mark Morningstar DC, PhD<sup>2</sup>, Clayton Stitzel DC<sup>3</sup>, Brian Dovorany DC<sup>4</sup>, Aatif Siddiqui, DC<sup>5</sup>

<sup>1</sup> Private practice of chiropractic, Las Vegas, NV; <sup>2</sup> Private practice of chiropractic, Grand Blanc, MI; <sup>3</sup> Private practice of chiropractic, Lititz PA; <sup>4</sup> Private practice of chiropractic, Green Bay, WI; <sup>5</sup> Private practice of chiropractic, New York, NY.

### ABSTRACT

**Objective:** To outline some of the tissue characteristics that must be dealt with in order to achieve sustainable corrections in the scoliotic spine on a theoretical basis

**Methods:** We conducted review of the PubMed and Index to Chiropractic Literature databases, as well as our own personal libraries

**Discussion:** All of the tissues of the spinal system, including nervous, ligament, muscle, and bone are discussed in detail, relating specifically to their involvement in the totality of scoliosis. None of these tissues respond to short term rehabilitation techniques in a corrective manner. Short term treatments may create plastic deformation forces that may be detrimental to long term outcomes.

**Conclusion:** Although short term treatments for scoliosis have resulted in positive outcomes, none of these changes have been supported by long-term follow-up studies. Scoliosis treatment involving chiropractic rehabilitation should focus on obtaining long term outcomes for skeletally immature patients, and avoid reporting only short term outcomes in both the adolescent and adult scoliosis populations.

**Key Words:** Chiropractic; Exercises; Posture; Rehabilitation; Scoliosis

### Introduction

Scoliosis is simply defined as a lateral spinal curvature above 10 degrees.<sup>1</sup> To expound upon this definition, it is important to identify the specific types of abnormalities and comorbidities often associated with scoliosis. In addition to the spine curvature itself, changes within the intervertebral discs, spinal ligament systems, spinal musculature, and the central nervous system itself, are some of the factors that may lead to the progression of the spinal curvature.

The purpose of this commentary is to discuss the adaptive changes and abnormalities within the spinal system that may lead to the development or progression of the scoliosis deformity. Central to this discussion are the specific characteristics of the involved tissues and their specific requirements for rehabilitative/structural change. We believe that these characteristics and rehabilitation requirements may

be discussed collectively in a way that fosters progressive discussion on the origins, progression factors, treatment methods, and treatment goals for non-surgical scoliosis therapies, especially as employed within the chiropractic profession. We focus not on the cellular characteristics of these tissues. This review is not meant to be an exhaustive review on the topic. Rather, this review will explore the clinical properties of these tissues and how clinicians may affect them in a positive manner.

As an organization, we felt it was important to provide our perspective on scoliosis rehabilitation within a chiropractic context. The International Chiropractic Scoliosis Board was formed to allow chiropractic doctors the opportunity for intra-professional communication on the very specific subject of

scoliosis. In our opinion, the available evidence on scoliosis and tissue characteristics seems to create a very straightforward path for treating patients with scoliosis. This paper serves to shed some light on this evidence, as well as our interpretation of it, and to provide our collective opinion as to the goals and treatment mechanisms most likely to result in long lasting positive treatment outcomes.

## Data Collection

In preparing this commentary, PubMed and Index to Chiropractic Literature searches were performed using the keywords “scoliosis,” “posture AND rehabilitation,” “neuromuscular rehabilitation,” and “neural control of posture.” We also reviewed textbooks from our own personal libraries. This compilation of data gave us the opportunity to review the basic characteristics of spinal tissues, as well as rehabilitation requirements necessary to make sustainable structural changes within the scoliotic spinal system.

## Discussion

### *White tissue:*

White tissue is so named because of its comparatively low blood supply. White tissue is made up of tropocollagen, a coiled protein that exhibits elastic properties and can change shape. Staggered arrays of tropocollagen molecules form fibrils, which arrange to form collagen fibers,<sup>2</sup> the macroscopic makeup of white tissue. White tissue includes ligaments, intervertebral discs, fascia, epimysium, perimysium, and the nervous system, etc. All of these fibers must be theoretically changed in order to achieve a sustained structural change to the spinal system. Spinal white tissue serves to minimize muscular requirements during static postures, while also providing increased spinal stability during dynamic postures and transient gravitational loads.<sup>3</sup> White tissue typically exhibits two basic clinical characteristics: elastic deformation, which can be subdivided into adaptive shortening and elongation, and plastic deformation.

Adaptive shortening occurs when the tissue has been shortened for a period of time and the tropocollagen coils change to adapt to the new position. Adaptive shortening does not require any energy or effort. Placing the tissue in a shortened position for a period of time causes it to coil upon itself. Reversing this phenomenon, however, requires energy. When attempting to affect structural changes to the body, associated tissue is invariably shortened to some degree. Adaptive shortening occurs through creep, a product of the tissue's viscoelastic properties.<sup>3</sup> White tissue is designed to automatically create this effect, in order to maintain positive stability.

White and Panjabi refer to this as viscoelastic stability,<sup>4</sup> where viscoelastic structures exhibit time-dependent properties. They state, “*It [viscoelastic structure] has a critical time period for a given load. Within this time period, the system is stable, and beyond it, it is unstable. Biologic structures are viscoelastic and therefore have time-dependent stability. Living bodies are much more complex. They are able to respond to unstable situations by altering the structure so as to re-create structural stability [our emphasis].*”<sup>4</sup> This has incredibly

important ramifications for scoliotic spinal deformity and goals for its treatment. This will be discussed later in this paper.

Adaptive elongation occurs when the coiled tropocollagen unwinds in response to a specific tissue load and loading rate. Gautieri et al<sup>5</sup> studied the elastic properties of tropocollagen strands and found that the deformation rate controls the quality of tropocollagen unwinding. They found that at low loading rates, complete unwinding takes place at 10-20% strain. At intermediate rates tropocollagen uncoils at a linear rate up to 35% strain, while high loading rates do not cause the tropocollagen to uncoil at all.<sup>5</sup> This has important clinical implications since white tissue deformation is necessary for sustained structural changes. Adaptive elongation is a healthy, non-pathological change.

Ligaments are retaining structures and their properties are a product of their individual and collective (microscopic and macroscopic) make up. One important trait of white tissue is its non-linear load-displacement curve, which is divided into three zones: a neutral zone, elastic zone, and plastic zone. The neutral and elastic zones combine to form the physiologic zone.<sup>4</sup> Within this physiologic zone, white tissue typically displays the normal elastic properties of adaptive shortening and lengthening.

For example, the total range of physiologic lengthening and shortening of the ligamentum flavum is 3% compression to 26% tension. The barrier characteristics of this ligament begin to activate only when stressed beyond the physiologic range.<sup>4,6</sup> Since the presence of scoliosis may alter the normal total physiologic range of deformation for the spinal ligaments, it is important to understand these characteristics within the confines of viscoelastic stability and gravity.

Plastic deformation is a pathological change in white tissue. Stretching too long or too hard causes an uneven change in the fibrous makeup, like over stretching a spring and causing distorted unraveling of the coil (see Figure 1). The unraveling creates a weakening of the tissue in this area. Although this does lengthen the tissue, it is now less able to perform its duties as a stabilizing structure. Plastic deformation is pathological in nature and has short term and long term orthopedic and neurological ramifications. Plastic deformation causes joint laxity, which causes it to be more susceptible to injury in the short term. In the long term, it leads to degenerative processes that are initiated to stabilize the joint and protect the corresponding neurological structures.

Neurologically, joint instability leads to desensitization of the related mechanoreceptors. As a result, somatosensory afferents to the brainstem and cerebellum are inhibited. This feedback is needed to control the local type I musculature at that corresponding level, thus reducing the information from which static and dynamic postural calculations are made. It also eliminates the protective reflexes that monitor that segmental level.<sup>7</sup>

In the long term, the information from those mechanoreceptors stimulates the related areas in the ipsilateral cerebellum, and subsequently the corresponding areas in the contralateral cortex. The long term loss of these mechanoreceptor afferents

may lead to transneuronal degeneration of the first order neurons. This may lead to early brain degeneration in those areas.

In light of the above information, procedures resulting in plastic deformation may not be appropriate in cases of scoliosis, as it creates new instabilities that were not previously present. It also results in an unhealthy tissue response under load as compared to healthy tissue.

#### *Red Tissue*

Red tissue is so named because of its myoglobin concentration. Red tissue is composed of the extrafusal and intrafusal muscle fiber systems. There are two basic kinds of muscle fibers: slow twitch (type 1), and fast twitch (type 2) muscle fibers.

Fast twitch muscle fibers are voluntary and are mediated via the anterior horn. Traditional exercise programs work primarily with these fibers. Fast twitch fibers can generate large forces, but fatigue very rapidly.<sup>8</sup> Slow twitch muscle fibers are involuntary and function within the autonomic nervous system. These fibers control the posture and movement of the shunt stabilizers, which are controlled sub-cortically. These muscle fibers do not generate large forces, however, they are very resistant to fatigue, and hence make up the majority of spinal muscle fibers.<sup>8</sup>

Any intended change to this system must be involuntary/autonomic and should target the slow twitch muscle fibers. Therefore, the types of prescribed exercises must target/activate slow twitch muscle fibers. Isometric exercises, as an example, activate these involuntary fibers. Isometric exercises work because they create a specific demand that activates slow twitch fibers. The afferent and efferent nerve fibers connected to slow twitch fibers are autonomic and are operated sub-cortically.

Traditional voluntary exercise systems fail in this respect, as they typically target fast twitch fibers. Posture is not primarily under voluntary control. Activating the slow twitch muscle fibers to change their morphology, strength and endurance may be the preferred way to make lasting change morphologically and functionally to the postural system. Changing strength, shape, and endurance takes time and numerous repetitions when working with the slow twitch muscle fiber system.

Surface EMG studies by Gaudreault et al<sup>9</sup> demonstrated that patients with scoliosis have a faster paraspinal muscle fatigue than control subjects. However, this is only observed at levels below the apex of the scoliosis. There is a higher percentage of concave slow twitch muscle fibers compared to that on the convex side of the scoliosis.<sup>10</sup> The fast twitch muscle fiber density is larger in the concavity paraspinals compared to the paraspinals on the convexity.

This density is increased compared to non-scoliotics.<sup>10</sup> Another EMG study by Tsai et al<sup>11</sup> found that adolescent idiopathic scoliosis patients with larger curves (20 to 50 degrees) tended to recruit paraspinal muscles of the concave

side of the scoliosis, with additional recruitment of the concave thoracic paraspinals. This is very important as it demonstrates the negative impact of performing repetitive lumbar and thoracic extension movements, such as roman chair exercises, swimming, gymnastics, and ballet, since recruitment of the concave paraspinal muscles may further increase the rotational displacement of the scoliosis, since these curves often display abnormal coupled motion patterns.<sup>12</sup> Modi et al found that adolescents who play volleyball have a significantly higher incidence of spinal curves, possibly due to the repetitive nature of thoracic extension movements.<sup>13</sup>

The paraspinal muscles in adolescents with idiopathic scoliosis may also undergo a transition from slow twitch to fast twitch muscle fibers as a consequence of bracing treatment.<sup>14</sup> This transformation is observed in the concave paraspinals. This also has implications for treatment since bracing causes a shift in the predominant postural afferentation from a more constant feedback to one based on rapid, intermittent contractile feedback.

Ge et al found that vertebral fixation that creates paraspinal lengthening decreases the activity of paraspinal muscle spindle afferents, thus limiting the proprioceptive feedback of the muscle.<sup>15</sup> The ability of the paraspinal muscles to provide accurate and timely proprioceptive information to the cerebellum is vital to maintaining a normal posture relative to gravity. Therefore, clinicians should carefully consider the value of rapidly stretching the paraspinal musculature in order to achieve a short-term scoliosis correction, as this may further alter the proprioceptive feedback system within the paraspinal muscles.

Future application of the fiber type changes seen on the concavity and convexity of the scoliosis curvature may have significant implications. Since these fiber changes are the result of neurological adaptation and functional recruitment, rather than a consequence of purely genetic expression, could lead to the development of a predictive model based on various high risk lifestyle activities (i.e. swimming, ballet, etc.) to assess curve progression using the current observation-based management strategy.

#### *Neural Tissue*

The nervous system includes the brain, brain stem, cerebellum, spinal cord, peripheral nerves and receptors of the nervous system. Mechanical tension, central pattern generators (hard-wired firing patterns), neural sensitivity and acuity, and vestibular patterning must all be changed in order to help maintain structural change. Often, retraining aberrant sensory and motor patterns can be more difficult than the soft tissue changes (white and red tissue) themselves.

Optimized neurological rehabilitation is first accomplished by giving the nervous system three vital components it needs to function: fuel, oxygen, and activation. Activation of the neuron is necessary so that the cell will go through reconstruction, repair, and maintenance. This process happens if the cell is either excited or inhibited. Without activation, the cell will degrade and die. Working with the nervous system requires balance; too little stimulation may cause cell death or result in failure to change.

Too much stimulation may result in fatigue and death. Knowing the training limits of the nervous system is extremely important. When we create a training response, we force the nervous system to adapt and change. The therapeutic process to create change in the nervous system is called *evoked plasticity*. Evoked plasticity is accomplished by 1) change in the internal structure of the cell, and 2) it's metabolic capacity. There is also an external change in the blood vascular supportive structure and efficiency.

The fuel component is the one consisting of proper nutrient and water intake. Nutrients known for improving neurological function include B vitamins, and amino acids. There is a significant correlation between deficient intake of pyridoxine (B6), folate (B9) and cobalamin (B12) and the development of neurodegenerative disorders.<sup>16</sup> Although the direct link between vitamin B6 and neurological function is tenuous,<sup>17</sup> it is involved in more than 50 metabolic reactions as a coenzyme, mainly during amino acid and fatty acid metabolism.<sup>18,19</sup>

Therefore, its intake is essential for normal nutrient uptake and utilization by the central nervous system. This nutrient is found mainly in potatoes, bananas, red meat, poultry, and fish.<sup>20</sup> In supplement form, the most biologically active form of B6 is pyridoxal 5' phosphate (P5P), with dosages ranging from 10-200mg per day.<sup>20</sup> Methylcobalamin, the coenzyme form of B12,<sup>20</sup> is intimately involved in nervous system function. Vitamin B12 is vital for amino acid metabolism, including glycine and serine, which are important neurotransmitters necessary for cognition and limbic function.<sup>21</sup> Food sources of vitamin B12 consist mainly of animal-based protein sources. Supplementation of vitamin B12 to treat deficiency may be as high as 3000-5000 µg per week orally.<sup>22</sup>

Intramuscular injections of 1000 µg every four days to two weeks may also be used.<sup>20</sup> Another B vitamin with significant neurological importance is folate, or B9. Folate deficiency has been linked to ataxia, migraines, peripheral neuropathy, autism, and depression.<sup>20</sup> The active form of folate is 5-methyltetrahydrofolate (5-MTHF), and should be taken whenever possible (versus other common forms found in dietary supplements) since it is estimated that 5-15% of the general population have a genetic defect of the enzyme responsible for the conversion of 5,10-methylenetetrahydrofolate into 5-methyltetrahydrofolate.<sup>23</sup> The best food sources of vitamin B9 include dark green leafy vegetables and citrus fruits.<sup>20</sup>

As mentioned above, B vitamin intake is important for the uptake and utilization of amino acids and lipids. Amino acids that are particularly beneficial for neurological function include L-tryptophan, L-tyrosine, and serine. L-tryptophan is an essential amino acid found in chickpeas, chocolate, bananas, poultry, sunflower seeds, pumpkin seeds, peanuts, and dairy products.<sup>20</sup> It is a precursor to the neurotransmitters serotonin and melatonin. In supplement form its first generation metabolite, 5-hydroxytryptophan (5-HTP), is often given due to its ability to cross the blood brain barrier.<sup>24</sup>

Once converted into serotonin, serotonin regulates many central and peripheral processes, including gut motility,<sup>25</sup>

learning and memory modulation,<sup>26</sup> food intake and hunger,<sup>27</sup> and regulating bone mass.<sup>28</sup> Altered levels of plasma serotonin have been associated with low bone density<sup>29</sup> and could be a future target for patients with scoliosis and concurrent bone density loss.<sup>30</sup> The conversion pathway of serotonin into melatonin is also an important neurological process to consider in idiopathic scoliosis, as melatonin deficiency<sup>31-34</sup> and melatonin signaling dysfunction<sup>35-39</sup> have been implicated in several studies.

Normal neuromotor control is dependent upon properly functioning serotonergic pathways, both centrally and peripherally. The spinal cord receives strong serotonergic innervation from axons originating in the midbrain and medullary raphe nuclei, which project into lamina I and II of the dorsal horn, lamina IX of the ventral horn, and the intermediolateral cell column.<sup>26</sup> The raphe nuclei are significant modulators of postural activity, receiving input from the substantia nigra, superior vestibular nucleus, locus ceruleus, cortex, and the nucleus tractus solitarius.<sup>26</sup>

As more and more research on the nutrient aspects of scoliosis becomes available, it is probable that the focus of early scoliosis intervention may become to identify these key neuroendocrine abnormalities and address them before the spinal curvature becomes a permanent postural deformity.

Within the brain itself, efferent cortical fibers from layer V of the cerebral cortex function as the main cortical input for spontaneous postural correction.<sup>40</sup> While most postural control studies focus on the cerebellum, brainstem, and spinal cord, the role of the frontal cortex in postural control has not been explored. The large pyramidal neurons on layer V project mainly to the basal ganglia, brainstem, and spinal cord. This layer has an oscillation frequency of 10-15 Hz.<sup>41</sup> Although reflexive postural control is mainly mediated by the cerebellum, brainstem, and spinal cord, layer V of the motor cortex does at least provide a supplementary role.<sup>40</sup>

Other authors give it more recognition, considering it is the main inhibitory influence on postural control necessary to inhibit antagonistic muscles, initiate shunt stabilization, and direct activation of agonists, thus preventing dystonia.<sup>42</sup>

Restoring the sagittal spinal curves significantly reduces the axial traction of the pons-cord tract (spinal cord to Pons).<sup>43</sup> This tension reduces conductivity and blood flow within these structures. The spinal curve system is a series of lever arms that work as units. Muscles that support these lever arms are situated according to their origin and insertion to those lever arms, as shown in Figure 2. Once the curves/lever systems are created by changing the soft tissues associated with them, the nervous system must then be rewired (re-engrammed) to run these lever arms and teach them to pivot about their altered pivot points.

Exercises that elicit central pattern generation must be used so that the nervous system reflexively uses the pivot points and spinal lever arms more efficiently via neuromuscular control. Temporary structural changes are common within a variety of chiropractic technique systems. However, unless the correct central pattern generators are in place to utilize a corrected spinal structure, "old" movement patterns and habits will

cause the spinal structure to adapt back to the old function. Corrected central pattern generators will allow for optimized neuromuscular function relative to corrected spinal structure, and thereby promote longer lasting spinal changes. Therefore, in order to create a spinal structural change that will last, and that is maintainable by the patient, all three tissues must be changed.

### *Bone Tissue*

Although not often viewed as a tissue, bone is nonetheless a tissue that displays certain characteristics in the scoliotic spine. Once a spine curvature is initiated, the vertebrae will remodel in their shape, via Heuter-Volkman, and in trabecular orientation and density, via Wolff's Law. For example, Birchall et al<sup>44</sup> found that 45% of the rotational displacement found in scoliosis was due to plastic deformation in the vertebral body.

While the cause of idiopathic scoliosis is still largely unknown and debated, it is without doubt that in order to achieve the best possible long-term outcome for juveniles and adolescents with idiopathic scoliosis, treatment that focuses on reversing abnormal gravitational loading on the spine must be initiated before the closing of the triradiate cartilage, before the onset of menarche, and before the peak growth spurt begins.<sup>45</sup> This is usually around a Risser 0 or 1.

Asymmetrical vertebral loading caused by scoliosis causes both osteoblastic endplate activity in the concavity and osteolytic processes in the convexity.<sup>46</sup> This asymmetrical loading causes accelerated disc degeneration, which may lead to degenerative lumbar scoliosis in adult patients.<sup>47</sup> This same asymmetrical gravitational loading is what Hawes et al<sup>48</sup> refer to as the vicious cycle.

There is no way, according to them, to reverse a scoliosis unless this asymmetrical loading is completely corrected and normalized. In order to make a sustained change and alter the asymmetrical spinal loading, sufficient forces must be applied to the scoliosis for an extended period of time. This is illustrated in a study by Stokes et al where vertebral loading over a 24-hour period of time produced twice as much corrective remodeling.<sup>45</sup>

Children with idiopathic scoliosis also often have low bone mineral density at a much higher rate than non-scoliotic children.<sup>49,50</sup> This may be due to decreased osteogenic differentiation by mesenchymal stem cells often found in patients with adolescent idiopathic scoliosis.<sup>51</sup> While this may seem logical considering the abnormal spinal loading created by the scoliosis, osteopenia in patients with adolescent idiopathic scoliosis is widespread, and not confined to only the spine, pelvis or hips.<sup>52</sup> This suggests that this is more of a systemic disorder compared to a secondary effect.

Studies have failed thus far to correlate low bone density and severity of the scoliosis.<sup>53</sup> However, patients with adolescent idiopathic scoliosis with low bone mineral density were more likely to have a more severe scoliosis into adulthood than those with normal bone density.<sup>54</sup> Low bone density is also strongly associated with vertebral

wedging and height loss in adults.<sup>55</sup> However, Pappou et al<sup>56</sup> found that adults with degenerative lumbar scoliosis had a significantly higher bone density in the lumbar spine, but significantly lower bone density in the hip compared with non-scoliotic controls. Again, curve magnitude did not correlate to the degree of osteopenia.

Low bone density appears to thus be a key factor in idiopathic scoliosis, whether it is a comorbid effect or contributing cause. Either way, addressing bone mineral density loss as early as possible seems to be critical in achieving long-term curvature reduction. There is evidence to suggest that the reason for this low bone density may be due to decreased circulating leptin,<sup>57,58</sup> abnormal leptin signaling,<sup>59</sup> or central leptin resistance.<sup>60</sup> Leptin, a hormone much higher in females than males, may play a role in female pubertal development, onset of menarche, and physical growth and development.<sup>61,62</sup> Leptin also acts directly on physical growth through chondrocyte leptin receptors.<sup>63</sup>

In addition to viewing the skeletal system as a support structure, looking at bone as an endocrine organ may give scoliosis researchers and clinicians a new perspective on bone's response to loading, its reactions to hormonal signaling, and developing targeted therapies for earlier scoliosis intervention.

### **Making Structural Corrections**

The universe is governed by law. The order that we experience it is a result of consistency of operation within the world of physics and physiology. Gravity is constant and can only be overcome by using other laws like those used in the field of Aerodynamics. Any attempt to overcome these basic effects takes cleverly applied principles. These principles must be followed in order to both change a spine and have it become stable enough that the patients can care for themselves without the doctor's oversight.

Scoliosis may be a primary neurological problem with orthopedic ramifications.<sup>64</sup> Loss of the sagittal, physiologic spinal curves causes axial stretching of the spinal cord (pons-cord tract), thereby decreasing cord thickness (through Poisson's Effect), which causes a decrease in conductivity within the cord, and even more deleteriously, decreasing blood flow within the cord.<sup>65-67</sup> The nervous system responds by creating a lateral buckling & rotation that lessens this axial tension at the expense of lateral spinal distortion in the coronal dimension.

The word scoliosis is not reflective of the true structure of deformity it represents. The term implies a one dimensional distortion. Most of the time, coronal and lateral radiographs are taken, and independently analyzed. Therefore, it is a two dimensional analysis of a three dimensional deformity.

The structural distortion of scoliosis is a three dimensional deformation, perhaps starting with a sagittal plane variance from the true primary and secondary curve system, which creates stretch on the pons-cord tract<sup>43</sup> creating a compensation to buckling and rotation, to relieve the cord tethering.

Any attempt to reduce a scoliosis, stabilize it, and prevent it from regressing, must begin with sagittal plane restoration to relieve the cord tension and restore structural/ biomechanical integrity so that when changes are made in the coronal plane they don't 1) increase tension on the spinal cord & 2) depends only upon the neuromuscular system for its structural support.

Taking the published works of Harrison et al<sup>65-67</sup> and Chu et al<sup>68</sup> into account, the spinal cord may become stretched due to axial tension originating cranially or caudally. This may be due to losing the normal sagittal cervical and/or lumbar lordoses, placing increased uniaxial tension on the spinal cord,<sup>43</sup> thus resulting in a coil-down effect of the surrounding vertebral column. It may also be a consequence of losing the normal primary thoracic lordosis,<sup>69</sup> which is comprised of the two longest lever arms within the spinal system. Since longer lever arms are more likely to buckle or breakdown than shorter lever arms, it seems logical that any additional compressive stress on these two longer lever arms may cause them to buckle into two shorter lever arms to maintain postural equilibrium.<sup>12</sup>

However, this concept has not been definitively studied. These studies support the concept that scoliosis may be a biomechanical compensation for anatomical or functional tethering of the spinal cord in one or more anatomic regions. Even newer bracing technologies have been developed to primarily affect the position of the sagittal spine to positively affect the scoliosis in a three dimensional capacity.<sup>70</sup>

Attempts to straighten a scoliosis without accounting for these changes will wind up creating a new harsh compensatory response to deal with the increase in cord tension. Therefore Cobb angle cannot be an initial goal, and may not be relevant to biomechanical evaluation and progress.<sup>71</sup> Restoring the sagittal curves, while also maintaining three dimensional head position, both spatially and in relation to the torso and pelvis, should be the primary goals.

There are 4 basic tissues that must be changed in order for a scoliosis to become stable in a way that the patient may sustain the change without help from the doctor. As we discussed, these are white tissue, red tissue, bone, and neural tissue. Those have already been described in this paper. Now we will discuss them in relation to exercise-based scoliosis treatment.

When working with white tissue it is important to remember that it responds slowly and must be held in the desired position and length over time. This is reflected in the basic definition of Work (where work equals Force X Time). Any attempt to shortcut this will either a) cause failure of the tissue (from rapid loading), thus weakening it as a retaining structure and leaving the involved joint thereafter unstable (neurologically discussed previously);<sup>72</sup> or b) may cause a progression of the scoliosis by inadvertently engaging the elastic properties of the white tissue (inanimate response), causing it to "rebound" under the governance of the red tissue's static and dynamic stretch reflexes (animate response).<sup>73</sup>

Rehabilitation of the intervertebral discs is important to sagittal plane restoration, especially since the cervical discs only comprise the anterior portion of the endplate surface area.<sup>74</sup> In scoliosis, it is also important in supporting and

maintaining the shape of the coronal plane structurally. This takes considerable molding and stability training to support of the new shape while hydrostatic pressure is improved via imbibition, which also takes a considerable amount of time. Meir et al measured the intradiscal pressure in scoliotic discs and found it to be over 300% greater than in normal discs, even in the absence of muscle loading.<sup>75</sup> Stokes suggested that this asymmetrical intradiscal pressure would have to be reversed in order to prevent progressive disc pathology.<sup>76</sup>

To us, the only viable non-surgical means of reversing this asymmetry of disc pressure consistently enough is by spinal orthosis. However, the orthosis must demonstrate the ability to do this via in-brace radiography. This may require approximately a >50% in-brace Cobb angle correction to approach this goal.<sup>77</sup> To date, there is no non-surgical, non-bracing method that has demonstrated the ability to reverse this asymmetrical disc loading and pressure.

Currently, the minimum recommended in-brace Cobb angle correction is about an average of 27%.<sup>78</sup> This is likely not enough to reverse this disc deformity and degeneration. The average level of in-brace correction using the Boston bracing protocols may be as high as 44%,<sup>79</sup> but it is unknown how many Boston brace patients achieve this level of in-brace correction.

Newer bracing concepts should be adopted in the United States that reflect this goal. Morningstar was able to accomplish 50% or greater in-brace correction in four patients, but only when TLSO bracing was combined with an external weighting system.<sup>80</sup> However, only three month results were reported for those patients.

In the continuum of exercise-based scoliosis research, the focus of non-surgical therapies should expand to include identification of any neuroendocrine or metabolic abnormalities discussed in the recent literature. Testing for these imbalances is already commercially available in many respects, and researchers are currently testing newer methods of predicting scoliosis.<sup>81</sup> This will have tremendous impact on the rehabilitation of scoliosis, and may ultimately diminish the current emphasis placed on the outdated Cobb angle assessment of scoliosis.<sup>71</sup>

## Summary

In the past, strategies for dealing with and attempting to correct scoliosis have not reflected consistent long term, predictable and sustainable results. This is due to a lack of clear understanding of what it is, what tissues must change and the principles governing these tissues and their change. Therefore any theories, principles, or concepts used in devising treatment protocols have not yielded true corrective results. The key to making structural changes is changing the connective tissues enough so that the patient can maintain the correction on their own without the help of a doctor.

The chief characteristic of tropocollagen is that of spring elasticity. When that elasticity is aggressively stretched, it has the potential of springing back aggressively. A rapid Cobb change in a short time 1) Does not allow sufficient adaptation in tropocollagen fibers, 2) is not sufficient to create muscular stabilization of the white tissue deformations, which may lead

to curvature progression under continued gravitational loading, 3) is not sufficient to alter neuromotor control of the postural system, which requires at least six weeks of consistent training,<sup>82,83</sup> and 4) may not be sufficient to allow lifestyle/postural modifications to become habitual.

Changing red tissue characteristics (morphology strength, flexibility, contractility, and endurance), especially slow twitch fibers, is much more difficult than working with fast twitch fibers. More time is often needed. The most difficult characteristic to alter is endurance, which requires time and repetition. Ignoring the time-dependent nature of soft tissue rehabilitation assures that the muscular system will provide a suboptimal response to reflexive, subcortical adaptations to gravitational loading and postural changes.

Changes that must take place to the nervous system include: 1) elimination of adverse mechanical tension within the central nervous system, 2) new central pattern generation to control the corrected spinal structure efficiently (re-engramming), and 3) proprioceptive retraining to reinforce correct neuromuscular responses and maintain states of both static and dynamic postural equilibrium.

However, before treatments based upon these goals are initiated, it is imperative that clinicians look at the neuroendocrine and metabolic characteristics of each patient, since ongoing hormonal and neurotransmitter imbalances may limit the effectiveness of scoliosis rehabilitation, and may promote scoliosis progression despite rehabilitative intervention.

The idea that scoliosis is a response to adverse mechanical tension in the CNS, and therefore compensatory to that tension, is not new. This concept can be found within the more accepted etiological models of scoliosis.<sup>84</sup> This is also supported by the observation that progressive scoliosis is much more likely to be associated with cervical kyphosis.<sup>85,86</sup> Any attempt to reduce Cobb angle before the restoration of the sagittal plane & therefore reduce adverse mechanical tension of the CNS will actually increase cord tension and may precipitate a detrimental compensatory action to attempt to relieve that tension.

This is also suggested by Kepler et al<sup>87</sup> who conclude that long-term scoliosis outcomes are compromised if the sagittal profile deteriorates. Scoliosis surgery is often aimed at attacking the compensation and not fixing the characteristics discussed here, leaving the system with a worsened intrinsic environment and with very few options for which to compensate.

A neural engram requires 300-350 repetitions to become permanently wired within the nervous system. To override an old faulty engram and replace it with a new optimal engram, it takes 3500-5000 repetitions without re-engaging the old engram. Importantly, this must not be done into neural fatigue. Time is vital to allow this process to be fulfilled.

Exercises that are rehabilitative in nature often isolate one area compared to another. These areas must be integrated into the entire system and decrease afferent threshold and improve proprioceptive communication. Proprioceptive integration allows for this process and takes time for all the components

to be connected and controlled. To sidestep this process means the system will not work in an integrated fashion, the way it was wired to function.

Finally the system must be optimally reoriented to gravity, giving the subcortical system that controls it a chance to appropriately respond to gravity and become more efficient at directing this response. This requires a lot of repetition independently and intermittently to operate in conjunction with the cortically controlled (volitional) movement centers.

External body weighting allows this process to happen subcortically to make the changes in each of the planes, which becomes the means of retaining the desired results in three dimensions relative to gravity. Without it, or only short term use of it, will not produce predictable controlled stabilization and retention of these changes by the patient, independent of the doctor.

## References

1. Lonstein JE, Winter RB, Bradford DS, Ogilvie JW. Moe's Textbook of Scoliosis and Other Deformities, 3<sup>rd</sup> Ed. 1995 Saunders
2. Buehler MJ. Nature designs tough collagen: explaining the nanostructure of collagen fibrils. *Proc Natl Acad Sci* 2006;33:12285-12290
3. Troyer KL, Puttlitz CM. Nonlinear viscoelasticity plays an essential role in the functional behavior of spinal ligaments. *J Biomech.* 2012 Feb 23;45(4):684-91.
4. White AA, Panjabi MM. *Clinical Biomechanics of the Spine*, 2<sup>nd</sup> Ed. 1990 Lippincott Williams & Wilkins, Philadelphia.
5. Gautieri A, Buehler MJ, Redaelli A. Deformation rate controls elasticity and unfolding pathway of single tropocollagen molecules. *J Mech Behav Biomed Mater* 2009;2:130-137.
6. Purslow PP, Wess TJ, Hukins DWL. Collagen orientation and molecular spacing during creep and stress-relaxation in soft connective tissues. *J Exp Biol* 1998;201:135-142.
7. Solomonow M, Bing-He Zhou EE, Baratta RV, Lu Y, Harris M. 1999 Volvo Award Winner in Biomechanical Studies- Biomechanics of Increased Exposure to Lumbar Injury Caused by Cyclic Loading: Part 1. Loss of reflexive Muscular Stabilization. *Spine* 1999;24:2426-34
8. Ijkema-Paassen J, Gramsbergen A. Development of postural muscles and their innervation. *Neural Plasticity* 2005;12:141-151.
9. Gaudreault N, Arsenault AB, Lariviere C, DeSerres SJ, Rivard CH. Assessment of the paraspinal muscles of subjects presenting an idiopathic scoliosis: an EMG pilot study. *BMC Musculoskelet Disord* 2005, 6:14.
10. Mannion AF, Meier M, Grob D, Muntener M: Paraspinal muscle fibre type alterations associated with scoliosis: An old problem revisited with new evidence. *Eur Spine J* 1998,7(4):289-293.


11. Tsai YT, Leong CP, Huang YC, Kuo SH, Wang HC, Yeh HC, Lau YC. The electromyographic responses of paraspinal muscles during isokinetic exercise in adolescents with idiopathic scoliosis with a Cobb's angle less than fifty degrees. *Chang Gung Med J* 2010;33:540-50.
12. Morningstar MW. Scoliosis I. Postgraduate seminar course in spinal biomechanics and scoliosis pathomechanics. 2012 Pettibon Institute.
13. Modi H, Srinivasalu S, Mehta SS, Yang JH, Song HR, Suh SW. Muscle Imbalance in Volleyball Players Initiates Scoliosis in Immature Spines: A Screening Analysis. *Asian Spine J* 2008;2:38-43.
14. Meier MP, Klein MP, Krebs D, Grob D, Müntener M. Fiber transformations in multifidus muscle of young patients with idiopathic scoliosis. *Spine* 1997;15:22:2357-64.
15. Ge W, Long CR, Pickar JG. Vertebral position alters paraspinal muscle spindle responsiveness in the feline spine: effect of positioning duration. *J Physiol* 2005;569.2:655-665.
16. Nachum-Biala Y, Troen AM. B-vitamins for neuroprotection: narrowing the evidence gap. *Biofactors* 2012;38:145-50.
17. Malouf R, Grimley Evans J. The effect of vitamin B6 on cognition. *Cochrane Database Syst Rev*. 2003;(4):CD004393.
18. Mueller JF. Vitamin B6 in fat metabolism. *Vitam Horm* 1964;22:287-796.
19. Mueller JF, Iacono JM. Effect of desoxypridoxine-induced vitamin B6 deficiency on polyunsaturated fatty acid metabolism in human beings. *Am J Clin Nutr* 1963;12:358-367.
20. Gaby AR. *Nutritional Medicine*. 2011 Fritz Perlberg Publishing. Concord, NH.
21. Yudkoff M. Disorders of Amino Acid Metabolism, pg 667-684. In: Siegel GJ, Albers RW, Brady ST, Price DL (editors). *Basic Neurochemistry: Molecular, Cellular, and Medical Aspects*, 7th Ed. 2006 Elsevier Academic Press, Burlington, MA.
22. Andres E, Kurtz JE, Perrin AE, Maloisel F, Demangeat C, Goichot B, Schlienger JL. Oral cobalamin therapy for the treatment of patients with food-cobalamin malabsorption. *Am J Med* 2001;111:126-129.
23. Molloy AM, Daly S, Mills JL, Kirke PN, Whitehead AS, Ramsbottom D, Conley MR, Weir DG, Scott JM. Thermolabile variant of 5,10-methylenetetrahydrofolate reductase associated with low red-cell folates: implications for folate intake recommendations. *Lancet* 1997;349:1591-1593.
24. Hardebo JE, Owman C. Barrier mechanisms for neurotransmitter monoamines and their precursors at the blood-brain interface. *Ann Neurol* 1980;8: 1-31.
25. Berger M, Gray JA, Roth BL. The expanded biology of serotonin. *Annu Rev Med* 2009;60:355-66.
26. Hensler JG. Serotonin. In: Siegel GJ, Albers RW, Brady ST, Price DL (editors). *Basic Neurochemistry: Molecular, Cellular, and Medical Aspects*, 7th Ed. 2006 Elsevier Academic Press, Burlington, MA.
27. Leibowitz SF. The role of serotonin in eating disorders. *Drugs* 1990;39 Suppl 3: 33-48.
28. Frost M, Andersen T, Gossiel F, Hansen S, Bollerslev J, Van Hul W, Eastell R, Kassem M, Brixen K. Levels of serotonin, sclerostin, bone turnover markers as well as bone density and microarchitecture in patients with high bone mass phenotype due to a mutation in Lrp5. *J Bone Miner Res* 2011; 26: 1721-8.
29. Mödder UI, Achenbach SJ, Amin S, Riggs BL, Melton LJ 3rd, Khosla S. Relation of serum serotonin levels to bone density and structural parameters in women. *J Bone Miner Res* 2010; 25: 415-22.
30. Yadav VK, Balaji S, Suresh PS, Liu XS, Lu X, Li Z, Guo XE, Mann JJ, Balapure AK, Gershon MD, Medhamurthy R, Vidal M, Karsenty G, Ducey P.
31. Kono H, Machida M, Saito M, Nishiwaki Y, Kato H, Hosogane N, Chiba K, Miyamoto T, Matsumoto M, Toyama Y. Mechanism of osteoporosis in adolescent idiopathic scoliosis: experimental scoliosis in pinealectomized chickens. *J Pineal Res*. 2011;51:387-93.
32. Girardo M, Bettini N, Dema E, Cervellati S. The role of melatonin in the pathogenesis of adolescent idiopathic scoliosis (AIS). *Eur Spine J*. 2011;20 Suppl 1:S68-74.
33. Machida M, Dubousset J, Yamada T, Kimura J. Serum melatonin levels in adolescent idiopathic scoliosis prediction and prevention for curve progression--a prospective study. *J Pineal Res*. 2009 Apr;46(3):344-8.
34. Machida M, Saito M, Dubousset J, Yamada T, Kimura J, Shibasaki K. Pathological mechanism of idiopathic scoliosis: experimental scoliosis in pinealectomized rats. *Eur Spine J*. 2005;14:843-8.
35. Moreau A, Wang DS, Forget S, Azeddine B, Angeloni D, Frascini F, Labelle H, Poitras B, Rivard CH, Grimard G. Melatonin signaling dysfunction in adolescent idiopathic scoliosis. *Spine* 2004;29:1772-81.
36. Letellier K, Azeddine B, Parent S, Labelle H, Rompré PH, Moreau A, Moldovan F. Estrogen cross-talk with the melatonin signaling pathway in human osteoblasts derived from adolescent idiopathic scoliosis patients. *J Pineal Res*. 2008;45:383-93.
37. Azeddine B, Letellier K, Wang da S, Moldovan F, Moreau A. Molecular determinants of melatonin signaling dysfunction in adolescent idiopathic scoliosis. *Clin Orthop Relat Res*. 2007;462:45-52.
38. Man GC, Wong JH, Wang WW, Sun GQ, Yeung BH, Ng TB, Lee SK, Ng BK, Qiu Y, Cheng JC. Abnormal melatonin receptor 1B expression in osteoblasts from girls with adolescent idiopathic scoliosis. *J Pineal Res*. 2011;50:395-402.
39. Man GC, Wang WW, Yeung BH, Lee SK, Ng BK, Hung WY, Wong JH, Ng TB, Qiu Y, Cheng JC. Abnormal proliferation and differentiation of osteoblasts from girls with adolescent idiopathic scoliosis to melatonin. *J Pineal Res*. 2010;49:69-77.
40. Beloozerova IN, Sirota MG, Swadlow HA, Orlovsky GN, Popova LB, Deliagina TG. Activity of different classes of neurons of the motor cortex during postural corrections. *J Neurosci* 2003;23:7844-7853.



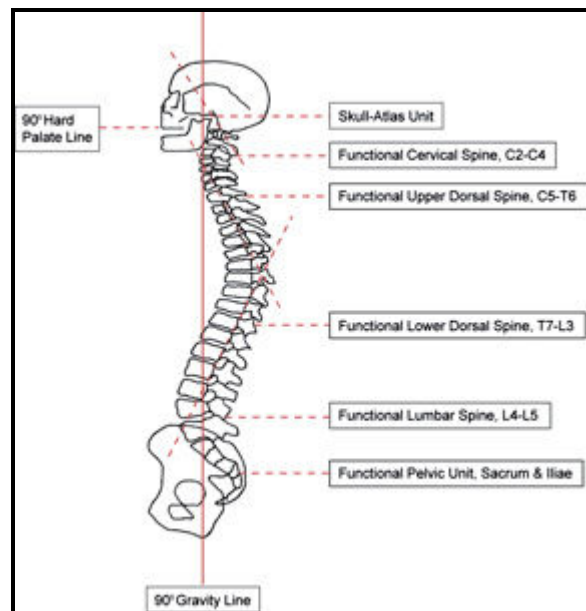
41. Sun W, Dan Y. Layer-specific network oscillation and spatiotemporal receptive field in the visual cortex. *Proc Natl Acad Sci U S A* 2009;106: 17986–17991.
42. Blood AJ. New hypotheses about postural control support the notion that all dystonias are manifestations of excessive brain postural function. *Biosci Hypotheses*. 2008 ; 1: 14–25.
43. Breig A. *Adverse Mechanical Tension in the Central Nervous System*. 1978 John Wiley & Sons Inc.
44. Birchall D, Hughes D, Gregson B, Williamson B. Demonstration of vertebral and disc mechanical torsion in adolescent idiopathic scoliosis using three-dimensional MR imaging. *Eur Spine J*. 2005 Mar;14(2):123-9.
45. Stokes IA, Gwadera J, Dimock A, Farnum CE, Aronsson DD. Modulation of vertebral and tibial growth by compression loading: diurnal versus full-time loading. *J Orthop Res*. Jan; 2005 23(1):188–195.
46. Laffosse JM, Accadbled F, Bonneville N, Gomez-Brouchet A, de Gauzy JS, Swider P. Remodelling of vertebral endplate subchondral bone in scoliosis: a micro-CT analysis in a porcine model. *Clin Biomech (Bristol, Avon)*. 2010 Aug;25(7):636-41.
47. Ding WY, Yang DL, Cao LZ, Sun YP, Zhang W, Xu JX, Zhang YZ, Shen Y. Intervertebral disc degeneration and bone density in degenerative lumbar scoliosis: a comparative study between patients with degenerative lumbar scoliosis and patients with lumbar stenosis. *Chin Med J (Engl)*. 2011 Dec;124(23):3875-8.
48. Hawes MC, O'Brien JP. The transformation of spinal curvature into spinal deformity: pathological processes and implications for treatment. *Scoliosis* 2006;1:3
49. Cheung CS, Lee WT, Tse YK, Lee KM, Guo X, Qin L et al. Generalized osteopenia in adolescent idiopathic scoliosis—association with abnormal pubertal growth, bone turnover, and calcium intake? *Spine* 2006;31:330–338.
50. Cheng JC, Tang SP, Guo X, Chan CW, Qin L. Osteopenia in adolescent idiopathic scoliosis: a histomorphometric study. *Spine* 2001;26:E19–E23.
51. Park WW, Suh KT, Kim JI, Kim SJ, Lee SJ. Decreased osteogenic differentiation of mesenchymal stem cells and reduced bone mineral density in patients with adolescent idiopathic scoliosis. *Eur Spine J* 2009;18:1920–1926.
52. Cheng JC, Guo X. Osteopenia in adolescent idiopathic scoliosis: a primary problem or secondary to the spinal deformity? *Spine* 1997;22:1716–1721.
53. Li XF, Li H, Liu ZD, Dai LY. Low bone mineral status in adolescent idiopathic scoliosis. *Eur Spine J* 2008;17:1431–1440.
54. Courtois I, Collet P, Mouilleseaux B, Alexandre C. Bone mineral density at the femur and lumbar spine in a population of young women treated for scoliosis in adolescence. *Rev Rhum Engl Ed* 1999;66:705–710.
55. Nicholson PH, Haddaway MJ, Davie MW, Evans SF. Vertebral deformity, bone mineral density, back pain and height loss in unscreened women over 50 years. *Osteoporos Int* 1993;3:300–307.
56. Pappou IP, Girardi FP, Sandhu HS, Parvataneni HK, Cammisa, Jr FP, Schneider R, Frelinghuysen P, Lane JM. Discordantly high spinal bone mineral density values in patients with adult lumbar scoliosis. *Spine* 2006;31:1614–1620.
57. Qiu Y, Sun X, Qiu X, Li W, Zhu Z, Zhu F, Wang B, Yu Y, Qian B. Decreased circulating leptin level and its association with body and bone mass in girls with adolescent idiopathic scoliosis. *Spine* 2007;32:2703–2710.
58. Liu Z, Tam EMS, Sun G-Q, Lam TP, Zhu ZZ, Sun X, Lee KM, Ng TB, Qiu Y, Cheng JCY, Yeung HY. Abnormal leptin bioavailability in adolescent idiopathic scoliosis. *Spine* 2012;37:599–604.
59. Liang G, Gao W, Liang A, Ye W, Peng Y, et al. Normal leptin expression, lower adipogenic ability, decreased leptin receptor and hyposensitivity to leptin in adolescent idiopathic scoliosis. *PLoS ONE* 2012;7: e36648.
60. Burwell RG, Aujla RK, Grevitt MP, Dangerfield PH, Moulton A, Randell TL, Anderson SI. Pathogenesis of adolescent idiopathic scoliosis in girls - a double neuro-osseous theory involving disharmony between two nervous systems, somatic and autonomic expressed in the spine and trunk: possible dependency on sympathetic nervous system and hormones with implications for medical therapy. *Scoliosis* 2009, 4:24.
61. Matkovic V, Ilich JZ, Skugor M, et al. Leptin is inversely related to age at menarche in human females. *J Clin Endocrinol Metab* 1997;82:3239–45.
62. Quinton ND, Smith RF, Clayton PE, et al. Leptin binding activity changes with age: the link between leptin and puberty. *J Clin Endocrinol Metab* 1999;84:2336–41.
63. Maor G, Rochwerger M, Segev Y, et al. Leptin acts as a growth factor on the chondrocytes of skeletal growth centers. *J Bone Miner Res* 2002;17:1034–43.
64. Winnie CW Chu, Wynnie MW Lam, Bobby KW Ng, Lam Tze-ping, Kwong-man Lee, Xia Guo, Jack CY Cheng, R Geoffrey Burwell, Peter H Dangerfield, Tim Jaspán. Relative shortening and functional tethering of spinal cord in adolescent scoliosis – Result of asynchronous neuro-osseous growth, summary of an electronic focus group debate of the IBSE. *Scoliosis* 2008, 3:8.
65. Harrison DE, Cailliet R, Harrison DD, Troyanovich SJ, Harrison SO. A review of biomechanics of the central nervous system--Part I: spinal canal deformations resulting from changes in posture. *J Manipulative Physiol Ther*. 1999 May;22(4):227-34.
66. Harrison DE, Cailliet R, Harrison DD, Troyanovich SJ, Harrison SO. A review of biomechanics of the central nervous system--part II: spinal cord strains from postural loads. *J Manipulative Physiol Ther*. 1999 Jun;22(5):322-32.
67. Harrison DE, Cailliet R, Harrison DD, Troyanovich SJ, Harrison SO. A review of biomechanics of the central nervous system--Part III: spinal cord stresses from postural loads and their neurologic effects. *J Manipulative Physiol Ther*. 1999 Jul-Aug;22(6):399-410.

68. Chu WCW, Lam WMW, Ng BKW, Tze-ping L, Lee K, Guo X, Cheng JCY, Burwell RG, Dangerfield PH, Jaspán T. Relative shortening and functional tethering of spinal cord in adolescent scoliosis – Result of asynchronous neuro-osseous growth, summary of an electronic focus group debate of the IBSE. *Scoliosis* 2008;3:8.
69. Cruickshank JL, Koike M, Dickson RA. Idiopathic scoliosis in three dimensions. *J Bone Joint Surg [Br]* 1989;71:259-63.
70. van Loon PJM, Roukens M, Kuit JDJ, Thunnissen FBTM. A new brace treatment similar for adolescent scoliosis and kyphosis based on restoration of thoracolumbar lordosis. Radiological and subjective clinical results after at least one year of treatment. *Scoliosis* 2012;7:19.
71. Morningstar MW, Stitzel CJ. Cobb's Angle in Scoliosis - Gold Standard or Golden Calf? A Commentary on Scoliosis Outcome Assessment. *J. Pediatric, Maternal & Family Health* 2010;1:6-10.
72. Whiting WC, Zernicke RF. *Biomechanics of Musculoskeletal Injury*, 2nd ed. 2008 Human Kinetics.
73. Hall JE. *Guyton and Hall Textbook of Medical Physiology*, 12th ed. 2010 Saunders
74. Cramer GD, Darby SA. *Basic and Clinical Anatomy of the Spine, Spinal Cord, and ANS*, 2nd ed. 2005 Mosby, Inc.
75. Meir AR, Fairbank JCT, Jones DA, McNally DS, Urban JPG. High pressures and asymmetrical stresses in the scoliotic disc in the absence of muscle loading. *Scoliosis* 2007;2:4.
76. Stokes IA, McBride C, Aronsson DD, Roughley PJ. Intervertebral disc changes with angulation, compression and reduced mobility simulating altered mechanical environment in scoliosis. *Eur Spine J*. 2011 Oct;20(10):1735-44.
77. Stokes IAF. Scoliosis: discs and vertebrae. Cobb angle: friend or foe? *Scoliosis* 2010, 5(Suppl 1):O62.
78. Clin J, Aubin CÉ, Sangole A, Labelle H, Parent S. Correlation between immediate in-brace correction and biomechanical effectiveness of brace treatment in adolescent idiopathic scoliosis. *Spine (Phila Pa 1976)*. 2010 Aug 15;35(18):1706-13.
79. Wiley JW, Thomson JD, Mitchell TM, Smith BG, Banta JV. Effectiveness of the boston brace in treatment of large curves in adolescent idiopathic scoliosis. *Spine (Phila Pa 1976)*. 2000 Sep 15;25(18):2326-32.
80. Morningstar MW. Integrative treatment using chiropractic and conventional techniques for adolescent idiopathic scoliosis: outcomes in four patients. *J Vertebral Subluxation Res* 2007 July 9: 1-7
81. Roye BD, Wright ML, Williams BA, Matsumoto H, Corona J, Hyman JE, Roye DP Jr, Vitale MG. Does ScolioScore provide more information than traditional clinical estimates of curve progression? *Spine* 2012;37:2099-103.
82. Enoka, RM. Muscle strength and its development: new perspectives. *Sports Med* 1988;6:146–68.
83. Sale, DG. Neural adaptation to resistance training. *Med Sci Sports Exerc* 1988;20: S135-S145.
84. Burwell RG, Aujla RK, Grevitt MP, Dangerfield PH, Moulton A, Randell TL, Anderson SI. Pathogenesis of adolescent idiopathic scoliosis in girls - a double neuro-osseous theory involving disharmony between two nervous systems, somatic and autonomic expressed in the spine and trunk: possible dependency on sympathetic nervous system and hormones with implications for medical therapy. *Scoliosis* 2009, 4:24.
85. Morningstar MW, Stitzel CJ. The relationship between cervical kyphosis and scoliosis. *J. Vertebral Subluxation Res* 2008;4:1-4.
86. Hilibrand AS, Tannenbaum DA, Graziano GP, Loder RT, Hensinger RN. The sagittal alignment of the cervical spine in adolescent idiopathic scoliosis. *J Pediatr Orthop* 1995;15:627-632.
87. Kepler CK, Meredith DS, Green DW, Widmann RF. Long-term outcomes after posterior spine fusion for adolescent idiopathic scoliosis. *Curr Opin Pediatr*. 2012 Feb;24(1):68-75.

## Figures



**Figure 1.** From left to right: As the spring is pulled through and beyond its elastic zone, it becomes permanently deformed. This is an illustration of plastic deformation. Once this occurs in white tissue, it can no longer provide the previous level of kinematic stability, to which the body must further adapt.



**Figure 2.** This figure shows the biomechanical lever arms that compose the spinal system. These lever arms are divided up based upon their respective muscle attachments and fulcrum points. Note that the two longest lever arms make up the thoracic kyphosis, which is often compromised in patients with scoliosis. Graphic adapted with permission from the Pettibon System, Inc.