


Original Investigation

Long-term Therapy With Interleukin 6 Receptor Blockade in Highly Active Neuromyelitis Optica Spectrum Disorder

Marius Ringelstein, MD; Ilya Ayzenberg, MD; Jens Harmel, MD; Ann-Sophie Lauenstein, MD; Eckart Lensch, MD; Florian Stögbauer, MD; Kerstin Hellwig, MD; Gisa Ellrichmann, MD; Mark Stettner, MD; Andrew Chan, MD; Hans-Peter Hartung, MD; Bernd Kieseier, MD; Ralf Gold, MD; Orhan Aktas, MD; Ingo Kleiter, MD

 Editorial

IMPORTANCE Neuromyelitis optica (NMO) is characterized by disabling relapses of optic neuritis and myelitis and the presence of aquaporin 4 antibodies (AQP4-abs). Interleukin 6, which is significantly elevated in serum and cerebrospinal fluid of patients with NMO, induces AQP4-ab production by plasmablasts and represents a novel therapeutic target.

OBJECTIVE To evaluate the long-term safety and efficacy of tocilizumab, a humanized antibody targeting the interleukin 6 receptor, in NMO and NMO spectrum disorder.

DESIGN, SETTING, AND PARTICIPANTS Retrospective observational study with 10 to 51 months of follow-up between December 2010 and February 2015, in neurology departments at tertiary referral centers. Participants were 8 female patients of white race/ethnicity with highly active AQP4-ab-seropositive NMO (n = 6) and NMO spectrum disorder (n = 2) whose disease had been resistant to previous medications, including B-cell depletion, and who switched to tocilizumab (6-8 mg/kg of body weight per dose).

MAIN OUTCOMES AND MEASURES Annualized relapse rate, Expanded Disability Status Scale score, spinal cord and brain magnetic resonance imaging, AQP4-ab titers, pain levels (numerical rating scale), and adverse effects.

RESULTS Patients were followed up for a mean (SD) of 30.9 (15.9) months after switching to tocilizumab. Two of eight patients received add-on therapy with monthly corticosteroid pulses (temporary) or azathioprine, respectively. During tocilizumab treatment, the median annualized relapse rate significantly decreased from 4.0 (interquartile range, 3.0-5.0) in the year before tocilizumab therapy to 0.4 (interquartile range, 0.0-0.8) ($P = .008$), and the median Expanded Disability Status Scale score significantly decreased from 7.3 (interquartile range, 5.4-8.4) to 5.5 (interquartile range, 2.6-6.5) ($P = .03$). Active magnetic resonance imaging lesions were seen in 6 of 8 patients at tocilizumab initiation and in 1 of 8 patients at the last magnetic resonance imaging. Three patients remained relapse free during tocilizumab treatment. In 5 patients, a total of 8 relapses occurred, 4 within the first 2½ months of therapy. Five attacks were associated with delayed tocilizumab administration (≥ 40 days), and 6 attacks were associated with reduced tocilizumab dosage (6 vs 8 mg/kg). The AQP4-ab titers ($P = .02$) and pain levels ($P = .02$) dropped significantly during tocilizumab treatment. Adverse effects included moderate cholesterol elevation in 6 of 8 patients, infections in 4 of 8 patients, and deep venous thrombosis and neutropenia in one patient each.

CONCLUSIONS AND RELEVANCE Prolonged tocilizumab therapy may be safe and effective from early treatment phases onward for otherwise therapy-resistant highly active NMO and NMO spectrum disorder. Relapse patterns indicate that adherence to a regular therapeutic regimen with monthly infusions of tocilizumab (8 mg/kg) may increase efficacy.

JAMA Neurol. doi:10.1001/jamaneurol.2015.0533
Published online May 18, 2015.

Author Affiliations: Department of Neurology, Heinrich Heine University Düsseldorf, Düsseldorf, Germany (Ringelstein, Harmel, Stettner, Hartung, Kieseier, Aktas); Department of Neurology, St Josef Hospital, Ruhr University Bochum, Bochum, Germany (Ayzenberg, Hellwig, Ellrichmann, Chan, Gold, Kleiter); Deutschen Klinik für Diagnostik Helios Klinik Wiesbaden, Wiesbaden, Germany (Lauenstein, Lensch); Department of Neurology, Clinic Osnabrück, Osnabrück, Germany (Stögbauer).

Corresponding Author: Ingo Kleiter, MD, Department of Neurology, St Josef Hospital, Ruhr University Bochum, Gudrunstrasse 56, 44791 Bochum, Germany (ingo.kleiter@rub.de).

Neuromyelitis optica (NMO) is a severe inflammatory disease of the central nervous system characterized by relapsing optic neuritis and longitudinally extensive transverse myelitis, with frequently poor recovery.^{1,2} Acute NMO attacks are usually treated with high-dose corticosteroids or require escalation therapy with plasma exchange.³ However, relapse prevention remains a challenging issue in NMO because established multiple sclerosis therapies such as interferons, natalizumab, and fingolimod have been reported to show little efficacy or even to be detrimental.⁴⁻⁶ According to smaller case series or retrospective cohort studies, long-term immunosuppression with azathioprine⁷ or mycophenolate mofetil⁸ is recommended for mild NMO cases, with methotrexate being an alternative treatment option.^{3,9} In patients with more severe NMO courses, rituximab¹⁰ and mitoxantrone hydrochloride¹¹ have been reported to diminish the relapse frequency. However, in these retrospective case series, some patients with NMO manifested persistent disease activity or experienced major adverse effects, rendering additional potent and well-tolerable medications desirable.

The autoantibody against aquaporin 4 (AQP4-ab), highly specific for NMO and its spectrum disorder (NMOSD),^{12,13} has been suggested to contribute to the pathogenesis of the disease, and the related B-cell-mediated immune processes were considered a potential target for future therapeutic interventions. Increased interleukin 6 (IL-6) levels were detected in serum and cerebrospinal fluid (CSF) of patients with NMO, particularly during relapses.¹⁴ Interleukin 6 promotes AQP4-ab production and secretion from B-cell-derived plasmablasts, whereas the blockade of IL-6 receptor signaling by an anti-IL-6 receptor antibody reduces the survival of plasmablasts *in vitro*.¹⁵ Tocilizumab, a humanized monoclonal antibody against the IL-6 receptor approved for treatment of rheumatoid arthritis,¹⁶ recently showed beneficial clinical and paraclinical effects in single patients with NMO and in one prospective cohort for treatment periods of 12 to 24 months.¹⁷⁻²²

The aim of this retrospective multicenter study was to evaluate the long-term safety and efficacy of tocilizumab in patients with highly active NMO. The patients had not adequately responded to previous first-line and second-line treatments.

Methods

Patients and Treatment

Eight female patients of white race/ethnicity with AQP4-ab-seropositive NMO (n = 6) and NMOSD (n = 2) diagnosed according to current criteria^{12,23} were retrospectively analyzed at the German departments of neurology at Heinrich Heine University Düsseldorf, St Josef Hospital at Ruhr University Bochum, German Diagnostic Clinic in Wiesbaden, and Clinic Osnabrück. All 6 patients with NMO had experienced 1 or more previous episodes of longitudinally extensive transverse myelitis and optic neuritis. In the 2 patients with NMOSD, no episodes of optic neuritis were reported, but recurrent longitudinally extensive transverse myelitis, 2 cerebellar attacks, and one brainstem attack had occurred. Before beginning tocilizumab therapy, all patients had been pretreated with immunomodulatory or immunosuppressant medications, including interferon beta-1b (n = 3), interferon beta-1a (n = 2), azathioprine (n = 2), mitoxantrone (n = 2), mycophenolate mofetil (n = 1), natalizumab (n = 1), glatiramer acetate (n = 1), alemtuzumab (n = 1), and monthly intravenous corticosteroids (250 mg/mo) (n = 1). Rituximab had been administered at least once to every patient before tocilizumab therapy, with a range of 1 to 3 therapeutic cycles comprising 1 to 2 infusions per cycle. Patient 1 received 1 cycle of 1500 mg, followed by 2 cycles of 1000 mg in yearly intervals (Table). Patients 2 and 4 received 1 cycle of 1500 mg. Patients 3, 5, and 6 received 1 cycle of 1000 mg. Patients 7 and 8 received 2 cycles of 1000 mg with a 2-week interval. Tocilizumab was initiated in 4 of 8 patients at a reduced dosage of 6 mg/kg of body weight in 4-week to 6-week intervals and was switched to 8 mg/kg in 2 of 4 patients after relapses had occurred. The reduced dosage was chosen by the treating physicians for safety reasons. In the other 4 patients, tocilizumab was continuously administered from the beginning of treatment at a higher dosage of 8 mg/kg at regular 4-week intervals. On some occasions, intervals between tocilizumab administration were prolonged (eg, due to holidays, missed appointments, or patient request). Among 8 patients, 5 had been previously reported in single case studies or smaller series on the effect of short-term tocilizumab intervention of 12 to 24 months: these included patients 1, 2, and 4 in a 2013 study,¹⁸ patient 3 in another 2013 study,¹⁷ and patient 5 in a 2014 study.²¹ This study was approved by the local ethics committees in Düsseldorf and Bochum as part of an observational study examining the treatment and disease course of NMO. All participants gave written informed consent.

Study Design

This was a retrospective observational study with 10 to 15 months of follow-up between December 2010 and February 2015 in neurology departments at tertiary referral centers. All clinical and paraclinical data were analyzed retrospectively by medical record review. Since beginning rituximab therapy, all patients had been treated continuously at one of the participating tertiary referral centers, all specialized in multiple sclerosis care, ensuring the regular assessment of clinical data (attacks and Expanded Disability Status Scale [EDSS] score²⁴) and paraclinical data (magnetic resonance [MR] imaging, AQP4-ab titers, and other laboratory tests). The primary outcome was the annualized relapse rate (ARR), calculated as the total number of attacks per patient, divided by the total observation time in years. An acute attack was defined as a new neurological worsening lasting for at least 24 hours and occurring more than 30 days after the previous attack. Laboratory tests, performed at regular intervals of 4 to 6 weeks during the first 6 months and quarterly thereafter, included complete blood cell count, electrolytes, kidney values, liver enzymes, C-reactive protein, coagulation status, and lipid values, including total cholesterol and high-density and low-density cholesterol levels. The AQP4-ab titers were tested by a cell-based assay²⁵ before tocilizumab initiation (n = 6) or within the first year of tocilizumab treatment (n = 2) and were retested during the last 3 tocilizumab treatment months. Pain levels were measured with a numerical rating scale, ranging from 0 (no pain) to 10

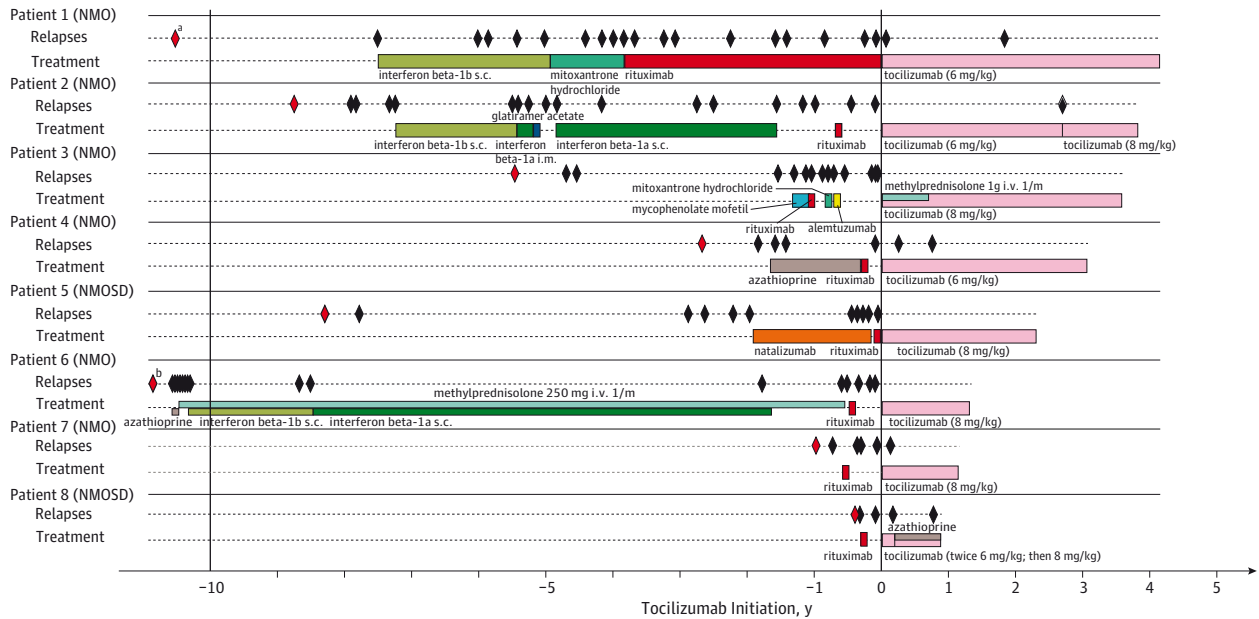
Table. Cohort of Patients With Neuromyelitis Optica (NMO) or Neuromyelitis Optica Spectrum Disorder (NMOSD) Receiving Tocilizumab Therapy

Variable	Patient 1	Patient 2	Patient 3	Patient 4	Patient 5	Patient 6	Patient 7	Patient 8
Diagnosis	NMO	NMO	NMO	NMO	NMOSD	NMO	NMO	NMOSD
Age at disease onset, y (date of first attack)	31 (October 1998)	18 (July 2002)	30 (January 2006)	37 (May 2009)	22 (November 2003)	24 (October 1989)	24 (January 2013)	49 (November 2013)
Age at tocilizumab initiation, y (date of first dose)	43 (December 2010)	27 (April 2011)	36 (July 2011)	39 (January 2012)	31 (October 2012)	48 (October 2013)	25 (December 2013)	49 (April 2014)
Disease duration before tocilizumab initiation, y	12.1	8.8	5.5	2.8	8.9	24.0	0.9	0.5
Immunomodulatory or immunosuppressant therapy before tocilizumab initiation	Interferon beta-1b, mitoxantrone hydrochloride, rituximab	Interferon beta-1b, interferon beta-1a, glatiramer acetate, interferon beta-1a, rituximab	Mycophenolate mofetil, rituximab, mitoxantrone hydrochloride, alemtuzumab, triamcinolone	Azathioprine, rituximab	Natalizumab, rituximab	Azathioprine, interferon beta-1a, methylprednisolone, rituximab	Rituximab	Rituximab
No. of tocilizumab cycles (treatment time until the last follow-up)	46 (51.0 mo)	38 (46.9 mo)	46 (43.4 mo)	32 (37.1 mo)	31 (28.1 mo)	18 (16.6 mo)	14 (14.4 mo)	10 (10.0 mo)
Tocilizumab dosage, mg/kg	6	6, 8 Since 33 mo	8, First 8 cycles with intravenous methylprednisolone (1 g)	6	8	8	8	6 For 2 cycles, since then 8 plus azathioprine (100 mg)
Treatment intervals, wk	4-5	6	4	4	4	4	4	4-5
No. of attacks before tocilizumab initiation	19 (6 ON, 13 myelitis)	18 (2 ON, 16 myelitis)	14 (4 ON, 10 myelitis)	5 (2 ON, 3 myelitis)	11 (8 Myelitis, 1 cerebellar, 2 brainstem)	17 (8 ON, 8 myelitis, 1 cerebral)	5 (1 ON, 4 myelitis)	3 (3 Myelitis)
No. of attacks during tocilizumab therapy (time after tocilizumab initiation)	2 (1½ and 23 mo)	1 (33 mo)	0	2 (2½ and 8 mo)	0	0	1 (2 mo)	2 (2 and 8½ mo)
ARR before tocilizumab initiation during entire disease duration	1.6	2.1	2.5	1.8	1.2	0.7	5.5	6.0
ARR before tocilizumab initiation during last 12 mo	3.0	3.0	7.0	1.0	5.0	5.0	5.0 ^a	3.0 ^a
ARR during tocilizumab therapy	0.5	0.3	0.0	0.6	0.0	0.0	0.8	2.4
MR imaging at tocilizumab initiation	No active spinal and brain lesions	Active spinal lesion, no active brain lesions	Active spinal lesion, normal brain MR imaging	No active spinal and brain lesions	Active spinal lesion, no active brain lesions	Active spinal lesion, no active brain lesions	Active spinal lesion, normal brain MR imaging	Active spinal lesion, normal brain MR imaging
Findings on last MR imaging (time after tocilizumab initiation)	No new or active spinal lesions (47 mo)	No new or active spinal lesions (33 mo)	No new or active spinal lesions (41 mo), normal brain MR imaging (29 mo)	No new or active spinal lesions (34 mo)	No new or active spinal lesions, normal brain MR imaging (28 mo)	No new but still active spinal lesions (14 mo)	No new or active spinal lesions (12 mo)	No new or active spinal lesions, normal brain MR imaging (3 mo)
Tocilizumab adverse effects	Transient diarrhea, deep venous thrombosis	Recurrent UTI during self-catheterization	None	Headache, fatigue	None	Transient mild fatigue	Mild postinfusion nausea, transient gastritis, recurrent UTI	Recurrent UTI
Laboratory abnormalities during tocilizumab therapy	Recurrent C-reactive protein↑, cholesterol↑	Mild cholesterol↑	Cholesterol↑	Mild liver enzyme↑, mild cholesterol↑	Mild lipase↑	Cholesterol↑, leukopenia	Transient transaminase↑, cholesterol↑	Leukopenia, neutropenia during azathioprine comedication

Abbreviations: ARR, annualized relapse rate; MR, magnetic resonance; ON, optic neuritis; UTI, urinary tract infection; ↑, increasing.

^a The disease duration before tocilizumab initiation of patients 7 and 8 was less than 1 year.

Figure 1. Disease Course and Immunomodulatory or Immunosuppressant Therapies of Aquaporin 4 Antibody-Seropositive Patients With Neuromyelitis Optica (NMO) or Neuromyelitis Optica Spectrum Disorder (NMOSD)



Clinical relapses (black diamonds, with first attacks in red) and treatments are shown. i.m. Indicates intramuscular; i.v., intravenous; s.c., subcutaneous; and 1/m, once per month.

^a Twelve years before tocilizumab initiation.

^b Twenty-four years before tocilizumab initiation.

(intolerable pain), at tocilizumab initiation and at the last follow-up. Magnetic resonance imaging (1.5 T) of the cervicothoracic spinal cord and the cranium was performed at tocilizumab initiation and at regular intervals (once per year), with gadolinium enhancement indicative of active lesions. Statistical analyses were performed using a software package (Prism 6; GraphPad). All outcome measures were analyzed with the nonparametric Wilcoxon rank sum test. $P < .05$ was considered significant. Values are given as the mean (SD) when normally distributed and otherwise as the median (interquartile range).

Results

We identified 8 AQP4-ab-seropositive female patients of white race/ethnicity with NMO ($n = 6$) or NMOSD ($n = 2$). Mean ages were 29.4 (9.9) years at disease onset and 37.3 (9.1) years at first tocilizumab administration, with a mean disease duration of 7.9 (7.7) years (Table). The mean number of attacks before tocilizumab treatment was 11.5 (6.5). All patients had high disease activity and had failed to respond to previous therapies, including B-cell depletion with rituximab (Figure 1).

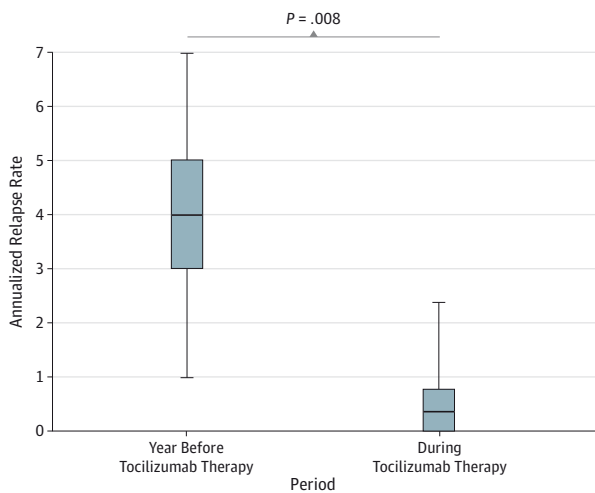
At the time of treatment initiation with tocilizumab, B-cell numbers were still reduced in 7 patients (mean, 1.4% [1.3%] relative amount of CD19⁺ B cells) but had normalized in 3 of 5 patients tested again after 4.6 (3.0-15.5) months. Spinal cord MR imaging revealed longitudinally extensive transverse myelitis in all patients, with gadolinium-enhancing lesions in 6

of 8 patients. Brain MR imaging was unremarkable in 3 of 8 patients and showed nonspecific nonactive white matter lesions in 5 of 8 patients.

A mean of 29.4 (14.0) tocilizumab infusions during a mean follow-up time of 30.9 (15.9 months) was administered at a dosage of 6 or 8 mg/kg. Patient 3 received the first 8 tocilizumab infusions in combination with intravenous prednisolone sodium succinate (1 g) because of persisting spinal cord MR imaging activity with gadolinium-enhancing lesions, and patient 8 was treated with add-on azathioprine (100 mg) following a relapse after the second tocilizumab infusion. No other additional immunomodulatory or immunosuppressant comedications were administered.

The median ARR over the entire disease duration before tocilizumab initiation was 2.0 (1.3-4.8), which increased in the year before tocilizumab initiation to 4.0 (3.0-5.0). During tocilizumab treatment, the ARR dropped significantly to 0.4 (0.0-0.8) ($P = .008$) (Figure 2). Three patients remained relapse free during tocilizumab treatment. In 5 patients, a total of 8 relapses occurred. Four of eight relapses occurred during the first 2½ months after tocilizumab initiation (40, 54, 58, and 74 days after tocilizumab initiation). These 4 relapses occurred at a dosage of 6 mg/kg in 3 patients (one each with optic neuritis, mild sensorimotor hemiparesis, and myelitis) and at a dosage of 8 mg/kg in one patient (with myelitis at 54 days after infusion). Three relapses (all in patients receiving 6 mg/kg of tocilizumab) manifesting as hemisensory syndrome in 2 patients and severe myelitis in one patient occurred 8, 23, and 33 months after the first tocilizumab infusion. Another relapse (worsen-

Figure 2. Annualized Relapse Rate Before and During Tocilizumab Therapy



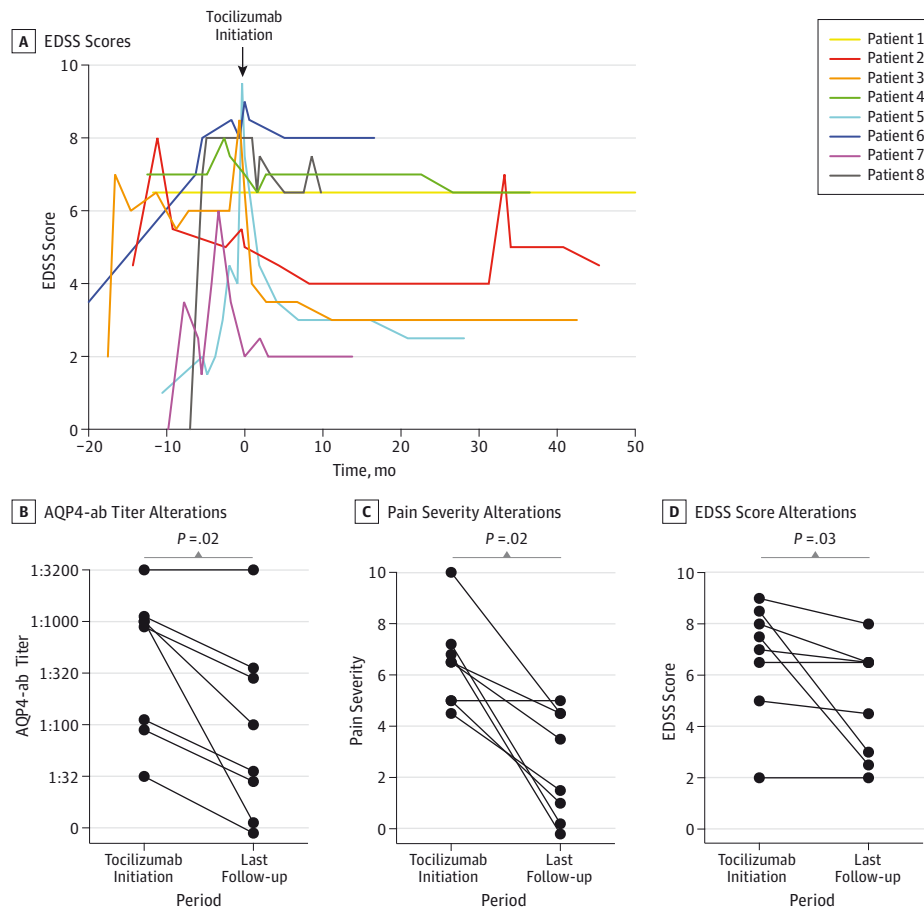
The median, interquartile range, and range are shown. The median annualized relapse rate significantly decreased from 4.0 (interquartile range, 3.0-5.0) in the year before tocilizumab therapy to 0.4 (interquartile range, 0.0-0.8) during tocilizumab therapy ($P = .008$).

ing of paraparesis) occurred after a 55-day interval due to leukopenia and neutropenia in a patient concomitantly treated with azathioprine. Therefore, 6 of 8 relapses occurred when receiving a reduced tocilizumab dosage of 6 mg/kg, and 5 of 8 attacks occurred after prolongation of the infusion interval to 40 days or longer. However, there were 31 additional prolongations of the infusion interval to 40 days or longer in 4 other patients that did not result in further attacks.

All 8 relapses were initially treated with high-dose intravenous methylprednisolone hydrogen succinate (1000 mg for 2-5 days). This was followed by rescue therapy in 5 patients, including plasma exchange or immunoadsorption using tryptophan as an adsorber (TR-350; Diamed Medizintechnik GmbH) in 4 attacks, an additional corticosteroid pulse with 4 cycles of 2000 mg in 2 attacks, and intrathecal application of corticosteroids in one attack. This treatment led to complete remission of 7 attacks and to persisting deficits after a severe case of myelitis in patient 2.

Disability measured by the EDSS score improved from 7.3 (5.4-8.4) at tocilizumab initiation to 5.5 (2.6-6.5) at the last follow-up ($P = .03$) (Figure 3). Six patients had a lower EDSS score, and no patient's condition deteriorated. In patients 4 and 5, the EDSS score had improved 16 and 21 months after the last relapse, respectively.

Figure 3. Features of Disease Activity Before and During Tocilizumab Therapy



A, Expanded Disability Status Scale (EDSS) scores. B, Alterations of aquaporin 4 antibody (AQP4-ab) titers. C, Alterations of pain severity assessed by a numerical rating scale. D, Alterations of EDSS scores between tocilizumab initiation and the last follow-up.

Pain was mainly reported as neuropathic pain. Pain levels decreased significantly from a median of 6.5 (5.0-7.0) at tocilizumab therapy initiation to 2.5 (0.3-4.5) at the last follow-up ($P = .02$) (Figure 3). Seven of eight patients had less pain at the last follow-up, with 2 of them completely pain free. Four patients received continuous pain medication with carbamazepine ($n = 1$); amitriptyline hydrochloride ($n = 1$); combinations of naloxone hydrochloride, oxycodone hydrochloride, and tetrahydrocannabinol ($n = 1$); or combinations of amitriptyline, pregabalin, tilidin hydrochloride, and naloxone ($n = 1$). Two other patients were treated by request with gabapentin or acetylsalicylic acid and paracetamol, respectively, and 2 patients were taking no pain medication at the last visit. During tocilizumab treatment, AQP4-ab titers dropped significantly from a median of 1:1000 to 1:66 ($P = .02$).

Active MR imaging lesions were seen in 6 of 8 patients at tocilizumab initiation and in 1 of 8 patients at the last MR imaging. Follow-up MR imaging revealed no active T1-weighted or new T2-weighted lesions in 6 patients with spinal cord MR imaging and 3 patients with cranium MR imaging available in the last year of tocilizumab therapy. Exceptions were persisting active spinal cord lesions in patient 3 during the initial treatment period and an active spinal lesion in patient 6 at 14 months after tocilizumab initiation.

During tocilizumab therapy, mild postinfusion nausea ($n = 1$), transient gastritis ($n = 1$), transient diarrhea ($n = 1$), headache ($n = 1$), fatigue ($n = 2$), and recurrent urinary tract infections ($n = 3$) were reported by the patients. Patient 1 had deep venous thrombosis of the right leg 3 years after tocilizumab initiation. However, no severe infections or other tocilizumab-related major adverse effects occurred. No further laboratory abnormalities were observed except for transient mild liver enzyme increase in 3 patients, recurrent C-reactive protein elevation in one patient (due to NMO attacks twice, venous catheter-associated infection once, and deep venous thrombosis once), leukopenia or neutropenia in 2 patients (in one patient during azathioprine comedication), and elevation of cholesterol levels in 6 patients.

Discussion

Neuromyelitis optica attacks are often disabling and result in a poor recovery. While therapeutic interventions with immunosuppressive drugs can reduce the frequency of NMO relapses,^{3,7-11} individual patients in most studies did not respond sufficiently to treatment or experienced major adverse effects. Therefore, better preventive NMO therapies are desirable. Herein, we present data demonstrating successful long-term treatment with the anti-IL-6 receptor antibody tocilizumab in 8 female patients with NMO or NMOSD who had failed to improve with several previous medications, including the B-cell-depleting antibody rituximab.

Tocilizumab is approved for the treatment of rheumatoid arthritis and systemic juvenile idiopathic arthritis. In both diseases, increased serum IL-6 levels have been shown to promote synovitis and induce progressive bone resorption and cartilage degeneration.¹⁶ Interleukin 6 also mediates inflammation,

demyelination, and astrogliosis in the central nervous system.²⁶ It is secreted primarily by activated astrocytes in the setting of infection, stroke, or inflammation.²⁶ In patients with transverse myelitis, IL-6 levels are elevated in the CSF and directly correlate with total nitrite oxide production, spinal cord tissue injury, and long-term clinical disability.²⁷ In patients with NMO, increased levels of IL-6 were detected in the CSF and serum, particularly in AQP4-ab-seropositive patients with severe disease activity.¹⁴ Using an ex vivo spinal cord organotypic section model, NMO IgG-mediated AQP4 loss and demyelination in the presence of IL-6 were markedly increased.²⁸ Finally, IL-6 enhances survival and AQP4-ab synthesis of the CD19 (intermediate), CD27 (high), CD38 (high), and CD180 (negative) phenotype plasmablasts, which were shown to circulate at increased levels in the peripheral blood of patients with NMO.¹⁵ Therapeutic inhibition of the IL-6-IL-6 receptor axis with tocilizumab reduced the level of AQP4-abs in the serum of patients with NMO.¹⁹⁻²¹ Several case reports^{17-19,21} (6 patients) and one recent prospective pilot study²⁰ (7 patients) demonstrated that tocilizumab administered for 12 to 24 months also reduced clinical and MR imaging disease activity of NMO.

Our longitudinal cohort extends these observations to a treatment time of up to 51 months (a total of 235 tocilizumab infusions) and to divergent treatment schedules. Most important, we confirmed several previous findings,¹⁷⁻²¹ particularly a significant reduction in the median ARR during tocilizumab long-term therapy from 4.0 to 0.4. The extent of ARR reduction in our cohort of white race/ethnicity is similar to that reported in a Japanese study,²⁰ indicating that tocilizumab suppresses NMO disease activity across different racial/ethnic populations. In contrast to the Japanese cohort, all of our patients (but none of their patients) had been pretreated at least once with rituximab and had a higher EDSS score (mean, 6.7 vs 5.1) and more relapses in the prior year (mean ARR, 4.0 vs 2.9) at tocilizumab initiation. Except for 2 patients with monthly high-dose corticosteroid infusions (temporary) and add-on azathioprine, respectively, our patients received no concomitant immunosuppressive medication during tocilizumab therapy. However, we cannot rule out that long-lasting biological effects of preceding immunotherapies such as rituximab overlapped with the subsequent tocilizumab therapy. In the Japanese cohort, all 7 patients received continuous comedication, including azathioprine, prednisolone, tacrolimus, and cyclosporine A.²⁰ Nevertheless, relapse activity was equally reduced in our cohort, demonstrating that tocilizumab can reduce the frequency of attacks in NMO without concomitant immunosuppression, even in patients with high disease activity. In addition, we observed a paraclinical improvement in MR imaging-detectable disease activity, illustrated by a reduction in gadolinium-enhancing MR imaging lesions from 6 of 8 patients at tocilizumab initiation to 1 of 8 patients at the last follow-up.

In line with previous case reports^{19,21} and a pilot study by Araki et al,²⁰ we also observed a decrease in the EDSS score and the AQP4-ab titers in most patients during tocilizumab treatment. Considering that disability in NMO is due to insufficient remission of attacks and that secondary progression is

uncommon, it is remarkable that 6 of 8 patients experienced an improvement in the EDSS score over 1 to 4 years, 2 of them dramatically (by 5.0 and 5.5 points, respectively). Because tocilizumab was initiated in all patients shortly after an NMO attack, enhanced remission from this attack is the most likely explanation. Disability improved in 2 patients long after the last relapse. Therefore, it may be hypothesized that the tocilizumab-mediated reduction in AQP4-abs, which has been shown to be pathogenic in experimental models²⁹ and is associated with disease activity,³⁰ facilitates tissue recovery. However, the precise underlying mechanisms remain to be clarified.

Despite good overall efficacy, 8 attacks occurred in 5 patients after tocilizumab therapy initiation. Except for one severe case of myelitis in patient 2, all attacks were mild to moderate, with complete recovery on the receipt of relapse therapy. Reasons for persisting disease activity in some patients remain elusive. Regarding a possible pattern, we found that 4 of 8 attacks occurred during the first 2½ treatment months (1 of 4 attacks in the study by Araki et al²⁰ was in the same period). Five relapses were related to delayed tocilizumab administration (intervals of ≥40 days), and 6 of 8 attacks were related to a lower tocilizumab dosage (6 vs 8 mg/kg). In contrast, no further attacks occurred after additional 31 prolonged infusion intervals (≥40 days). However, these data indicate that adherence to strict dosing regimens might improve the therapeutic efficacy of tocilizumab.

Chronic pain is a common symptom of NMO and is difficult to treat.^{31,32} Pathological mechanisms are not well characterized, but the release of potentially pronociceptive cytokines (including tumor necrosis factor, IL-1β, IL-17, and IL-6) might be important for the development of intractable pain in patients with NMO.^{33,34} Inhibition of the IL-6 receptor with tocilizumab was thought to alleviate chronic pain in Japanese patients with NMO.²⁰ We found a similar decrease in pain as

assessed with a numerical rating scale in our patients. It is possible that the effect of tocilizumab on pain is at least partly independent of effects on the immune system because epidural administration of tocilizumab was shown to reduce radicular pain in patients with lumbar spinal stenosis.³⁵

Regarding adverse effects of tocilizumab, a slightly elevated risk of infections has been reported in patients with rheumatoid arthritis.³⁶ These mainly included upper respiratory tract infections and reactivation of latent tuberculosis, along with increased concentrations of hepatic aminotransferases and plasma lipids and decreased absolute neutrophil counts and C-reactive protein levels. In our study, no major adverse effects or laboratory abnormalities were detected except for elevation of cholesterol levels in 6 patients and neutropenia in 1 patient.

Conclusions

Long-term tocilizumab therapy without concomitant immunosuppression in patients of white race/ethnicity with highly active NMO or NMOSD appears to be safe and effective in reducing relapses in otherwise treatment-resistant patients, particularly in rituximab nonresponders. A reduced dosage of tocilizumab (6 mg/kg) and a prolonged tocilizumab administration interval (≥40 days) seem to increase the risk of relapses, especially during the first 2 to 3 months of treatment. In the absence of a randomized clinical trial for tocilizumab, our study findings suggest a dense therapeutic regimen with infusions every 28 days at a dosage of 8 mg/kg to achieve optimal response to tocilizumab therapy. Subcutaneous IL-6 receptor blockade formulations are being prospectively studied in NMO and have shown beneficial effects in patients with rheumatoid arthritis.³⁷

ARTICLE INFORMATION

Accepted for Publication: March 12, 2015.

Published Online: May 18, 2015.

doi:10.1001/jamaneurol.2015.0533.

Author Contributions: Drs Ringelstein and Kleiter had full access to all the data in the study and take responsibility for the integrity of the data and the accuracy of the data analysis. Drs Ringelstein and Ayzenberg contributed equally to this work. Drs Aktas and Kleiter contributed equally to this work as senior authors.

Study concept and design: Ringelstein, Ayzenberg, Hartung, Gold, Aktas, Kleiter.

Acquisition, analysis, or interpretation of data: All authors.

Drafting of the manuscript: Ringelstein, Ayzenberg, Aktas, Kleiter.

Critical revision of the manuscript for important intellectual content: All authors.

Statistical analysis: Ringelstein, Kleiter.

Conflict of Interest Disclosures: Dr Ringelstein reported receiving speaker honoraria from Novartis and travel reimbursement from Bayer, Biogen Idec, and Genzyme (with permission by the rector of Düsseldorf University Hospital). Dr Ayzenberg reported receiving travel reimbursement from the International Headache Society. Dr Harmel

reported receiving travel reimbursement from Merck Serono (with permission by the rector of Düsseldorf University Hospital). Dr Lauenstein reported receiving travel reimbursement from UCB, Eisai, and Genzyme. Dr Lensch reported receiving speaker honoraria and travel reimbursement from Bayer, Biogen Idec, Genzyme, Sanofi, and Teva. Dr Stögbauer reported receiving speaker honoraria and travel reimbursement from Biogen Idec, Novartis, Boehringer, and Genzyme. Dr Hellwig reported receiving grants from the German Research Foundation and reported receiving speaker honoraria and research grants from Biogen Idec, Bayer, Teva, Merck Serono, Novartis, and Genzyme. Dr Ellrichmann reported receiving speaker honoraria or scientific grant support from Biogen Idec, Teva, Almirall Pharma, and Novartis. Dr Stettner reported receiving speaker honoraria and travel reimbursement from Biogen Idec, Novartis, and Teva (with permission by the rector of Düsseldorf University Hospital). Dr Chan reported receiving personal compensation as a speaker or consultant for Bayer, Biogen Idec, Genzyme, Merck Serono, Novartis, Sanofi, and Teva and reported receiving research support from the German Ministry for Education and Research, Biogen Idec, Genzyme, and Novartis. Dr Hartung reported receiving grants from Walter and Ilse Rose Stiftung,

Eugène Devic European Network, and the German Ministry for Education and Research; reported receiving honoraria for consultancy and speaking from Bayer, Biogen Idec, GeNeuro, Genzyme, Novartis, Opexa, Teva, Sanofi, and Roche; and reported holding patents (with permission by the rector of Heinrich Heine University Düsseldorf). Dr Kieseier reported receiving honoraria for lecturing, travel expenses for attending meetings, and financial support for research from Bayer, Biogen Idec, Genzyme/Sanofi, Grifols, Merck Serono, Mitsubishi Europe, Novartis, Roche, Talecris, Teva, and UCB. Dr Gold reported serving on scientific advisory boards for Teva, Biogen Idec, Bayer, and Novartis; reported receiving speaker honoraria from Biogen Idec, Teva, Bayer, and Novartis; reported receiving research support from Teva, Biogen Idec, Bayer, Merck Serono, and Novartis. Dr Aktas reported receiving grants from the German Research Foundation, Eugène Devic European Network, German Ministry for Education and Research, and Schauler Foundation; reported receiving honoraria for lectures from Novartis, Bayer, Teva, and Biogen Idec; and reported holding

patients and receiving travel, accommodation, and meeting expenses from Novartis, Bayer, and Merck Serono (with permission by the rector of Heinrich Heine University Düsseldorf). Dr Kleiter reported receiving honoraria for consultancy or speaking and travel reimbursement from Bayer, Biogen Idec, Chugai, and Novartis and reported receiving research grants from the Mercator Foundation, Bayer, Biogen Idec, Novartis, and Teva.

Funding/Support: The multiple sclerosis center at the Department of Neurology of Heinrich Heine University Düsseldorf is supported in part by Walter and Ilse Rose Stiftung (Drs Hartung and Aktas), Eugène Devic European Network (Drs Hartung and Aktas), the German Ministry for Education and Research (Dr Kieseier), and the Innovative Medicines Initiative Joint Undertaking under grant agreement 115303, resources that are financial contributions from the European Union's Seventh Framework Programme and European Federation of Pharmaceutical Industries and Associations companies' in-kind contribution. The multiple sclerosis center at the Department of Neurology of St Josef Hospital at Ruhr University Bochum is supported in part by the German Ministry for Education and Research (Dr Gold).

Role of the Funder/Sponsor: The funders had no role in the study design, data collection and analysis, decision to publish, or preparation of the manuscript.

Additional Information: This project was completed with equal cooperation between the Neurology Department at Heinrich Heine University Düsseldorf, Düsseldorf, Germany, and the Neurology Department at St Josef Hospital, Ruhr University Bochum, Bochum, Germany.

REFERENCES

- Wingerchuk DM, Weinshenker BG. Neuromyelitis optica (Devic's syndrome). *Handb Clin Neurol*. 2014; 122:581-599.
- Jarius S, Ruprecht K, Wildemann B, et al. Contrasting disease patterns in seropositive and seronegative neuromyelitis optica: a multicentre study of 175 patients. *J Neuroinflammation*. 2012;9:14.
- Trebst C, Jarius S, Berthele A, et al; Neuromyelitis Optica Study Group (NEMOS). Update on the diagnosis and treatment of neuromyelitis optica: recommendations of the Neuromyelitis Optica Study Group (NEMOS). *J Neurol*. 2014;261(1):1-16.
- Shimizu J, Hatanaka Y, Hasegawa M, et al. IFN β -1b may severely exacerbate Japanese optic-spinal MS in neuromyelitis optica spectrum. *Neurology*. 2010;75(16):1423-1427.
- Kleiter I, Hellwig K, Berthele A, et al; Neuromyelitis Optica Study Group. Failure of natalizumab to prevent relapses in neuromyelitis optica. *Arch Neurol*. 2012;69(2):239-245.
- Min JH, Kim BJ, Lee KH. Development of extensive brain lesions following fingolimod (FTY720) treatment in a patient with neuromyelitis optica spectrum disorder. *Mult Scler*. 2012;18(1): 113-115.
- Elsone L, Kitley J, Luppe S, et al. Long-term efficacy, tolerability and retention rate of azathioprine in 103 aquaporin-4 antibody-positive neuromyelitis optica spectrum disorder patients: a multicentre retrospective observational study from the UK. *Mult Scler*. 2014;20(11):1533-1540.
- Huh SY, Kim SH, Hyun JW, et al. Mycophenolate mofetil in the treatment of neuromyelitis optica spectrum disorder. *JAMA Neurol*. 2014;71(11):1372-1378.
- Kitley J, Elsone L, George J, et al. Methotrexate is an alternative to azathioprine in neuromyelitis optica spectrum disorders with aquaporin-4 antibodies. *J Neurol Neurosurg Psychiatry*. 2013;84(8):918-921.
- Kim SH, Huh SY, Lee SJ, Joung A, Kim HJ. A 5-year follow-up of rituximab treatment in patients with neuromyelitis optica spectrum disorder. *JAMA Neurol*. 2013;70(9):1110-1117.
- Kitley JL, Leite MI, Matthews LA, Palace J. Use of mitoxantrone in neuromyelitis optica. *Arch Neurol*. 2011;68(8):1086-1087.
- Wingerchuk DM, Lennon VA, Lucchinetti CF, Pittock SJ, Weinshenker BG. The spectrum of neuromyelitis optica. *Lancet Neurol*. 2007;6(9): 805-815.
- Lennon VA, Kryzer TJ, Pittock SJ, Verkman AS, Hinson SR. IgG marker of optic-spinal multiple sclerosis binds to the aquaporin-4 water channel. *J Exp Med*. 2005;202(4):473-477.
- Uzawa A, Mori M, Araki K, et al. Cytokine and chemokine profiles in neuromyelitis optica: significance of interleukin-6. *Mult Scler*. 2010;16 (12):1443-1452.
- Chihara N, Aranami T, Sato W, et al. Interleukin 6 signaling promotes anti-aquaporin 4 autoantibody production from plasmablasts in neuromyelitis optica. *Proc Natl Acad Sci U S A*. 2011;108(9):3701-3706.
- Hashizume M, Tan SL, Takano J, et al. Tocilizumab, a humanized anti-IL-6R antibody, as an emerging therapeutic option for rheumatoid arthritis: molecular and cellular mechanistic insights [published online August 6, 2014]. *Int Rev Immunol*.
- Kieseier BC, Stüve O, Dehmel T, et al. Disease amelioration with tocilizumab in a treatment-resistant patient with neuromyelitis optica: implication for cellular immune responses. *JAMA Neurol*. 2013;70(3):390-393.
- Ayzenberg I, Kleiter I, Schröder A, et al. Interleukin 6 receptor blockade in patients with neuromyelitis optica nonresponsive to anti-CD20 therapy. *JAMA Neurol*. 2013;70(3):394-397.
- Araki M, Aranami T, Matsuoka T, Nakamura M, Miyake S, Yamamura T. Clinical improvement in a patient with neuromyelitis optica following therapy with the anti-IL-6 receptor monoclonal antibody tocilizumab. *Mod Rheumatol*. 2013;23(4):827-831.
- Araki M, Matsuoka T, Miyamoto K, et al. Efficacy of the anti-IL-6 receptor antibody tocilizumab in neuromyelitis optica: a pilot study. *Neurology*. 2014;82(15):1302-1306.
- Lauenstein AS, Stettner M, Kieseier BC, Lensch E. Treating neuromyelitis optica with the interleukin-6 receptor antagonist tocilizumab. *BMJ Case Rep*. 2014;bcr2013202939. doi:10.1136/bcr-2013-202939.
- Rose-John S, Gold R. Devic disease: translational medicine at work. *Neurology*. 2014;82(15):1294-1295.
- Wingerchuk DM, Lennon VA, Pittock SJ, Lucchinetti CF, Weinshenker BG. Revised diagnostic criteria for neuromyelitis optica. *Neurology*. 2006; 66(10):1485-1489.
- Kurtzke JF. Rating neurologic impairment in multiple sclerosis: an Expanded Disability Status Scale (EDSS). *Neurology*. 1983;33(11):1444-1452.
- Jarius S, Probst C, Borowski K, et al. Standardized method for the detection of antibodies to aquaporin-4 based on a highly sensitive immunofluorescence assay employing recombinant target antigen. *J Neurol Sci*. 2010;291 (1-2):52-56.
- Van Wagoner NJ, Benveniste EN. Interleukin-6 expression and regulation in astrocytes. *J Neuroimmunol*. 1999;100(1-2):124-139.
- Kaplin AI, Deshpande DM, Scott E, et al. IL-6 induces regionally selective spinal cord injury in patients with the neuroinflammatory disorder transverse myelitis. *J Clin Invest*. 2005;115(10):2731-2741.
- Zhang H, Bennett JL, Verkman AS. Ex vivo spinal cord slice model of neuromyelitis optica reveals novel immunopathogenic mechanisms. *Ann Neurol*. 2011;70(6):943-954.
- Bennett JL, Lam C, Kalluri SR, et al. Intrathecal pathogenic anti-aquaporin-4 antibodies in early neuromyelitis optica. *Ann Neurol*. 2009;66(5):617-629.
- Jarius S, Aboul-Enein F, Waters P, et al. Antibody to aquaporin-4 in the long-term course of neuromyelitis optica. *Brain*. 2008;131(pt 11):3072-3080.
- Kanamori Y, Nakashima I, Takai Y, et al. Pain in neuromyelitis optica and its effect on quality of life: a cross-sectional study. *Neurology*. 2011;77(7):652-658.
- Qian P, Lancia S, Alvarez E, Klawiter EC, Cross AH, Naismith RT. Association of neuromyelitis optica with severe and intractable pain. *Arch Neurol*. 2012;69(11):1482-1487.
- Bradl M, Kanamori Y, Nakashima I, et al. Pain in neuromyelitis optica: prevalence, pathogenesis and therapy. *Nat Rev Neurol*. 2014;10(9):529-536.
- Uzawa A, Mori M, Kuwabara S. Cytokines and chemokines in neuromyelitis optica: pathogenetic and therapeutic implications. *Brain Pathol*. 2014;24 (1):67-73.
- Ohtori S, Miyagi M, Eguchi Y, et al. Efficacy of epidural administration of anti-interleukin-6 receptor antibody onto spinal nerve for treatment of sciatica. *Eur Spine J*. 2012;21(10):2079-2084.
- Smolen JS, Beaulieu A, Rubbert-Roth A, et al; OPTION Investigators. Effect of interleukin-6 receptor inhibition with tocilizumab in patients with rheumatoid arthritis (OPTION study): a double-blind, placebo-controlled, randomised trial. *Lancet*. 2008; 371(9617):987-997.
- Besada E. Potential patient benefit of a subcutaneous formulation of tocilizumab for the treatment of rheumatoid arthritis: a critical review. *Patient Prefer Adherence*. 2014;8:1051-1059.