



Comments? Questions?

Email: [compendium@medimedia.com](mailto:compendium@medimedia.com)

Web: [VetLearn.com](http://VetLearn.com) • Fax: 800-556-3288

CE

Article #2 (1.5 contact hours)

Refereed Peer Review

## KEY FACTS

- Ultrasonography is a valuable tool for diagnosis of intestinal foreign bodies.
- Proper fluid and electrolyte administration is essential for management of patients with intestinal foreign bodies.
- Asymptomatic cats with linear foreign bodies may be managed conservatively.

# Intestinal Foreign Bodies in Dogs and Cats

Aristotle University of Thessaloniki  
Thessaloniki, Greece

L. G. Papazoglou, DVM, PhD, MRCVS

M. N. Patsikas, DVM, PhD, DECVDI

T. Rallis, DVM, PhD

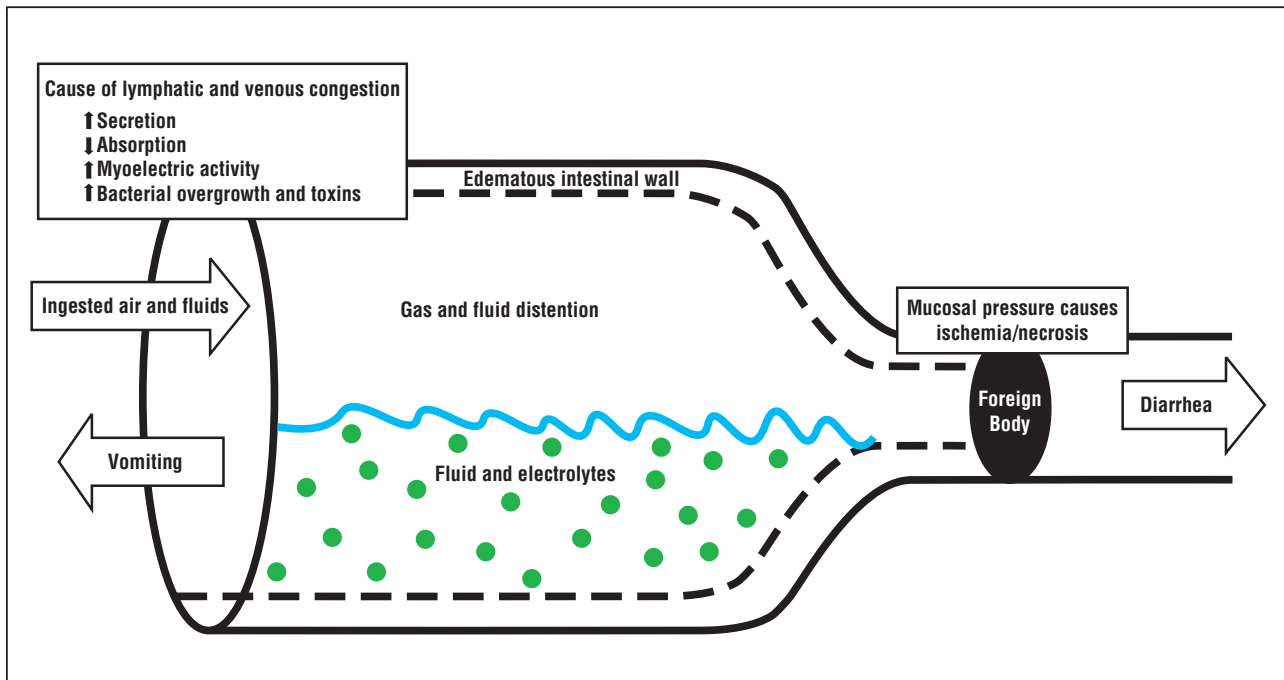
**ABSTRACT:** Intestinal foreign bodies are some of the most common causes of intestinal obstruction in dogs and cats. The size of the foreign body determines whether obstruction is partial or complete. Life-threatening complications caused by fluid and electrolyte imbalances, hypovolemia, and toxemia may be associated with intestinal foreign bodies. Diagnosis is made on the basis of clinical signs and results of radiography and ultrasonography and is confirmed by abdominal exploration. Most foreign bodies can be removed through one or more enterotomies.

Dogs and cats may ingest foreign bodies (FBs) that cause intestinal obstruction, which is one of the most common intestinal disorders requiring emergency surgical treatment. FBs may lodge in any part of the intestinal tract; obstruction most often develops in the small intestine when the luminal diameter becomes smaller.

FB obstruction may be classified<sup>1-3</sup> on the basis of:

- Degree of obstruction (complete or partial)
- Location of obstruction along the intestinal tract (proximal or “high”; middle; distal, or “low”; and colonic)
- Pathophysiologic alterations (simple, or mechanical, versus strangulating)

The degree of obstruction is usually dictated by the size of the FB. Small irregular or linear FBs can cause partial obstruction (with limited passage of fluid or gas), whereas complete obstruction may be attributed to large circular FBs. A high intestinal obstruction involves the duodenum or upper jejunum; a middle intestinal obstruction, the middle jejunal region; and a low intestinal obstruction, the distal small intestine. FBs usually induce simple (or mechanical) intestinal obstruction in which no compromise in the intestinal wall blood supply occurs. A strangulating obstruction, which is usually complete, involves impairment of the blood supply of the involved intestinal segment. However, in clinical situations few obstructions are purely simple because there is almost always some form of vascular impairment in the affected region of the intestinal wall.<sup>3</sup> Knowledge of pathophysiology is essential for correct diagnosis and quick and systematic treatment of the patient with suspected intestinal obstruction.



**Figure 1**—Basic pathophysiologic mechanisms of FB-induced intestinal obstruction.

## PATHOPHYSIOLOGY

Intestinal obstruction involves a complex interaction of local and systemic factors<sup>1,2,4,5</sup> (Figure 1), which remain partly obscure. Life-threatening complications result because of fluid, acid–base, and electrolyte imbalances, hypovolemia, and toxemia.<sup>4,6</sup>

In complete simple intestinal obstruction, accumulation of gas and fluid contributes to luminal distention proximal to the obstruction.<sup>1,7</sup> Most of the gas is swallowed air (70% nitrogen, 10% to 12% oxygen, and 1% to 3% hydrogen); carbon dioxide (6% to 9%) formed as a result of bicarbonate neutralization in the intestinal lumen; and organic gases (methane [1%] and hydrogen sulfide [1% to 10%]) derived from bacterial fermentation.<sup>1</sup> Gaseous luminal distention gradually increases because nitrogen is not absorbed by the intestinal mucosa.<sup>3</sup>

Accumulating fluids come from two sources: an increased amount of secretion in the upper gastrointestinal tract (saliva and bile, and gastric, pancreatic, and small intestinal secretions) and retention of ingested fluids.<sup>2</sup> Solute absorption is reduced because of lymphatic and venous congestion, increased intraluminal osmolality, and decreased enterocyte turnover rate.<sup>2,8,9</sup> After 24 hours of obstruction, the distended bowel may lose its ability to absorb fluids, and local hypersecretion is observed.<sup>2</sup> Intraluminal fluid volume is increased as the obstruction becomes prolonged.<sup>8</sup> In complete proximal intestinal obstructions, a large quantity of secretions and ingested fluids cannot establish contact with the jejunal

and ileal mucosa for reabsorption.<sup>2</sup> In distal intestinal obstructions, some fluid moves proximally by reverse peristalsis and reaches a nondistended intestinal loop, where normal absorption occurs.<sup>2</sup> Although the pathophysiology of these events has yet to be completely defined, four major mechanisms of hypersecretion and decreased absorption may exist:

- Hypersecretion mediated by enteric bacterial toxins secreted by noninvasive pathogenic bacteria that bind specific enterocyte receptors and stimulate salt and water production via the messenger cAMP or cyclic guanosine monophosphate pathways<sup>4,5</sup>
- Increased concentrations of bile and fatty acids and products of tissue ischemia at the obstruction site<sup>4</sup>
- Increased blood flow in the proximal parts of the intestinal obstruction that may stimulate secretory activity<sup>10</sup>
- Release of serotonin (5-hydroxytryptamine) by enteroendocrine cells that may be stimulated by increased luminal distention, which activates reflex pathways that increase chloride ion secretion<sup>11</sup>

Moreover, chemical mediators of the enteric nervous system, such as acetylcholine, vasoactive intestinal polypeptide, and substance P, activate chloride ion–rich fluid secretion by various mechanisms.<sup>5,12,13</sup>

The effects of luminal distention are related to the increasing intraluminal pressure generated proximal to

the intestinal obstruction and to the duration of the obstruction.<sup>1</sup> Intraluminal pressure proximal to the obstruction increases gradually because of fluid and gas accumulation (Figure 1). The arterial circulation is not affected, but capillary bed congestion may occur and lead to elevated hydrostatic pressure that produces intestinal wall edema.<sup>3</sup> In addition, fluid can be extravasated through the serosal surface to the peritoneal cavity.<sup>2</sup> Experimental studies with dogs documented selective mucosal ischemia after simple intestinal obstruction, when intraluminal pressure rose above 40 mm Hg.<sup>14</sup> At a pressure of 44 mm Hg, the blood supply to the intestinal segment may be severely compromised so that blood is shunted away from intestinal capillaries and into arteriovenous anastomoses. In spontaneous intestinal obstruction, full-thickness necrosis of the intestinal wall may not be seen in the dilated proximal segment because intraluminal pressure is apparently below 50 mm Hg.<sup>14</sup> Large FBs, because of the pressure that they apply on the intestinal wall, may cause venous stasis and edema followed by arterial flow compromise, ulceration, necrosis, and perforation.<sup>1</sup> Also, linear FBs may cause increased peristaltic activity proximal and distal to the obstruction site and contribute to intestinal wall laceration.<sup>1</sup>

Intestinal luminal distention causes increased myoelectric activity proximal to the obstruction and a simultaneous decrease distally.<sup>15</sup> As the duration of obstruction is prolonged, clusters of intense myoelectric activity that migrate distally are interrupted by periods of absent motor activity. These periods of inactivation may represent a protective mechanism because uninhibited hyperperistalsis may result in elevated intraluminal pressure that can lead to ischemia and rupture.<sup>15</sup> Increased myoelectric activity proximal to an intestinal obstruction appeared to be cholinergically mediated, whereas noncholinergic nonadrenergic pathways may mediate distal inhibition of spike bursts.<sup>16</sup>

Simple intestinal obstruction may cause an increase in the intraluminal pathogenic bacterial population as a result of stasis or loss of the migratory myoelectric complex, which helps move intestinal contents distally and keeps bacterial numbers low.<sup>2,4</sup> Prolonged and severe luminal distention may impair the enteric mucosal barrier and result in increased permeability and entry of bacteria and toxins into the systemic circulation, causing endotoxic shock, or into the peritoneal cavity, resulting in septic peritonitis.<sup>1</sup> Prompt decompression of obstruction is advisable because it allows quick mucosal regeneration.<sup>14</sup>

A significant amount of fluids and electrolytes can be lost in simple obstruction, which results in hypovolemia and electrolyte and acid–base imbalances.<sup>1</sup> The volume of

fluid lost and its metabolic effects depend on the degree, location, and duration of the intestinal obstruction. Fluid and electrolyte losses are caused by vomiting, sequestration in the intestinal lumen, diarrhea, intestinal wall edema, and extravasation into the peritoneal cavity.<sup>3,4</sup>

Clinical signs of partial intestinal obstruction are associated with maldigestion and malabsorption of nutrients (stagnant loop syndrome). Diarrhea may be attributed to combined osmotic effects of unabsorbed substances in the intestinal lumen and to secretory activity of enterocytes.<sup>6,9</sup> FB-induced colonic obstruction is usually partly due to distensibility of the colon and its slightly rhythmic segmentation.<sup>3</sup> Obstruction causes large quantities of feces to accumulate in the colon and water and electrolyte absorption to take place, often prolonging the course of the disease.<sup>6</sup>

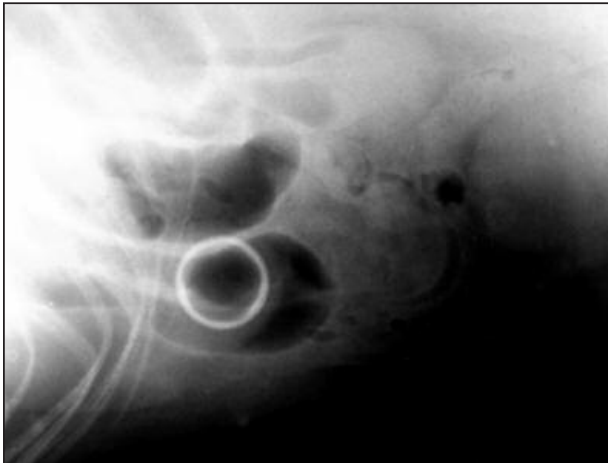
## NONLINEAR FOREIGN BODIES

Dogs, especially young dogs (mean age, 3.5 to 3.7 years),<sup>17</sup> may ingest a large variety of nonlinear FBs.<sup>4,17,18</sup> Young dogs commonly chew on objects, and the recent disappearance of an object may raise suspicion of intestinal obstruction. In dogs, the nonlinear FBs most often encountered include stones, plastics, fabrics, coins, rubber objects, food wrappings, toys, bottle caps, fish hooks, sewing needles, marbles, corn cobs, hairballs, fruit seeds, tampons, and bones.<sup>4,17,18</sup> In cats, however, ingestion of nonlinear FBs, except trichobezoars, is rare.<sup>19</sup> Round smooth FBs, such as balls, may cause complete intestinal obstruction and pressure necrosis of the intestinal wall. Sometimes, if they move down the intestine, these objects can cause intestinal edema.<sup>3</sup> Sharp FBs may penetrate the intestinal wall and cause septic peritonitis and adynamic ileus.

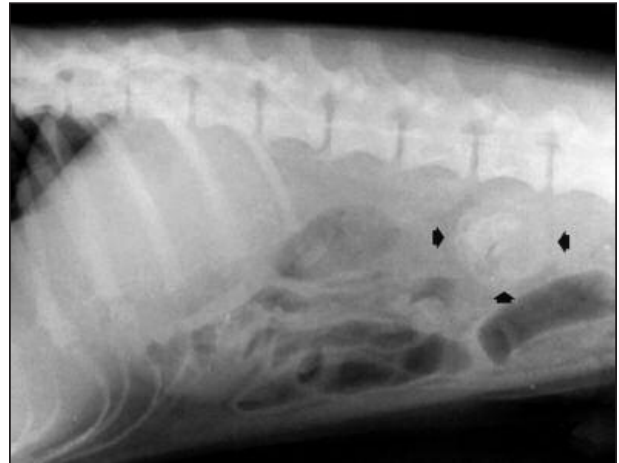
## Diagnosis

### *Clinical Signs and Physical Examination Findings*

The clinical picture and survival associated with intestinal obstruction depend on the degree of obstruction, location of obstruction, and changes in intestinal blood flow.<sup>6</sup> Complete obstructions are usually more acute than are partial obstructions, proximal obstructions are more acute than are distal obstructions, and strangulating obstructions are more severe than are simple obstructions.<sup>6</sup> Common clinical signs include anorexia, dehydration, depression, abdominal pain or discomfort, and vomiting.<sup>17,20</sup> Intestinal obstruction should be included in the differential diagnosis of a patient with acute vomiting, chronic diarrhea, acute abdomen, and weight loss. The differential diagnosis includes acute gastritis, intussusception, acute pancreatitis, peritonitis, and parvoviral enteritis in young dogs.



**Figure 2**—Lateral abdominal radiograph showing a plastic FB in the small intestine of a dog.



**Figure 3**—Lateral abdominal radiograph showing a peach seed (*arrowheads*) in the small intestine of a dog.

Vomiting may lead to dehydration and depression. In these situations, signs of malabsorption and maldigestion are noted. In experimental complete proximal intestinal obstruction in dogs and cats, vomiting began within 24 to 72 hours after obstruction.<sup>2,8,21</sup> Profuse vomiting may be seen in complete proximal obstructions, whereas vomiting is usually intermittent in partial distal obstructions and may be seen 2 to 3 days after obstruction.<sup>2</sup> Defecation may be absent<sup>17</sup> or decreased in frequency; bloody stools may occur, with or without mucus. Diarrhea is common in animals with partial intestinal obstruction. Distal intestinal obstruction is characterized by lethargy, anorexia, and weight loss; animals can drink but not eat.<sup>2</sup>

Careful abdominal palpation may or may not reveal the presence of an FB<sup>17,18</sup> and intestinal fluid and gas accumulating proximally. In deep-chested dogs, abdominal palpation is facilitated if the front legs are elevated. Palpation may elicit abdominal pain,<sup>17</sup> and sedation is required for nervous animals. Abdominal auscultation may detect noise resulting from peristaltic rushes or silence in the case of adynamic ileus or peritonitis.<sup>4</sup>

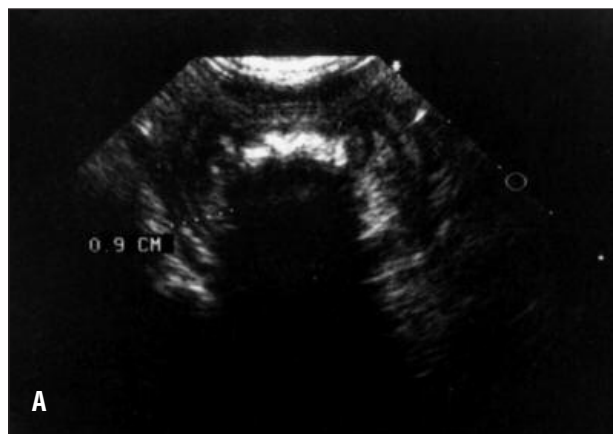The major cause of death in animals with proximal intestinal obstruction may be hypovolemia and acid-base and severe electrolyte imbalances. With no treatment of these disorders, death usually results in 3 to 4 days.<sup>1</sup> If the animal survives, toxemia caused by bacterial proliferation in the obstruction site may also cause death.<sup>6</sup> In distal intestinal obstruction, however, animals may live for 3 weeks or longer if water intake is adequate.<sup>2</sup> Fluid loss and toxemia related to bacterial proliferation are causes of death in complete distal intestinal obstruction. In chronic colonic obstructions, animals become anorectic and die of starvation.<sup>6</sup>

### Laboratory Findings

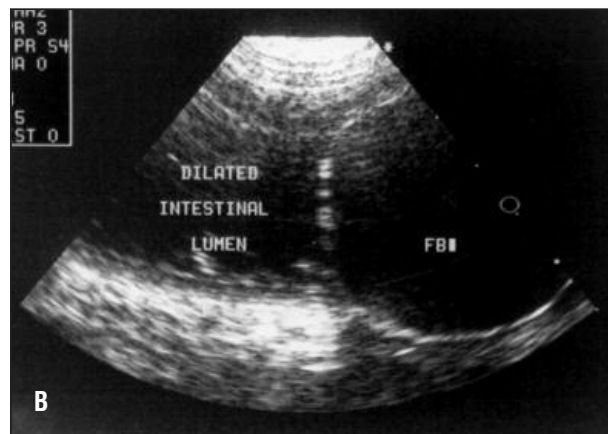
Laboratory findings vary according to the nature of the intestinal obstruction. Packed cell volume and total protein levels may be elevated, and serum albumin concentration may be decreased. Intestinal perforation may cause leukocytosis with a shift to the left. In early stages of pyloric obstruction, vomiting of gastric juices that are rich in potassium, sodium, hydrogen, and chloride ions may result in hypochloremic, hypokalemic, and moderately hyponatremic metabolic alkalosis.<sup>2</sup> Duodenal and proximal jejunal obstructions may be associated with vomiting of intestinal contents containing hydrochloric acid and pancreatic secretions rich in bicarbonate, which results in mild metabolic acidosis and dehydration.<sup>2</sup> In distal intestinal obstruction, proximal intestinal secretions rich in bicarbonate are sequestered at the obstruction site. Bicarbonate loss, dehydration, and starvation contribute to development of metabolic acidosis.<sup>1</sup> In cases of chronic intestinal obstruction, a slight increase in the activity of alanine aminotransferase, alkaline phosphatase, and lipase, as well as in blood urea nitrogen and creatinine concentrations, may be noted.

### Diagnostic Imaging

Radiopaque intestinal FBs can easily be seen in plain radiographs (Figure 2). Certain other nonopaque FBs can be identified on the basis of a typical shape and contained gas lucencies<sup>22</sup> (Figure 3). Diagnosis of radiolucent intestinal FBs is based on radiographic signs of intestinal obstruction. The radiologic diagnosis of FB-induced intestinal obstruction is usually based on signs that may include localized intestinal distention related to gas or fluid accumulation, distended intestinal loops



**Figure 4A**—The irregular curvilinear strong echogenicity that casts a “clear” shadow represents metallic wires obstructing the intestinal lumen.



**Figure 4B**—A rubber ball (*FB*) in the small intestine. The ball has echogenic borders but is anechoic.

**Figure 4**—Two ultrasonographic appearances of intestinal FBs in dogs.

that lie in layers parallel to each other and are connected with sharp hairpin turns, and unequal gas–fluid interfaces seen in a standing lateral projection.<sup>7,23</sup> Distal intestinal obstruction may produce greater distention with more accumulation of fluid or gas compared with proximal intestinal obstruction.<sup>20</sup> The differential diagnosis should include other intraluminal, extraluminal, or intramural causes of intestinal obstruction. Adynamic ileus produced by parvoviral enteritis in young dogs may be considered.<sup>23</sup>

Diagnosis of intestinal distention may be aided by use of the ratio of maximum intestinal diameter to the height of the body of the fifth lumbar vertebra at its narrowest point. Values higher than 1.6 indicate the presence of distention; values higher than 2 indicate a high probability of obstruction.<sup>24</sup> No intestinal distention may be evident in cases of partial obstruction, but accumulation of indigestible material proximal to the obstruction may be noted (“graveling” sign).<sup>4</sup>

In questionable cases, diagnosis requires examination of the intestinal tract with contrast enhancement. A radiolucent area surrounded by contrast material outlining the FB may be visualized. Prolonged gastric emptying or small intestine transit time or complete stasis (depending on the degree of obstruction) characterizes simple intestinal obstruction.<sup>25</sup> Dilution of the barium suspension can be seen in a distended, fluid-filled, proximal intestinal segment.<sup>25</sup> Contrast studies may be repeated at 6-hour intervals after barium administration for diagnosis of most proximal small intestinal obstructions; for repeated studies of most distal small intestinal obstructions, 24-hour intervals are needed.<sup>20</sup> In cases of suspected intestinal perforation, a water-soluble contrast agent rather than barium should

be used for the study.<sup>26</sup> Barium-impregnated polyethylene spheres were developed to assist in the diagnosis of intestinal obstruction in dogs and cats. Radiopaque spheres may have a high sensitivity for diagnosis of chronic partial intestinal obstruction. In acute simple intestinal obstruction, however, spheres are of limited use because they cannot differentiate functional intestinal obstruction from simple.<sup>27</sup>

Ultrasonography appears to be a valuable adjunct to radiography for detection of FBs (Figure 4). Acoustic patterns vary, depending on the physical properties of the FB and interaction with the ultrasound beam. FBs that transmit sound can be accurately detected; strongly attenuating FBs produce acoustic shadows that, if seen in association with the intestinal lumen, can be a useful indicator of an FB.<sup>28</sup>

## Treatment

### Conservative

Some small, sharp FBs, such as pins, sewing needles, and fish hooks, that are found in asymptomatic animals may be treated conservatively and will pass uneventfully, possibly because of the generation of local intestinal dilation (mural withdrawal reflex) in response to contact between the mucosa and this kind of FB.<sup>4</sup> FB transit through the intestinal tract should be monitored radiographically, and the animal should be evaluated clinically on a regular basis to ensure uncomplicated FB passage.<sup>3,20</sup> Movement of the FB through the ileocolic junction is not an indication of complete elimination because colonic or rectal perforation is still possible.<sup>3</sup> Occasionally, a nonlinear FB that causes a large intestinal obstruction may be dislodged endoscopically. Conservative treatment of hairballs in long-haired cats

may include administration of semisolid petrolatum-based laxatives for lubrication and easy aboral elimination of the hairball and introduction of a commercial diet to facilitate passage of ingested hair (e.g., Hill's Science Diet Hairball Control formula).<sup>19</sup>

### **Surgical**

Treatment of FB-induced intestinal obstruction is achieved by exploratory celiotomy. Preoperative stabilization of the patient includes antibiotic prophylaxis and management of fluid, acid-base, and electrolyte imbalances. Prophylactic antibiotics are indicated in animals with intestinal obstruction for two reasons: (1) surgical techniques involving entrance to the intestinal lumen are considered clean-contaminated, and (2) the risk of contamination is high because of bacterial overgrowth. For proximal and midintestinal surgery, first-generation cephalosporins (e.g., cefazolin at 30 mg/kg IV) should be administered. For distal small and large intestine surgery, second-generation cephalosporins (e.g., cefoxitin at 30 mg/kg IV) are recommended. Ideally, antibiotic prophylaxis should commence preoperatively, approximately 30 minutes before the surgical incision, at the time of anesthetic induction; a second dose may be given if surgical time exceeds 1.5 hours.<sup>29</sup>

Fluid therapy aims at correcting dehydration and improving tissue perfusion. The fluid volume and rate of fluid administration depend on the degree of dehydration and the presence of shock. Acid-base and electrolyte values, if available, determine the type of fluid to be administered. In the case of pyloric and proximal intestinal obstruction, administration of 0.9% sodium chloride supplemented with potassium chloride (20 mEq/L) is recommended because of possible alkalosis. Otherwise, lactated Ringer's solution supplemented with potassium chloride (20 mEq/L) is the appropriate replacement fluid.<sup>4</sup> In an experimental study of dogs with intestinal obstruction, colloids were better than crystalloids when large volumes of fluids were required for volume expansion.<sup>30</sup> Plasma oncotic pressure and net loss of fluid into the dilated intestinal lumen were decreased after crystalloid administration, whereas with colloids the plasma oncotic pressure increased temporarily and the jejunum was allowed to maintain normal absorptive capacity.<sup>30</sup>

A ventral midline celiotomy of sufficient length to allow adequate inspection of the abdomen should be performed. The FB can be localized by evaluation of the entire intestinal tract. The most common obstruction sites in order of frequency are the jejunum, ileum, and duodenum.<sup>17,18</sup> When complete intestinal obstruction is present, marked intestinal distention proximal to the obstruction may be seen, and congestion or cyanosis

characterizes the distended intestinal loops. The affected intestinal segment is exteriorized and isolated from the other viscera by moistened laparotomy sponges. Intestinal viability may be best assessed after decompression of the distended loops and removal of the FB.

An enterotomy distal to the FB is performed in the antimesenteric border, and the FB is removed. Incisions over the FB or proximal to the obstruction in the distended intestine may interfere with normal intestinal healing, possibly because of some degree of vascular compromise of the intestinal wall, and therefore such incisions are not recommended.<sup>20</sup> The enterotomy is closed in a single layer with a simple interrupted or continuous approximating pattern,<sup>31</sup> by using 3-0 or 4-0 synthetic absorbable sutures (polydioxanone, polyglyconate). Monofilament nonabsorbable sutures such as polypropylene or skin staples may also be used. Suture bites are spaced 2 to 3 mm from the incision edges and 3 to 4 mm apart.<sup>32</sup> After closure, the enterotomy is lavaged with warm sterile saline, and omentum is put around the incision to prevent leakage. Serosal patch reinforcement is advised for the contused intestinal wall to prevent postoperative leakage. For enterotomies in an intestinal loop with a small diameter, a transverse closure is preferable to a longitudinal one to avoid stenosis. On rare occasions, FBs such as needles, bones, and hairballs that are entrapped in the colon wall require colotomy for removal. Most colonic FBs can be milked distally to a point where they may be retrieved by using long forceps inserted through the anus.

In most cases of simple intestinal obstruction, intestinal viability is preserved, and the appearance of dark distended loops improves as soon as decompression and FB removal are achieved.<sup>2</sup> If nonviable tissue is present, intestinal resection and anastomosis are required. Clinical criteria for intestinal viability assessment may include wall color, presence of arterial pulsations, or peristaltic contractions induced by a mechanical stimulation such as a pinch.<sup>2</sup> However, these criteria do not give consistently accurate results.<sup>26</sup> Fluorescein dye (20 mg/kg injected IV) viewed by a Wood's lamp may assist in the appreciation of intestinal wall vascularity.<sup>20</sup> If viability is questionable and a significant length of intestine is not involved, intestinal resection and anastomosis would be safer and easier to perform.

Finally, the abdominal cavity is lavaged with warm sterile saline and the celiotomy incision is closed routinely.

### **Postoperative Care and Complications**

Maintenance fluid and electrolyte therapy should continue until the patient starts eating again. Usually, food and water are started 24 hours after surgery, pro-

vided the animal is not vomiting. A bland diet is offered in frequent, small feedings during the day. Early food introduction may provide a source of fluids and electrolytes and may stimulate intestinal motility.

The most common and serious complication after FB removal is dehiscence of the enterotomy incision with subsequent leakage of intestinal contents into the peritoneal cavity, resulting in peritonitis. In a study of dogs that underwent enterotomy for FB removal, the postoperative mortality rate in the dehiscence group was 73.7%.<sup>33</sup> Signs of peritonitis may be vague at early stages. Persistent vomiting, pyrexia, tachycardia, abdominal pain, and leukocytosis may be seen and indicate peritonitis. Diagnosis can be based on history, clinical signs, and results of abdominocentesis or diagnostic peritoneal lavage. Abdominal exploration, copious lavage, resection, and anastomosis of the dehisced segment and peritoneal drainage are the recommended treatments.<sup>34</sup> Dehiscence rates in small animals after FB removal in two studies ranged from 6% to 27.7%.<sup>31,33</sup> FB entrapment in the intestinal lumen may compromise blood supply, impair intestinal integrity, and result in dehiscence.<sup>31,33</sup> One study found that the mean time from surgery to dehiscence was 3.9 days, which correlated well with the lag phase of intestinal healing.<sup>33</sup> The same study also found a significantly higher band neutrophil count during the first 4 to 6 postoperative days and a higher incidence of peritonitis in the dehiscence group when compared with a group of animals without dehiscence. Reasons that may contribute to dehiscence include excessive tension on the suture line, sutures placed in nonviable tissue, poorly placed sutures, inappropriate suture material, traumatic tissue handling, and excessive mucosal eversion.<sup>26,31,33</sup> Another study reported no difference in mortality for animals having surgery on the small or large intestine: Both groups of patients had the same risk for dehiscence or bacterial peritonitis.<sup>35</sup>

## LINEAR FOREIGN BODIES

Linear FBs produce a unique type of intestinal obstruction in small animals because they may cause serious and extensive damage to the intestinal tract. Linear FBs are more commonly reported in cats<sup>36-38</sup> than in dogs<sup>36,39</sup>: String and thread were found in cats,<sup>37,38</sup> whereas string, elastic tape, carpet, nylon hosiery, cord, plastics, and fabrics were found in dogs.<sup>36,39</sup> In cats, 90.6% of FBs were thread and 9.4% were thread and needle.<sup>38</sup> Linear FBs initially cause a partial intestinal obstruction; a chronic problem will result in large portions of the small intestine becoming damaged and nonfunctional, which leads to signs similar to those of complete intestinal obstruction.

The pathogenesis of linear FB intestinal obstruction involves fixation of the FB at a cranial site of the digestive tract. Usually, the linear FB either wraps around the base of the tongue or is entrapped in the pylorus. Peristaltic waves continue to move the free end of the FB in a distal direction in the small intestine, with resultant pleating or gathering of the intestine around the FB. Occasionally, secondary intussusception may occur. Intestinal pleating may be explained by the fact that peristaltic waves cause movement of the intestine and intestinal contents in an opposite direction. The small intestine forms circular loops because of mesenteric restriction, and the linear FB, being under tension, tends to arrange in a straight line. The mesenteric border thus becomes firm and edematous as the linear FB is forced against the intestinal wall. Perforation of the affected intestinal loops eventually occurs as the FB cuts through the intestinal wall at the mesenteric border; local or generalized peritonitis ensues.<sup>4,7,36,38</sup>

## Diagnosis

### *Clinical Signs and Physical Examination Findings*

Cats with linear FBs (mean age of 64 cats, 2.7 years<sup>38</sup>; median age of 24 cats, 1 year<sup>37</sup>) are younger than dogs with linear FBs (mean age of 32 dogs, 4.5 years; median age, 2 years<sup>39</sup>). Vomiting and anorexia are common clinical signs<sup>37-39</sup>; bloody diarrhea may also be seen.<sup>4,20,38</sup> Most affected cats may drink small amounts of water, and in many cats the frequency of vomiting decreased as the duration of intestinal obstruction increased.<sup>38</sup> Physical examination findings include depression, fever, dehydration, abdominal pain, a thread looped around the tongue, an FB hanging from the mouth, an FB protruding from the anus, and palpable intestinal plication.<sup>37-39</sup> Thorough oral examination is mandatory for animals with a suspected linear FB intestinal obstruction. An initial physical examination failed to detect the linear FB found at the base of the tongue in 6 of 13 cats that presented with the linear FB lodged sublingually.<sup>37</sup> Nervous animals may need sedation to allow thorough oral inspection. A string was found around the base of the tongue in 50% of affected cats in two reports,<sup>37,38</sup> whereas only 6% of affected dogs had a string revealed by physical examination.<sup>39</sup> Hematologic and biochemical findings in an animal with a linear FB intestinal obstruction are not different from those in an animal with a nonlinear FB intestinal obstruction.

### *Diagnostic Imaging*

Survey abdominal radiographic findings in cats with a linear FB intestinal obstruction include intestinal pli-

cation, increased numbers of eccentrically located comma-shaped or tapered luminal gas bubbles, small intestinal shortening to the right of the midline as viewed ventrodorsally, radiopaque FB visualization, intestinal obstruction, and peritonitis<sup>36,38</sup> (Figure 5). These findings led to a tentative diagnosis of linear FB in 54% of cats in one study.<sup>38</sup> In this study, however, no radiographic abnormalities were seen in 14% of affected cats. It was thought that tapered bubbles possibly resulted from gas-filled intestine that was corrugated around the linear FB.<sup>38</sup>

Radiographic signs of linear FBs in cats may be differentiated from (1) hyperperistaltic activity resulting in symmetric convolutions and formation of centrally located luminal bubbles in the affected intestinal segment (linear FBs, in contrast, cause asymmetric convolutions and eccentrically located gas bubbles<sup>36</sup>); (2) intestinal adhesions after previous intraabdominal surgery<sup>4,36</sup>; and (3) intestinal ascarids, which appeared as luminal linear filling defects but without intestinal pleating.<sup>36</sup> Findings obtained from radiography with contrast enhancement include eccentric plication and shortening of the small intestine, fixation of the duodenum in pleated position, and occasional visualization of eccentrically located gas bubbles<sup>36</sup> (Figure 6).

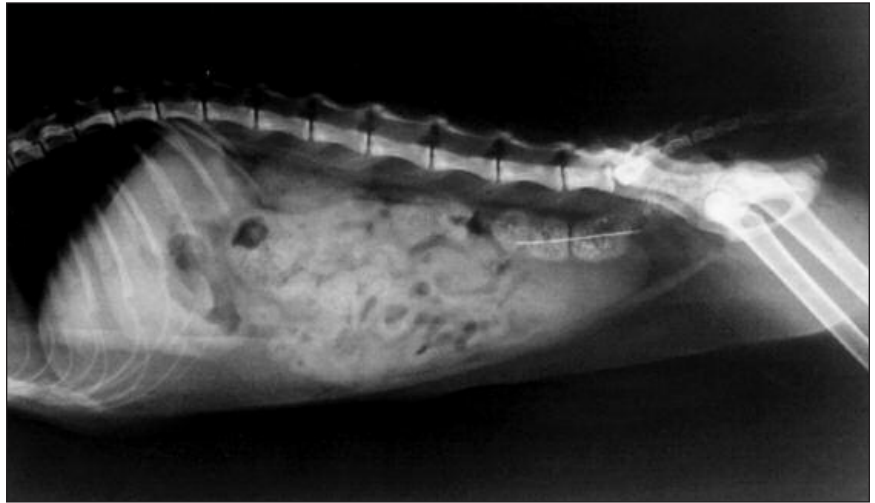Radiographic findings in dogs with a linear FB intestinal obstruction were similar to those of cats. However, on the basis of the same radiographic findings as mentioned above, diagnosis of a linear FB was more common in dogs (71%)<sup>39</sup> than in cats (54%).<sup>38</sup> In addition, the presence of tapered gas bubbles is not a common radiographic finding in dogs.<sup>39</sup> Ultrasonographic examination may detect intestinal plication, which is considered diagnostic for linear FBs. However, linear FBs are not always visualized during this examination.<sup>28</sup>

### Treatment

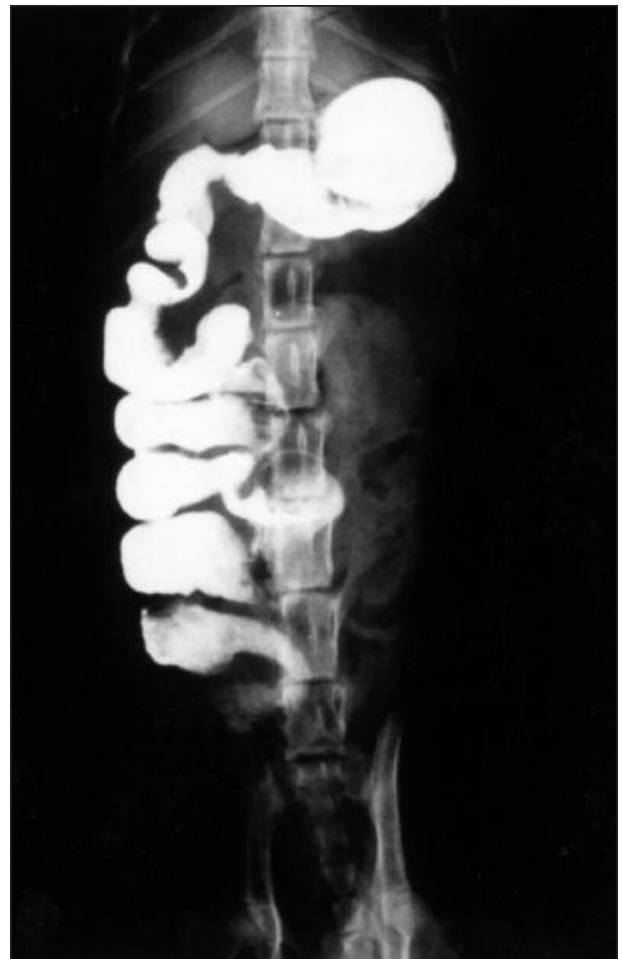
Although most surgeons favor surgical treatment as soon as the diagnosis of linear FB is established, conservative therapy can be tried in selected feline cases.

### Conservative

One study<sup>37</sup> found that 38% of cats that have a linear FB looped around the base of the tongue may be managed conservatively, provided certain criteria are met. The cat must be presented soon after linear FB inges-

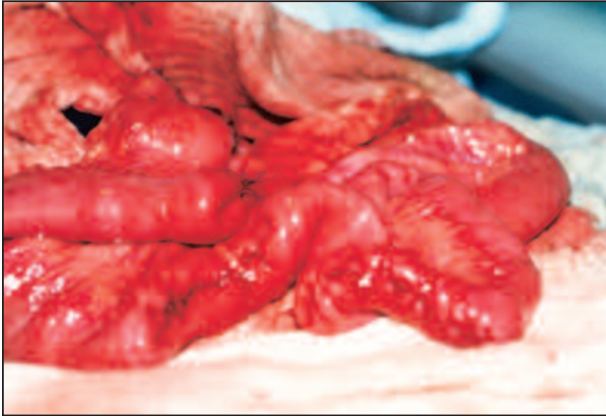


**Figure 5**—Lateral abdominal radiograph of a cat with intestinal plication and tapered gas bubbles resulting from thread and a needle in the small and large intestine, respectively.

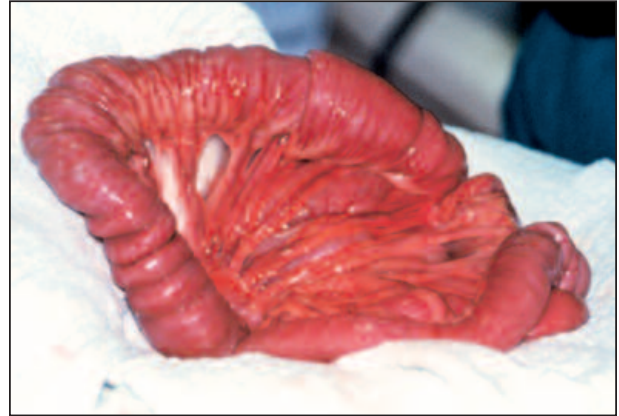

**Figure 6**—Ventrodorsal radiograph of a cat after barium administration showing intestinal plication secondary to a linear FB.





**Figure 7**—Multiple enterotomies are required for removal of a linear FB in a dog.



**Figure 8**—Intestinal plication and intussusception secondary to a linear FB in a dog.

tion and the owner must be aware of the ingestion; if the cat is showing no signs of peritonitis, the linear FB that is embedded sublingually should be cut, which may allow elimination of the linear FB in the feces within 1 to 3 days. Hospitalization of the cat is essential for clinical, radiologic, and laboratory monitoring. Immediate surgical intervention is warranted if the patient's clinical condition deteriorates or if peritonitis or pyloric entrapment of the linear FB occurs.<sup>37</sup>

### **Surgical**

A linear FB that is wrapped around the tongue should be identified and released before a celiotomy. The linear FB may be localized by identifying intestinal plication after a midline celiotomy. Usually, a gastrotomy is required to release a linear FB lodged in the pylorus, a common location in dogs, possibly because of the large size of ingested foreign material in canine species.<sup>39</sup> An enterotomy is performed midway along the site of obstruction. With the aid of a curved mosquito hemostat, a linear FB located in a mesenteric site can be pulled gently and gradually until the more distal point of fixation is reached. Another enterotomy is made at the distal position. Multiple enterotomies, spaced along the intestine, are required to minimize excessive traction and avoid subsequent intestinal perforation and to remove the FB completely<sup>32</sup> (Figure 7).

A single-incision technique has been described for extraction of string in cats, provided no penetration of the mucosa has occurred.<sup>40</sup> An enterotomy is made to the most proximal site of the duodenum, and the linear FB is attached with suture to the end of a red rubber catheter. The entire catheter is placed into the small intestine in a proximal direction, and the incision is closed routinely. The catheter is then milked along the intestine, so that the plicated intestine is resolved and

the linear FB is carried along with the catheter until an assistant retrieves it through the anus. However, failure of this technique in a cat was reported.<sup>41</sup>

The linear FB may compromise the intestinal wall at several sites, which can result in multiple perforations and subsequent peritonitis. If the linear FB has been present for a long period, localized peritonitis and intestinal fibrosis may occur, leading to permanent plication. Those cases may be best managed with intestinal resection and anastomosis. Peritonitis should be managed as described earlier.

Intussusception was reported to accompany linear FBs in dogs, possibly because of increased irritation by the types of linear FBs ingested by dogs or because of different reactions of the canine intestine to linear FBs<sup>39</sup> (Figure 8). Enterotomies may be closed as described earlier or by using skin staples in dogs.<sup>42</sup> The stapling technique reduces time at surgery and minimizes spilling of intestinal contents during surgery.<sup>42</sup> After closure, the entire intestinal tract should be examined for perforations in the mesenteric border. Fat and fibrin deposition may mask intestinal leaks. Normal saline injection into the isolated intestinal segment may facilitate detection of leakage. The abdominal cavity is thoroughly lavaged and is then closed in a routine fashion.

### **Postoperative Care, Complications, and Prognosis**

Postoperative care and complications are similar to those for animals with nonlinear FBs. Short-bowel syndrome may result after resection of 90% of the small intestine.<sup>20,26</sup> After ileocecal valve removal, overgrowth of bacteria that ascend from the colon may contribute to diarrhea.<sup>20</sup> The small intestine that remains after extensive resection may undergo adaptation associated with increased diameter, enlarged microvilli, and

increased numbers of mucosal cells, the result being increased absorption.<sup>20,26</sup>

Mortality rates after surgical removal of linear FBs were higher in dogs (22%)<sup>39</sup> than in cats (16%)<sup>38</sup> because frequencies of perforations and peritonitis were higher in dogs (31%)<sup>39</sup> than in cats (16%).<sup>38</sup> Moreover, a significant prognostic indicator associated with an increased probability of peritonitis in dogs is the presence of fabric and plastic linear FBs.<sup>39</sup> One study reported decreased survival of dogs and cats that underwent more than one intestinal procedure in the same operation.<sup>35</sup> In addition, dogs require an increased number of intestinal resections for linear FB management compared with cats, possibly because of the increased severity of intestinal trauma in dogs.<sup>39</sup>

## REFERENCES

- Lantz GC: The pathophysiology of acute mechanical small bowel obstruction. *Compend Contin Educ Pract Vet* 3:910–918, 1981.
- Ellison GW: Intestinal obstruction, in Bojrab MJ (ed): *Disease Mechanisms in Small Animal Surgery*, ed 2. Philadelphia, Lea & Febiger, 1993, pp 252–257.
- Walshaw R: The small intestine, in Gourley IM, Vasseur PB (eds): *General Small Animal Surgery*. Philadelphia, JB Lippincott, 1985, pp 343–384.
- Guilford WG, Strombeck DR: Intestinal obstruction, pseudo-obstruction, and foreign bodies, in Guilford WG, Center SA, Strombeck DR, et al (eds): *Strombeck's Small Animal Gastroenterology*, ed 3. Philadelphia, WB Saunders, 1996, pp 487–502.
- Jones S, Blivslager A: Role of the enteric nervous system in the pathophysiology of secretory diarrhea. *J Vet Intern Med* 16:222–228, 2002.
- Pass MA: Small intestines—physiology, in Slatter DH (ed): *Textbook of Small Animal Surgery*, ed 1. Philadelphia, WB Saunders, 1985, pp 738–752.
- O'Brien TR: Small intestine, in O'Brien TR (ed): *Radiographic Diagnosis of Abdominal Disorders in the Dog and Cat: Radiographic Interpretation, Clinical Signs, Pathophysiology*. Philadelphia, WB Saunders, 1978, pp 259–351.
- Mishra NK, Appert HE, Howard JM: The effects of distention and obstruction on the accumulation of fluid in the lumen of small bowel of dogs. *Ann Surg* 180:791–795, 1974.
- Guilford WG, Strombeck DR: Classification, pathophysiology and symptomatic treatment of diarrheal diseases, in Guilford WG, Center SA, Strombeck DR, et al (eds): *Strombeck's Small Animal Gastroenterology*, ed 3. Philadelphia, WB Saunders, 1996, pp 351–366.
- Enochsson L, Nylander G, Ohman U: Effects of intraluminal pressure on regional blood flow in obstructed and unobstructed small intestines in the rat. *Am J Surg* 144:558–561, 1982.
- Cooke HJ, Reddix RA: Neural regulation of intestinal electrolyte transport, in Johnson LR (ed): *Physiology of the Gastrointestinal Tract*. New York, Raven, 1994, pp 2083–2132.
- Cullen JJ, Caropreso DK, Hemman LL, et al: Pathophysiology of adynamic ileus. *Dig Dis Sci* 42:731–737, 1997.
- Basson MD, Fielding LP, Bilchik AJ, et al: Does vasoactive intestinal polypeptide mediate the pathophysiology of bowel obstruction? *Am J Surg* 157:109–114, 1989.
- Shikata JI, Shida T, Amino K, Ishioka K: Experimental studies on the hemodynamics of the small intestine following increased intraluminal pressure. *Surg Gynecol Obstet* 156:155–160, 1983.
- Summers RW, Yanda R, Prihoda M, Flatt A: Acute intestinal obstruction: An electromyographic study in dogs. *Gastroenterology* 85:1301–1306, 1983.
- Prihoda M, Flatt A, Summers RW: Mechanisms of motility changes during acute intestinal obstruction in the dog. *Am J Physiol* 247:G37–G42, 1984.
- Capak D, Simpraga M, Maticic D, et al: Incidence of foreign-body-induced ileus in dogs. *Berl Munch Tierarztl Wochenschr* 114:290–296, 2001.
- Clark WT: Foreign bodies in the small intestine of the dog. *Vet Rec* 83:115–119, 1968.
- Barrs VR, Beatty JA, Tisdall PLC, et al: Intestinal obstruction by trichobezoars in five cats. *J Feline Med Surg* 1:199–207, 1999.
- Orsher RJ, Rosin E: Small intestine, in Slatter DH (ed): *Textbook of Small Animal Surgery*, ed 2. Philadelphia, WB Saunders, 1993, pp 593–612.
- Shields R: The absorption and secretion of fluid and electrolytes by the obstructed bowel. *Br J Surg* 52:774–779, 1965.
- Lamb CR, Hansson K: Radiological identification of nonopaque intestinal foreign bodies. *Vet Radiol Ultrasound* 35:87–88, 1994.
- McNeel SV: The small bowel, in Thrall DE (ed): *Textbook of Veterinary Diagnostic Radiology*, ed 2. Philadelphia, WB Saunders, 1994, pp 524–543.
- Graham JB, Lord PF, Harrison JM: Quantitative estimation of intestinal dilation as a predictor of obstruction in the dog. *J Small Anim Pract* 39:521–523, 1998.
- Gomez JA: The gastrointestinal contrast study. *Vet Clin North Am* 4:805–842, 1974.
- Bauer MS, Matthiesen DT: Complications and decision making associated with small intestine surgery. *Probl Vet Med* 1:316–332, 1989.
- Robertson ID, Burbidge HM: Pros and cons of barium-impregnated polyethylene spheres in gastrointestinal disease. *Vet Clin North Am Small Anim Pract* 30:449–465, 2000.
- Tidwell AS, Penninck DG: Ultrasonography of gastrointestinal foreign bodies. *Vet Radiol Ultrasound* 33:160–169, 1992.
- Bright RM: Preoperative antibiotics: Do I or don't I? *Proc ACVS Symp*:260–263, 2001.
- Allen D, Kvietys PR, Granger DN: Crystalloids versus colloids: Implications in fluid therapy of dogs with intestinal obstruction. *Am J Vet Res* 47:1751–1755, 1986.
- Weisman DL, Smeak DD, Birchard SJ, Zweigart SL: Comparison of a continuous suture pattern with a simple interrupted pattern for enteric closure in dogs and cats: 83 cases (1991–1997). *JAVMA* 214:1507–1510, 1999.
- Ellison GW: Enterotomy, in Bojrab MJ (ed): *Current Techniques in Small Animal Surgery*, ed 4. Baltimore, Williams & Wilkins, 1998, pp 245–248.

33. Allen DA, Smeak DD, Schertel ER: Prevalence of small intestinal dehiscence and associated clinical factors: A retrospective study of 121 dogs. *JAAHA* 28:70–76, 1992.
34. Papazoglou LG, Rallis T: Diagnosis and surgical management of septic peritonitis in the dog and cat. *Waltham Focus* 11:9–14, 2001.
35. Wyllie KB, Hosgood G: Mortality and morbidity of small and large intestinal surgery in dogs and cats: 74 cases (1980–1992). *JAAHA* 30:469–474, 1994.
36. Root CR, Lord PF: Linear radiolucent gastrointestinal foreign bodies in cats and dogs: Their radiographic appearance. *J Am Vet Radiol Soc* 12:45–53, 1971.
37. Basher AWP, Fowler JD: Conservative versus surgical management of gastrointestinal linear foreign bodies in the cat. *Vet Surg* 16:135–138, 1987.
38. Felts JE, Fox PR, Burk RL: Thread and sewing needles as gastrointestinal foreign bodies in the cat: A review of 64 cases. *JAVMA* 184:56–59, 1984.
39. Evans KL, Smeak DD, Biller DS: Gastrointestinal linear foreign bodies in 32 dogs: A retrospective evaluation and feline comparison. *JAAHA* 30:445–450, 1994.
40. Anderson S, Lippincott CL, Gill PJ: Single enterotomy removal of gastrointestinal linear foreign bodies. *JAAHA* 28:487–490, 1992.
41. Muir P, Rosin E: Failure of the single enterotomy technique to remove a linear intestinal foreign body from a cat. *Vet Rec* 136:75, 1995.
42. Coolman BR, Ehrhart N, Marretta SM: Use of skin staples for rapid closure of gastrointestinal incisions in the treatment of canine linear foreign bodies. *JAAHA* 36:542–547, 2000.

### ARTICLE #2 CE TEST

The article you have read qualifies for 1.5 contact hours of Continuing Education Credit from the Auburn University College of Veterinary Medicine. *Choose the best answer* to each of the following questions; then mark your answers on the postage-paid envelope inserted in *Compendium*.

1. Which factors contribute to luminal distention in complete intestinal obstruction?
  - a. gas accumulation
  - b. fluid accumulation related to hypersecretion in the gastrointestinal tract
  - c. fluid accumulation related to reduced absorption in the gastrointestinal tract
  - d. all of the above
2. Experimental studies of dogs with intestinal obstruction showed selective intestinal mucosal ischemia when intraluminal pressure was
 

a. 10 mm Hg.	c. higher than 40 mm Hg.
b. 30 mm Hg.	d. 80 mm Hg.
3. Fluid and electrolyte losses in intestinal obstruction may be the result of
  - a. vomiting.
  - b. diarrhea.
  - c. fluid sequestration in the intestinal lumen.
  - d. all of the above

4. Vomiting in a dog with distal intestinal obstruction may result in
    - a. metabolic alkalosis.
    - b. metabolic acidosis.
    - c. hypokalemic metabolic alkalosis.
    - d. hypochloremic metabolic alkalosis.
  5. Which antibiotic is recommended for prophylactic use in surgery on the large intestine?
    - a. cefalexin
    - b. ceftiofur
    - c. cefazolin
    - d. cefadroxil
  6. Which characteristic is not used for assessment of intestinal viability?
    - a. wall thickness
    - b. wall color
    - c. appearance with IV fluorescein dye
    - d. arterial pulsations
  7. \_\_\_\_\_ may increase the possibility of dehiscence after enterotomy closure.
    - a. Minimal mucosal eversion
    - b. Excessive mucosal eversion
    - c. Atraumatic tissue handling
    - d. Lack of tension on the suture line
  8. Cats with linear FB ingestion may be managed conservatively if they
    - a. present soon after ingestion and have no signs of peritonitis.
    - b. show signs of acute abdomen.
    - c. show signs of pyloric obstruction.
    - d. have chronic hemorrhagic diarrhea.
  9. Which approach is not recommended for enterotomy closure?
    - a. simple continuous approximating suture pattern
    - b. simple interrupted approximating suture pattern
    - c. skin staples
    - d. wound glue
  10. In patients with linear FBs, intestinal resection and anastomosis are recommended for treatment of
    - a. multiple perforations and subsequent peritonitis.
    - b. intestinal fibrosis and permanent plication.
    - c. extensive intestinal wall compromise.
    - d. all of the above
-