

In collaboration with the American College of Veterinary Surgeons

Suspensory Ligament Rupture Technique During Ovariohysterectomy in Small Animals

Lawrence N. Hill, DVM, DABVP
The Ohio State University

Daniel D. Smeak, DVM, DACVS^a
Colorado State University

Abstract: During ovariohysterectomy, suspensory ligament (SL) rupture permits retraction of the ovary and distal ovarian pedicle through a limited ventral midline incision. This allows the surgeon to confirm that the pedicle is securely double ligated and includes no ovarian remnant. For less experienced surgeons, SL rupture is often difficult and daunting because the ligament is buried within the abdominal viscera and must be identified blindly by palpation. Furthermore, in dogs, the ligament must be digitally disrupted, which may cause hemorrhage and serious injury to surrounding structures such as the ovarian pedicle. This article describes step-by-step techniques to disrupt the SL in dogs and cats. We have found that these techniques can be taught easily and successfully to novice surgeons.

Ovariohysterectomy is the most common elective surgical procedure performed by small animal practitioners.^{1,2} In young, healthy patients, the technique can be performed safely through a small ventral midline laparotomy incision to save time and reduce trauma. This limited approach makes exposure of the ovarian pedicle for ligation one of the most challenging aspects of ovariohysterectomy, particularly for inexperienced solo surgeons. Exposure is vitally important because the surgeon must ensure that the pedicle is securely double ligated and includes no ovarian remnant. In dogs and cats, the suspensory ligament (SL) tethers the ovary to the dorsal abdominal cavity.

SL rupture is performed only when it is not possible to expose enough ovarian pedicle for safe ligation. In some dogs and cats—particularly animals that are pregnant or have an enlarged uterus—and depending on the extent of the abdominal approach, it is possible to expose enough ovarian pedicle for ligation without SL rupture. However, SL rupture is usually required to allow retraction of the ovary and distal ovarian pedicle through the small abdominal incision, especially in deep-chested dogs.

Experienced surgeons familiar with the anatomy and the amount of force required to disrupt the SL have adopted

^aDr. Smeak discloses that he has received financial benefits from Covidien.

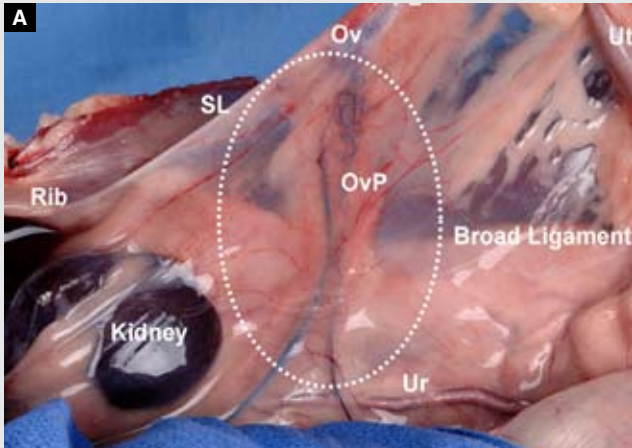
many different ways to safely control the rupture of this structure. For inexperienced surgeons, however, the procedure is often daunting and difficult because the ligament is buried within the abdominal viscera and must be identified blindly by palpation. Additionally, in dogs, the SL must be digitally disrupted with considerable force, creating the potential for serious damage to other soft tissue structures, particularly the vascular pedicle of the ovary.

In veterinary school circles, the process of SL rupture with the index finger is commonly referred to as “strumming” or stretching the ligament. Simply pulling on the SL will rupture it, but the region of disruption is not controlled, and excess tension can cause complete avulsion of the ovarian pedicle and serious bleeding. Using the techniques described in this article, inexperienced surgeons can disrupt the ligament safely with one controlled motion.

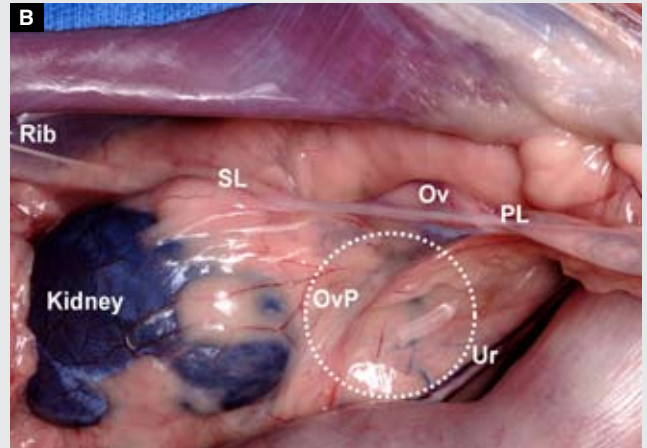
We acknowledge that many successful methods of rupturing the SL exist.³⁻⁵ In this article, we describe how we teach two different techniques for performing a “controlled” SL rupture in small animals and explain the rationale for each technique. We have found these techniques particularly useful when teaching novice surgeons. In dogs, we prefer to rupture the SL at its craniodorsal attachment to the abdominal wall because this area is furthest from important vascular structures, which helps reduce the risk of signifi-

FIGURE 1

Canine surgical anatomy. The left abdominal wall has been incised and reflected laterally for exposure. *Ov* = ovary, *OvP* = ovarian pedicle, *PL* = proper ligament, *SL* = suspensory ligament, *Ur* = ureter, *Ut* = uterus. The dashed circle indicates the mesovarium area.



A Upward (ventral) traction on the uterus exposes the left ovary and important surrounding structures.



B Caudal traction on the uterus shows a tight left SL attachment to the caudal ribs, a loose ovarian pedicle, and reflection of the mesovarium to the left kidney capsule.

Images © The Ohio State University

cant hemorrhage. Unlike dogs, cats do not have deep chests and have very little fat around the mesovarium, allowing the SL to be readily distinguished from surrounding tissue; therefore, in cats, the SL can be disrupted sharply close to the ovary. For orientation purposes, the images in this article show the patient with the cranial part of the abdomen to the left, except where noted.

Surgical Anatomy

The ovaries, oviducts, and uterine horns are attached to the

dorsal abdominal wall by paired double folds of peritoneum called the right and left *broad ligaments*⁶ (**FIGURE 1A**). Within the free cranial border of the mesovarium, between two layers of peritoneum, lies the SL. It is continued caudally by the proper ligament of the ovary, which is a strong fibrous ligament between the uterine horn and ovary. In dogs, the proper ligament has significant strength and can be safely clamped with hemostatic forceps and held firmly to stabilize and retract the ovary and SL. In cats, the proper ligament is fragile, so retraction of this structure must be performed carefully to avoid complete separation of the ovary from the oviduct and uterine horn; hemorrhage; and inadvertent ovarian fragmentation. The SL spans the distance from the ovary to the rib cage and attaches to the middle and dorsal thirds of the last two ribs (**FIGURE 1**). It must be distinguished from the peritoneal reflections of the mesovarium to the caudal pole of the kidney (see the area below, or dorsal to, the SL in **FIGURE 1**). In dogs, a considerable amount of fat within the mesovarium conceals the ovarian blood supply and SL. In cats, the mesovarium is not laden with fat, so structures within it are easily observed (**FIGURE 2**). Because the left kidney is more caudal in the abdominal cavity than the right, the left ovary is usually the most easily retracted and exposed first. For the purposes of this article, the ovarian pedicle refers to both the arterial and venous structures within the mesovarium.

The ovary is supplied with blood through the ovarian artery, which arises from the aorta caudal to the renal vessels. Within the mesovarium in dogs, the tortuous ovarian veins run close to the ovary, beside the arteries, and drain blood



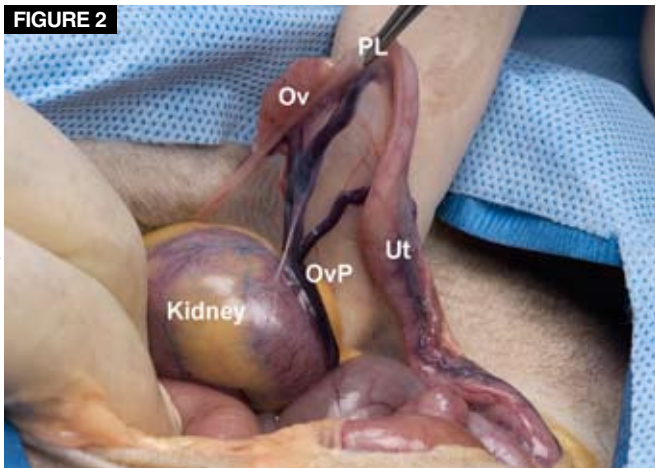
ACVS[®]
AMERICAN COLLEGE of
VETERINARY SURGEONS

Surgical Views is a collaborative series between the American College of Veterinary Surgeons (ACVS) and *Compendium*.

All Surgical Views articles are peer-reviewed by ACVS diplomates.

To locate a diplomate, ACVS has an online directory that includes practice setting, species emphasis, and research interests (acvs.org/VeterinaryProfessionals/FindaSurgeon).

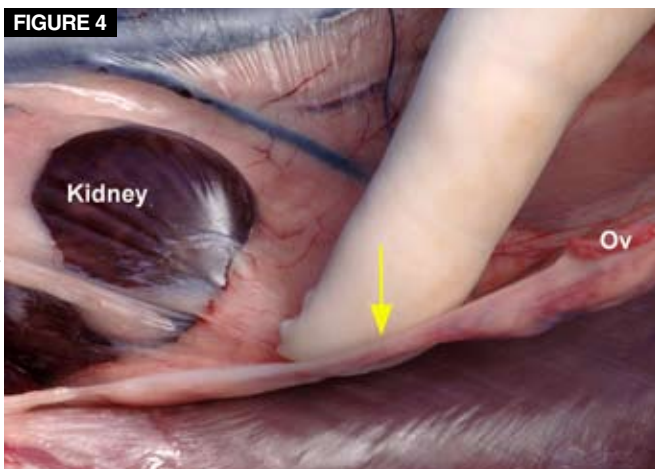
FIGURE 2



© The Ohio State University

Feline surgical anatomy. Left ovary (Ov) and important surrounding structures. OvP = ovarian pedicle, PL = proper ligament, Ut = uterus.

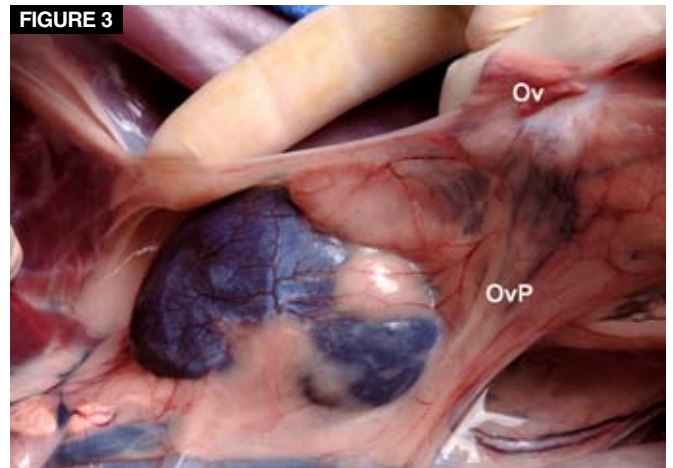
FIGURE 4



© The Ohio State University

Improper medial-to-lateral finger force (arrow) to rupture the right SL in a dog. The right abdominal wall is reflected laterally. Caudal traction on the right uterine horn tightens the SL. Application of excessive force in the direction indicated by the arrow could cause inadvertent avulsion of the ovarian pedicle and rupture of vessels within the mesovarium. Ov = ovary.

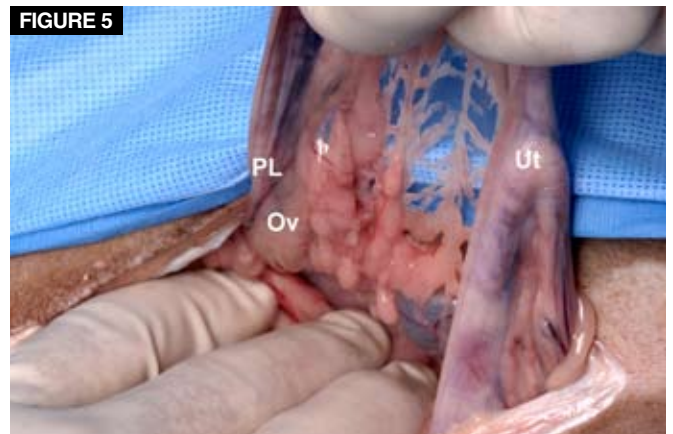
FIGURE 3



© The Ohio State University

Correct lateral-to-medial finger force to rupture the SL in a dog. The left abdominal wall is reflected laterally. Caudal traction on the left uterine horn and ovary (Ov) tightens the SL. Note that blood supply of the ovarian pedicle (OvP) is more obscure than that in the cat in Figure 2; also note the branches to the kidney capsule within the mesovarium (in more obese dogs, the blood supply is totally obscured by fat in the pedicle). No significant vasculature is seen where the SL attaches to the abdominal wall.

FIGURE 5



© The Ohio State University

Typical approach during ovariohysterectomy in a dog. The uterus (Ut) has been retracted from the abdominal cavity to expose the proper ligament (PL) and adjacent left ovary (Ov).

from the ovary and uterus (FIGURE 1A). In cats, the venous drainage is not tortuous and does not branch out as it does in dogs (FIGURE 2). In both species, the right ovarian vein drains directly into the vena cava, and the left ovarian vein drains separately into the left renal vein. Within the canine mesovarium, the indistinct ovarian vasculature also supplies considerable branches to the adipose tissue and capsule of the kidney (FIGURE 3). Blood supply in these branches can be significant, especially during pregnancy and in association with uterine diseases such as neoplasia and pyometritis. Therefore, the portion of the mesovarium attaching to the kidney must be avoided while isolating and disrupting the SL in dogs. Several current veterinary textbooks illustrate

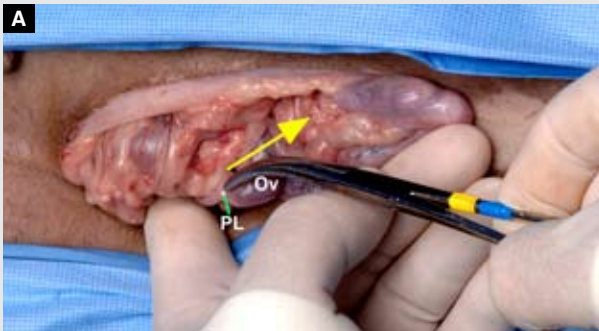SL rupture by depicting the surgeon tearing the “ligament” (mesovarium) that appears to be attached to the kidney.^{3,5} In cats, ovarian pedicle branches are rarely found extending to the renal capsule, and the SL is distinct, so it is safe to disrupt the SL near the attachment to the ovary (FIGURE 2).

Intuitive Technical Mistakes During Suspensory Ligament Rupture in Dogs

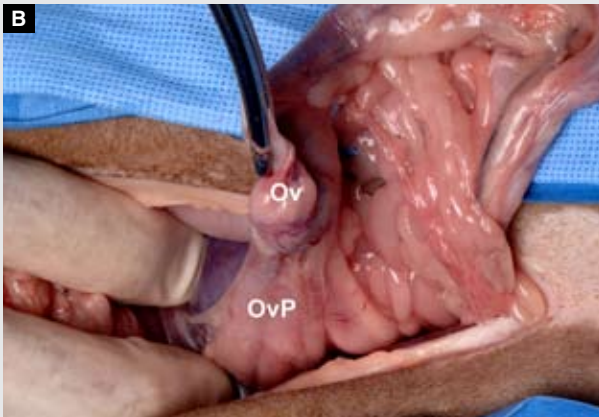
In our experience, novice surgeons, who are less familiar with surrounding anatomy, do not want to tear structures they cannot see. Particularly in deep-chested dogs, the SL is often confused with the reflections of the mesovarium

FIGURE 6

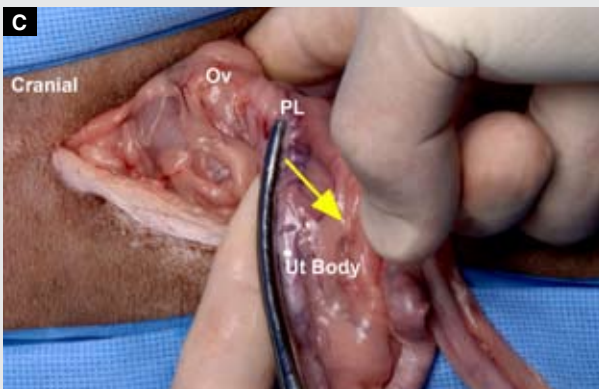Typical approach during ovariectomy in a dog.
The surgeon is standing on the patient's right side (cranial is to the left). (Ov = ovary; PL = proper ligament)



The right hand puts caudomedial tension (arrow) on the right SL. The left index finger rides (or courses) along the lateral aspect of the tense SL to the right dorsal abdominal wall.



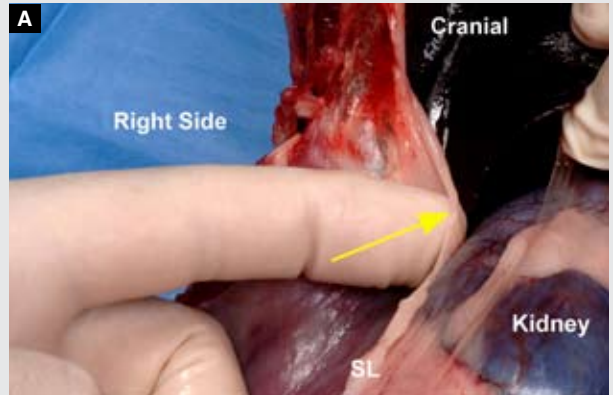
Once the SL has been ruptured, the right ovary is fully exposed and the ovarian pedicle (OvP) is ready for ligation.



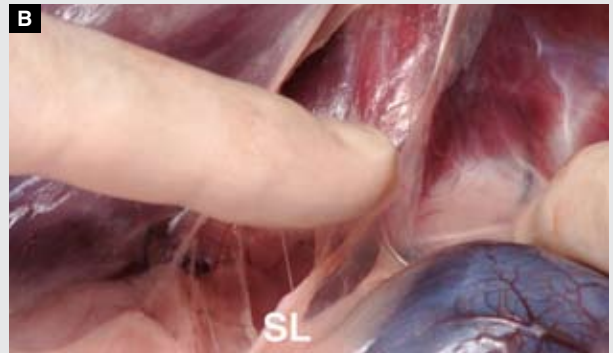
To rupture the left SL, the surgeon places caudomedial tension on the SL with the left hand, while the right index finger rides along the lateral surface of the left SL toward the abdominal wall attachment.

FIGURE 7

Close-up view of the right SL in a dog.
The right abdominal wall has been incised and reflected laterally (cranial is at the top of the image).

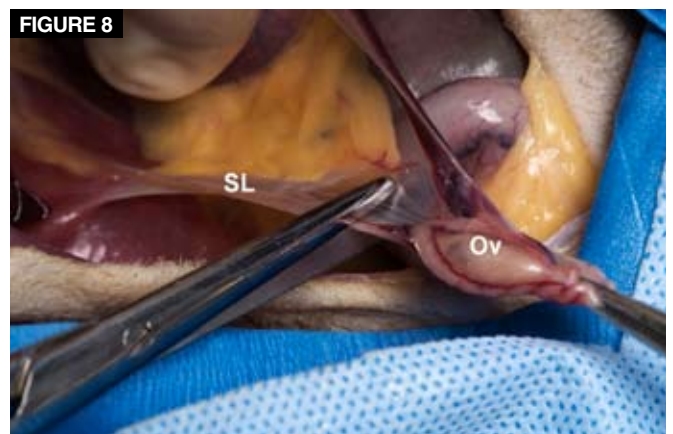

While constant caudomedial tension is placed on the right SL, the left index finger is thrust in a craniomedial direction (arrow) toward the kidney, well away from the ovarian pedicle.



The left SL is ruptured at its broad attachment to the dorsal abdominal wall.

FIGURE 8



Incision of the right SL in a cadaver cat. The right abdominal wall is retracted laterally. Caudal tension is placed on the SL, which is sharply incised where it can be seen close to the ovary.

attaching to the caudal pole of the kidney during blind palpation. Consequently, novice surgeons attempt to rupture tissue close to the ovary; unfortunately, this is where the blood supply to the ovary and venous branches to the kidney are closest to the SL. The risk of hemorrhage in this vascular area is significantly greater than that in the relatively avascular abdominal wall attachment region (**FIGURE 3**). In addition, novice surgeons tend to pull up (ventrally) on the proper ligament, which tightens not only the SL but also the mesovarium attachments to the kidney and ovarian pedicle. It then becomes difficult to identify and isolate the SL by palpation. There is also a tendency to put tension on the SL and mesovarium with the index finger pointing in a medial-to-lateral direction (**FIGURE 4**). Because the medial extension of the mesovarium attaches to the kidney, it is easy to disrupt the tissue to the kidney capsule along with the SL when force is applied this way. Furthermore, the direction of this finger force runs toward the more laterally situated SL attachment and away from the source of the blood supply (the aorta on dorsal midline; **FIGURE 4**), which may induce more risk of avulsing the ovarian pedicle before SL rupture. We recommend SL rupture with only lateral-to-medial force. Because the SL runs lateral to the kidney as it courses to the dorsal abdominal wall, it is difficult for a novice surgeon to break it using medial-to-lateral force in the least vascular area (at the attachment to the abdominal wall). In our experience, when the procedure described below is performed correctly, the chance of complications involving rib fracture, diaphragmatic tears, or kidney damage is minimal.

Suspensory Ligament Rupture Technique

Dogs

Three tasks are important for safe SL rupture in dogs:

- Identify the proper ligament, and clamp it with forceps.
- Identify the SL at its free cranial border within the mesovarium, and isolate the ligament with the appropriate index finger.
- Rupture the SL in a controlled fashion from a lateral-to-medial direction as close as possible to the SL attachment to the abdominal wall.

Identify the proper ligament, and clamp it with forceps. Once the uterus is identified, follow one of the uterine horns cranially until the ovary can be palpated (**FIGURE 5**). In deep-chested dogs, the ovary may not be visible, but the tough proper ligament to the ovary can be isolated and clamped with hemostatic forceps.

Identify the SL at its free cranial border within the mesovarium, and isolate it with the appropriate index

Key Points

- Adequate exposure of the ovarian pedicle during ovariectomy is important to ensure that the pedicle is securely double ligated and does not include any ovarian remnant.
- Suspensory ligament rupture should be performed when it is not possible to expose enough ovarian pedicle for safe ligation.
- In dogs, the preferred site of suspensory ligament rupture is at the ligament's craniodorsal attachment to the abdominal wall because this area is furthest from important vascular structures. Blunt rupture of the ligament in this area is performed blindly with the index finger in a lateral-to-medial direction.
- In cats, the proper ligament and ovarian pedicle are more friable and the suspensory ligament can be readily distinguished from surrounding mesovarian structures; therefore, the suspensory ligament can be safely disrupted by sharp transection where it can be seen close to the ovary.

finger. Regardless of whether the surgeon is right- or left-handed, or on which side of the patient the surgeon is standing, the left index finger is used to disrupt the right SL (**FIGURES 6A** and **6B**), and the right index finger is used to disrupt the left SL (**FIGURE 6C**). The surgeon's body should be oriented toward the cranial aspect of the animal during SL rupture. Using the hemostatic forceps on the proper ligament as a handle, pull the ovary in a caudomedial direction (not too much ventrally), which should create tension directly on the SL alone (not the medial attachments of the mesovarium to the kidney or the ovarian pedicle). Maintain this tension throughout the remaining portion of the SL rupture maneuver.

Rupture the SL in a controlled fashion in a lateral-to-medial direction as close as possible to the SL attachment to the abdominal wall. With the palm of the hand facing medially, allow the correct index finger to course along the lateral aspect of the taut SL as far cranially as possible until the attachment fans out to the abdominal wall. While the other hand holds the hemostatic forceps and maintains tension on the ligament, use only the index fingertip to avulse the ligament from its attachment to the abdominal wall (pull only as hard as necessary on the hemostatic forceps to keep the index finger firmly positioned on the SL). Sudden rupture is accomplished by thrusting the index finger held on the SL in a craniomedial direction (**FIGURE**

Practice Exercise

This exercise gives surgeons the chance to experience the amount of finger force necessary to break the suspensory ligament (SL) in medium-sized to larger dogs. In addition, it illustrates how to direct the force of the index finger to break the ligament consistently at its attachment point.

Objectives

- To consistently break a tense fibrous band (similar in strength to a dog's SL) directly at the tip of the index finger.
- To understand the amount and direction of force required to disrupt the SL at its attachment.
- To reinforce how much tension should be placed on the SL to help guide the index finger to the ligament attachment and how to maintain tension during fingertip rupture of the SL.

Requirements

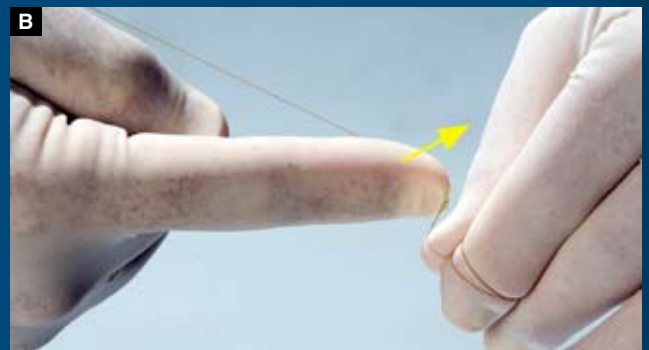- Fresh, moist 4-0 chromic gut suture
- Assistant

Exercise Description

Have a colleague wrap the suture several times around a finger and hold it firmly. Visualizing the attachment to be either on the right or left side of a body cavity, stand so you are facing the attachment (cranially). The point at which the suture is held represents the abdominal wall attachment of the SL (**FIGURE A**). Put sufficient tension on the free end of the suture to position the correct index finger (i.e., if you are practicing disruption of the attachment on the left side of the abdomen, use your right index finger [**FIGURES B and C**]; use your left index finger for attachment on the right side of the abdomen [**FIGURE D**]) at the attachment with the palm of your hand facing away from the attachment (**FIGURE B**). Hold tension on the suture with the opposite hand, and push your index finger forward (cranially) and away (medially) from the attachment. Push firmly until the suture snaps (**FIGURE C**). If this is done correctly, the suture will break just under the tip of the index finger. Practice this maneuver with simulated attachments on both sides of the abdomen until you can consistently break the suture at its attachment with either index finger.



A An assistant (right) firmly holds a strand of moist 4-0 chromic gut suture material wrapped around an index finger. The suture represents the SL, and the assistant's finger represents the abdominal wall. You (the surgeon) are standing on the imaginary patient's right side with your right palm toward the patient's midline. To practice rupturing the left SL, hold the suture tight enough with your left hand to ride your right index finger down the suture to within 1 to 2 cm of the attachment.



B Holding constant, firm tension on the suture with your left hand, thrust your right index finger forward and away from the attachment (arrow). This simulates breaking the SL from the patient's left abdominal wall.



C The suture should break in the area under the tip of your index finger each time you practice this maneuver.



D To practice rupturing the right SL, maintain tension on the suture with your right hand, hold your left palm toward the patient's midline, and thrust your left index finger forward and away (cranially and medially; arrow) from the attachment as described above. You are still standing on the imaginary patient's right side.

7A). Do not put additional tension on the hemostatic forceps while pushing the index finger, or the SL will break indiscriminately along its course rather than just at the wall attachment.

When the technique is performed correctly, the SL either “pops” and ruptures completely or stretches out but remains partially intact. Either outcome is acceptable provided that the ovary and pedicle are adequately exposed. If the ligament is stretched, gentle caudal tension on the hemostatic forceps while the index finger is depressed dorsally on the middle of the SL will break down any remaining SL attachments. When performed correctly, the SL consistently ruptures at its weakest point—its fanned out attachment—well away from important vascular structures found more caudally (**FIGURE 7B**). The ovarian pedicle is double ligated using a proper three-clamp hemostatic technique. Repeat the procedure on the opposite side.

Cats

SL rupture in cats is more straightforward because the cat’s cranial abdomen is shallower than that of deep-chested dogs, and the SL and ovarian pedicle can be readily seen within the mesovarium (**FIGURE 2**). The ovarian pedicle and proper ligament to the ovary are considerably more fragile

in cats than in dogs, so traction on these structures for SL rupture (as in dogs) is more dangerous. Therefore, we recommend sharp rather than blunt division of the SL in cats. After completing the celiotomy approach and grasping one of the uterine horns, carefully identify the ovary and SL. While gently pulling the uterus caudal and up (or more ventral), sharply incise the ligament away from ovarian tissue, and retract the ovary from the abdominal cavity to expose the ovarian pedicle (**FIGURE 8**). Any avascular portion of the mesovarium cranial to the ovary can be sharply broken down if additional exposure is necessary. Securely double ligate the ovarian pedicle using a three-clamp technique. Repeat the procedure on the opposite side.

References

1. Johnson AL, Greenfield CL, Klippert L, et al. Frequency of procedure and proficiency expected of new veterinary school graduates with regard to small animal surgical procedures in private practice. *JAVMA* 1993;202:1068-1071.
2. Stone EA. Reproductive system. In: Slatter D, ed. *Textbook of Small Animal Surgery*. St. Louis: Saunders; 2003:1495-1498.
3. Finland RB. Ovariohysterectomy. In: Bojrab MJ, Ellison GW, Slocum B, eds. *Current Techniques in Small Animal Surgery*. Baltimore: Williams and Wilkins; 1998:489-492.
4. Sicard GK, Finland RB. Surgery of the ovaries and uterus. In: Birchard SJ, ed. *Saunders Manual of Small Animal Practice*. St. Louis: Saunders; 2006:992-998.
5. Fossum TW. Surgery of the reproductive and genital systems. In: *Small Animal Surgery*. St. Louis: Mosby; 2002:616-617.
6. Evans HE, Christenson GC. *Miller’s Anatomy of the Dog*. Philadelphia: WB Saunders; 1981.

3 CE CREDITS

CE TEST

This article qualifies for 3 contact hours of continuing education credit from the Auburn University College of Veterinary Medicine. Subscribers must take individual CE tests online and get real-time scores at Vetlearn.com. Those who wish to apply this credit to fulfill state relicensure requirements should consult their respective state authorities regarding the applicability of this program.

1. **When disrupting the SLs in a dog, which index finger should the surgeon use?**
 - a. the left for both
 - b. the right for both
 - c. the index finger of his or her dominant hand
 - d. the left index finger for the right SL, and the right index finger for the left SL
2. **The left ovarian vein in dogs and cats**
 - a. empties into the left side of the vena cava.
 - b. empties into the left renal vein.
 - c. empties into the vena cava cranial to the kidney.
 - d. runs within the mesometrium caudal to the ovary.
3. **Which is not a potential source of difficulty when performing SL rupture?**
 - a. In dogs, the SL is usually not seen and must be identified blindly by palpation.
 - b. In cats, the proper ligament is friable, and too much tension during SL rupture can disrupt the ovarian blood supply or proper ligament.
 - c. Considerable force is required to break the SL in large-breed dogs.
 - d. In dogs, rupturing the SL too far cranially may lead to excessive hemorrhage.
4. **Which statement regarding the anatomy of the ovarian ligaments and vascular supply in dogs and cats is false?**
 - a. The SL runs from the ovary to the kidney capsule.
 - b. The proper ligament is a continuation of the suspensory ligament and runs from the ovary to the uterine horn.
 - c. The ovarian venous system is more tortuous in dogs than in cats.
 - d. More branches of the ovarian blood supply run to the kidney capsule in dogs than in cats.
5. **The recommended site of SL rupture in dogs is**
 - a. as close to the ovary as possible.
 - b. in the tissue between the ovary and the kidney.
 - c. as close to the abdominal wall attachment as possible.
 - d. within the mesovarium dorsomedial to the ovary.
6. **The recommended site of SL transection in cats is**
 - a. close to the ovary.
 - b. in the tissue close to the mesovarium attaching to the kidney.
 - c. as close to the abdominal wall attachment as possible.
 - d. within the mesovarium dorsomedial to the ovary.
7. **Which is a correct technique when breaking down the SL in dogs?**
 - a. Rupture the tissue between the ovary and kidney.
 - b. Pull ventrally on the proper ligament to identify the SL during palpation.
 - c. Disrupt the SL in a medial-to-lateral direction.
 - d. Clamp the proper ligament with a hemostatic forceps to help put tension on the SL.
8. **When disrupting the SL in dogs, the force of the index finger should be directed**
 - a. craniomedially.
 - b. craniolaterally.
 - c. caudomedially.
 - d. caudolaterally.
9. **During blind palpation, to help identify the SL in dogs, the surgeon should**
 - a. not place a hemostatic forceps on the proper ligament because it is too friable to tolerate any tension.
 - b. put caudal, medial, and as much ventral tension as possible on the SL.
 - c. put caudal, medial, and minimal ventral tension on the SL.
 - d. put caudal, lateral, and as much ventral tension as possible on the SL.
10. **To rupture the SL in dogs, the surgeon should face _____, and the palm of the hand being used should face _____.**
 - a. cranially; medially
 - b. cranially; laterally
 - c. medially; medially
 - d. medially; laterally