

Mass mortality of young striped jack *Pseudocaranx dentex* caused by a fungus *Ochroconis humicola*

Chutharat Munchan¹, Osamu Kurata¹,
Kishio Hatai^{1*}, Noriko Hashiba¹,
Noriyoshi Nakaoka² and
Hidemasa Kawakami²

¹Laboratory of Fish Diseases, Nippon Veterinary and Life Science University, Tokyo 180-8602, Japan

²Ehime Prefecture Fish Disease Control Center, Uwajima, Ehime 798-0087, Japan

(Received July 4, 2006)

ABSTRACT—In April 2004, a fungal infection occurred in cultured young striped jack *Pseudocaranx dentex* at a fish farm in Ehime Prefecture, Japan. The cumulative mortality reached about 25% in one month after the disease was first recognized. Moribund fish showed disease signs such as abdominal swelling and distended kidney. A fungus was purely isolated from the kidney of the fish using PYGS agar. The colony was pale brown in color, and the conidia were two-celled, cylindrical to oblong with rounded ends and smooth-walled. From these morphological characteristics, the fungus was identified as *Ochroconis humicola*. This infection of marine fishes has been reported in the skin of juvenile fish, but not known in young fish. This paper describes the first case of *O. humicola* infection in visceral organs of young striped jack.

Key words: *Ochroconis humicola*, *Pseudocaranx dentex*, striped jack, fungal infection

The fungal infection in fishes caused by *Ochroconis humicola* was first reported from the kidney of coho salmon *Oncorhynchus kisutch* (Ross and Yasutake, 1973). Later, *O. humicola* infection were reported from rainbow trout *Salmo gairdneri* (Ajello *et al.*, 1977), Atlantic salmon *Salmo salar* (Schaumann and Priebe, 1994), devil stinger *Inimicus japonicus* (Wada *et al.*, 1995), barramundi cod *Cromileptes altivelis* (Bowater *et al.*, 2003), red sea bream *Pagrus major* and marbled rockfish *Sebastes marmoratus* (Wada *et al.*, 2005). This paper describes the first case of *O. humicola* infection in striped jack *Pseudocaranx dentex* in Japan.

Materials and Methods

In April 2004, a fungal infection occurred in cultured young striped jack *Pseudocaranx dentex* at a fish farm in Ehime Prefecture, Japan. The water temperature in this month was 17–18.5°C. The examined 0-year-old fish were 6 to 10 cm in body length and 5 to 10 g in body weight (n = 5).

Isolation and identification of the fungus

Pieces of kidneys of striped jack with fungal infection were inoculated onto PYGS agar (peptone 1.25 g, yeast extract 1.25 g, glucose 3 g, artificial seawater 37.60 g, agar 12 g) supplemented with small amounts of ampicillin and streptomycin. The plates were incubated at 25°C for 10 days. Pure culture was made from a single conidium. For identification, shape and color of colony were first observed one month after incubation at 25°C on PDA (Nissui Co., Ltd., Tokyo). The identification was made according to de Hoog *et al.* (2000).

Effect of temperature on growth

The fungus was inoculated onto PDA and incubated at 25°C for one month to allow forming a giant colony. An agar block taken from the edge of the growing colony with a No. 2 cork borer (5.5 mm in diameter) was inoculated onto the center of PDA plate. The inoculated plates were incubated at seven different temperatures (10, 15, 20, 25, 30, 35 and 37°C), and the colony radii was measured four weeks after inoculation.

Effect of NaCl concentrations on growth

A part of growing colony was inoculated as previously onto the center of PDA plates containing various concentrations of NaCl (0, 1, 3, 5, 7, 8, 9, 11 and 13%) and incubated at 25°C. The colony radii were measured as described above.

Histopathological observations

The musculature, spleen and kidney of diseased fish were fixed in 10% phosphate-buffered formalin solution after necropsy. Subsequently, the samples were routinely embedded in paraffin and sectioned at 4 to 5 µm. The sections were stained with Grocott's variation counter stained with hematoxylin and eosin (Grocott's-HE) for detecting fungal elements.

Results

Moribund fish with fungal infection showed disease signs such as swelling of abdomen and distended kidney (Fig. 1). Numerous brownish hyphae were found in squash preparation of the kidney under microscopy (Fig. 2). The cumulative mortality of the disease reached 25% (62,500 out of 250,000 fish) for one month after the

* Corresponding author
E-mail: hatai@nvl.u.ac.jp




Fig. 1. A naturally infected fish with swelling abdomen. Bar = 1 cm.

Fig. 2. Fungal hyphae with septate in the kidney of an affected fish. Bar = 10 μm .

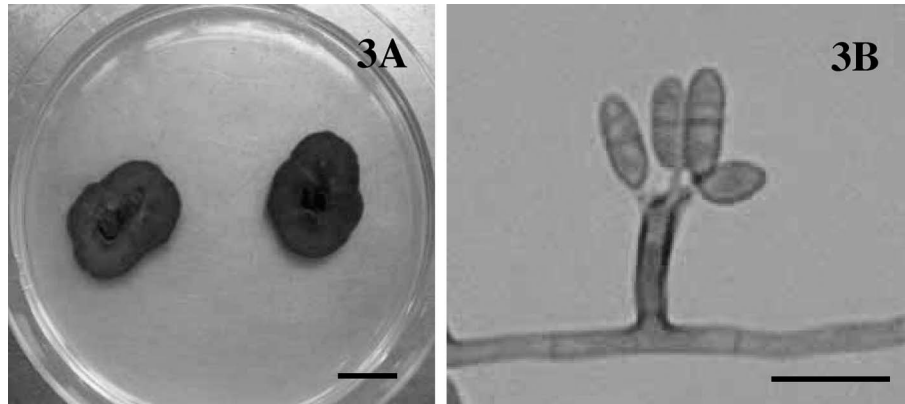


Fig. 3. Isolate NJM 0472. (A) Colonies on PDA after four weeks at 25°C. Bar = 2 cm. (B) Conidiophores and conidia. Bar = 10 μm .

disease was recognized.

Fungal identification

A fungus was purely isolated from infected fish. As all isolates were judged as the same fungus, an isolate NJM 0472 was randomly selected among the isolates and used for all experiments in this study. Colony of the isolate showed dark brown to black color when observed from the reverse side of the plate and no visible exudates diffused into the medium, and it was flat, very slow-growing on PDA plate. Colony radii on PDA incubated at 25°C reached 30.1 mm after four weeks. Hyphae were septate, 2 to 3 μm in diameter, pale brown in color, and aerial hyphae were sparse. Conidiophores were predominantly cylindrical, average $2.5 \times 7.5 \mu\text{m}$ and had denticles at each tip. Conidia were holoblastic, two-celled, cylindrical to oblong with rounded ends, average $2.5\text{--}4.5 \times 5.5\text{--}12.5 \mu\text{m}$, smooth-walled, and pale brown in color (Fig. 3). The isolate was identified as *Ochroconis humicola* from these characteristics.

Effect of temperature on growth

Colony radii of the isolate NJM 0472 incubated on PDA at 10, 15, 20, 25 and 30°C were 1.4, 10.5, 21.5, 30.0 and 26.3 mm, respectively. No fungal growth was observed at 35°C.

Effect of NaCl concentrations on growth

Colony radii of the isolate NJM 0472 incubated on PDA including 0, 1, 3, 5, 7, 9 and 11% NaCl were 30.0, 33.4, 34.1, 27.9, 15.5, 7.2 and 0 mm, respectively. The fungus grew well on PDA containing 3% NaCl.

Histopathological observations

Fungal hyphae were found in the musculature (Fig. 4A), spleen (Fig. 4B) and kidney. Granulomas encapsulating hyphae were observed in the spleen (Fig. 4C) and kidney (Fig. 4D). The granulomas consisted of massive fungal elements and outer layers surrounded by epitheloid cells. No bacteria or parasites were histopathologically found in the examined tissues.

Discussion

The genus *Ochroconis* belongs to the dematiaceous fungi, which are characterized by the presence of melanin compound within the cell wall of hyphae or spores (Schell, 2003). Therefore, the color of colony looks like brown to black. *Ochroconis humicola* (formerly named *Scolecobasidium humicola*) has been reported in salmonids (Ross and Yasutake, 1973; Schaumann and Priebe, 1994; Ajello *et al.*, 1977), later marine fishes (Wada *et al.*, 1995; Bowater *et al.*, 2003; Wada *et al.*, 2005), and also in tortoise (Weitzman *et al.*, 1985).

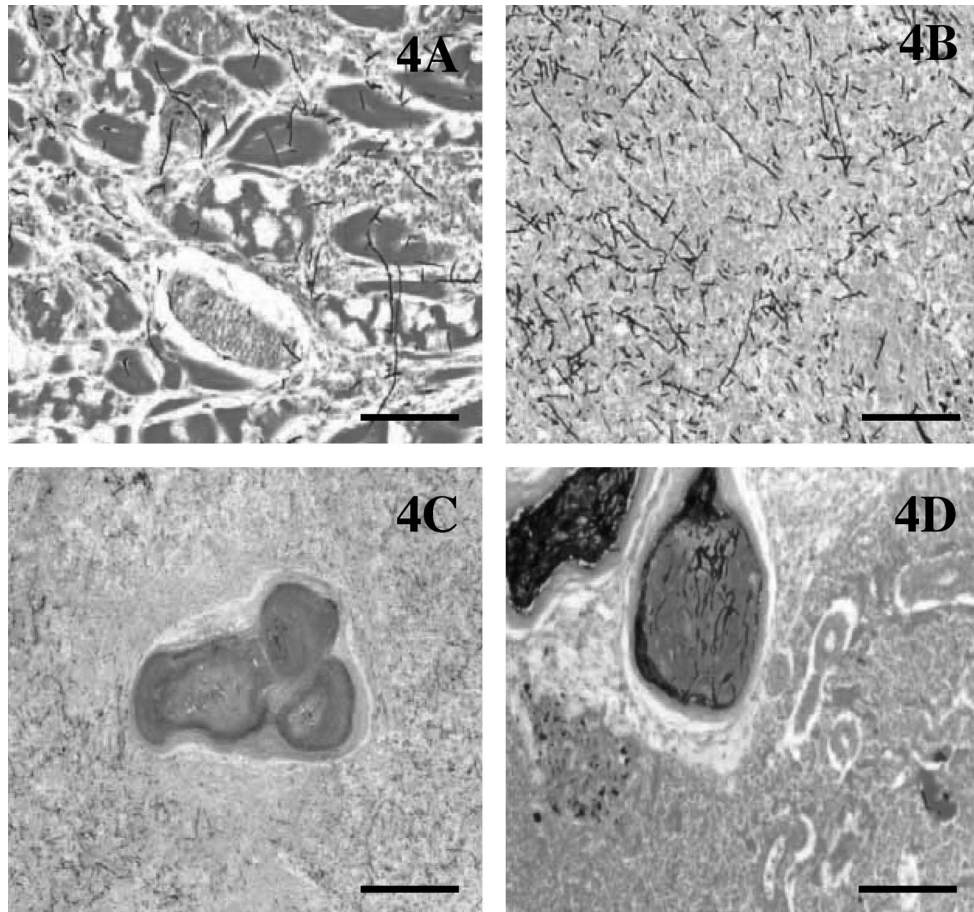


Fig. 4. Histopathological sections of naturally infected fish. Note fungal hyphae penetrated in the musculature (A) and spleen (B). Fungal granulomas were found in the spleen (C) and kidney (D). Grocott's-HE. Bar =100 μ m.

O. humicola infection was found in a wild-caught barramundi cod in Australia (Bowater *et al.*, 2003). The size was not described, but it was matured fish, not young. Up to the present *O. humicola* infection in cultured marine fishes in Japan has been found only in the skin of juvenile, namely 1.4 g devil stinger *Inimicus japonicus* (Wada *et al.*, 1995) and 1.2 g red sea bream *Pagrus major* and 1.0 g marbled rockfish *Sebastiscus marmoratus* (Wada *et al.*, 2005), but not in young stage more than 5 g in body weight. Furthermore, many striped jack died due to the infection in the present case. Namely, *O. humicola* infection in young striped jack accompanied with mass mortality is the first case.

The isolate grew at 10 to 30°C, but not at 35°C. The results were corresponded with Horr e *et al.* (1999) who reported that *O. humicola* isolated from brain of fish did not grow at 35°C. The isolate NJM 0472 could grow up to 9% NaCl indicating that *O. humicola* could grow in an environment with a wide range of salinity.

Histopathological findings of naturally infected fish were almost similar to the results of previous reports on *O. humicola* in fishes (Ross and Yasutake, 1973; Ajello *et al.*, 1977; Wada *et al.*, 1995; Bowater *et al.*, 2003;

Wada *et al.*, 2005). The diagnosis of the infection caused by phaeohyphomycosis, which is an infection caused by dematiaceous fungi, is relatively easy, because the presence of brown pigmented fungal elements in tissues is histopathologically demonstrated (Carter and Chengappa, 1991).

References

- 1) Ajello, L., M. R. McGinnis and J. Camper (1977): *Mycopathologia*, **62**, 15–22.
- 2) Barron, G. L. and L. V. Busch (1962): *Can. J. Bot.*, **40**, 78–84.
- 3) Bowater, R. O., A. Thomas, R. G. Shivas and J. D. Humphrey (2003): *J. Fish Dis.*, **26**, 681–686.
- 4) Carter, G. R. and M. M. Chengappa (1991): *Essentials of veterinary bacteriology and mycology*. Lea and Febiger, London, pp. 262–263.
- 5) de Hoog, G. S., J. G. Gen e and M. J. Figueras (2000): *Atlas of clinical fungi*. 2nd edition. Centraalbureau voor Schimmelcultures Utrecht, The Netherlands, 1126 p.
- 6) Horr e, R., G. S. de Hoog, C. Kluczny, G. Marklein and K. P. Schaal (1999): *Stud. Mycol.*, **43**, 194–205.
- 7) Padhye, A. A., R. L. Amster, M. Browning and E.P. Ewing (1994): *J. Med. Vet. Mycol.*, **32**, 141–145.
- 8) Ross, A. J. and W. T. Yasutake (1973): *J. Fish. Res. Bd. Can.*, **30**, 994–995.
- 9) Schaumann, K. and K. Priebe (1994): *Can. J. Bot.*, **72**, 1629–1634.
- 10) Schell, W. A. (2003): *Dematiaceous hyphomycetes*. 2nd edition. Haward, D. H. (eds). *Pathogenic fungi in humans and animals*. Marcel Dekker, Inc., New York,

pp. 565–636. 11) Wada, S., C. Hanjavanit, O. Kurata and K. Hatai (2005): *Fish. Sci.*, **71**, 682–684. 12) Wada, S., K. Nakamura and K. Hatai (1995): *Fish Pathol.*, **30**, 125–126. 13)

Weitzman, I., S. A. Rosenthal and J. L. Shupack (1985): *J. Med. Vet. Mycol.*, **23**, 287–293.