

**Characterization of patients with pre-clinical Acromegaly.  
~Radiological, endocrinological, and pathological findings~**

Hidetoshi Ikeda, MD.,PhD.

Research Institute for Pituitary disease, Southern Tohoku General  
Hospital. Koriyama, Japan

**Key words: pre-Acromegaly, radiology, Endocrinology, Pathology**

## **Abstract**

**Objerct;** The aim of this study is to disclose early endocrinological, neuroradiological and pathological nature of pre-clinical Acromegaly to contribute the establishment of early detection of GH secreting adenomas.

**Materials and Methods;** The 32 patients who, were regarded as pre-Acromegaly were underwent transsphenoidal surgery at Southern Tohoku General Hospital between 2011 and 2013 were analized. We defined patients as having abnormal GH secretary dynamics, who meet with the one or more criteria; as follows: (1) high GH level and/or IGF-1 level; (2) no suppression of GH levels as determined using the 75g-oGTT loading test; and (3) paradoxical response of GH to the TRH/LHRH loading test. Those patients who meet with the criteria of abnormal GH dynamics were subjected to examine composite 3T MRI and MET-PET imagings. We set up critical value as SUVmax 1.0 to differentiate normal pituitary tissue and hormone active adenomatous tissue. Surgical specimens were subjected to immunohistochemical staining. We adopted the surgical cure rate for acromegaly using both 2000 and 2010 cure criteria (12,13).

**Results;** The most sensitive endocrinological diagnostic method for pre-clinical acromegaly was found to be TRH/LHRH, followed by 75g-oGTT , and high GH and/or high IGF-1 values. High MET accumulation was observed in all 32 cases, thus the diagnostic sensitivity of MET-PET fusion 3T-MRI was 100% for pre-clinical acromegaly. The overall surgical cure rate for patients without obvious clinical features of acromegaly (pre-clinical acromegaly) was 100%. In all 32 cases, strong immunoreactivity for GH was demonstrated.

**Conclusion;** Early surgical treatment of acromegaly, i.e., in the state of pre-acromegaly promises a high cure rate; therefore early detection of abnormal GH dynamics is important in the preventive treatment of Acromegaly.

## **Introduction**

GH secreting pituitary adenoma is hard to diagnose in the early stages because of growth hormone (GH) excess and slow progression. The disease is frequently missed for many years until changes in external body features, especially the face, become noticeable. Therefore, diagnosis of the disease is delayed for approximately 2.5–10 years (mean, 8 years) from onset of symptoms.<sup>1</sup> Furthermore, acromegaly is associated with a twofold or threefold increase in patient mortality, and a reduced life expectancy of 10 to 15 years relative to the general population. This is due to the presence of other diseases such as diabetes mellitus, high blood pressure, hyperlipidemia, cardiovascular and respiratory disease and neoplastic complications.<sup>1-4</sup> The duration of disease is one of the prognostic factors. An early diagnosis of the disease is mandatory, although none of these symptoms is sufficiently sensitive, especially during the early stages of the disease. Hence, establishing guidelines for the early diagnosis or assessment of the disease activity of acromegaly is a major challenge.<sup>1,5,6</sup>

This study was undertaken to disclose early endocrinological, neuroradiological and pathological nature of pre-clinical Acromegaly to contribute the establishment of early detection of GH secreting adenomas.

## **Material and Method**

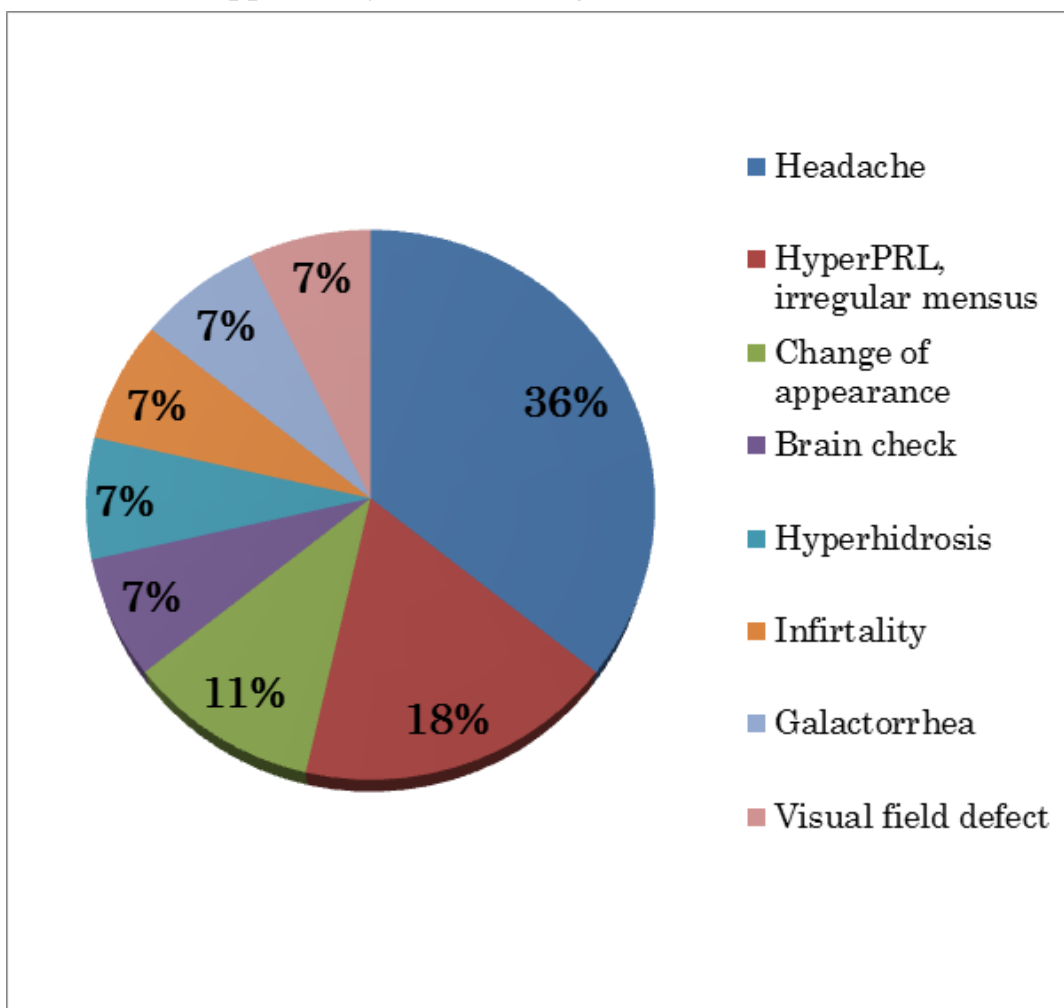
### ***Patients***

The 32 patients who, were regarded as pre-Acromegaly, had no apparent clinical characteristics of acromegaly (i.e., pre-clinical acromegaly), such as obvious cheekbones, bulging forehead, enlarged jaw, and soft tissue swelling resulting in enlargement of the hands, feet, nose, or lips.<sup>1,2,7</sup> were underwent transsphenoidal surgery by skilled pituitary surgeon (H.I.) at Southern Tohoku General Hospital between 2011 and 2013.

***Motive of finding GH secreting adenoma***

Patients with pre-Acromegaly were found out during consulting for headache (36%), hyperprolactinemia and abnormal menses (18%), Deformity of face and head (11%), pointed out by brain-check (7%), abnormal sweating (7%), treatment infertility (7%), galactorrhea (7%), visual field impairment (7%) etc.

**Fig. 1.** The opportunity of consulting our institute.



Of these patients, 11 were male and 21 were female. The patient’s mean age was 36 years (range 13–68 years). And the patients’ mean height was 164cm, mean body weight was 63Kg, and mean BMI was 23.2.

Five out of 33 patients suffered from hypertension, and one patient

suffered from DM.

### ***Endocrinological assessment***

The endocrine status of the patients with GH-secreting adenomas was evaluated before and after surgery by measurement of serum levels of GH and insulin-like growth factor-1 (IGF-1), prolactin, ACTH, cortisol, thyroid-stimulating hormone, free-T3 and free-T4, follicle-stimulating hormone, luteinizing hormone, estradiol, and testosterone. The secretory status of the tumor and preoperative evaluation of the baseline pituitary function were established. Precise endocrinological tests were performed using the GH suppression test, as determined using the 75-g oGTT loading test and the TRH/LHRH loading test, to examine the paradoxical response to GH. These stimulatory and inhibitory tests were not indicated in patients with severe diabetes mellitus or with large pituitary adenoma for fear of pituitary apoplexy.

We defined patients as having abnormal GH secretory dynamics, who meet with the one or more criteria; as follows: (1) high GH level and/or IGF-1 level; (2) no suppression of GH levels as determined using the 75g-oGTT loading test; and (3) paradoxical response of GH to the TRH/LHRH loading test.

We analyzed interrelationships among the following parameters: GH level; IGF-1 basal level; MET-PET SUV<sub>max</sub>; FDG-PET SUV<sub>max</sub>; and tumor volume. In those patients who were checked several times for GH and IGF-1 levels, we calculated the mean values and analyzed the interrelationship among these mean values and other parameters.

### ***Magnetic Resonance Imaging***

The size and extent of the tumors were determined using magnetic resonance (MR) images obtained with a 3.0-T MR unit (Signa HDx; General Electric, Fairfield, CT, USA). T1- and T2-weighted thick sagittal and coronal spin-echo MR images were obtained as 2-mm-thick slices. Additional T1-weighted axial, sagittal, and coronal MR images (500/15

ms) were obtained immediately after injection of 0.1 mmol/kg gadolinium-diethylenetriaminepenta-acetic acid (Schering, Berlin, Germany). The images were reconstructed by means of a two-dimensional Fourier transformation on a  $256 \times 256$  image matrix. The tumor size and cavernous sinus invasion were evaluated on axial, sagittal, and coronal images of MET-PET fusion 3T-MRI with gadolinium enhancement. The tumor volume was measured using a reliable empirical formula for volume estimation published by Petersen et al.<sup>8</sup>

### ***Positron Emission Tomography Imaging***

As of 2008, the PET-computerized tomography (PET-CT) studies were undertaken using the Discovery LS (General Electric) for all cases. The PET machine used bismuth germanium oxide crystals. All patients fasted before the procedure and received intravenous injections of [<sup>11</sup>C] methionine (MET;  $5.6 \text{ MBq} \times \text{body weight}$  [dose range, 225.7–558.3 MBq, i.e., 6.1–15.1 mCi]). PET scans of 10 min duration were obtained starting 20 min after injection. At 1 h after the MET injection, all patients received intravenous injection of fludeoxyglucose (FDG;  $3.7 \text{ MBq} \times \text{body weight}$  [dose range, 155–269.5 MBq, i.e. 4.2–7.3 mCi]). PET scans of 10 min duration were obtained starting 60 min after injection. The MET-/FDG-PET procedure was performed in a three-dimensional mode, which provided a set of 35 planes with a section thickness of about 4.1 mm. The uptake of FDG and MET during PET scanning was evaluated using a standardized uptake value (SUV) max.

### ***Image Post-Processing***

The MR and PET images were co-registered to Gd-enhanced, T1-weighted axial, coronal, and sagittal images using the software workstation (Advantage Windows, General Electric). For co-registration between MR images and PET images, MRI data were first reconstructed based on the CT skull shape ascertained using PET-CT. This procedure was performed based on anatomical landmarks, such as optic nerves, the

internal occipital protuberance, and the vestibular cochlear nerve. Then, the MR images were fused to the PET scan. Thereafter, the PET scans that had been overlaid onto the MR images were automatically viewed.<sup>9,10,11</sup>

The presence of pituitary adenomas was evaluated by composite 3T-MRI and MET-PET imaging. Using MET SUVmax value; we set up threshold of adenomatous “high” uptake of MET considering normal appearing pituitary gland of volunteer.

Background activity in normal pituitary tissue included in this study showed a mean ( $\pm$  SD) MET SUVmax of  $1.3 \pm 0.23$ , and a mean FDG SUVmax of  $3.19 \pm 0.74$ . The background activity of normal pituitary tissue from PET examination in the 10 individuals who did not seem to have pituitary disease was  $0.74 \pm 0.18$  (range 0.50–1.0) for MET SUVmax and  $2.72 \pm 0.96$  (range 1.3–4.5) for FDG SUVmax<sup>10</sup>. Thus, background noise in proposed adenoma cases was higher than that in cases with normally functioning pituitary glands, probably due to tumor uptake artifact.

In light of the above facts, we considered SUVmax 1.0 is reasonable to define as critical value to differentiate normal pituitary tissue and hormone active adenomatous tissue.

The FDG uptake was probably not detected in adenomas with low activity because the background activity of FDG was greater than that of MET.

### ***Pathological Examination***

All the surgical specimens from 32 patients were fixed in 10% neutral buffered formalin and embedded in paraffin. Three □m thick slice  
prepared and stained with hematoxylin and eosin. Immunohistochemical staining was performed using the avidin-biotin complex method with the following antibodies: polyclonal adrenocorticotrophic hormone (Dako, Glostrup, Denmark); polyclonal growth hormone (Dako); polyclonal prolactin (Dako); monoclonal thyroid-stimulating hormone- $\beta$  (Neo markers, Fremont, CA, USA); monoclonal luteinizing hormone- $\beta$  (Cosmo Bio Co.

Ltd, Tokyo, Japan); monoclonal follicle-stimulating hormone- $\beta$  (Cosmo Bio Co. Ltd); polyclonal  $\alpha$ -subunit (Dako), and monoclonal Ki-67 (Dako).

### ***Remission Criteria***

We adopted the surgical cure rate for acromegaly using both 2000 and 2010 cure criteria. Those patients with GH-secreting adenomas who had a glucose suppressed (nadir) GH level of less than 1.0 ng/ml, and a normal sex- and age-adjusted IGF-1 level were defined as being in remission using the 2000 criteria<sup>12</sup>. Likewise, those patients with GH-secreting adenomas who had a glucose-suppressed (nadir) GH level of less than 0.4 ng/ml, a normal sex- and age-adjusted IGF-1 level, and postoperative random GH levels of 1 ng/ml or less were defined as being in remission based on the 2010 criteria<sup>13</sup>. To identify remission, we examined these criteria at 1, 6, and 12 months after surgery.

### ***Surgical Outcome.***

For the patients with abnormal GH secretory dynamics, both FDG-PET and MET-PET studies, which have been shown to be able to detect hormonally-active pituitary adenoma in the early stages<sup>9,10,11,14</sup> were undertaken using a PET-CT scanner (Discovery LS General Electric, Fairfield, CT, USA). In addition, FDG-PET was examined to rule out malignant tumors in the whole body which can be associated with GH secreting adenomas. For those patients whose pituitary gland showed MET accumulation more than 1.0 MET-SUVmax, we underwent transsphenoidal pituitary surgery.

### ***Statistical Analysis***

Since none of the parameters showed a normal distribution, Spearman's rank correlation test was used. A P value of <0.05 was taken to be statistically significant. To compare the differences between two independent groups, where each group showed a normal distribution, Welch's t-test was used.



## **Results**

### ***Endocrinological assessment;***

Pre-operatively, GH levels determined using the 75g-oGTT loading test were not suppressed in 20 out of 32 (63%) cases. In 24 out of 32 (75%) cases a paradoxical GH response to the TRH/LHRH loading test was observed. High GH and/or high IGF-1 values were observed 15 out of 32 (47%) cases. In the light of these findings, the most sensitive endocrinological diagnostic method for pre-clinical acromegaly was found to be TRH/LHRH, followed by 75g-oGTT , and high GH and/or high IGF-1 values. As shown in Table 1, initial abnormality of GH secretary dynamics was paradoxical response of GH to TRH/LHRH test for TRH/LHRH responder. Postoperatively, all the cases fulfilled the 2010 cure criteria of Acromegaly with 75g-oGTT loading test.

**Table 1.** Colored Colum indicate abnormal hormone values or abnormal response of GH.

No.	GH/IGF-1	o-GTT	TRH/LHRH
1			
2			
3			
4			
5			
6			
7			
8			
9			
10			
11			
12			
13			
14			
15			
16			
17			
18			
19			
20			
21			
22			
23			
24			
25			
26			
27			
28			
29			
30			
31			
32			
33			

**Neuroradiological findings;**

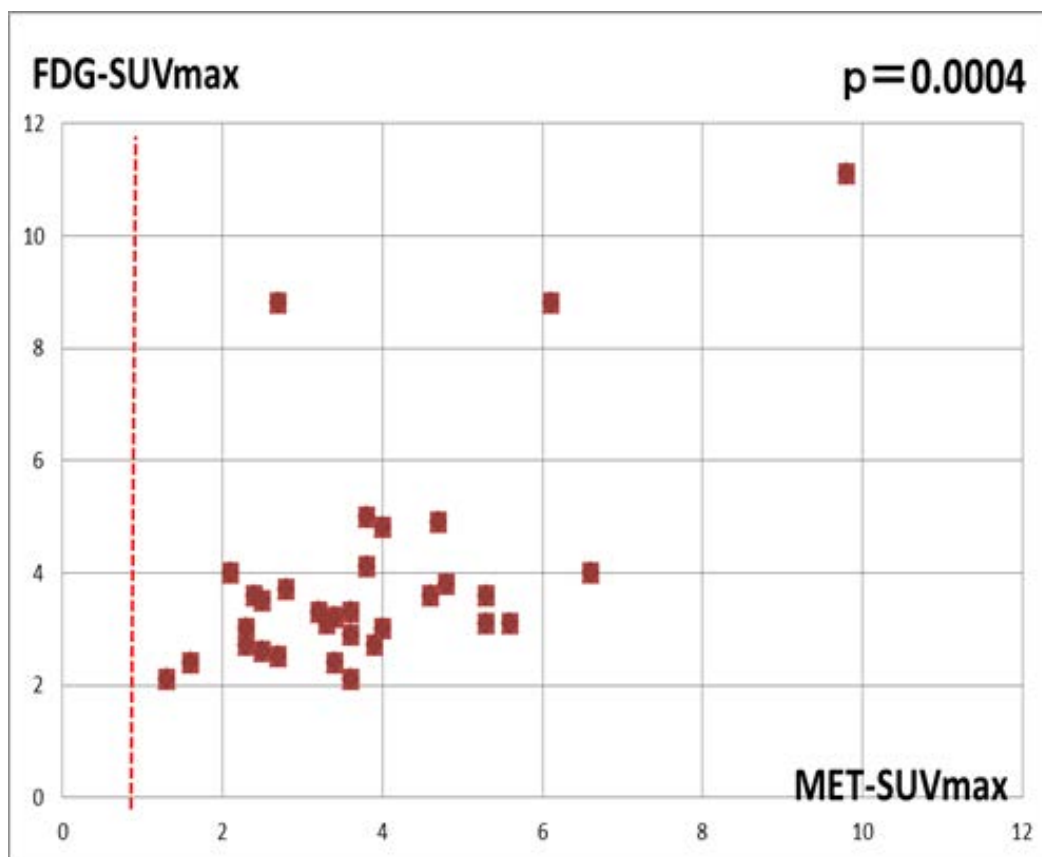
In pre-clinical acromegaly, 30 out of 32 (73%) cases were demonstrated as microadenoma. 3T-MRI disclosed adenoma in 4 cases and rest of the 28 cases the adenomas could not be visualized. High MET accumulation was observed in all 32 cases, thus the diagnostic sensitivity of MET-PET fusion 3T-MRI was 100% for pre-clinical acromegaly.

The criteria of “high” uptake of MET were defined as follows. Background activity in normal pituitary tissue in this study showed a mean MET SUVmax of  $1.3 \pm 0.23$ , and a mean FDG SUVmax of  $3.19 \pm 0.74$ . In contrast, the background activity of normal pituitary tissue by PET examination in the 10 volunteer individuals who did not seem to have pituitary disease was  $0.74 \pm 0.18$  (range 0.50–1.0) for MET SUVmax.

Therefore we considered SUVmax 1.0 as a reasonable critical value to differentiate normal pituitary tissue and hormone active adenomatous tissue. We suspect adenoma to exist when SUVmax of MET-PET exceeds 1.0 (Fig.2).

**Fig. 2.**

Relationship between FDG-SUVmax and MET-SUVmax in pre-clinical Acromegaly. There is a significant correlation ( $p=0.0004$ ) between these two factors. Note that all the cases of MET-SUVmax exceed the criteria of 1.0.



The mean MET-SUVmax was 3.8, and mean FDG-SUVmax was 3.9 in this study. There were significant correlation between MET-SUVmax and FDG SUVmax, MET SUVmax and adenoma volume, FDG SUVmax and

adenoma volume, GH and IGF-1 value, and IGF-1 value and adenoma volume (Table 2). However there were no significant correlation between MET SUVmax and GH value, MET SUVmax and IGF-1 value, FDG SUVmax and GH value, FDG SUVmax and IGF-1 value, and GH value and adenoma volume (Table 2).

Table 2

Correlation between GH, IGF-1, adenoma volume, MET-SUVmax, and FDG-SUVmax. (P<0.05; significant)

	<b>GH</b>	<b>IGF-1</b>	<b>volume</b>	<b>MET-SUV max</b>	<b>FDG-SUV max</b>
<b>GH</b>	X				
<b>IGF-1</b>	0.0258	X			
<b>volume</b>	0.89005	0.4879	X		
<b>MET-SUVmax</b>	0.50547	0.17456	0.0001018	X	
<b>FDG-SUVmax</b>	0.26744	0.0717	0.00000297	0.000423	X

### ***Surgical cure rates;***

The overall surgical cure rate for patients without obvious clinical features of acromegaly (pre-clinical acromegaly) was 100%, using both 2000 and 2010 cure criteria.

### **Pathological results.**

In all 32 cases, strong immunoreactivity for GH was demonstrated.

Except for two cases of complex adenomas, 30 cases of pathological diagnosis was plurihormonal adenoma. Pathological study demonstrated

that 17 out of 32 cases had pituitary adenomas in association with Rathke's cleft cyst. A case of double adenoma consisted of PRL cell adenoma and plurihormonal adenoma. A case of triple adenoma consisted of PRL cell adenoma, gonadotroph adenoma, and plurihormonal adenoma.

## **Discussion**

Our data evaluation revealed that it is important to diagnose GH secreting adenoma as early as possible because this contributes to an improved surgical cure rate, resulting in the prevention of progressive organ failure. At the same time adverse effects caused by the surgical procedures were minimal<sup>15</sup> because most of the early stage adenoma corresponded to Knosp grade 0–1. Therefore, there was no need for manipulation in the cavernous sinus, resulting in a reduced risk factor for surgery.

For the detection and delineation of tumor location, especially in the case of microadenoma, the diagnostic accuracy of superconductive MR imaging has been reported to be only 10 to 40%, with 33% false-negatives and 20% false-positives.<sup>9,10</sup> In general, the use of dynamic MR imaging is considered to improve diagnostic accuracy. However, Tabarin et al.<sup>16</sup> reported on the rates of accurate diagnosis with MRI and dynamic MRI using 1.0-T MRI. They indicated that true positivity was 53% for MRI and 67% for dynamic MRI, illustrating that there was no significant difference between the diagnostic accuracy of these two imaging techniques.

Conventional imaging has failed to diagnose early stage GH secreting adenoma. However, MET-PET fusion MRI has enabled the detection of adenoma in all patients with abnormal GH dynamics that have been examined.<sup>11</sup> Pre-clinical Cushing's adenoma was efficiently detected using MET-PET fusion MRI;<sup>9,10</sup> similarly, pre-clinical acromegaly was also detected by MET-PET fusion MRI. The reason why MET-PET has a high sensitivity in the detection of microadenoma is attributed to the following factors: (1) GH adenoma have high cellularity relative to normal anterior pituitary tissue; (2) almost all of the cells in these two types of adenoma show strong positive immunoreactivity for either GH; (3) electron microscopyc studies have shown that GH adenoma have densely packed secretary granules in their cytoplasm; and (4) adenoma from pre-clinical

acromegaly exhibit multiple hormone production.<sup>11,14</sup> In the light of these findings it is clear that amino acid metabolism in GH adenoma is extremely active, thus accounting for the high accumulation of methionine during MET-PET.

The goal of the overall management of acromegaly should be to provide patients with the most effective means of long-term control of this benign but potentially disabling disease. For this purpose, early surgical treatment of acromegaly promises a high cure rate and minimal adverse surgical effects.

## References

1. Ben-Shlomo A, Melmed S: Acromegaly. **Endocrinol Metab Clin North Am** 37:101-122, 2008
2. Chanson P, Salenave S, Kamenicky P, Cazabat L, Young J: Acromegaly. **Best Pract Res Clin Endocrinol Metab** 23:555-574, 2009
3. Baldys-Waligorska A, Krzentowska A, Golkowski F, Sokolowski G, Hubalewska-Dydejczyk A The prevalence of benign and malignant neoplasms in acromegalic patients. *Endokrynol Pol* 61:29–34, 2010
4. Beauregard C, Truong U, Hardy J, Serri O (2003) Long-term outcome and mortality after transsphenoidal adenomectomy for acromegaly. *Clin Endocrinol* 58:86–91.
5. Bergstrom M, Muhr C, Lundberg PO, Langstrom B PET as a tool in the clinical evaluation of pituitary adenomas. *J Nucl Med* 32:610–615,1991
6. De Souza B, Brunetti A, Fulham MJ, Brooks RA, DeMichele D, Cook P, et. al (1990) Pituitary microadenoma; a PET study. *Radiology* 177:39–44.
7. Brooke AM, Drake WM Serum IGF-levels in the diagnosis and monitoring of acromegaly. *Pituitary* 10:173–179,2007
8. Petersen OF, Espersen JO: Extradural hematomas: measurement of size by volume summation on CT scanning. **Neuroradiology** 26:363-367, 1984
9. Ikeda H: Diagnosis of Cushing's disease, in Berhardt LV (ed): **Advances in Medicine and Biology**. New York: Nova Science Publishers, Inc., 2011, Vol 23, pp 185–204
10. Ikeda H, Abe T, Watanabe K: Usefulness of composite methionine-positron emission tomography/3.0-tesla magnetic resonance imaging to detect the localization and extent of early-stage Cushing adenoma. **J Neurosurg** 112:750–755, 2010



11. Sato S, Ikeda H, Saginoya T, Watanabe K: Composite MET-PET fusion 3.0 Tesla MRI is a new sensitive method for the detection of GH secreting adenomas with abnormal GH secretary dynamics. **J Metabolic Synd S2:005**, 2012. DOI:10.4172/2167-0943.S2-005
12. Giustina A, Barkan A, Casanueva FF, Cavagnini F, Frohman L, Ho K, et al: Criteria for cure of acromegaly: a consensus statement. **J Clin Endocrinol Metab 85:526–529**, 2000
13. Giustina A, Chanson P, Bronstein MD, Klibanski A, Lamberts S, Casanueva FF, et al: A consensus on criteria for cure of acromegaly. **J Clin Endocrinol Metab 95:3141–3148**, 2010
14. Ikeda H, Sato S, Saginoya T, Kudo T, Watanabe K: The outcome of surgery in patients with growth hormone secreting adenomas: early surgical intervention is essential for improving the surgical cure rate. **J Metabolic Synd S2:001**, 2012. DOI:10.4172/2167-0943.S2-001
15. Colao A, Ferone D, Marzullo P, Lombardi G Systemic complications of acromegaly: epidemiology, pathogenesis, and management. *Endocr Rev* 25:102–152,2004
16. Tabarin A, Laurent F, Catargi B, Olivier-Puel F, Lescene R, et al. Comparative evaluation of conventional and dynamic magnetic resonance imaging of the pituitary gland forthe diagnosis of Cushing’s disease. *Clin Endocrinol (Oxf)* 49:293–300,1998

