

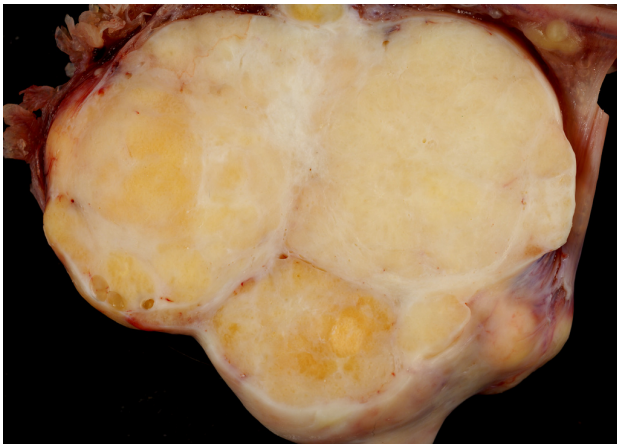
TITLE: A CASE OF RENAL OBSTRUCTION DUE TO ENDOMETRIOSIS AND A BRENNER TUMOR

Background: A 46-year-old gravida 2 para 2002 Hispanic female presented to a community hospital with severe primarily left-sided pelvic pain. On examination the pain was primarily left lower quadrant pain. The patient also stated on presentation that she had some pain in the left costal-vertical area and an ultrasound showed a 4cm left-sided adnexal mass. CT scan shows a large amount of hydronephrosis on the kidney.

Methods: Case study on interesting surgical case that was seen at our hospital.

Results: Patient's symptoms resolved after laparoscopic surgical intervention. A Brenner Tumor is a very rare pathology and was not the expected intraoperative or pathologic findings.

Conclusions: Generally, adnexal masses within the abdominal cavity do not cause obstruction of the urinary system. In this case, a patient who suffered with endometriosis had a Brenner tumor of the left ovary which was fixed in position in such a way that it did compromise the urinary tract. Patient was cured with laparoscopic oophorectomy performed through two ports.



Brenner Tumor

Image: Brenner tumour. (2017, April 03). Retrieved from https://en.wikipedia.org/wiki/Brenner_tumour

