

POSTER PRESENTATION

Open Access

3D printed cardiovascular models for surgical planning in complex congenital heart diseases

Israel Valverde^{1,2*}, Gorka Gomez³, Cristina Suarez-Mejias³, Amir-Reza Hosseinpour⁴, Mark Hazekamp⁵, Arno Roest⁶, Jaime F. Vazquez-Jimenez⁸, Issam El-Rassi⁷, Sergio Uribe⁹, Tomas Gomez-Cia³

From 18th Annual SCMR Scientific Sessions
Nice, France. 4-7 February 2015

Background

A precise understanding of the anatomical structures of the heart and great vessels is essential for surgical planning in order to avoid unexpected findings. Rapid prototyping techniques are used to print three-dimensional (3D) replicas of patients' cardiovascular anatomy based on 3D clinical images such as MRI. The purpose of this study is to explore the use of 3D patient-specific cardiovascular models using rapid prototyping techniques to improve surgical planning in patients with complex congenital heart disease.

Methods

This European prospective multicenter study included 8 patients with complex congenital heart diseases (Figure 1). Magnetic resonance imaging (MRI) and computed tomography (CT) were used to acquire 3D cardiovascular anatomy. Images were segmented and 3D mesh was created using AYRA software (IKIRIA, Spain). Fused deposition technique using polylactic acid was used. A Bland-Altman analysis was used to evaluate the diameters measurement agreement between the 3D printed model and the patient's MRI and CT. 3D-models were used to plan the surgery. After the procedure, surgeons involved filled a questionnaire form to evaluate the usefulness of the 3D printed models to plan the surgery.

Results

The Bland-Altman analysis showed accurate agreement in the diameter between medical images and 3D-models (-0.12 ± 1.40 mm, mean bias \pm standard deviation, Figure 2). 3D-models showed the spatial relationships between the ventricular septal defect and great vessels (Case2, Case-6,

Case-7, Case-8), re-appraisal for biventricular repair (Case-1, Case-8), planning of lateral tunnel completion (Case3), re-opening of a restrictive VSD and its relationship with the conductive tissue (Case4) and evaluation of RVOT aneurysm and pulmonary artery origin (Case 5). Surgeons found the 3D models to be very useful for surgical planning with an overall level of satisfaction of 8.5 out of 10, all agreed (score 4 out of 5) that 3D-models they were helpful to decrease possible surgical complications, strongly agree (score 5 out of 5) that would recommend it to other colleagues as well as teaching for trainees.

Conclusions

3D-printed cardiovascular models accurately replicate the patient's anatomy and are extremely helpful for planning surgery in complex congenital heart disease. They may potentially reduce operative time and morbidity.

Funding

This research has been co-financed by Institute of Health Carlos III - FIS research grant number PI13/02319 from the Spanish Ministry of Science and Innovation.

Authors' details

¹Cardiovascular Pathology Unit, Institute of Biomedicine of Seville (IBIS), Seville, Spain. ²Paediatric Cardiology, Hospital Virgen del Rocío, Seville, Spain. ³Technological Innovation Group, Hospital Virgen del Rocío, Seville, Spain. ⁴Cardiac Surgery Unit, Hospital Virgen del Rocío, Seville, Spain. ⁵Department of Cardiothoracic Surgery, University Hospital Leiden, Leiden, Netherlands. ⁶Paediatric Cardiology, University Hospital Leiden, Leiden, Netherlands. ⁷Pediatric Cardiac Surgery, American University Hospital Medical Center, Beirut, Lebanon. ⁸Pediatric Cardiac Surgery, University Hospital RWTH Aachen, Aachen, Germany. ⁹Department of Radiology and Biomedical Imaging Center, Pontificia Universidad Católica de Chile, Santiago, Chile.

¹Cardiovascular Pathology Unit, Institute of Biomedicine of Seville (IBIS), Seville, Spain

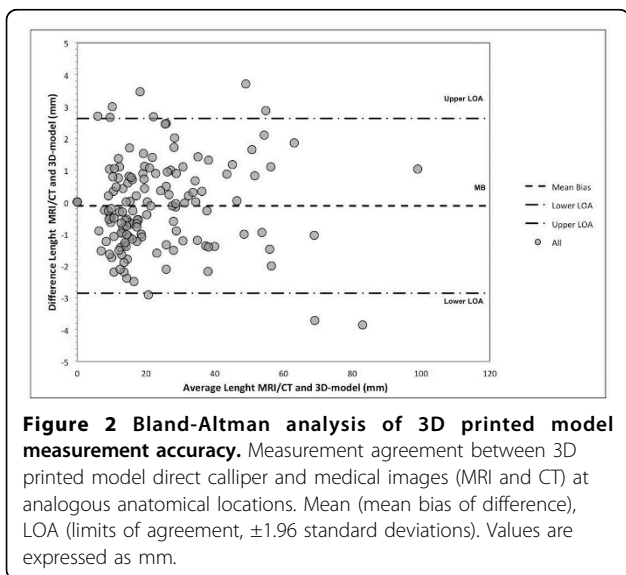
Full list of author information is available at the end of the article

Published: 3 February 2015

CASE	Medical image	3D model	Case	Medical Image	3D model
1 Age: 8 years. Weight: 36 Kg. Diagnosis: Dextrocardia, Double outlet right ventricle. Surgery: Glen Image: MRI 3DbSSFP Center: VRUH, Seville, Spain			5 Age: 15 years. Weight: 50 Kg. Diagnosis: Tetralogy Fallot Surgery: Complete repair Image: CT Center: VRUH, Seville, Spain		
2 Age: 1.5 years. Weight: 9 Kg. Diagnosis: D-TGA, pulmonary stenosis. Surgery: BT shunt Image: MRI 3DbSSFP Center: VRUH, Seville, Spain			6 Age: 2 years. Weight: 9 Kg. Diagnosis: Double outlet right ventricle Surgery: PA banding Image: CT Center: LUMC Leiden, Netherlands.		
3 Age: 9 years. Weight: 30 Kg. Diagnosis: Hypoplastic left heart syndrome. Surgery: Kawashima Image: MRI M2DbSSFP Center: RWTH, Aachen, Germany			7 Age: 3 years. Weight: 13 Kg. Diagnosis: Discordant AV connection, Double outlet right ventricle. Surgery: None Image: CT Center: LUMC Leiden, Netherlands		
4 Age: 10 years. Weight: 52 Kg. Diagnosis: Double inlet left ventricle. Surgery: Fontan Image: MRI 3D-Angio Center: VRUH, Seville, Spain			8 Age: 1.5 years. Weight: 8 Kg. Diagnosis: Atrioventricular septal defect Surgery: None Image: CT Center: AU, Liban, Beirut.		

VRUH (Virgen Rocio University Hospital, Seville), RWTH (Rheinisch-Westfälische Technische Hochschule Aachen), LUMC (Leiden University Medical Centre), AU (American University, Liban)

Figure 1 Study population demographics, medical images and 3D-models.



doi:10.1186/1532-429X-17-S1-P196
Cite this article as: Valverde et al.: 3D printed cardiovascular models for surgical planning in complex congenital heart diseases. *Journal of Cardiovascular Magnetic Resonance* 2015 **17**(Suppl 1):P196.

Submit your next manuscript to BioMed Central and take full advantage of:

- Convenient online submission
- Thorough peer review
- No space constraints or color figure charges
- Immediate publication on acceptance
- Inclusion in PubMed, CAS, Scopus and Google Scholar
- Research which is freely available for redistribution

Submit your manuscript at www.biomedcentral.com/submit