

Primary chemotherapy followed by anterior craniofacial resection and radiotherapy for paranasal cancer

L. Licitra^{1*}, L. D. Locati¹, R. Cavina¹, I. Garassino¹, F. Mattavelli², N. Pizzi², P. Quattrone³, P. Valagussa⁴, L. Gianni¹, G. Bonadonna¹, C. L. Solero⁵ & G. Cantu²

¹Unit of Medical Oncology A, ²Maxillofacial Surgery Department, ³Pathology Department and ⁴Operations Office, Istituto Nazionale Tumori, Milan; ⁵Second Division of Neurosurgery, Istituto Nazionale Neurologico C. Besta, Milan, Italy

Received 26 March 2002; revised 10 October 2002; accepted 22 November 2002

Background: To study prospectively the activity of primary chemotherapy with cisplatin, fluorouracil and leucovorin (PFL) in patients with paranasal cancer receiving surgery and postoperative radiotherapy.

Patients and methods: Forty-nine patients, previously untreated, with resectable paranasal carcinoma were enrolled. PFL (leucovorin 250 mg/m²/day for 5 days as a 120 h continuous infusion (c.i.), 5-fluorouracil 800 mg/m²/day from day 2 as a 96 h c.i. and cisplatin 100 mg/m² day 2 q 3 weeks) was planned for five courses.

Results: Thirty-two patients (65%) completed three or more chemotherapy courses. Two deaths from thrombotic events were observed after the first cycle. Eight cardiac toxicities were recorded during chemotherapy causing treatment discontinuation. Objective response to PFL was observed in 21 patients [43%; 95% confidence interval (CI) 29% to 58%], including four complete responses (CRs) (8%; 95% CI 2% to 20%) and 17 partial responses (PRs) (35%). Pathological complete remission (pCR) was achieved in eight of 49 patients (16%). At 3 years, overall survival was 69% and event-free survival 57%. Overall and event-free survival in patients achieving pCR is 100%.

Conclusions: PFL is active in paranasal cancer. Patients who attain a pathological complete remission have a favorable prognosis. Cardiovascular complications represent the limiting toxicity. Primary chemotherapy combined with surgery-sparing treatment approaches deserves further investigation.

Key words: anterior craniofacial resection, paranasal cancer, primary chemotherapy

Introduction

Paranasal sinus carcinomas are rare tumors; in particular, ethmoid sinus carcinoma represents only 0.6% of all head and neck cancers. At the time of diagnosis, ethmoidal tumors are mostly at a locally advanced stage, adhering or eroding the cribriform plate, and sometimes invading to the anterior cranial fossa.

Until the 1980s, surgical treatment of paranasal sinus carcinoma varied greatly, and combined therapies often consisted of external beam radiotherapy before or after surgical resection [1–5]. Specific information regarding ethmoidal cancer is difficult to extrapolate since many reports do not distinguish paranasal sinus carcinomas in specific sub-sites and histology. In addition, no standard surgical approach has been available for a long time. Recently, en bloc resection via a combined neurosurgical and transfacial approach, that sometimes includes orbital clearance, has greatly improved the results of surgical intervention. This approach, followed by radiotherapy, produces the highest rate of local control and is now considered by many investigators as the standard treatment [4, 6–9]. However, local disease recurrence still remains the main cause of treatment failure and death [2, 3, 6].

There are very few reports on the use of chemotherapy in paranasal sinus carcinoma and in many instances the studies are retrospective and dealing with a small number of patients with different histotypes, who were enrolled over a prolonged period of time. Different chemotherapies have been studied, but platinum-based regimens were most often applied and afforded an objective response rate ranging from 36% to 84% [10–13]. Some investigators suggested that chemotherapy associated with surgery and radiotherapy could improve the overall treatment outcome, and patients achieving a good clinical, and especially a pathological, response appeared to obtain the largest benefit [12]. Based on these indications from the literature and on the established role of induction chemotherapy in achieving a high response rate for the treatment of head and neck cancer in general, we conducted a prospective phase II study in patients with paranasal cancer to investigate the role of primary chemotherapy within the multidisciplinary approach to these rare tumors.

Patients and methods

Patient selection

Patients with resectable, untreated ethmoid and maxillary carcinoma, who were eligible for anterior craniofacial resection, were enrolled in this prospective non-randomized trial. Inclusion criteria were as follows: histologically

*Correspondence to: Dr L. Licitra, Unit of Medical Oncology A, Istituto Nazionale Tumori, Via Venezian 1, 20133 Milan, Italy. Tel: +39-02-23902-805; Fax: +39-02-23902-804; E-mail: lisa.licitra@istitutotumori.mi.it

proven diagnosis of sinonasal carcinoma; stages I, II, III or IV of the disease, with the exception of patients with intradural extension; age between 18 and 75 years; Eastern Cooperative Oncology Group (ECOG) performance status ≤ 2 ; granulocytes count $\geq 1500/\mu\text{l}$, hemoglobin ≥ 11 g/dl, platelet count $\geq 140000/\mu\text{l}$, serum creatinine concentration ≤ 1.3 mg/dl, serum bilirubin < 1.5 mg/dl, aspartate aminotransferase and alanine aminotransferase $\leq 2 \times$ upper limit for normal. Patients with active infections, serious concomitant illnesses, pre-existing clinically significant peripheral neuropathy and patients with previous myocardial infarction or unstable cardiac disease or ST-T abnormalities at baseline ECG were excluded. Signed informed consent was obtained from all patients before study entry. Stage of disease and toxicity were determined according to the American Joint Committee on Cancer (AJCC)–International Union Against Cancer (UICC) classification (1997) and the National Cancer Institute–Common Toxicity Criteria (2nd edition), respectively.

Evaluation

Pre-treatment work-up included complete physical examination, assessment of performance status, complete blood cell count (CBC), liver and kidney function tests, urinalysis, electrocardiogram, chest X-ray, nasal examination with biopsy and computed tomography (CT) or magnetic resonance imaging (MRI) of paranasal sinuses and skull base. Physical examination, performance status, CBC, routine serum chemistries, urinalysis and chemotherapy toxicity evaluations were assessed before each cycle. Starting from patient number 13, cases with increased cardiovascular risk, such as history of smoking, hypertension and diabetes mellitus, were screened with ECG-Holter and monitored during 5-fluorouracil (5-FU) continuous infusion.

Response to chemotherapy was evaluated based on clinical examination before every other planned course of therapy, and with CT or MRI after the third and fifth course, and in all cases before surgery. Complete remission (CR) was defined as the disappearance of any evidence of tumor. Partial response (PR) was defined as a reduction of $>50\%$ of the measurable lesion's two greatest perpendicular diameters. No response was defined as any response that was less than a PR, stable disease, progression of disease or death while receiving chemotherapy. Overall response and survival rates were analysed with the purpose of intention-to-treat.

Pathological evaluation of surgically treated patients

After surgery, all gross specimens were carefully evaluated and surface labeled sections were taken. The response to chemotherapy was determined by a thorough examination that included 20–25 tumor sections. A complete pathological remission was defined as the absence of any viable tumor cells.

Study design

This is a single institution phase II study. The primary objective was to estimate the activity and toxicity of the PFL combination in patients with paranasal cancer. The treatment plan consisted of primary PFL chemotherapy for five courses followed by anterior craniofacial resection and postoperative external portal beam radiotherapy.

The PFL regimen included leucovorin (LV) 250 mg/m²/day, given for the first 5 days as a 120 h continuous infusion (c.i.), 5-FU 800 mg/m²/day delivered as a 96 h c.i. from day 2 to day 5, and cisplatin (cDDP) 100 mg/m² administered on day 2. Each cycle was repeated every 21 days for five courses. Leucovorin and 5-FU were mixed together in 2 l of 5% dextrose solution supplied daily with ranitidine 200 mg and KCl 30 mEq, shielded from light and were given by c.i. infusion. Cisplatin was dissolved in 500 ml of 0.9% saline and given over 30 min. Before and after the completion of cDDP administration the patients received 1 l of 0.9% saline, containing KCl 30 mEq. Appropriate antiemetics were used before and after administering cDDP. The dose of 5-FU and LV was reduced by 1 day in cases of mucositis grade 3–4, and/or diarrhea grade 3–4 during the previous cycle. If on the

planned day of re-treatment, the WBC and granulocyte count was $< 1.200/\mu\text{l}$ or $800/\mu\text{l}$, respectively, the course was postponed 1 week. No cisplatin dose reduction was planned.

In cases of a progressive disease, stable disease or minimal response after three courses, chemotherapy was discontinued and the patient was referred to surgical treatment. Four weeks after the last chemotherapy cycle, all patients were candidates for anterior craniofacial resection with double approach and to postoperative radiation therapy. En bloc resection and surgical reconstruction were performed as already reported elsewhere [9]. Postoperative radiation at dosages ranging between 50 and 60 Gy was planned with no interruption. The daily fraction was of 2 Gy, five fractions per week, over a period of 5–7 weeks.

The follow-up planned after local-regional treatment consisted of head and neck examination every 3 months for the first year, every 6 months for the second year and on a yearly basis thereafter. Skull base or paranasal MRI or CT and chest X-ray were performed every 6 months for the first 2 years, and on a yearly basis thereafter.

Statistical analysis

Event-free survival (EFS) was calculated from the date at which chemotherapy began to the first evidence of treatment failure, defined as documented disease progression or death, with evidence of disease for non-responding patients. Overall survival (OS) was calculated from the beginning of chemotherapy to death from any cause. The Kaplan–Meier product–limit method was adopted to estimate survival [14]. Differences in EFS and OS according to type of response at surgery (pCR or not pCR) were assessed in all patients who underwent surgery and were tested by means of the log-rank test [15] with two-tailed *P* values.

Results

From November 1996 to October 2000, 49 consecutive patients were enrolled on this trial. Patient characteristics are reported in Tables 1 and 2. The most frequent histotype was adenocarcinoma in 37 patients (76%). Thirty-eight patients (78%) had stage III–IV disease. Objective response to primary chemotherapy was documented in 21 patients [43%; 95% confidence limit (CI) 29% to 58%], including four CRs (8%; 95% CI 2% to 20%) and 17 PRs (35%). After three courses, 19 patients achieved an objective response including one CR. Twenty-one patients (43%) completed the five cycles of planned chemotherapy. After the fifth cycle, three additional CRs were observed. Two patients refused to continue the planned chemotherapy after the third and fourth delivered cycles, respectively. Ninety per cent (19/21) of the responding patients underwent anterior craniofacial resection followed by radiation. Two patients refused to undergo surgical resection. Eighty-two per cent (23/28) of the non-responding patients were submitted to surgical treatment and radiotherapy. Two patients died after the first course of chemotherapy, three patients were submitted to radiotherapy alone, two for progressive disease experienced during chemotherapy, while one patient was judged unfit for surgical resection due to cardiovascular toxicity developed during primary chemotherapy. Overall, 42 patients (86%) underwent surgical treatment. Surgical margins were clear in all but one patient. Histological assessment identified complete pathological remission (pCR) in eight patients (16%). The disease stage of these patients was stage I in two, stage II in one, stage III in two and stage IV in three patients. Six of them had an histological diagnosis of adenocarcinoma. Only three of the eight

Table 1. Patient characteristics

Age (years)	
Median	55
Range	32–75
Gender	
Male	46
Female	3
PS (ECOG)	
1	49
Range	0–1
Histology	
Adenocarcinoma	37
Squamous cell carcinoma	11
Schneiderian type carcinoma	1
Primary site	
Ethmoid sinus	47
Maxillary sinus	2
Risk factors	
Wood dust exposition	14
Leather	14
Cement	2
Unrelated	19

ECOG, Eastern Cooperative Oncology Group.

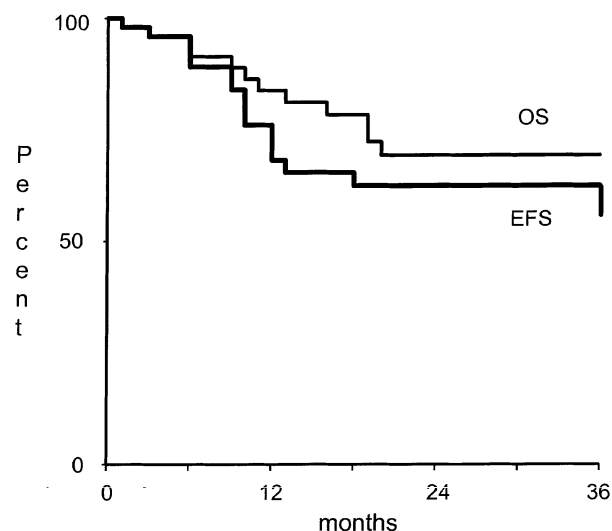
Table 2. Staging according to American Joint Committee on Cancer (AJCC)–International Union Against Cancer (UICC) classification (1997)

Stage	T1	T2	T3	T4
N0	6	5	14	20
N1	–	–	–	1
N2	–	–	1	1
N3	–	–	1	–
Total	6	5	16	22

achieving pCRs were defined as complete responders based on radiological examination before surgery.

Postoperative and late complications were not significantly different from those reported in a previous case series treated with surgery and radiotherapy at our institute [9]. Forty-one patients (84%) underwent radiotherapy at total doses ranging from 39 to 74 Gy (median dose 56 Gy). Doses exceeding 60 Gy were delivered in patients not undergoing craniofacial resection.

At a median follow-up of 26 months (range 1–59 months) 31 patients (63%) were alive without evidence of disease. The 3-year OS rate for the entire series was 69%, while the 3-year EFS rate was 57% (Figure 1). As displayed in Figures 2 and 3, patients achieving pCR had a better outcome than patients not achieving pCR (3-year OS: pCR 100%, no pCR 65%, $P = 0.09$; 3-year EFS: pCR 100%, no pCR 43%, $P = 0.03$).

**Figure 1.** Overall results in terms of survival and event-free survival.

Twelve patients (24%) relapsed, 11 of which did so within 1 year of the end of radiotherapy. Relapse was at the primary site in six cases, involved the cervical lymph nodes in two, consisted of local relapse and cervical lymph node involvement in two, and of local relapse and lung metastases in the last two patients. Only the two patients who underwent lymph nodal salvage resection are alive and well. Palliative chemotherapy was resorted to in one case and radiotherapy in three patients.

Toxicity

All 49 patients treated with PFL were assessable for toxicity. The incidence of toxicities is reported in Table 3.

A total of 171 PFL cycles [median, four courses (range 1–5)] were given. One hundred courses (58%) were given at full dose. Eight patients discontinued chemotherapy due to treatment limiting toxicity. Thirty-two patients (65%) completed three or more courses of chemotherapy. Two deaths, one due to a cerebral thrombosis and the other to an abdominal thrombosis occurred after the first cycle of therapy. Both deaths were considered to be treatment related. Eight episodes of treatment-limiting toxicity were observed during 5-FU intravenous infusion: four patients had cardiac ischemia (8%), three had cardiac arrhythmia and one patient had severe hypertension. Planned chemotherapy was discontinued in all eight patients after the toxic episode. Two of these patients could not undergo surgery due to cardiac impairment, while one of the remaining six undergoing surgery died postoperatively due to cardiac complications. After patient number 13, an ECG-Holter screening and monitoring of high risk patients was performed. No patient was found to have an abnormal baseline ECG-Holter evaluation. In four patients chemotherapy was discontinued based on the appearance of abnormalities following ECG-Holter evaluation: treatment was discontinued during cycle 1 in one patient, during cycle 2 in two cases and during cycle 4 in one case. In every case after treatment discontinuation, ECG evaluation proved normal within a few days.

The most frequent toxicity of the PFL regimen was grade 2–3 stomatitis, occurring in 76% of patients. Grade 3 and 4 neutro-

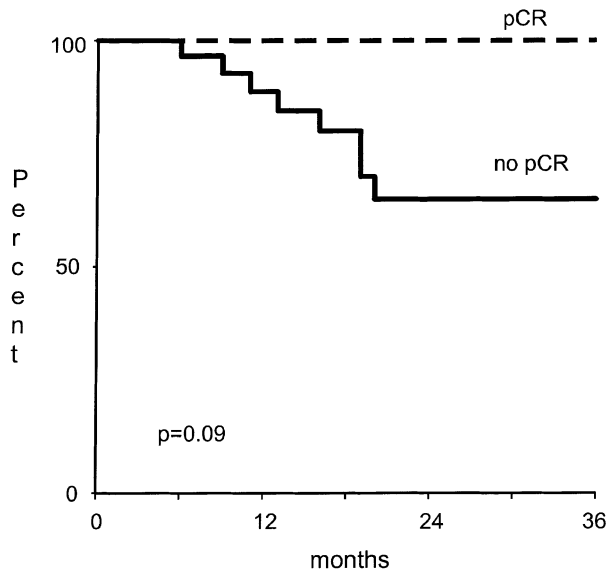


Figure 2. Overall survival as a function of complete pathological remission (pCR). *P* values correspond to the 3-year overall survival (OS)/event-free survival (EFS).

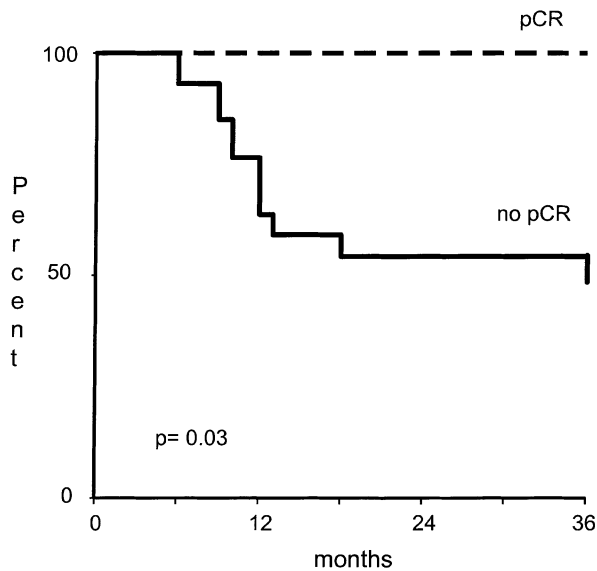


Figure 3. Event-free survival as a function of complete pathological remission (pCR). *P* values correspond to 3-year overall survival (OS)/event-free survival (EFS).

penia occurred in 37% of patients. No significant renal toxicity was recorded. There was one case of reversible toxic hepatitis in a patient without liver infectious disease or prior liver impairment.

Discussion

To our knowledge, this is the first report of a prospective study adopting the administration of the PFL regimen for five courses in patients with sinonasal tumors, mostly characterized by adenocarcinoma histology. The main goals of this study were to evalu-

Table 3. Incidence of toxicity according to National Cancer Institute–Common Toxicity Criteria (NCI-CTC) criteria

	NCI-CTC toxicity grade				
	0	1	2	3	4
Nausea	24 ^a	50	24	2	–
Vomiting	47	12	33	8	–
Stomatitis	18	6	53	23	–
Creatinine	84	16	–	–	–
Diarrhea	88	6	6	–	–
Leukocytes	37	35	26	2	–
Neutrophils	31	8	24	31	6
Platelets	82	16	2	–	–
Hemoglobin	10	74	14	2	–
Arrhythmia	94	6	–	–	–
Ischemia	92	–	4	4	–
Hypertension	96	2	–	2	–
Transaminase	98	–	–	2	–

^aPercentage of patients.

ate the activity and the feasibility of the PFL regimen, and to assess the potential of such a chemotherapy regimen for improving the poor survival of these patients (as has been shown from historical series), although we are aware that the exclusion from this trial of patients with intracranial tumor extension could be partially responsible for potentially better outcomes. In addition, patients were studied prospectively to evaluate the possibility of early detection of those individuals with good prognosis in whom demolitive surgery could eventually be spared by resorting to radiotherapy as the only procedure to achieve definitive local control. The results of our investigation show that prolonged PFL therapy is feasible, active (43% overall response rate) and capable of achieving a pCR that leads to long-lasting relapse-free survival in about one fifth of patients who also underwent surgery and radiotherapy.

Several considerations were taken into account in the design and the conduct of the trial. To improve the activity of induction regimens containing cisplatin and fluorouracil in head and neck cancer, many strategies have been adopted, including the administration of more than three cycles of chemotherapy and biochemical modulation of 5-FU with LV [16]. Selection of the PFL regimen was based on its established antitumor activity in head and neck cancers [17–20]. In advanced squamous cell carcinoma of the head and neck the administration of two to three cycles of PFL can obtain an overall response rate of 80% and a complete response rate of 66%, with a high proportion of patients reaching a pathological remission [21]. Other investigators reported lower antitumor activity and described substantial bone marrow toxicity, stomatitis and toxic deaths [22, 23]. Little is known about the ideal duration of preoperative chemotherapy for maximizing the likelihood of a complete pathological remission. However, it has consistently been observed that, regardless of the subsequent surgery and/or radiotherapy, patients achieving a clinical com-

plete response with induction chemotherapy have a better prognosis than the less responsive or unresponsive patients, and that patients with a good response to primary chemotherapy may be successfully treated with radiotherapy alone [24]. A favourable outcome has been reported particularly in patients with complete pathological remission at surgery [25]. In addition, it has been shown that the administration of three cycles of PFL chemotherapy instead of two increases the percentage of clinical complete responses, implying that the number of courses may be important in multimodality treatment programs aimed at increasing the rate of pathological remission [26]. Based on all of the above evidence, we empirically selected to administer five cycles of preoperative PFL in our study to maximize the likelihood of achieving pCR.

In agreement with such an empiric rationale, our experience has shown that after three treatment cycles one patient only was in radiological CR, while three additional patients reached radiological CR after five cycles. Such data suggest that patients can benefit from a prolonged treatment duration.

Of note, and unlike other trials, our study included mostly patients with adenocarcinoma. In this respect, our experience shows that sinonasal adenocarcinoma is a chemosensitive tumor, and that chemotherapy may accomplish a high rate of complete pathological remissions. Furthermore, a complete pathological response was observed in every stage subgroup, suggesting that sensitivity to PFL was not related to tumor extension. This observation is different from what is described in the literature dealing with head and neck squamous cell cancer [24]. In this type of histology, the response rate is reported as inversely related to stage. Our findings may therefore lead to the consideration that all patients with sinonasal carcinoma, independent of histological type and tumor extension, could be candidates for primary chemotherapy.

The results of our study indicate that there was a substantial lack of concordance between the radiological findings of response and the pathological findings of complete remission at surgery. Indeed, only half of the patients with complete pathological remission were correctly classified on imaging as having a complete response. The inability of defining at which treatment cycle tumor shrinkage can be an indication of complete pathological remission limits the possibility of tailoring treatment duration in individual patients, and undermines the possibility of reliably identifying those patients in whom surgery could be avoided, as well as those for whom PFL will bring little benefit. There may be many reasons for the discordance between radiological and surgical findings. One resides in the apparently low specificity of CT and MRI. As far as sinonasal cancers are concerned, there is some indication that MRI is superior to CT in discriminating between the extent of the tumor and other pathological changes (such as inflammation or secretion), but no data are available concerning the role of MRI in assessing the response after chemotherapy [27]. Little is known concerning the accuracy of FDG-PET in correctly classifying pathological tumor response to chemotherapy in the head and neck cancer patient, and no experience has been reported in paranasal sinus tumors [28].

The need for a sensitive and dependable measure of response for appropriate decision making in individual patients during

treatment is further supported by the consideration that the toxicity of PFL was not minor. Our study showed that toxicity could be severe even if cisplatin was administered on a single day at the dose of 100 mg/m², and even when the dosages of 5-FU and LV were reduced by 1 day after a prior course with mucosal/bone marrow toxicity. The severity and frequency of stomatitis and neutropenia were similar to those reported by others [18, 19, 21], even if the dosages of cDDP and/or 5-FU are not completely comparable. As expected from the addition of LV both toxicities seem to be less severe than those reported for standard cDDP and 5-FU treatment.

As in the study reported by Pfister et al. [23], all serious adverse events occurred after the first treatment cycle. We did not observe any toxic deaths due to infection, suggesting that planned dose modifications and dose reductions were adequate in preventing major problems due to bone marrow suppression and stomatitis. Unexpectedly, cardiovascular toxicity was substantial causing two toxic deaths and thus it represented the limiting toxicity. Fatal events (including sudden deaths), vascular accidents and sepsis have been reported at different rates ranging from 0% to 18% in different series [23, 29]. The occurrence of an excessive rate of unpredictable cardiovascular events early during the present study prompted us, based on the experience of Rezkalla et al. [30], to screen and monitor patients at high risk for heart function by ECG-Holter during therapy. The endpoint was to discontinue chemotherapy if asymptomatic cardiac alterations were detected early during infusion. Importantly, after adopting this policy, no additional fatal cardiovascular events were recorded.

In conclusion, this study shows that prolonged primary chemotherapy with PFL is active in paranasal cancer, and toxicity is manageable provided that an adequate cardiovascular evaluation before chemotherapy is performed.

Due to the fact that paranasal cancer is a rare disease, a prospective randomized study of the impact of chemotherapy on local tumor control, disease-free survival and overall survival is not feasible. However, the results of this study suggest that primary chemotherapy may play a role in surgery-sparing treatment approaches. Such a potential role should be explored prospectively by using new agents and investigating the ability of diagnostic tools (e.g. with serial positron emission tomography) and molecular phenotyping of the primary tumor in reliably predicting pathological complete response and, eventually, avoiding surgery. Such studies are in progress at our institution.

Acknowledgements

The preliminary results of this research were submitted at the Thirty-sixth Annual Meeting of the American Society of Clinical Oncology that took place on May 20–23, 2000 in New Orleans, Louisiana. This work was supported in part by the Italian Association for Cancer Research (AIRC).

References

1. Cheng V, Wang C. Carcinomas of the paranasal sinuses. *Cancer* 1977; 40: 3038–3041.

2. Bush SE, Bagshaw MA. Carcinoma of the paranasal sinuses. *Cancer* 1982; 50: 154–158.
3. Spiro JD, Soo KC, Spiro RH. Squamous carcinoma of the nasal cavity and paranasal sinuses. *Am J Surg* 1989; 158: 328–332.
4. Lavertu P, Roberts JK, Kraus DH et al. Squamous cell carcinoma of the paranasal sinuses: the Cleveland Clinic experience 1977–1986. *Laryngoscope* 1989; 99: 1130–1136.
5. Waldron JN, O'Sullivan B, Warde P et al. Ethmoid sinus cancer: twenty-nine cases managed with primary radiation. *Int J Radiat Oncol Biol Phys* 1998; 41: 361–369.
6. Jiang GL, Morrison WH, Garden AS et al. Ethmoid sinus carcinomas: natural history and treatment results. *Radiother Oncol* 1998; 49: 21–27.
7. Dilhuydy JM, Lagarde P, Allal AS et al. Ethmoidal cancers: a retrospective study of 22 cases. *Int J Radiat Oncol Biol Phys* 1993; 25: 113–116.
8. Ketcham AS, Van Buren JM. Tumors of the paranasal sinuses: a therapeutic challenge. *Am J Surg* 1985; 150: 406–413.
9. Cantù G, Solero CL, Mariani L et al. Anterior craniofacial resection for malignant ethmoid tumors: a series of 91 patients. *Head Neck* 1999; 21: 185–191.
10. LoRusso P, Tapazoglou E, Kish JA et al. Chemotherapy for paranasal sinus carcinoma. A 10-year experience at Wayne State University. *Cancer* 1988; 62: 1–5.
11. Rosen A, Vokes EE, Scher N et al. Locoregionally advanced paranasal sinus carcinoma. Favorable survival with multimodality therapy. *Arch Otolaryngol Head Neck Surg* 1993; 119: 743–746.
12. Brasnu D, Laccourreye O, Bassot V et al. Cisplatin-based neoadjuvant chemotherapy and combined resection for ethmoid sinus adenocarcinoma reaching and/or invading the skull base. *Arch Otolaryngol Head Neck Surg* 1996; 122: 765–768.
13. Björk-Eriksson T, Mercke C, Petruson B et al. Potential impact on tumor control and organ preservation with cisplatin and 5-fluorouracil for patients with advanced tumors of the paranasal sinuses and nasal fossa. A prospective pilot study. *Cancer* 1992; 70: 2615–2620.
14. Kaplan EL, Meier P. Nonparametric estimation from incomplete observations. *J Am Stat Assoc* 1958; 53: 457–481.
15. Peto R, Peto J. Asymptotically efficient rank invariant test procedures. *J R Stat Soc A* 1972; 135: 185–198.
16. Ensley J, Kish J, Tapazoglou E et al. An intensive, five course, alternating combination chemotherapy induction regimen used in patients with advanced, unresectable head and neck cancer. *J Clin Oncol* 1988; 6: 1147–1153.
17. Vokes EE, Schilsky RL, Weichselbaum RR et al. Induction chemotherapy with cisplatin, fluorouracil and high-dose leucovorin for locally advanced head and neck cancer: a clinical and pharmacologic analysis. *J Clin Oncol* 1990; 8: 241–247.
18. Clark JR, Busse PM, Norris CM Jr et al. Induction chemotherapy with cisplatin, fluorouracil and high-dose leucovorin for squamous cell carcinoma of the head and neck: long-term results. *J Clin Oncol* 1997; 15: 3100–3110.
19. Schneider M, Etienne MC, Milano G et al. Phase II trial of cisplatin, fluorouracil and pure folinic acid for locally advanced head and neck cancer: a pharmacokinetic and clinical survey. *J Clin Oncol* 1995; 13: 1656–1662.
20. Alba E, Sanchez-Chaparro MA, Alonso L et al. Cisplatin, 5-fluorouracil and high dose folinic in patients with advanced unresectable head and neck cancer. *Am J Clin Oncol* 1996; 19: 140–143.
21. Dreyfuss AI, Clark JR, Wright JE et al. Continuous infusion high-dose leucovorin with 5-fluorouracil and cisplatin for untreated stage IV carcinoma of the head and neck. *Ann Intern Med* 1990; 112: 167–172.
22. Papadimitrakopoulou VA, Dimery IW, Lee JJ et al. Cisplatin, fluorouracil, and L-leucovorin induction chemotherapy for locally advanced head and neck cancer: the M.D. Anderson Cancer Center experience. *Cancer J Sci Am* 1997; 3: 92–99.
23. Pfister DG, Bajorin D, Motzer R et al. Cisplatin, fluorouracil, and leucovorin. Increased toxicity without improved response in squamous cell head and neck cancer. *Arch Otolaryngol Head Neck Surg* 1994; 120: 89–95.
24. Cognetti F, Pinnaro P, Ruggeri EM et al. Prognostic factors for chemotherapy response and survival using combination chemotherapy as initial treatment of advanced head and neck squamous cell cancer. *J Clin Oncol* 1989; 7: 829–837.
25. Al-Kourainy K, Kish J, Ensley J et al. Achievement of superior survival for histologically negative versus histologically positive clinically complete responders to cisplatin combination in patients with locally advanced head and neck cancer. *Cancer* 1987; 59: 233–238.
26. Rooney M, Kish J, Jacobs J et al. Improved complete response rate and survival in advanced head and neck cancer after three-course induction therapy with 120-hour 5-FU infusion and cisplatin. *Cancer* 1985; 55: 1123–1128.
27. Lund VJ, Howard DJ, Lloyd GA et al. Magnetic resonance imaging of paranasal sinus tumors for craniofacial resection. *Head Neck* 1989; 11: 279–283.
28. Lowe JV, Dunphy FR, Varvares M et al. Evaluation of chemotherapy response in patients with advanced head and neck cancer using [F-18] fluorodeoxyglucose positron emission tomography. *Head Neck* 1997; 19: 666–674.
29. Vokes EE, Weichselbaum RR, Mick R et al. Favorable long-term survival following induction chemotherapy with cisplatin, fluorouracil and leucovorin and concomitant chemoradiotherapy for locally advanced head and neck cancer. *J Natl Cancer Inst* 1992; 84: 877–882.
30. Rezkalla S, Kloner RA, Ensley J et al. Continuous ambulatory ECG monitoring during fluorouracil therapy: a prospective study. *J Clin Oncol* 1989; 7: 509–514.