

Blocked Fallopian Tubes - Treatment Options

Gautam Allahbadia

Medical Director, Deccan Fertility Clinic
& Keyhole Surgery Center,
Shivaji Park, Mumbai and Rotunda
The Center for Human Reproduction Bandra (W),
Mumbai - 400 050. India.
91 98200 96000 Email : drallah@gmailcom

Editorial

Blocked Fallopian Tubes – Treatment Options

Tubal factors are said to account for about 20 to 30 percent of all infertility cases around the world¹. The main contributing factor: blocked fallopian tubes. A blocked fallopian tube, although not necessarily life threatening, can be a very serious cause for concern because although conventional surgery may provide relief from the condition, damage to the tubes are generally considered irreversible and hence, subsequent pregnancy may prove almost impossible - but not quite.

Blocked fallopian tubes following genital infection with *Chlamydia trachomatis* is an escalating global public health concern causing considerable morbidity and socioeconomic burden worldwide. The major clinical manifestations of genital chlamydial infection in women include mucopurulent cervicitis, endometritis and pelvic inflammatory disease². Genital infection with *C. trachomatis* markedly enhances the risk for reproductive tract sequelae in women, including tubal factor infertility, chronic pain and ectopic pregnancy. Tubal infertility following chlamydial infection is one of the leading causes of infertility in the developed world.

A consequence of assisted reproduction technology in infertility management has been a decline in tubal surgery. Microsurgery to correct localized damage has the advantage of long-standing restoration of fertility. A simple prognostic classification is lacking. The severity of the tubal damage and the health of the mucosa is key in determining outcome. Visualization of the tube by hysterosalpingography (HSG) or by sonosalpingography (The Sion Test) has limitations³. Laparoscopy has the advantage of inspecting the tube and its relation to other pelvic organs. Differentiating between anatomical obstruction or spasm at the uterine end of the tube might be achieved by selective salpingography and tubal catheterization (SSTC) and should precede IVF⁴. Laparoscopic Microsurgery

should be provided, if the skills are available, where cannulation has failed⁵. Laparoscopic microsurgical tubal reanastomosis after tubal sterilization can be performed using a remote-controlled robotic system. Systematization of the operative steps allowed for operative times that compare favorably with the time needed for open microsurgical technique⁵. Transvaginal hydrolaparoscopy and fertiloscopy appear to be an alternative to hysterosalpingography as a first line procedure to investigate the tubal factor. Assessment of mucosal health by fertiloscopy is claimed to be less invasive. Fertiloscopy includes hydrolaparoscopy, tubal patency testing by dye hydrotubation, salpingoscopy and objective demonstration if the mucosa is healthy⁶. Where the mucosa is unhealthy, surgery is not justified; early referral for IVF is indicated. The prognostic value of salpingoscopy during operative laparoscopy for tubal factor infertility in terms of reproductive outcome has been confirmed⁷. The prognostic significance of microsalingoscopy needs further validation in large-scale clinical trials⁷.

A decrease in expertise in tubal microsurgery has resulted largely from the use of IVF as the treatment option for most causes of infertility and more specifically for tubal factor infertility. Selective salpingography and tubal cannulation have a unique role in the management of tubal infertility and should be offered to selected candidates prior to IVF⁸. Tubal cannulation can be used effectively to restore patency in a proportion of cases of proximal tubal obstruction thus avoiding the need for expensive assisted reproductive techniques⁸. Another option for women with blocked tubes and hoping for a successful pregnancy is to resort to Endoscopic Fallopian Tube Recanalisation; which works best with proximal tubal occlusion & a method of Tactile Cannulation using Laparoscopic guidance that has been pioneered in India⁹. (Figures 1 & 2).

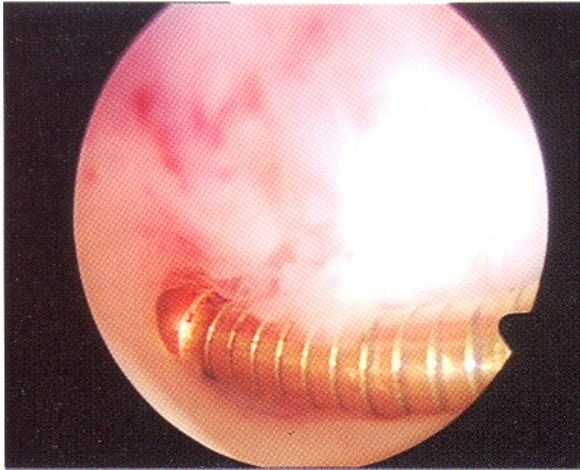


Figure 1. The Glide wire seen in the proximal portion of the fallopian tube after tactile cannulation under laparoscopic guidance.

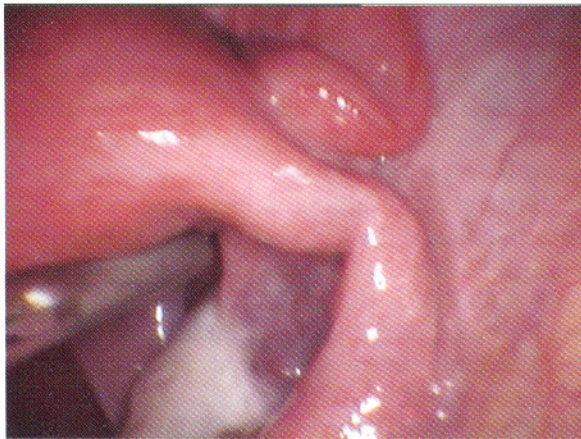


Figure 1. The Glide wire seen in the proximal portion of the fallopian tube after tactile cannulation under laparoscopic guidance.

There are many different surgery techniques for unblocking fallopian tubes and the differences generally involve the length of the incision, the area affected, the type of blockage present, and the method of unblocking applied (e.g. complete removal or creation of another opening).¹⁰ Tubal reanastomosis involves the complete removal of the blocked portion of the tube and a subsequent joining of the healthy ends. This procedure is usually done today either with Laparotomy or Laparoscopy.

Salpingectomy involves the surgical removal of the infected or blocked fallopian tube. It is usually done on

patients who have a hydrosalpinx and want to improve their chances of pregnancy through in vitro fertilization (IVF).¹¹ This procedure is preferred over salpingostomy which is another surgical procedure available for dealing with hydrosalpinges (fluid-filled blocked fallopian tubes).¹² Salpingostomy is a procedure that requires an incision through the affected fallopian tube. In neosalpingostomy, the idea is to create a new opening in the part of the tube closest to the ovary while in linear salpingostomy the incision serves as the pathway to release the blockage. Neosalpingostomy is generally used in dealing with hydrosalpinges. This technique however more often than not merely provides temporary unblocking as it is a common occurrence for scar tissue growth to reseal the new opening created by neosalpingostomy thereby effectively blocking of the tube once more. When the problem is a partial blockage or a scarring in the fimbriae (fingerlike projections at the end of the fallopian tube near the ovary), Fimbrioplasty is an option where the blockage or the scar adhesions are removed and the fringed ends are rebuilt such that wafting motion of the fimbriae are restored. All these surgical interventions are being replaced gradually by Assisted Reproductive Technologies.

Conclusion

Treatment should be individualized, based upon the findings of the tubal investigation, the couple's wishes and the costs involved. The age of the female is the most important factor that affects the outcome with both treatment options. The live birth rate per cycle with IVF is 28% at best, whereas surgical intervention on the tubes if done with microsurgical principles yields a birth rate that exceeds 45%, without increased risk of multiple pregnancy. It offers the couple multiple cycles in which to achieve conception naturally, and the opportunity to have more than one pregnancy from a single intervention. The real dilemma lies with the "hypermarketing" of IVF, and its frequent use as primary treatment for infertility. The dilemma is heightened by the fact that reconstructive tubal microsurgery is being taught and practised less and less, thereby eliminating this credible surgical option in most centres.

References

1. Das S, Nardo LG, Seif MW. Proximal tubal disease: the place for tubal cannulation. *Reprod Biomed Online*. 2007;15:383-8.
2. den Hartog JE, Morr  SA, Land JA. Chlamydia

- trachomatis-associated tubal factor subfertility: Immunogenetic aspects and serological screening. *Hum Reprod Update*. 2006;12:719-30.
3. Allahbadia GN, Nalawade YV, Patkar VD., Niyogi GM, Shah PK. The Sion Test. *Aust NZ J Obstet Gynaecol* 1992;32:67-70.
 4. Rawal N, Haddad N, Abbott GT. Selective salpingography and fallopian tube recanalisation: experience from a district general hospital. *J Obstet Gynaecol*. 2005;25:586-8.
 5. Vlahos NF, Bankowski BJ, King JA, Shiller DA. Laparoscopic tubal reanastomosis using robotics: experience from a teaching institution. *J Laparoendosc Adv Surg Tech A*. 2007;17:180-5.
 6. Watrelot A. Place of transvaginal fertiloscopy in the management of tubal factor disease. *Reprod Biomed Online*. 2007;15:389-95.
 7. Marana R, Catalano GF, Muzii L. Salpingoscopy. *Curr Opin Obstet Gynecol*. 2003;15:333-6.
 8. Papaioannou S, Afnan M, Sharif K. The role of selective salpingography and tubal catheterization in the management of the infertile couple. *Curr Opin Obstet Gynecol*. 2004;16:325-9.
 9. Allahbadia GN, Mangeshkar P, Pai Dhungat PB, Desai SK, Gudi AA, Arya A. Hysteroscopic fallopian tube recanalization using a flexible guide cannula and hydrophilic guide wire. *Gynaecological Endoscopy* 2000;9:31-35
 10. Rodgers AK, Goldberg JM, Hammel JP, Falcone T. Tubal anastomosis by robotic compared with outpatient minilaparotomy. *Obstet Gynecol*. 2007;109:1375-80.
 11. Ozmen B, Diedrich K, Al-Hasani S. Hydrosalpinx and IVF: assessment of treatments implemented prior to IVF. *Reprod Biomed Online*. 2007;14:235-41.
 12. Strandell A. Treatment of hydrosalpinx in the patient undergoing assisted reproduction. *Curr Opin Obstet Gynecol*. 2007;19:360-5.

*Gautam Allahbadia

*Medical Director, Deccan Fertility Clinic & Keyhole Surgery Center,
Shivaji Park, Mumbai
and

Rotunda - The Center For Human Reproduction
Bandra (W) 400 050, India
91 98200 96000 Email: drallah@gmail.com