

# Temporal lobe epilepsy and emotion recognition without amygdala: a case study of Urbach-Wiethe disease and review of the literature

Stefano Meletti<sup>1</sup>, Gaetano Cantalupo<sup>2</sup>, Francesca Santoro<sup>3</sup>,  
Francesca Benuzzi<sup>1</sup>, Anna Federica Marliani<sup>4</sup>,  
Carlo Alberto Tassinari<sup>5</sup>, Guido Rubboli<sup>3,6</sup>

<sup>1</sup> Department of Biomedical Sciences, Metabolism, and Neurosciences; University of Modena and Reggio Emilia, Modena

<sup>2</sup> Department of Life and Reproduction Sciences, University of Verona, Verona

<sup>3</sup> IRCCS Institute of Neurological Sciences, Neurology Unit, Bellaria Hospital, Bologna

<sup>4</sup> IRCCS Institute of Neurological Sciences, Neuroradiology Unit, Bellaria Hospital, Bologna

<sup>5</sup> Department of Neuroscience, University of Parma, Parma, Italy

<sup>6</sup> Danish Epilepsy Centre, Filadelfia/University of Copenhagen, Dianalund, Denmark

Received January 29, 2014; Accepted August 10, 2014

**ABSTRACT** – We describe the epilepsy features and emotion recognition abilities (recognition of basic facial emotions and recognition of emotional prosody) in a patient with Urbach-Wiethe disease with bilateral amygdala calcifications. Our data, supported by ictal video-EEG recording, indicated that our patient suffered from mesial temporal lobe epilepsy. Emotion recognition abilities were compared to those of healthy controls and those of patients with bilateral mesial temporal lobe epilepsy. Our patient showed a selective impairment of the recognition of facial expression of fear, whereas recognition of emotional prosody was preserved, in contrast to bilateral mesial temporal lobe epilepsy patients that presented with deficits in both domains. We also reviewed the literature on epilepsy in Urbach-Wiethe disease (41 patients). Our findings suggest that in Urbach-Wiethe disease, the circumscribed damage of both amygdalae results in a selective dysfunction of fearful face processing, in contrast to bilateral mesial temporal lobe epilepsy patients who present with a widespread and multimodal impairment in the judgement of emotional stimuli.

**Key words:** temporal lobe epilepsy, Urbach-Wiethe disease, lipid proteinosis, amygdala, emotion recognition, emotional prosody

**Correspondence:**

Guido Rubboli  
Danish Epilepsy Center,  
Kolonivej 1-4293 Dianalund,  
Denmark  
<guru@filadelfia.dk>

Lipoid proteinosis or Urbach-Wiethe disease (UWD) (OMIM 247100), is a rare autosomal recessive disorder, mapped to chromosome 1q21, characterized by deposition of hyaline material in skin and mucosae. UWD starts in early infancy and progresses

over the years with widespread warty hyperkeratosis, skin scarring, and infiltration of the upper respiratory tract mucosae (Urbach and Wiethe, 1929). Extra-cutaneous features include neuropsychological sequelae, psychiatric disturbances, and epilepsy, often in association with peculiar “bean-shaped” bilateral amygdala calcifications (Friedman *et al.*, 1984). Studies of UWD have explored mainly neuropsychological compromise due to amygdalae damage (Adolphs *et al.*, 1994; Hurlemann *et al.*, 2007), whereas epilepsy has been rarely investigated (Newton *et al.*, 1971). In this report, we describe the epilepsy features and abilities to process stimuli with emotional valence in a patient with UWD, comparing these latter abilities with those of healthy controls (HC) and those of patients with bilateral mesial temporal lobe epilepsy (BMTLE).

## Case study

A 36-year-old, right-handed female, born from consanguineous parents and whose genetic findings were previously published (Lupo *et al.*, 2005), presented with hoarseness of the voice, dysphonia, and lesions of the oral mucosa at the age of two years; over the years, skin thickening and cutaneous lesions had appeared. When she was 12 years old, the diagnosis of UWD was made. Her epilepsy started at the age of eight years with a tonic-clonic seizure and with episodes characterized by olfactory hallucinations, oro-alimentary and upper limbs automatisms, *déjà vécu*, and, occasionally, impairment of consciousness. She started antiepileptic treatment at the age of 12 years after two additional convulsive seizures. At the time of our observation, the patient’s seizures were characterized by a “sensation of something touching her nose”, *déjà vécu*, pallor, and, rarely, impairment of consciousness. Seizures occurred several times per month, poorly controlled by phenobarbital and clobazam; previously, carbamazepine and phenytoin resulted ineffective.

Clinical examination showed a dysphonic whispering voice and multiple hyperkeratotic skin lesions. Psychiatric evaluation diagnosed anxiety and mild depression.

Brain CT and MRI showed bilateral symmetric calcifications with the typical “comma-shaped” morphology in the antero-medial aspects of temporal lobes involving the amygdaloid complex and the perirhinal cortex (*figure 1A*).

## Video-EEG study

Wakefulness and sleep EEG showed sporadic bilateral sharp theta activities in temporal leads. Three stereotyped seizures were collected during long-

term video-EEG monitoring. Clinically, the patient sat abruptly in bed from the supine position, referring to a “sensation of something touching her nose”, associated with a *déjà vécu* feeling. Consciousness was not impaired. Ictal EEG showed a diffuse “flattening”, followed by a rhythmic sharp theta activity in the right temporal leads, spreading to fronto-central regions (*figure 1B*).

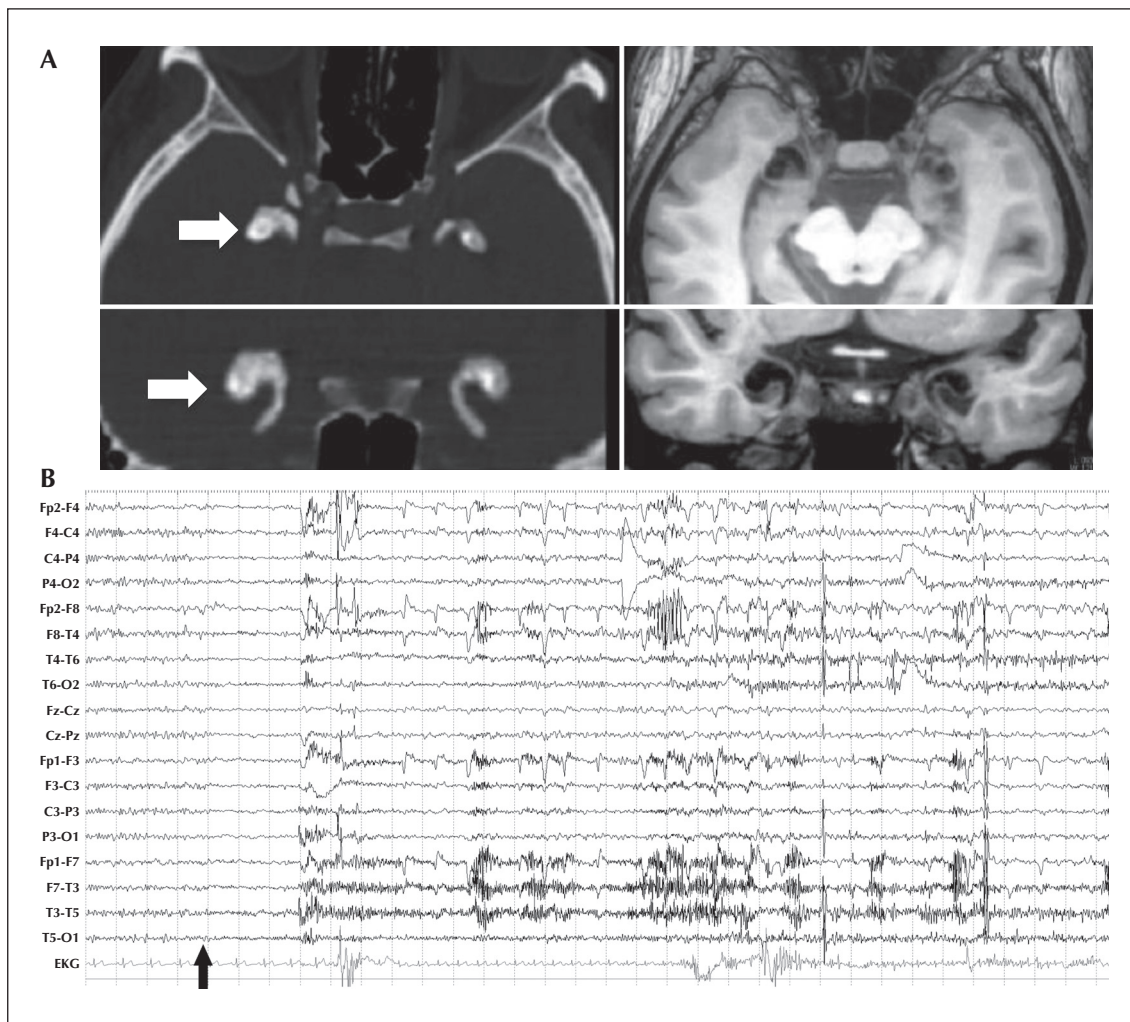
## Neuropsychological study

Emotion recognition abilities were evaluated by using two tasks that required the recognition of emotional facial expressions and emotional prosody (Bonora *et al.*, 2011). We compared the performances of our patient respectively with those of a healthy control (HC) group of 12 women matched for education and age, and with those of a group of 12 women with BMTLE (*table 1*). The UWD patient was tested twice, six months apart. Informed consent from all participants and local ethical committee approval were obtained. Neuropsychological assessment of the patient, details of the neuropsychological tasks, and characteristics of the HC group and BMTLE patients are reported in *Supplementary material* and in *table 2*.

In *table 1* and *figure 2*, emotion recognition scores of the UWD patient, healthy control group, and BMTLE patients are reported. In comparison to HC, the UWD patient presented with a marked impairment of the recognition of fearful faces (60% and 40% correct recognition at test and retest, respectively;  $>2$  SD relative to HC scores), whereas she correctly recognized all other facial expressions. In addition, her score in emotional prosody recognition was within the range of the HC group. In contrast to the UWD patient, emotion recognition in the BMTLE group was characterized by low scores in the recognition of all facial and vocal expressions, except happiness.

## Discussion

Although epilepsy is reported to occur in about 30% of patients with UWD, it has received marginal attention, and ictal seizure patterns have never been documented. Our patient reported an ictal semiology characterized by sensory and olfactory hallucinations, *déjà vécu*, paleness, oro-alimentary and upper limb automatisms, and, occasionally, impairment of consciousness. On video-EEG monitoring, we recorded brief seizures characterized by sensory hallucinations and *déjà vécu*, associated with epileptic activity in the right temporal leads. Lack of impairment of consciousness was probably due to the brief duration of the discharge and the mainly unilateral localization. These findings are consistent with seizure onset in



**Figure 1.** A) Brain CT: axial and coronal reconstruction with bone density magnification (left panel); the white arrows indicate bean-shaped calcification of the amygdalae. Brain MRI axial and coronal inversion recovery sequences (right panel); the calcified amygdalae appeared as marked hypo-intensity of the medial temporal lobe region. B) Ictal EEG recording. The black arrow indicates the clinical onset of the seizure. The EEG shows a widespread desynchronization during the three seconds following clinical onset and rhythmic theta activity is then evident on the right temporal leads. ECG trace shows ictal tachycardia.

the mesial temporal lobe structures, as hypothesized in previous reports (Newton *et al.*, 1971). Reviewing the literature on epilepsy in UWD using the Pubmed electronic database (search terms: “Urbach Wiethe Disease”, “Lipoid Proteinosis”, “epilepsy”, and “seizures”), we retrieved 18 articles, describing 41 patients with UWD and epilepsy (table 3). In 21 cases (50%) with bilateral amygdalae calcifications, seizure semiology was referred to as having, or suggested to have, temporal lobe involvement. In 10 other cases, seizures were non-specifically described as “convulsive”. Auras, described in 10 cases, were characterized by olfactory hallucinations (5 patients) and *déjà vu/déjà vécu* (5 patients). Interestingly, UWD patients, including the patient presented here, never reported ictal fear, further supporting the concept that functional, or partly functional, amygdalae are required to per-

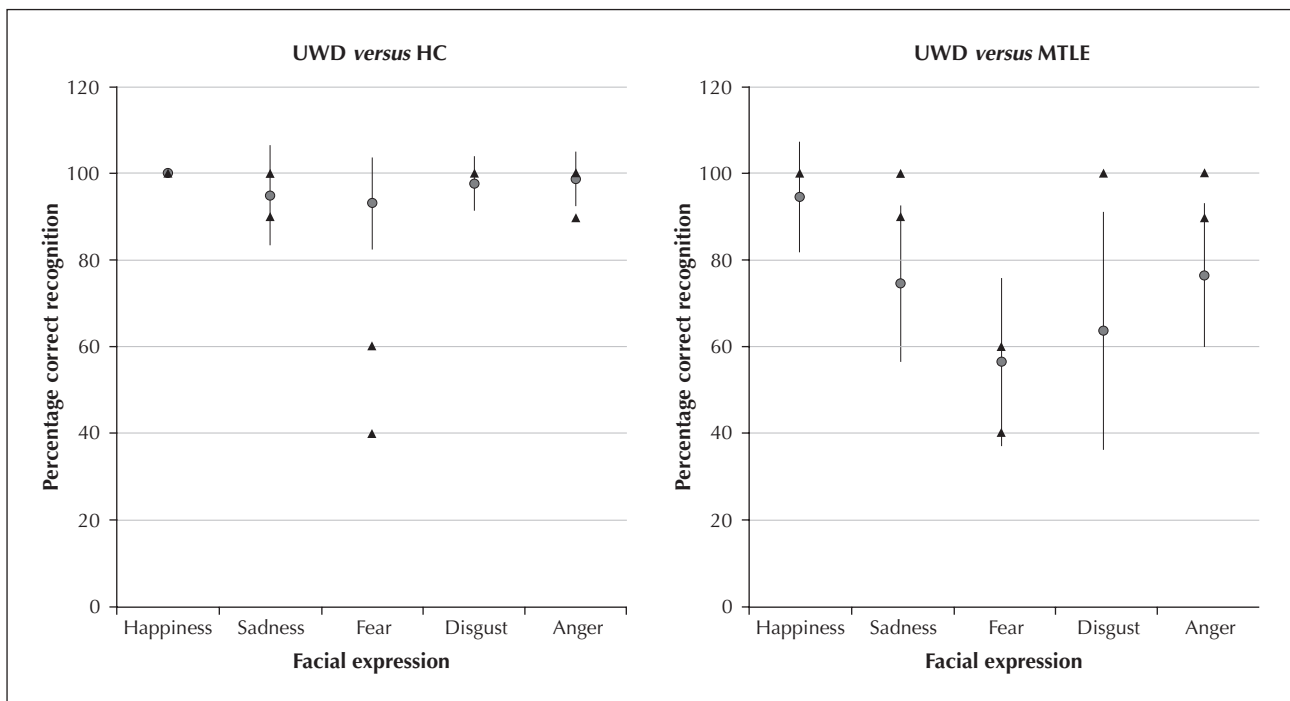
ceive or express ictal fear. However, the description of panic attacks in UWD patients with bilateral amygdala damage demonstrate that acute fear of non-epileptic origin can be expressed even in the absence of the amygdala (Feinstein *et al.*, 2013).

Regarding emotion recognition ability, our patient showed a selective impairment of recognition of fear from faces, while she correctly recognized other basic emotions, as previously reported in UWD (Adolphs *et al.*, 1994), supporting the notion that the bilateral absence of a functional amygdala selectively impairs the recognition of fear in others. This defect has been hypothesized to depend on the lack of spontaneous fixation on the eye region, essential for fear recognition, implying that bilateral amygdala damage impairs the processing of visual information from the perocular region.

**Table 1.** Recognition of emotions (percentage of correct responses) in healthy controls (HC), patients with bilateral-MTLE (BMTLE), and the Urbach-Wiethe Disease (UWD) patient.

	HC (n=12)		BMTLE (n=12)		UWD Patient	
	Mean	SD	Mean	SD	Test 1	Test 2
<b>Facial expression</b>						
Happiness	98.6	0	94.5	12.9	100	100
Sadness	9.2	11.6	74.5	18.1	100	90
Fear	81.4	10.6	56.4	19.4	60	40
Disgust	88.8	6.5	63.6	27.8	100	100
Anger	92.6	5.2	76.4	16.6	100	90
Total score	89.3		69.5		92	84
<b>Emotional prosody</b>						
Happiness	92.4	11.7	85.4	13.9	90	100
Sadness	90.2	10.6	66.8	14.8	90	90
Fear	94	11.5	52.2	15.5	80	100
Disgust	72.8	8.3	54.5	14.6	70	60
Anger	90	12.5	72.8	14.7	100	90
Total score	87.9		66.3		86	88

A non-parametric test was used (Mann-Whitney U test) for the comparison of emotion recognition between BMTLE and HC. The accuracy of BMTLE recognition was lower with respect to HC ( $p < 0.05$ ) for every basic emotion, except happiness.

**Figure 2.** Recognition of facial emotions by the UWD patient, Healthy Controls (HC), and patients with bilateral mesial temporal lobe epilepsy (BMTLE).

The left panel shows the performance of the UWD patient (triangles) compared with HC (grey dot). The right panel shows the performance of the UWD patient (triangles) compared with BMTLE (grey dot).

The UWD patient was tested twice. Bars indicate standard deviation.

Emotion recognition for voices (emotional prosody) in our patient was essentially the same as that of HC. To our knowledge, this is the first study of emotional prosody in UWD with documented temporal lobe seizures. In MTLE, studies on emotional prosody have provided conflicting results showing no impairment at the group level (although defects were detected in single-subject analysis) (Adolphs *et al.*, 2001), or, on the contrary, deficits in the recognition of both facial and vocal expression of emotions, with a strong correlation between performances across the two tasks (Bonora *et al.*, 2011). These latter data suggest that in MTLE, impairment of emotion recognition extends beyond facial expressions to emotional prosody, reinforcing the hypothesis that in MTLE, deficits in emotion recognition are not specific to facial expressions and do not depend on the sensory modality of stimulus presentation. In our study, in agreement with previous data from our group (Meletti *et al.*, 2003; Bonora *et al.*, 2011), patients with severe BMTLE and bilateral dysfunction of the amygdala failed to recognize multiple facial and vocal expressions of emotions, in contrast to the selec-

tive deficit of fear recognition without impairment of emotional prosody recognition observed in our UWD patient. We can speculate that since our UWD case and the BMTLE group had similar epilepsy duration (although in our patient the seizure disorder was less severe), epilepsy "*per se*" cannot account for the more comprehensive deficit observed in BMTLE patients. Indeed, the differences between UWD and BMTLE might depend on possibly progressive network dysfunctions and atrophic processes that in MTLE, in contrast to UWD, extend beyond the medial temporal lobe to cortical-sub-cortical regions engaged in processing different emotions, comprising the anterior insula (*i.e.* disgust), the orbito-frontal cortex (*i.e.* anger and sadness) and somato-sensory cortices. In conclusion, our report contributes to further defining the epilepsy features and emotion recognition performances in UWD, and suggests that different pathophysiological mechanisms underlie the defect in processing emotional stimuli in this disorder, as compared to other epileptic conditions with bilateral amygdalae involvement (*i.e.* BMTLE). □

## Supplementary material

### Formal cognitive assessment of the patient

IQ was normal (WAIS-R full scale=95). Short and long-term verbal memory were at the lower end of the normal range, whereas visuo-spatial short-term memory abilities were defective (see *table 2*).

### Characteristics of the control groups

Healthy control (HC) group was composed of 12 women matched for education and age (mean age: 35.6 years). BMTLE control group was composed of 12 female patients with a mean age at testing of 35 years (SD: 8 years), 11 years of education (SD: 3 years), and a mean duration of epilepsy of 26 years (our patient's epilepsy duration was 28 years). The mean full scale IQ (WAIS-R) was  $90 \pm 8$  (verbal: 89; performance: 92). High-field MRI (3T) documented hippocampal sclerosis with bilateral amygdala signal hyperintensity in nine cases, bilateral temporo-medial gliotic lesions after viral encephalitis in two, cortical dysplasia in one.

### Emotion recognition tests

#### *Task 1. Recognition of basic facial emotions*

We used a previously published protocol used by our group for the evaluation of facial expressions (Meletti *et al.*, 2003; Meletti *et al.*, 2009). Pictures of facial affect, taken from the Ekman & Friesen series, were used to prepare a task requiring subjects to match a facial expression with the appropriate verbal label, choosing among the following five basic emotions: happiness, sadness, fear, disgust, and anger. Five pictures (facial stimuli) were used for each emotion giving a total of 25 trials. Normative data (for the Pictures of Facial Affect series) report the following mean percentages of correct recognition for the selected items: happiness=99.2%; sadness=95.6%; fear=88.4%; disgust=95.6%; anger=94.4%. Pictures (10 × 13 cm) were presented, one by one, on a sheet of paper. The verbal labels for the five facial expressions were printed under each picture and the subjects were asked to select the word that best described the emotion shown in each photograph.

#### *Task 2. Recognition of emotional prosody*

A prosodic affect-naming task taken from a previously published protocol conducted at our department (Ariatti *et al.*, 2008; Bonora *et al.*, 2011) was used in the current study. All subjects had normal hearing thresholds as determined by standard audiometric testing.

We carefully designed our stimuli so that they only varied with respect to a single factor of interest: emotional prosody. We used brief Italian sentences (of approximately three seconds) with a neutral meaning (*i.e.* Marta is combing the cat), spoken by a male or female performer instructed to produce a specific emotional tone of voice. Neutral sentences were spoken for each of the five "basic" emotions: happiness, sadness, fear, disgust, and anger. After digitization, stimuli were presented to the subjects *via* a PC. The task required the subject to select the emotion conveyed by the intonation of the sentence among five alternatives. The five alternatives were presented on the computer screen. The test consists of 25 trials, five for each emotion (happiness, fear, disgust, anger, and sadness).

In both emotion recognition tasks, participants were instructed to consider carefully all five alternatives before responding. There was no time limit for each stimulus and the patients were given no feedback on their performances. For the prosody recognition task, the stimulus could be repeated without any limits until the subjects had chosen the emotional label. All the subjects completed these tests in a single session that typically lasted from 20 to 40 minutes.

**Table 2.** Patient's neuropsychological evaluation.

Neuropsychological test	Range	Cut-off	Row Score	Corrected Score	Equivalent Score
<b>Executive function and Attention</b>					
Attentional matrices	0-60	>31	41	32.75	1
Stroop test: errors		<4.24	3	3.25	1
Stroop test: time		<36.92	24	32.75	1
<b>Abstract-logical reasoning</b>					
Raven CPM '47	0-36	>18.96	25	21.4	2
<b>Spatial Cognition</b>					
Complex Rey figure: copy	0-36	<28.88	36	36	4
<b>Visuo-spatial memory</b>					
Corsi block-tapping test span	0-9	>3.5	4	3.75	1
supra-span	0-31	>5.5	17.25	9.5	1
Immediate visual recall	0-22	13.8	11	9.5	0*
Complex Rey figure: recall	0-36	<9.47	16	13	3
<b>Verbal memory</b>					
Digit span	0-9	>3.75	5	4.5	2
Ray Auditory Verbal Learning Test	0-75	>28.53	43	35.5	2
Immediate recall					
Delayed recall	0-15	>4.69	8	5.6	1
<b>Language/frontal functions</b>					
Phonemic fluencies		>17.35	32	26.1	3
Semantic fluencies		>25	31	26	1
Token test	0-36	>26.5	35	32.5	3

(Age: 36 yrs; Years of education: 13; Right-handed)  
Standardized test on Italian population.

\*The performance is expressed in Row Scores, Corrected Scores for age and education, and Equivalent Score. The EQ expresses the performance in a scale from 0 to 4 in which 0 corresponds to a pathological performance (performance below the tolerance limits for 95% of the control population) with 95% confidence; 4 corresponds to a superior performance respect with the median of the sample (4 > 50th percentile); the intermediate scores are determined by dividing equally the remaining part of the distribution.

Table 3. Literature review - Features of epilepsy in UWD.

Reference	Subjects with epilepsy	Age/sex	Age epilepsy onset	Aura description	Seizure description	EEG	Treatment response	Amygdala calcification	Other neuropsychiatric features
Eberhartinger and Niebauer, 1959	2	n.a.	n.a.	n.a.	n.a.	n.a.	n.a.	yes	n.a.
Cowan <i>et al.</i> , 1961	1	42/F	30	n.r.	akinetic, blackouts	normal	PHT (partial)	yes	migraine
Heyl <i>et al.</i> , 1963	8/20	5-50/n.r.	n.r.	olfactory (3/8); déjà vu (5/8)	psychoomotor; grand mal type	n.r.	n.r.	yes	confusional states; hallucinations
Newton <i>et al.</i> , 1971	2	36/F	3	olfactory	dreamlike state; psychoomotor	background slowing	PHT + PRM	yes	rage attacks; anxiety; depression; memory impairment;
Juberg <i>et al.</i> , 1975	1	48/M	5	olfactory	arrest; automatism with lip smacking	background slowing	PHT + PRM	yes	emotional lability; paranoid delusion; memory deficit
Navarro <i>et al.</i> , 1999	1	27/M	n.r.	n.r.	convulsive	n.r.	n.r.	n.r.	social isolation
Ito <i>et al.</i> , 2000	1	32/F	n.r.	n.r.	convulsive	n.r.	n.r.	yes	n.r.
Hamada <i>et al.</i> , 2003	3/10*	16/M	10	déjà vu	arrest; dreamlike	temporal lobe spikes	CBZ (partial)	yes	n.r.
Van Houghenhouck-Tulleken <i>et al.</i> ; 2004	5/24	38/M	n.r.	n.r.	temporal lobe seizures	n.r.	n.r.	n.r.	n.r.
Desmet <i>et al.</i> , 2005	1	30/F	n.r.	n.r.	loss of consciousness	n.r.	n.r.	n.r.	n.r.
Kini <i>et al.</i> , 2006	1	n.r.	n.r.	n.r.	2/5 temporal lobe epilepsy	n.r.	n.r.	n.r.	n.r.
Appenzeller <i>et al.</i> , 2006	1	6/M	3	n.r.	convulsive	n.r.	CBZ	n.r.	n.r.
	1	12/M	n.r.	n.r.	n.r.	n.r.	n.r.	n.r.	n.r.
	1	44/F	15	n.r.	temporal lobe seizures	n.r.	n.r.	yes	n.r.



Table 3. (Continued)

Reference	Subjects with epilepsy	Age/sex	Age epilepsy onset	Aura description	Seizure description	EEG	Treatment response	Amygdala calcification	Other neuropsychiatric features
Claeys <i>et al.</i> , 2007	1	39/F	5	n.r.	arrest and loss of consciousness	temporal lobe spikes	TPM (previous multiple AED failures)	yes	migraine; depression; suicide attempts
Baykal <i>et al.</i> , 2007	2/14	35/F	n.r.	n.r.	temporal lobe seizures	n.r.	n.r.	yes	n.r.
		24/M	n.r.	n.r.	temporal lobe seizures	n.r.	n.r.	yes	n.r.
Thornton <i>et al.</i> , 2008	8/27	n.r.	n.r.	n.r.	temporal lobe seizures; generic seizures	n.r.	n.r.	yes	depression; anxiety; phobia; emotion recognition deficits
Omrani <i>et al.</i> , 2012	1	14/F	5	n.r.	arrest, loss of contact, lip smacking	n.r.	drug-resistant epilepsy; CBZ + LEV	yes	n.r.
Becker <i>et al.</i> , 2012	1/2 twins	36/F	12	n.r.	n.r.	n.r.	n.r.	yes	n.r.
Messina <i>et al.</i> , 2012	1	39/F	n.r.	n.r.	complex partial	n.r.	n.r.	yes	migraine; ICH

n.r.: not reported; n.a.: not available; CBZ: carbamazepine; TPM: topiramate; PHT: phenytoin; LEV: levetiracetam; ICH: intracranial cerebral haemorrhage.  
\*One of the three cases was previously reported by Ito *et al.*, 2000.

**Disclosures.**

The authors do not have any conflicts of interests to disclose.

**References**

- Adolphs R, Tranel D, Damasio H, Damasio AR. Impaired recognition of emotion in facial expressions following bilateral damage to the human amygdala. *Nature* 1994;372: 669-72.
- Adolphs R, Tranel D, Damasio H. Emotion recognition from faces and prosody following temporal lobectomy. *Neuropsychology* 2001; 15: 396-404.
- Appenzeller S, Chaloult E, Velho P, de Souza EM, et al. Amygdalae calcifications associated with disease duration in lipid proteinosis. *J Neuroimaging* 2006; 16: 154-6.
- Ariatti A, Benuzzi F, Nichelli P. Recognition of emotions from visual and prosodic cues in Parkinson's disease. *Neurol Sci* 2008; 29: 219-27.
- Baykal C, Topkarci Z, Yazganoglu KD, Azizielri G, et al. Lipoid proteinosis: a case series from Istanbul. *Int J Dermatol* 2007; 46: 1011-6.
- Becker B, Mihov Y, Scheele D, et al. Fear processing and social networking in the absence of a functional amygdala. *Biol Psychiatry* 2012; 72: 70-7.
- Bonora A, Benuzzi F, Monti G, et al. Recognition of emotions from faces and voices in medial temporal lobe epilepsy. *Epilepsy Behav* 2011; 20: 648-54.
- Claeys KG, Claes LR, Van Goethem JW, et al. Epilepsy and migraine in a patient with Urbach-Wiethe disease. *Seizure* 2007; 16: 465-8.
- Cowan MA, Alexander S, Vickers HR, Cowdell RH. Case of lipoid proteinosis. *Br Med J* 1961; 2: 557-60.
- Desmet S, Devos SA, Chan I, et al. Clinical and molecular abnormalities in lipoid proteinosis. *Eur J Dermatol* 2005; 15: 344-6.
- Eberhartinger C, Niebauer G. Contribution to the recognition of Urbach-Wiethe lipoid proteinosis (Hyalinosis cutis et mucosae). *Hautarzt* 1959; 10: 54-65.
- Feinstein JS, Buzza C, Hurlmann R, et al. Fear and panic in humans with bilateral amygdala damage. *Nat Neurosci* 2013; 16: 270-2.
- Friedman L, Mathews RD, Swanepoel PD. Radiographic and computed tomographic findings in lipoid proteinosis. A case report. *S Afr Med J* 1984; 65: 734-5.
- Hamada T, Wessagowit V, South AP, et al. Extracellular matrix protein 1 gene (ECM1) mutations in lipoid proteinosis and genotype-phenotype correlation. *J Invest Derm* 2003; 120: 345-50.
- Heyl TL. Lipoid proteinosis: the clinical picture. *Brit J Derm* 1963; 75: 465-72.
- Hurlmann R, Wagner M, Hawellek B, et al. Amygdala control of emotion-induced forgetting and remembering: evidence from Urbach-Wiethe disease. *Neuropsychologia* 2007; 45: 877-84.
- Ito D, Nagasaka T, Tanaka K, et al. Hyalinosis cutis et mucosae: a case report. *J Neurol* 2000; 247: 58-60.
- Juberg RC, Winder PR, Turk LL. A case of hyalinosis cutis et mucosae (lipoid proteinosis of Urbach and Wiethe) with common ancestor in four remote generations. *J Med Genet* 1975; 12: 110-2.
- Kini S, Jain A, Shet TM, et al. Lipoid proteinosis in a 12-year-old child: a report from west India. *Dermatol Online J* 2006; 12: 10.
- Lupo I, Cefalu AB, Bongiorno MR, et al. A novel mutation of the extracellular matrix protein 1 gene (ECM1) in a patient with lipoid proteinosis (Urbach-Wiethe disease) from Sicily. *Brit J Dermatol* 2005; 153: 1019-22.
- Meletti S, Benuzzi F, Rubboli G, et al. Impaired facial emotion recognition in early-onset right mesial temporal lobe epilepsy. *Neurology* 2003; 60: 426-31.
- Meletti S, Benuzzi F, Cantalupo G, Rubboli G, Tassinari CA, Nichelli P. Facial emotion recognition impairment in chronic temporal lobe epilepsy. *Epilepsia* 2009; 50: 1547-59.
- Messina MJ, Nuzzaco G, Barbieri A, et al. Spontaneous intracerebral hemorrhage in Urbach-Wiethe disease. *Neurology* 2012; 79: 1740-1.
- Navarro C, Fachal C, Rodriguez C, Padro L, Dominguez C. Lipoid proteinosis. A biochemical and ultrastructural investigation of two new cases. *Br J Dermatol* 1999; 141: 326-31.
- Newton FH, Rosenberg RN, Lampert PW, O'Brien JS. Neurological involvement in Urbach-Wiethe's disease (lipoid proteinosis): a clinical, ultrastructural, and chemical study. *Neurology* 1971; 21: 1205-13.
- Omrani HG, Tajdini M, Ghelichnia B, et al. Should we think of Urbach-Wiethe disease in refractory epilepsy? Case report and review of the literature. *J Neurol Sci* 2012; 320: 149-52.
- Thornton HB, Nel D, Thornton D, et al. The neuropsychiatry and neuropsychology of lipoid proteinosis. *J Neuropsychiatry Clin Neurosci* 2008; 20: 86-92.
- Urbach C, Wiethe E. Lipoidosis cutis et mucosae. *Virchows Arch Pathol Anat Physiol Klin Med* 1929; 273: 285-319.
- Van Houghouck-Tulleken W, Chan I, Hamada T, et al. Clinical and molecular characterization of lipoid proteinosis in Namaqualand, South Africa. *Br J Dermatol* 2004; 151: 413-23.