

Effectiveness of Hesperidin on Methotrexate-Induced Testicular Toxicity in Rats ^[1]

Saadet BELHAN ¹  Mustafa ÖZKARACA ² Fatih Mehmet KANDEMİR ³
Fetih GÜLYÜZ ⁴ Serkan YILDIRIM ² Ali Doğan ÖMÜR ⁵ Zabit YENER ⁶

^[1] This study was supported by Yuzuncu Yil University Scientific Researches Project Foundation with project number: 2015-VF-B115

¹ Yuzuncu Yil University, Veterinary Faculty, Dept. of Reproduction and Artificial Insemination, TR-65080 Van - TURKEY

² Ataturk University, Veterinary Faculty, Department of Pathology, TR-25240 Erzurum - TURKEY

³ Ataturk University, Veterinary Faculty, Department of Biochemistry, TR-25240 Erzurum - TURKEY

⁴ Akdeniz University, Faculty of Agriculture, Department of Zootechnics, TR-07070 Antalya - TURKEY

⁵ Ataturk University, Veterinary Faculty, Dept. Reproduction and Artificial Insemination, TR-25240 Erzurum - TURKEY

⁶ Yuzuncu Yil University, Veterinary Faculty, Department of Pathology, TR-65080 Van - TURKEY

Article Code: KVFD-2017-17752 Received: 22.03.2017 Accepted: 05.07.2017 Published Online: 05.07.2017

Citation of This Article

Belhan S, Özkaraca M, Kandemir FM, Gülyüz F, Yıldırım S, Ömür AD, Yener Z: Effectiveness of hesperidin on methotrexate-induced testicular toxicity in rats. *Kafkas Univ Vet Fak Derg*, 2017 (in Press). DOI: 10.9775/kvfd.2017.17752

Abstract

The aim of this study was to investigate the effect of hesperidin on male reproductive system in rats to which methotrexate (MTX) was administered. In the study, 28 male Wistar albino rats at the age of 8 weeks and had 250-300 g of live weight were used. Four experimental groups were formed; Group 1 (n=7): The control group, only feed and water were given. Group 2 (n=7): MTX group, a single dose of 20 mg/kg of i.p. MTX was administered. Group 3 (n=7): Hesperidin group, 200 mg/kg of hesperidin was administered by gavage for 7 days. Group 4: MTX + hesperidin group (n=7): Following administration of a single dose of 20 mg/kg i.p. MTX, 200 mg/kg of Hesperidin was administered by oral gavage for 7 days. At the end of the experiment, rats were decapitated and biochemical, histopathological and spermatological parameters were examined. It was observed that in the MTX group, sperm motility and density, the enzymes CAT, GPx and SOD and GSH level decreased, TNF-alpha and IL-1 Beta, as well as MDA, levels were increased, regular structure of spermatogenic cells was impaired, and seminiferous tubules became necrotic and degenerative. It was determined that spermatological parameters improved and, necrotic and degenerative changes diminished by the administration of MTX+hesperidin. These outcomes indicated that hesperidin had a protective effect on destructive effects of MTX in rat testicles.

Keywords: Male rat, Hesperidin, Methotrexate, Sperm, Reproductive system

Ratlarda Metoraksat Kaynaklı Testiküler Toksikite Üzerine Hesperidin'in Etkisi

Özet

Bu çalışmanın amacı, metoraksat (MTX) uygulanan ratlarda hesperidin'in erkek üreme sistemi üzerindeki etkisini araştırmaktır. Çalışmada 8 haftalık yaşta, 250-300 g canlı ağırlığa sahip 28 erkek Wistar albino cinsi rat kullanıldı. Dört deney grubu oluşturuldu; Grup 1 (n=7): kontrol grubu, sadece yem ve su verildi. Grup 2 (n=7): MTX grubu, 20 mg/kg MTX i.p. tek doz uygulandı. Grup 3 (n=7): Hesperidin grubu, 200 mg/kg hesperidin 7 gün süre ile ağızdan sonda yardımıyla verildi. Grup 4 (n=7): MTX + hesperidin grubu, 20 mg/kg MTX i.p tek doz uygulamasını takiben 200 mg/kg hesperidin 7 gün süre ile ağızdan sonda yardımıyla verildi. Deney sonunda ratlar dekapite edilerek biyokimyasal, histopatolojik ve spermatolojik parametreler incelendi. MTX grubunda sperm motilitesi ve yoğunluğunun, CAT, GPx ve SOD enzimlerinin ve GSH düzeyinin düştüğü, TNF-alpha ve IL-1 Beta ile MDA düzeyinin arttığı, spermatojenik hücrelerin düzenli yapısının bozulduğu, seminifer tubullerin nekrotik ve dejeneratif bir hal aldığı gözlemlendi. MTX + hesperidin uygulaması ile spermatolojik parametrelerin düzeldiği, nekrotik ve dejeneratif değişikliklerin azaldığı tespit edildi. Bu sonuçlar hesperidin'in rat testislerinde MTX tarafından oluşan yıkıcı etkiler üzerinde koruyucu etkiye sahip olduğunu gösterdi.

Anahtar sözcükler: Erkek rat, Hesperidin, Metotretksat, Spermatozoon, Üreme sistemi



İletişim (Correspondence)



+90 432 2251128



saadetbelhan@yyu.edu.tr

INTRODUCTION

Chemotherapeutics are well-known to have an acute toxic effect which influences many organs. One of these effects is testicular toxicity presenting with azoospermia and infertility in males^[1]. Methotrexate causes defective oogenesis and spermatogenesis^[2].

Presence of omega 3 polyunsaturated fatty acids (PUFAs) within the membrane of testicle makes this organ more susceptible to oxidative stress^[3,4]. There are various antioxidant mechanisms in testicle which neutralize harmful effects of reactive oxygen species. However, MTX application causes an increase in formation of free radicals due to loss of effectiveness of antioxidant mechanisms, alterations in proinflammatory cytokine system and activation of phagocytic cells^[5,6]. Activation of immune cells via proinflammatory cytokines leads to overproduction of ROS, resulting in overproduction of ROS, which leads to an increase in LP levels, just like MDA. Overproduced ROS interacts with structure and ratio of PUFA2 and leads to loss of fluidity in biological membranes^[4,6].

It has been reported in previous studies that MTX leads to reductions in weights of reproductive organs, as well as leads to severe degradation of seminiferous epithelium, reduction of diameter of seminiferous tubules, reduction in size of spermatogenic cells and dilations in interstitial region^[7,8].

It has been reported that MTX-induced organ toxicity can be as a result of oxidative stress^[9]. Therefore, compounds with antioxidant properties may protect testicular tissue from harmful effects of the oxidative stress caused by MTX^[10].

The antioxidant known as Hesperidin is a bioflavonoid antioxidant used in traditional Chinese medicine^[11]. In many studies, it was demonstrated that Hesperidin reduced toxic effects^[12-14].

HP has radical clearance and anti-inflammatory effects^[15,16]. It has been reported that Hesperidin significantly reduces lipid peroxidation in testicular tissue, leads to positive effects on sperm parameters and biochemical parameters, as well as provides improvements in epididymal functions^[14,17].

Although protective properties of some antioxidants in rats exposed to MTX have been investigated, protective property of Hesperidin has not been investigated yet. Therefore, in this study, effect of Hesperidin on male reproductive system is investigated at biochemical, histopathological and spermatological levels.

MATERIAL and METHODS

Chemicals

MTX (Ebewe Pharma® Unterach-Austria) was bought from a pharmacy. Hesperidin (Sigma-Aldrich St. Louis, MO, USA)

was provided from a medical market. Rat TNF alpha ELISA kit and Rat IL-Beta ELISA Kit were procured from Cayma and other chemicals, however, were procured from Abcam and Merc.

Animals and Experimental Procedure

The study was approved by Yuzuncu Yil University Local Ethics Committee On Animal Experiments (Approval number: 2015/28). The study was performed on 28 healthy male Wistar albino rats (8 week-old, with 250-300 g of body weight) which were provided from Firat University Faculty of Medicine Experimental Research Center (Elazig, Turkey). Animals were adjusted to experimental conditions for a 1-week period before starting dosage. The animals were housed in standard laboratory conditions (24±3°C temperature, 40-60% humidity and 12 h light/12 h darkness). They were fed with commercial pelleted feed (Bayramoglu Food, Erzurum/Turkey) and fresh drinking water was provided ad libitum.

The experimental administrations were done in Experimental Animal Research Center of Yuzuncu Yil University. Rats were divided into 4 experimental groups, with 7 rats in each. Dosages of administered drugs were regulated in accordance with previous studies^[10,14,18].

Group 1: Healthy control group (n=7): Only feed and water were given.

Group 2: MTX group (n=7): A single dose of 20 mg/kg of MTX was administered I.P. Because, it was revealed in previous studies that this dose (20 mg/kg) causes tissue toxicity^[19]. MTX was dissolved in physiological saline.

Group 3: Hesperidin group (n=7): 200 mg/kg of hesperidin was administered by oral gavage for 7 days^[14]. Hesperidin was dissolved in physiological saline.

Group 4: MTX + hesperidin group (n=7): Following administration of a single dose of 20 mg/kg MTX I.P., 200 mg/kg of Hesperidin was administered by oral gavage for 7 days.

Twenty-four hours after the last administration, the rats were decapitated under mild anaesthesia with sevoflurane. One of the testicular tissues was taken for biochemical analyses and kept under -80°C, and cauda epididymis of the other testicle was taken for spermatological examinations and the related testicle was fixed in Bouin's solution^[20].

Collection of Samples and Evaluation of Spermatological Features

Testicles were removed. In order to obtain sperm from cauda epididymis, the method which was previously described by Sonmez et al.^[21] was used. Briefly, epididymis is minced within 1.0 mL of physiological saline (0.9% w/v NaCl) by using an anatomical scissor in a petri dish. In order to provide transition of all spermatozoa into the fluid, it was left for incubation for 15 min. The obtained fluid was used as a sperm sample.

Sperm density was determined by using a slight modification of the method described by Sonmez et al.^[21]. Sperm sample was poured into an eppendorf tube via an automated pipette with 10 µL of volume and 990 µL of eosine solution was added. Approximately 10 µL of diluted sperm suspension was transferred to counting chambers of a thoma slide (HHH Germany) and 5 min were awaited. They were counted at 200x magnification under phase contrast microscopy and calculated by using the formula used for calculation of sperm density.

Percentage of sperm motility was evaluated at 200x magnification by using a light microscope with a heating stage (ECLIPSE E 400 Nikon JAPAN), as it was stated by Sonmez et al.^[21]. Average of three consecutive evaluations was used as the final motility score.

In order to evaluate abnormal sperm cells, the method which was reported in the study conducted by Turk et al.^[22] was used. Briefly, one drop of sperm sample was mixed with the same amount of eosine-nigrosine staining (1.67% eosine, 10% nigrosine, and 0.1 M sodium citrate) and thin smear was prepared. 300 sperm cells were examined at 400x magnification under light microscope.

Biochemical Evaluations of Testicular Tissues

The testicular tissue which was triturated in porcelain mortar by using liquid nitrogen was diluted with 1.15% KCl and homogenized within ice with IKA-T-18 BASIC model ultra turrax. Firstly, obtained homogenate was centrifuged at 3500 rpm for 15 min and then the supernatant portion was separated for determination of protein, malondialdehyde, glutathione, superoxide dismutase and catalase.

The testicular tissue which was weighed according to dilution rate was diluted with 1.15% KCl and homogenized within ice by IKA T-18 BASIC ultra-turrax homogenisator. After the homogenate was centrifuged at 11.000 rpm for 20 min, the supernatant portion was separated for determination of glutathione peroxidase.

Determination of MDA was performed with thiobarbituric acid reaction method, which was reported by Placer et al.^[23]. Measurement of GSH level was performed in accordance with the method reported by Sedlak and Lindsay^[24]. SOD activity was performed with the method reported by Sun et al.^[25]. SOD activity is measured via absorbance at 560 nm demonstrated by farmasone within the formed coloured solution. GPx activity was measured with the method of Matkovic et al.^[26]. CAT activity in the testicular tissue was measured with method of Aebi^[27]. Testicular cytokine production was measured by using a commercial enzyme-linked immunosorbent assay (ELISA) kit in accordance with the instructions of the producer. Testis tumour necrosis factor-α (TNF-α) and Interleukin-1β (IL-1β) kits were provided from Sunred biological technology (Shangai, China). Protein amount was determined by using the method described by Lowry et al.^[28].

Histopathological Evaluations

Obtained testicular tissues were fixed in Bouin's solution for 24-48 h. Tissues taken into paraffin blocks were passed through routine alcohol-xylol series. Slices which were sectioned 5 µm in thickness were stained with hematoxylin-eosin and examined under light microscope. For histopathological evaluation, Johnsen's testicular biopsy score was used^[20].

Score	Definition
1	No cells
2	No germ cells, sertoli cells present
3	Only spermatogonia present
4	Few spermatocytes
5	Many spermatocytes
6	Few early spermatids
7	Many undifferentiated early spermatids
8	Few late spermatids
9	Many late spermatids
10	Complete spermatogenesis

Immunohistochemical Evaluations

Following deparaffinization, the slices were treated with 400 watts antigen retrieval solution (pH 6.0) in microwave oven for 15 minutes. To prevent endogenous peroxidase activity, it was awaited within 3% H₂O₂ for 10 minutes. Slices washed with PBS were incubated for 15 minutes under room temperature with 8-OhDG primary antibody (cat no. Sc-66036, dilution ratio 1/200, Santa Cruz Biotechnology USA) and anti-NFKB1 antibody (cat no. ab7971, dilution ratio 1/200, Abcam, USA). Slices washed with PBS were continued to be stained with expose mouse and rabbit specific HRP/DAB detection IHC kit. 3,3' diaminobenzidine (DAP) was used as a chromogen. Slices which were passed through alcohol xylol series following counterstaining with hematoxylin were examined under light microscope. Immunopositivity was evaluated as none (0), mild (1), moderate (2) and severe (3).

Statistical Analysis

All statistical data were evaluated by using SPSS program (SPSS for windows, version 20.0). Spermatological and biochemical data were evaluated with Post hoc Tukey-HSD test and One-way variance analysis (ANOVA) in order to determine the differences between the groups. For histopathological and immunohistochemical findings, non-parametric Kruskal-Wallis and Mann-Whitney-U tests were used. P<0.05 value was accepted to be significant.

RESULTS

Spermatological Parameters

Sperm density, motility and abnormal sperm rate are given in *Table 1*. MTX group exhibited a significant decrease in sperm density and motility and a significant increase in

abnormal sperm rate, compared to the control and other groups. In addition to this, it was determined that MTX with Hesperidin treatment reduced the increased abnormal sperm rate and increased the reduced sperm motility and sperm density, compared to the only MTX group (Table 1, $P < 0.05$).

Biochemical Results

Biochemical results of the testicular tissue are given in Table 2. It was determined that in the testicular tissue, MDA level increased in MTX group compared to the control group and MTX + hesperidin administration lowered this level to a near value in the control group ($P < 0.05$). It was also determined that GSH level reduced in MTX group and MTX + hesperidin administration increased this lowered level ($P < 0.05$).

It was determined that CAT, GPx and SOD activities were lower in the MTX-treated group compared to the control group, MTX + hesperidin administration led to an increase in enzyme activities and strengthened antioxidant defence system ($P < 0.05$).

When the testicular tissue was examined in terms of TNF-alpha and IL-1 Beta levels among cytokines, it was determined that the levels were significantly lower in the group for which hesperidin was administered alone, compared to the control group. With MTX administration, increase in TNF-alpha and IL-1 Beta levels occurred, and addition of hesperidin treatment to MTX treatment was observed to decrease TNF-alpha and IL-1 Beta levels ($P < 0.05$).

Histopathological Findings

Structure of seminiferous tubules was observed to be normal in the control and hesperidin groups (Fig. 1A-1B). It was recognized that in the group for which MTX was administered, regular structure of spermatogenic cells was impaired, and seminiferous tubules became necrotic and degenerative, with development of sporadic flaking (Fig. 1C). It was determined that in the group for which MTX was administered together with hesperidin, observed necrotic and degenerative changes were reduced compared to the group for which MTX was administered alone (Fig. 1D, Table 3, $P < 0.05$).

Table 1. Sperm motility, density and abnormal sperm rate in rats after administration of methotrexate and hesperidin. The different letters (a,b,c) in the same column indicate differences between the groups ($P < 0.05$)

Groups	Motility Rate (%)	Density ($\times 10^6$)	Abnormal Sperm Rate (%)		
			Head	Tail	Total
Control n=7	70.71 \pm 1.30 ^a	70.42 \pm 1.91 ^a	3.42 \pm 0.29 ^a	6.14 \pm 0.79 ^a	9.57 \pm 0.99 ^a
Hesperidin n=7	76.42 \pm 0.92 ^a	71.85 \pm 1.73 ^a	3.14 \pm 0.59 ^a	5.71 \pm 0.64 ^a	8.85 \pm 0.98 ^a
Methotrexate n=7	36.42 \pm 1.42 ^b	33.85 \pm 1.56 ^b	13.57 \pm 0.78 ^b	18.28 \pm 1.86 ^b	32.28 \pm 1.28 ^b
Methotrexate+ hesperidin n=7	45.71 \pm 2.02 ^c	44.14 \pm 0.98 ^c	9.42 \pm 0.71 ^c	10.71 \pm 0.80 ^c	20.28 \pm 1.50 ^c
Significance	($P < 0.05$)	($P < 0.05$)	($P < 0.05$)	($P < 0.05$)	($P < 0.05$)

Table 2. MDA, GSH, GPx, SOD, CAT, TNF α and IL-1 Beta levels in testicular tissues of rats for which methotrexate and hesperidin were administered. The different letters (a,b,c,d) in the same column indicate differences between the groups ($P < 0.05$)

Groups	MDA (nmol/g tissue)	GSH (nmol/g tissue)	GPx (U/g protein)	SOD (U/g protein)	CAT (katal/g protein)	TNF α (ng/g tissue)	IL-1Beta (pg/g tissue)
Control (n=7)	73.47 \pm 1.28 ^c	4.47 \pm 0.03 ^b	8.57 \pm 0.16 ^b	18.96 \pm 0.35 ^b	6.02 \pm 0.07 ^b	3961 \pm 36.78 ^c	14078 \pm 58.84 ^c
Hesperidin (n=7)	68.14 \pm 0.64 ^d	4.94 \pm 0.04 ^a	9.57 \pm 0.14 ^a	21.54 \pm 0.32 ^a	6.81 \pm 0.09 ^a	3644 \pm 27.64 ^d	12892 \pm 74.29 ^d
Methotrexate (n=7)	103.42 \pm 2.83 ^a	3.59 \pm 0.04 ^d	6.63 \pm 0.17 ^d	14.50 \pm 0.22 ^d	4.22 \pm 0.08 ^d	5313 \pm 68.38 ^a	21153 \pm 292.78 ^a
Methotrexate+ hesperidin (n=7)	83.34 \pm 1.09 ^b	4.26 \pm 0.84 ^c	7.42 \pm 0.13 ^c	17.13 \pm 0.15 ^c	5.28 \pm 0.10 ^c	4081 \pm 40.84 ^b	17319 \pm 176.41 ^b
Significance	$P < 0.05$	$P < 0.05$	$P < 0.05$	$P < 0.05$	$P < 0.05$	$P < 0.05$	$P < 0.05$

Table 3. Histopathological changes in testicular tissues of rats for which methotrexate and hesperidin were administered. The different letters (a, b, c, d) in the same column indicate differences between the groups ($P < 0.05$)

Groups	Johnsen's Testicular Biopsy Score
Control	9.42 \pm 0.20 ^a
Hesperidin	9.57 \pm 0.20 ^b
Methotrexate	7.14 \pm 0.26 ^c
Methotrexate + hesperidin	5.42 \pm 0.29 ^d
Significance	($p < 0.05$)

Table 4. 8-OhDG and NFKB1 expressions levels in testicular tissues of rats for which methotrexate and hesperidin were administered. The different letters (a,b,c,d) in the same column indicate differences between the groups ($P < 0.05$)

Groups	8-OhDG	NFKB1
Control	0.28 \pm 0.18 ^a	0.57 \pm 0.20 ^a
Hesperidin	0.57 \pm 0.20 ^b	0.85 \pm 0.14 ^b
Methotrexate	2.85 \pm 0.40 ^c	2.42 \pm 0.20 ^c
Methotrexate + hesperidin	1.85 \pm 0.26 ^d	1.57 \pm 0.20 ^d
Significance	($P < 0.05$)	($P < 0.05$)

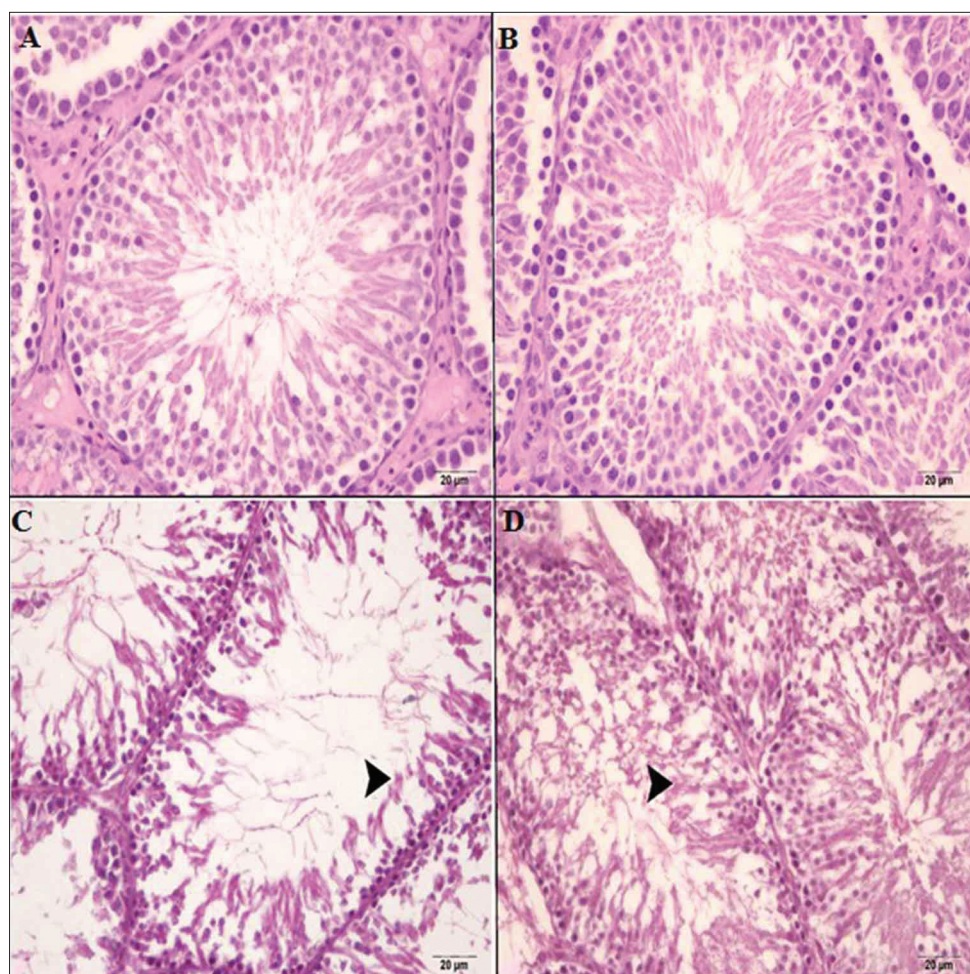


Fig 1. Structure of seminiferous tubules was observed to be normal in the control and hesperidin groups (A-B). Intense necrotic and degenerative alterations (*arrow head*) of seminiferous tubules are seen in the MTX alone group (C). Slightly necrotic and degenerative alterations (*arrow head*) are seen in the MTX + hesperidin group (D); H-E; (magnification 20 \times .)

Immunohistochemical Findings

8-OHdG expression was determined to be extremely low in control and hesperidin groups (Fig. 2A-2B). It was determined that in the group for which MTX was administered alone, 8-OHdG was expressed strongly in seminiferous tubules but 8-OHdG expression level decreased in the group for which MTX was administered together with hesperidin (Fig. 2C-2D, Table 4, $P < 0.05$). NFKB1 expression, however, was at extremely low level in control and hesperidin groups (Fig. 3A-3B). Whereas it was observed that NFKB1 was expressed strongly in spermatids in the group for which MTX was administered alone, expression level was observed to begin decreasing in the group for which MTX was administered together with hesperidin (Fig. 3C-3D, Table 4, $P < 0.05$)

DISCUSSION

Testicles are the most important target organs for oxidative stress due to their high content of polyunsaturated membrane lipids [29]. Increased oxidative stress in testicles damages to spermatological parameters [30].

In the current study, the decrease in sperm count and sperm motility and the increase in abnormal sperm rate

determined following MTX administration confirmed previous studies [7,18,31]. The increase in abnormal sperm rate and reduction in sperm density and motility are associated with the increased lipid peroxidation. This situation can be explained by that MTX damages cell membrane integrity by disturbing lipids and proteins within the sperm membrane. It was determined in previous studies that like MTX, Cisplatin causes a marked decrease in sperm density and motility [32-34].

Hesperidin administration in addition to MTX decreased effects of MTX on sperm parameters and increased sperm count and motility. Protective effects of hesperidin are probably may be referred to its obvious antioxidant potential which was observed in this study.

Our biochemical findings indicated that MTX increased MDA level which is among the most important oxidant parameters in the testicular tissue, compared to the control group. This finding is consistent with some reports indicating that MTX stimulates oxidative stress by increasing MDA levels [8,10,35]. Also, it revealed that MTX treatment significantly decreased endogenous antioxidant enzyme activities such as SOD, CAT and GPx and GSH level, which are commonly used for monitoring oxidant/antioxidant status. In the study, it was determined that Gpx, CAT and SOD enzyme

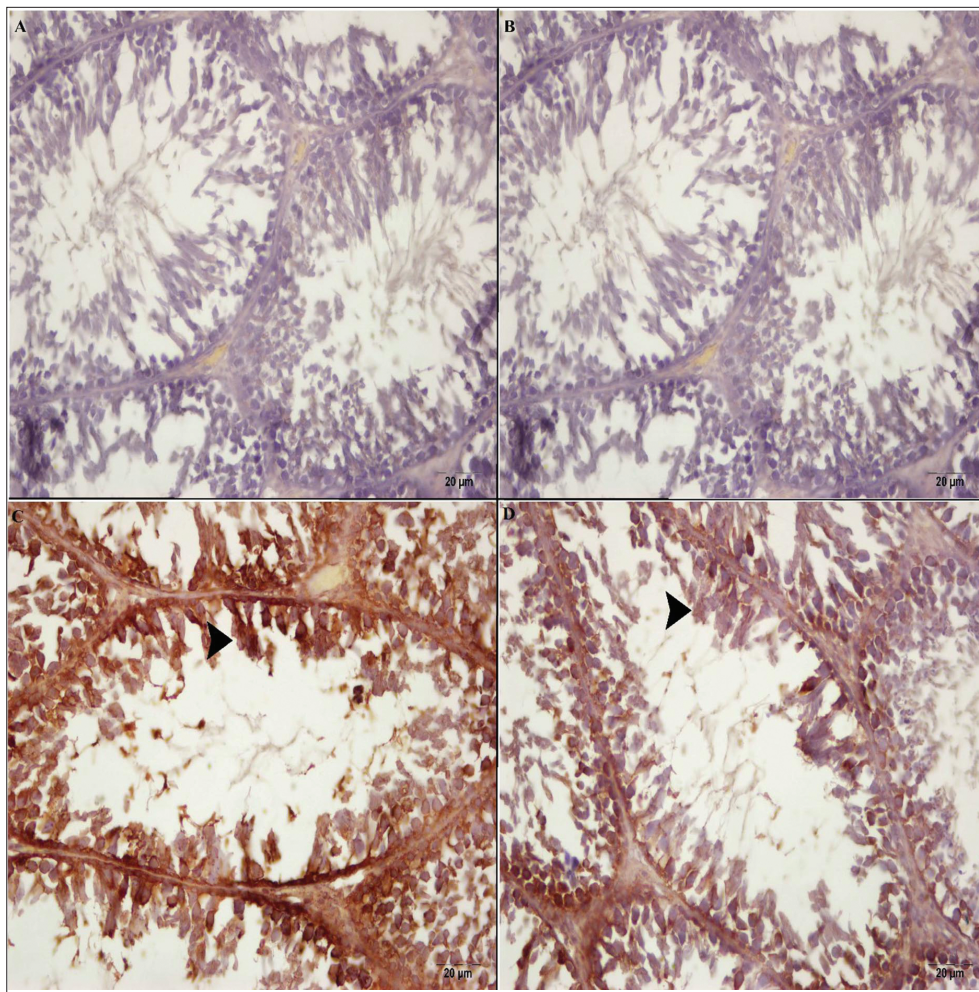


Fig 2. 8-OHdG expression was determined to be extremely low in control and hesperidin groups (A-B). In the MTX alone group, intensive 8-OHdG expression (*arrow head*) is detected (C). Slightly expression of 8-OHdG (*arrow head*) is seen in the MTX + hesperidin group (D); IHC; (Magnification 20 \times .)

activities, as well as GSH level, were significantly increased and lipid peroxidation induced by MTX was significantly reduced with hesperidin administration. These results are consistent with those of previous studies [14,17,36].

TNF- α exists in seminiferous tubules and is strongly up-regulated under both pathological and physiological conditions [37,38]. IL-1 Beta is produced by macrophages. This cytokine is known as an important mediator of various cellular functions, including reproduction, differentiation and apoptosis, and of the inflammatory response [39]. The increase in TNF- α and IL-1 Beta levels which was observed after MTX administration suggested that MTX led to an inflammatory reaction. Reduction of this increase in TNF- α and IL-1 Beta levels by administration of hesperidin in addition to MTX suggests that hesperidin has anti-inflammatory effects. It was reported in a previous study that MTX led to an increase in TNF- α level [40]. It is consistent with this study that Cisplatin, Doxorubicin and Sodium nitrite increase TNF- α and IL-1 Beta levels among pro-inflammatory cytokines in testicular tissue [40-42].

In histopathological evaluation, severe necrotic and degenerative changes were determined in MTX group. In

MTX + hesperidin group, however, necrotic and degenerative changes were determined to be milder. Therefore, possible protective effect of hesperidin was evaluated immunohistochemically with 8-OHdG in regard to DNA damage and with NfKB in regard to inflammatory reaction. 8-OHdG is a form of free radicals and a biomarker used in oxidative stress [43]. In various studies it was expressed that severity of DNA damage in testicular destruction due to oxidative stress was determined with 8-OHdG [44]. In the present study, whereas 8-OHdG was strongly expressed in MTX group, reduction in 8-OHdG expression in the group for which MTX was administered together with hesperidin suggested that DNA damage was diminished and, hence, hesperidin had a protective property. NfKB, however, is a molecule which is activated when oxidative stress is developed [45,46]. It was reported that level of NfKB increased with testicular intoxication [47,48]. Present study, NfKB was determined to be severe in MTX group and moderate in MTX + hesperidin group. This situation was expressed as that hesperidin reduced inflammatory reaction.

This study demonstrated that administration of a single dose of 20 mg/kg of MTX increased lipid peroxidation levels in testicles of Wistar albino rats and, thus, caused oxidative stress. Additionally, it also demonstrated that

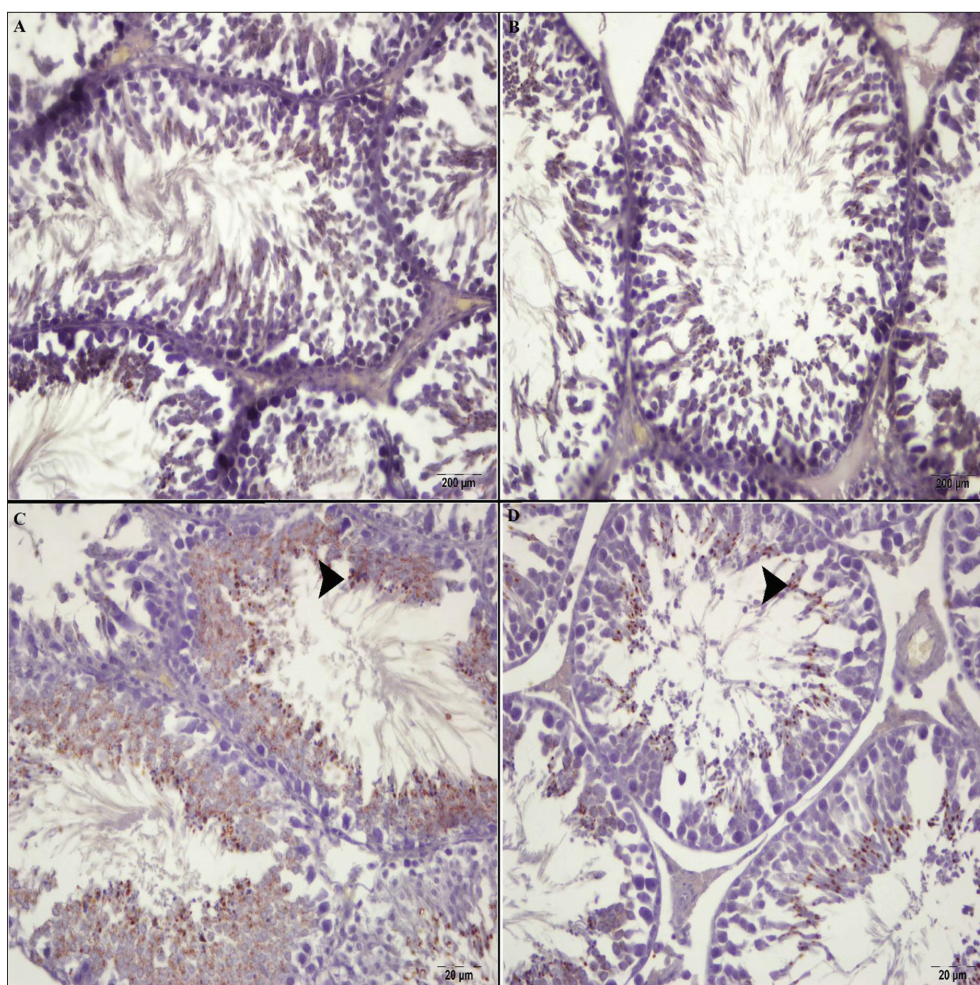


Fig 3. NFκB1 expression was at extremely low level in control and hesperidin groups (A-B). In the MTX alone group, intensive NFκB1 expression (arrow head) is detected (C). Slightly expression of NFκB1 (arrow head) is seen in the MTX + hesperidin group (D); IHC; (Magnification 20×.)

it had toxic effects including histopathological changes and spermatological damage. Treatment of MTX together with hesperidin was determined to significantly prevent toxicity of MTX on reproductive system. When results of all groups are taken into consideration, we suggest that hesperidin has a regenerative effect on testicular tissue and sperm parameters.

REFERENCES

1. Kim J, Kim K, Chung M: Testicular cytotoxicity of DA-125, a new anthracycline anticancer agent, in rats. *Reprod Toxicol*, 13, 391-397, 1999. DOI: 10.1016/S0890-6238(99)00028-3
2. Bayram M, Ozogul C, Dursun A, Ercan ZS, Isik I, Dilekoz E: Light and electron microscope examination of the effects of methotrexate on the endosalpinx. *Eur J Obstet Gynecol Reprod Biol*, 120, 96-103, 2005. DOI: 10.1016/j.ejogrb.2004.08.014
3. Naziroglu M: Enhanced testicular antioxidant capacity in streptozotocin-induced diabetic rats: Protective role of vitamins C and E and selenium. *Biol Trace Elem Res*, 94, 61-72, 2003. DOI: 10.1385/BTER:94:1:61
4. Sikka SC: Oxidative stress and role of antioxidants in normal and abnormal sperm function. *Front Biosci*, 1, 78-86, 1996.
5. Uzar E, Sahin O, Koyuncuoglu HR, Uz E, Bas O, Kilbas S, Yilmaz H, Yurekli VA, Kucuker H, Songur A: The activity of adenosine deaminase and the level of nitric oxide in spinal cord of methotrexate administered rats: Protective effect of caffeic acid phenethyl ester. *Toxicology*, 218, 125-133, 2006. DOI: 10.1016/j.tox.2005.10.014
6. Jahovic N, Sener G, Cevik H, Ersoy Y, Arbak S, Yeğen BC: Amelioration of methotrexate-induced enteritis by melatonin in rats. *Cell Biochem Funct*, 22, 169-178, 2004. DOI: 10.1002/cbf.1071
7. Nouri HS, Azarmi Y, Movahedin M: Effect of growth hormone on testicular dysfunction induced by methotrexate in rats. *Andrologia*, 41, 105-110, 2009. DOI: 10.1111/j.1439-0272.2008.00897.x
8. Gökce A, Oktar S, Koc A, Yonden Z: Protective effects of thymoquinone against methotrexate-induced testicular injury. *Hum Exp Toxicol*, 30, 897-903, 2011. DOI: 10.1177/0960327110382564
9. Şener G, Demiralp EE, Çetiner M, Ercan F, Yeğen BÇ: B-glucan ameliorates methotrexate-induced oxidative organ injury via its antioxidant and immunomodulatory effects. *Eur J Pharmacol*, 542, 170-178, 2006. DOI: 10.1016/j.ejphar.2006.02.056
10. Vardi N, Parlakpınar H, Ates B, Cetin A, Otlu A: Antiapoptotic and antioxidant effects of B-carotene against methotrexate-induced testicular injury. *Fertil Steril*, 92, 2028-2033, 2009. DOI: 10.1016/j.fertnstert.2008.09.015
11. Gil-Izquierdo A, Gil MI, Ferreres F, Tomas-Barberan FA: *In vitro* availability of flavonoids and other phenolics in orange juice. *J Agric Food Chem*, 49, 1035-1041, 2001. DOI: 10.1021/jf0000528
12. Yousef MI, Omar SA, El-Guendi MI, Abdelmegid LA: Potential protective effects of quercetin and curcumin on paracetamol-induced histological changes, oxidative stress, impaired liver and kidney functions and haematotoxicity in rat. *Food Chem Toxicol*, 48, 3246-3261, 2010. DOI: 10.1016/j.fct.2010.08.034
13. Dimpfel W: Different anticonvulsive effects of hesperidin and its aglycone hesperetin on electrical activity in the rat hippocampus *in-vitro*. *J Pharm Pharmacol*, 58, 375-379, 2006. DOI: 10.1211/jpp.58.3.0012
14. Arafa HMM, Aly HAA, Abd-Allah MF, El-Refaey HM: Hesperidin attenuates benzo[a]pyrene-induced testicular toxicity in rats via

regulation of oxidant/antioxidant balance. *Toxicol Ind Health*, 25, 417-427, 2009. DOI: 10.1177/0748233709106624

15. Meiyanto E, Hermawan A, Anindyajati A: Natural products for cancer-targeted therapy: Citrus flavonoids as potent chemopreventive agents. *Asian Pac J Cancer Prev*, 13, 427-436, 2012. DOI: 10.1155/2012/516981

16. Tanaka T, Tanaka T, Tanaka M, Kuno T: Cancer chemoprevention by citrus pulp and juices containing high amounts of β -cryptoxanthin and hesperidin. *J Biomed Biotechnol*, 2012 (2012): Article ID: 516981, 2012. DOI: 10.1155/2012/516981

17. Kaya K, Ciftci O, Cetin A, Dogan H, Basak N: Hesperidin protects testicular and spermatological damages induced by cisplatin in rats. *Andrologia*, 47, 793-800, 2015. DOI: 10.1111/and.12332

18. Padmanabhan S, Tripathi DN, Vikram A, Ramarao P, Jena GB: Methotrexate-induced cytotoxicity and genotoxicity in germ cells of mice: Intervention of folic and folinic acid. *Mutat Res*, 673, 43-52, 2009. DOI: 10.1016/j.mrgentox.2008.11.011

19. Uzar E, Koyuncuoglu HR, Uz E, Yilmaz HR, Kutluhan S, Kilbas S, Gultekin F: The activities of antioxidant enzymes and the level of malondialdehyde in cerebellum of rats subjected to methotrexate: Protective effect of caffeic acid phenethyl ester. *Mol Cell Biochem*, 291, 63-68, 2006. DOI: 10.1007/s11010-006-9196-5

20. Johnsen SG: Testicular biopsy score count - A method for registration of spermatogenesis in human testicles. Normal values and results of 335 hypogonadal males. *Hormones*, 1, 2-25, 1970. DOI: 10.1159/000178170

21. Sonmez M, Turk G, Yuca A: The effect of ascorbic acid supplementation on sperm quality, lipid peroxidation and testosterone levels of male Wistar rats. *Theriogenology*, 63, 2063-2072, 2005. DOI: 10.1016/j.theriogenology.2004.10.003

22. Turk G, Atessahin A, Sonmez M, Ceribasi AO, Yuca A: Improvement of cisplatin-induced injuries to sperm quality, the oxidant-antioxidant system, and the histologic structure of the rat testis by ellagic acid. *Fertil Steril*, 89, 1474-1481, 2008. DOI: 10.1016/j.fertnstert.2007.04.059

23. Placer ZA, Cushman LL, Johnson BC: Estimation of product of lipid peroxidation (malonyl dialdehyde) in biochemical systems. *Anal Biochem*, 16, 359-364, 1966. DOI: 10.1016/0003-2697(66)90167-9

24. Sedlak J, Lindsay RH: Estimation of total, protein-bound, and nonprotein sulfhydryl groups in tissue with Ellman's reagent. *Anal Biochem*, 25, 192-205, 1968. DOI: 10.1016/0003-2697(68)90092-4

25. Sun Y, Oberley LW, Li Y: A simple method for clinical assay of superoxide dismutase. *Clin Chem*, 34, 497-500, 1988.

26. Matkovics B, Szabo L, Varga IS: Determination of enzyme activities in lipid peroxidation and glutathione pathways. *Lab Diagn*, 15, 248-249, 1988.

27. Aebi H: Catalase. In, Bergmeyer HU (Ed): *Methods in Enzymatic Analysis*. 276-286, Academic Press, New York, 1983.

28. Lowry OH, Rosenbrough NJ, Farr AL, Randall RJ: Protein measurements with the folin phenol reagent. *J Biol Chem*, 193, 265-275, 1951.

29. Drasga RE, Einhorn LH, Williams SD, Patel DN, Stevens EE: Fertility after chemotherapy for testicular cancer. *J Clin Oncol*, 1, 179-183, 1983. DOI: 10.1200/JCO.1983.1.3.179

30. Chandra AK, Chatterjee A, Ghosh R, Sarkar M: Vitamin E-supplementation protect chromium (VI)-induced spermatogenic and steroidogenic disorders in testicular tissues of rats. *Food Chem Toxicol*, 48, 972-979, 2010. DOI: 10.1016/j.fct.2010.01.008

31. Padmanabhan S, Tripathi DN, Vikram A, Ramarao P, Jena GB: Cytotoxic and genotoxic effects of methotrexate in germ cells of male Swiss mice. *Mutat Res*, 655(1-2), 59-67, 2008. DOI: 10.1016/j.mrgentox.2008.07.003

32. Aksu EH, Akman O, Özkaraca M, Ömür AD, Uçar Ö: Effect of maclura pomifera extract on cisplatin-induced damages in reproductive system of male rats. *Kafkas Univ Vet Fak Derg*, 21, 397-403, 2015. DOI: 10.9775/kvfd.2014.12662

33. Ateşşahin A, Karahan İ, Türk G, Gür S, Yılmaz S, Çeribaşı AO: Protective role of lycopene on cisplatin-induced changes in sperm characteristics, testicular damage and oxidative stress in rats. *Reprod Toxicol*, 21, 42-47, 2006. DOI: 10.1016/j.reprotox.2005.05.003

34. Salem EA, Salem NA, Maarouf AM, Serefoglu EC, Hellstrom WJG: Selenium and lycopene attenuate cisplatin-induced testicular toxicity associated with oxidative stress in Wistar rats. *Urology*, 79, 1184.e1-1184.e6, 2012. DOI: 10.1016/j.urology.2011.12.006

35. Armagan A, Uzar E, Uz E, Yılmaz HR, Kutluhan S: Caffeic acid phenethyl ester modulates methotrexate-induced oxidative stress in testicles of rat. *Hum Exp Toxicol*, 27, 547-552, 2008. DOI: 10.1177/0960327108092293

36. Shagirtha K, Pari L: Hesperetin, a citrus flavonone, protects potentially cadmium induced oxidative testicular dysfunction in rats. *Ecotoxicol Environ Saf*, 74, 2105-2111, 2011. DOI: 10.1016/j.ecoenv.2011.06.002

37. Amin A, Abraham C, Hamza A, Abdalla ZA, Al-Shamsi SB, Harethi SS, Daoud S: A standardized extract of *Ginkgo biloba* neutralizes cisplatin-mediated reproductive toxicity in rats. *J Biomed Biotechnol*, 2012, 362049, 2012. DOI: 10.1155/2012/362049

38. Riccioli A, Starace D, D'Alessio A, Starace G, Padula F, De Cesaris P, Filippini A, Ziparo E: TNF-alpha and IFN-gamma regulate expression and function of the Fas system in the seminiferous epithelium. *J Immunol*, 165, 743-749, 2000. DOI: 10.4049/jimmunol.165.2.743

39. Zarpelon AC, Rodrigues FC, Lopes AH, Souza GR, Carvalho TT, Pinto LG, Xu D, Ferreira SH, Alves-Filho JC, McInnes IB: Spinal cord oligodendrocyte-derived alarmin IL-33 mediates neuropathic pain. *FASEB J*, 30, 54-65, 2016. DOI: 10.1096/fj.14-267146

40. Georgy GS, Maher OW: Ellagic acid and rosmarinic acid attenuate doxorubicin-induced testicular injury in rats. *J Biochem Mol Toxicol*, 2017 (In Press). DOI: 10.1002/jbt.21937

41. Sherif IO, Abdel-Aziz A, Sarhan OM: Cisplatin-induced testicular toxicity in rats: The protective effect of arjunolic acid. *J Biochem Mol Toxicol*, 28, 515-521, 2014. DOI: 10.1002/jbt.21593

42. Alyoussef A, Al-Gayyar MM: Thymoquinone ameliorates testicular tissue inflammation induced by chronic administration of oral sodium nitrite. *Andrologia*, 48, 501-508, 2016. DOI: 10.1111/and.12469

43. Valavanidis A, Vlachogianni T, Fiotakis C: 8-hydroxy-2'-deoxyguanosine (8-OHdG): A critical biomarker of oxidative stress and carcinogenesis. *J Environ Sci Health C Environ Carcinog Ecotoxicol Rev*, 27, 120-139, 2009. DOI: 10.1080/10590500902885684

44. Akman O, Şengül E, Özkanlar S, Can S, Koç A, Karadeniz A, Şimşek N: The melatonin attenuates alloxan induced post-diabetic testicular damage and oxidative effects in rats. *Kafkas Univ Vet Fak Derg*, 21, 719-728, 2015. DOI: 10.9775/kvfd.2015.13249

45. Tugcu V, Gedikbasi A, Mutlu B, Guner E, Uhri M, Andican G, Ozbek E, Tasci AI: Increased testicular 8-hydroxy-20-deoxyguanosine (8-OHdG) and inducible nitric oxide synthetase (iNOS) and nuclear factor κ B (NF- κ B) expressions in experimental rat varicocele. *Arch Ital Urol Androl*, 82, 148-153, 2010.

46. Shen YC, Yen JC, Liou KT: Ameliorative effects of caffeic acid phenethyl ester on an eccentric exercise-induced skeletal muscle injury by down-regulating NF- κ B mediated inflammation. *Pharmacology*, 91, 219-228, 2013. DOI: 10.1159/000348412

47. Amin A, Abraham C, Hamza AA, Abdalla ZA, Al-Shamsi SB, Harethi SS, Daoud S: A standardized extract of *Ginkgo biloba* neutralizes cisplatin-mediated reproductive toxicity in rats. *J Biomed Biotechnol*, 2012. DOI: 10.1155/2012/362049

48. Şimşek N, Koç A, Karadeniz A, Yıldırım ME, Çelik HT, Sarı E, Kara A: Ameliorative effect of selenium in cisplatin-induced testicular damage in rats. *Acta Histochemica*, 118, 263-270, 2016. DOI: 10.1016/j.acthis.2016.02.002