

Common extensor tendon thickness measurements at the radiocapitellar region in diagnosis of lateral elbow tendinopathy

Uğur Toprak, Bedriye Başkan, Evren Üstüner, Erol Öten, Levent Altın, Mehmet Alp Karademir, Hatice Bodur

PURPOSE

The aim of this study was to determine the value of measuring common extensor tendon (CET) thickness at the radiocapitellar and capitellar regions with qualitative ultrasonographic findings in the diagnosis of lateral elbow tendinopathy.

MATERIALS AND METHODS

The study included 164 lateral elbow tendinopathy patients (84 bilateral, 80 unilateral) matched by age, gender, and body mass index with 80 normal subjects. CET was examined using gray-scale and Doppler ultrasonography for tendinopathy, and tendon thickness was measured at two landmark locations: capitellar and radiocapitellar.

RESULTS

In tendinopathy, tendon thickness including the dominant capitellar region, increased in every measured location. In the capitellar region of the dominant elbow, the cut-off thickness was 5.15 mm, and in the radiocapitellar region, this value was 4.05 mm. For the non-dominant elbow, the cut-off thickness was 4.61 mm, whereas in the radiocapitellar region, this value was 3.51 mm. The greatest risk of tendinopathy was at the radiocapitellar region on the dominant side. The overall sensitivity and specificity of gray-scale findings were 54% and 88%, respectively, and the addition of Doppler readings did not alter these values. When capitellar measurements were added, the values increased to 79% and 80% for sensitivity and specificity, respectively. These values further increased to 93% and 91%, respectively, when radiocapitellar measurements were included.

CONCLUSION

A second tendon thickness measurement at the radiocapitellar region of CET in addition to the capitellar region is recommended on the grounds that combined qualitative and quantitative evaluation of CET increases the diagnostic performance of ultrasonography in lateral elbow tendinopathy.

Key words: • tendons • lateral humeral epicondylitis • ultrasonography • tendinosis

Lateral elbow tendinopathy (LET) is a clinical entity known as “tennis elbow,” which presents with pain due to the overuse of the common extensor tendon (CET). LET has mistakenly been referred to as lateral epicondylitis (1). LET diagnosis is often made by physical examination on a clinical basis, and imaging is rarely needed; however, in cases where conservative treatment methods fail due to the advanced disease stage or the presence of additional pathologies, imaging may be needed to assess the level of impairment, plan treatment strategies, or guide surgery (2).

Ultrasonography (US) is a valuable imaging method in LET. Gray-scale US and Doppler findings in LET have been previously described in detail (1–7). Some authors have argued for the diagnostic value of tendon thickness and area at the capitellar region over quantitative methods of diagnosis (5, 7). Yet, there are controversial topics related to the diagnosis of LET, such as the presence of asymptomatic patients despite US findings of tendinosis (hypoechoogenicity heterogeneity) (1, 4, 8). This decreases the specificity of qualitative US findings. Another controversial topic is the claim that the addition of Doppler findings increases the accuracy of diagnosis in chronic LET (4). Unfortunately, neovascularization, as identified by previous studies, is not a common finding in chronic tendinopathies (5) but is often reported in acute cases (9, 10). Finally, in a study that measured the capitellar tendon thickness/area, thickness/area and specificity increased, but sensitivity decreased (7). This suggests that a potential increase in false-negative cases is possible. Thus, in cases in which increased tendon thickness is not sufficient for assessment, the measurement of capitellar tendon thickness may not be of value. Therefore new criteria are needed to increase the accuracy of US. In light of the above-mentioned concerns, we aimed to study the overall combined accuracy and diagnostic value of qualitative US findings combined with capitellar and radiocapitellar tendon-thickness measurements in LET.

Material and methods

Written consent was obtained from all patients, and the study was approved by the Institutional Review Board. The group of patients with LET (the study group) was assessed by a doctor qualified in physical treatment and rehabilitation. Pathologies such as entrapment of the radiocapitellar joint, intra-articular body, and posterior rotator disability that were included in the differential diagnosis of LET were ruled out. Clinical diagnosis of LET was regarded as the reference standard (11). Tenderness on the lateral epicondyle, pain aggravation by extension, and radial deviation of the wrist were considered positive for LET. Those who had received steroid injections within three weeks prior to the study, and those with surgery or acute trauma were excluded from the study (12).

From the Clinics of Radiology (U.T. ✉ ugurtoprakk@gmail.com, L.A., M.A.K.) and Physical Therapy and Rehabilitation (B.B., E.Ö., H.B.), Ankara Numune Training and Research Hospital, Ankara, Turkey; the Department of Radiology (E.Ü.), Ankara University School of Medicine, Ankara, Turkey.

Received 2 January 2012; revision requested 30 January 2012; revision received 29 February 2012; accepted 13 March 2012.

Published online 13 April 2012
DOI 10.4261/1305-3825.DIR.5575-12.2

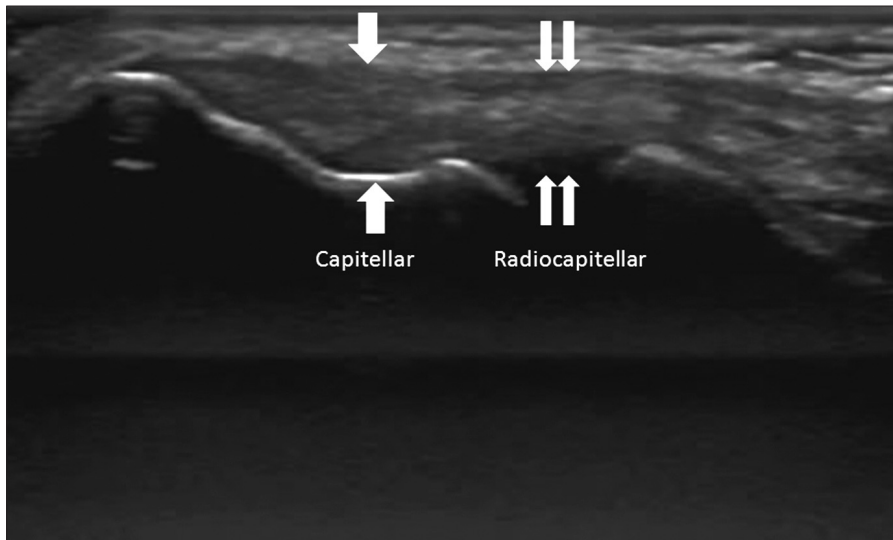


Figure 1. Longitudinal appearance of the common extensor tendon. Localizations of capitellar (single arrows) and radiocapitellar (double arrows) measurement regions are seen.

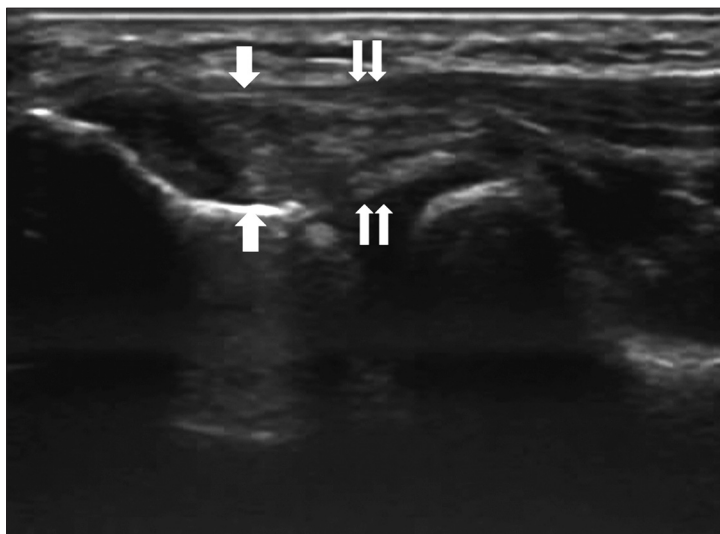


Figure 2. Measurement regions of an involved tendon (single arrows, capitellar; double arrows, radiocapitellar). Irregularity of the bony surface (arrows), swelling, and focal hypoechoic areas in the adjacent tendon are visible.

The control group was formed from volunteers who worked in the hospital and who had no elbow complaints, history of trauma, inflammatory arthritis, or abnormality related to the elbow.

The study included 164 patients (84 bilateral, 80 unilateral). A total of 104 non-dominant, and 144 dominant elbows were examined. Fifty females and 34 males were examined bilaterally, and 60 females and 20 males received unilateral examination. Elbows not examined were not included in the study.

The control group consisted of 80 people (50 females and 30 males), all of whom were examined bilaterally. Elbow dominance was indicated during the examination.

Ultrasonography

US examination (General Electric Medical Systems, Milwaukee, Wisconsin, USA) was performed on the same day as the physical examination with linear 12-MHz (10–14 MHz) probes in real time. A standard technique outlined by the European Society of Musculoskeletal Radiology US Subcommittee was followed for all elbow testing (13). Briefly, the lateral aspect of the elbow is examined with both elbows in extension, thumbs up, palms of the hands together or with the elbow in flexion. The CET is visualized along its long axis based on coronal planes, with the cranial edge of the probe placed on the lateral epicondyle. Studies were performed by a radiologist

with five years of experience in musculoskeletal US imaging.

Tendon hyper/hypoechoogenicity was considered as tendinosis, and loss of fibrillary continuity as a tear (if within the tendon, as intrasubstantial), and echogenicity with acoustic shadowing within the tendon was referred to as calcification. Enthesophytes within the region of the tendon insertion and any irregularities of the bony surface were regarded as bony degeneration, and the presence of fluid along the tendon was regarded as effusion. Power Doppler was utilized for Doppler examinations. New vessel formation thicker than 1 mm within or near the CET was accepted as neovascularization.

CET was imaged in the long axis and angled so that the entire tendon length was optimally visualized. Care was taken to avoid probe compression during all measurements so as to not interfere with measurements of tendon thickness. CET thickness measurements were made at two locations: the deepest point of the capitellum (called the capitellar part) and the mid-point of the radiocapitellar joint (referred to as the radiocapitellar part) (Figs. 1 and 2).

Statistical analysis

Data analysis was carried out using a commercially available software (Statistical Package for Social Sciences, SPSS Inc., Chicago, Illinois, USA). If the distribution was normal within the groups, a t test was used. If the distribution was not normal, the Mann-Whitney U test was used. Comparisons between groups on categorical variables were made using the chi-square test. The Spearman correlation test was used to determine whether the relationship between two continuous variables was statistically significant. To calculate the cut-off value discriminating normal from abnormal tendon thickness, the area under the receiver operating characteristic curve was used. Depending on the cut-off value differentiating the normal from the abnormal tendon thicknesses, the odds ratio (OR) was calculated for tendinosis. Analysis of variance was used to determine whether the differences at the two measurement locations differed from each other. The Wilcoxon signed-rank test was employed to study the differences in thicknesses between the dominant and non-dominant sides. To include clinical diagnosis as a

reference, for each US finding, the sensitivity, specificity, and accuracy were calculated. Sensitivity and specificity values were determined using the 2x2 table. The confidence interval (CI) was 95%, and $P < 0.05$ was considered statistically significant.

Results

The patients and the control group were matched based on age and gender. The mean age of the control group was 39 years (range, 17–71 years), and the mean age of the study group was 43 years (range, 19–66 years). Tendon thickness in the study group was increased bilaterally at both measurement points on each side. The increase was more pronounced on the dominant side and in the capitellar region (Table 1). In the control group, tendon thickness was greater on the dominant side in both locations ($P < 0.001$). In the dominant elbow, the tendon thickness increased with body mass

index (BMI) ($P < 0.001$), whereas thickness on the non-dominant side was not related to BMI ($P = 0.018$ for capitellar region; $P = 0.032$ for radiocapitellar region; $P > 0.25$ with Bonferroni correction), suggesting that the dominant side was affected by body shape, height, and BMI.

Cut-off values and ORs were calculated for each measurement location to differentiate tendinopathy from normal tendon. In the capitellar region of the dominant elbow, the cut-off thickness was 5.15 mm (OR=3.844, 95% CI=1.78–8.31); in the radiocapitellar region this value was 4.05 mm (OR=4.783, 95% CI=1.79–12.76). In the capitellar region of the non-dominant elbow, the cut-off thickness was 4.61 mm (OR=2.140, 95% CI=1.00–4.54), whereas in the radiocapitellar region, this value was 3.51 mm (OR=2.200, 95% CI=1.05–4.65). The greatest risk was in the radiocapitellar region of the dominant side.

Tears, effusions, and neovascularization were detected in 35%, 27%, and 19% of the involved elbows, respectively, with 100% specificity. Tendinosis, bony degeneration, and tendon calcification were detected in both involved and non-involved elbows, whereas tendinosis was detected in 12% of the non-involved and 54% of the involved elbows. Bony degeneration was detected in 9% of the non-involved and 55% of the involved elbows, and tendon calcification in 1% of the non-involved and 31% of involved elbows.

In Table 2, the qualitative and quantitative US findings and their diagnostic values are presented. Gray-scale findings alone had 54% sensitivity, 88% specificity, and 73% accuracy. Despite Doppler findings of 100% specificity, their sensitivity value was so low (19%) that their combination with gray-scale findings did not increase the overall diagnostic performance compared with gray-scale findings alone. There was only a negligible increase in accuracy values only; combined gray-scale and Doppler showed sensitivity of 54%, specificity of 88%, and accuracy of 72%.

Thickness measurements alone were not as accurate as the gray-scale US exam. Accuracy for capitellar region thickness was 67%, whereas accuracy for radiocapitellar thickness was 63%, compared to an accuracy of 70% with gray-scale findings. However, when thickness measurements were combined with gray-scale and Doppler findings, the overall sensitivity, specificity, and accuracy of the examination increased considerably. The addition of capitellar measurement alone increased the sensitivity, specificity, and accuracy to 79%, 80%, and 80%, respectively. When all measures were combined, the overall sensitivity, specificity, and accuracy values were 93%, 91%, and 92%, respectively.

Discussion

Although clinical findings are still considered the gold standard in LET, US has gained ground in the diagnosis and follow-up (1–7). However, because of high rates of false positives and negatives, US lags behind the clinical findings in the diagnosis of LET.

The first problem raised by US is the presence of hypoechogenicity and heterogeneity in the tendon, which imply tendinosis in a robust tendon (1, 4, 8).

Table 1. Tendon thicknesses (mean±standard deviation) in the dominant and non-dominant sides of non-involved and involved participants

	Capitellar tendon thickness (mm)		Radiocapitellar tendon thickness (mm)	
	Non-involved participants	Involved participants	Non-involved participants	Involved participants
Non-dominant side	4.23±0.66 (n=80)	4.58±0.77 (n=104)	3.24±0.44 (n=80)	3.51±0.53 (n=104)
<i>P</i>	0.014		0.009	
Dominant side	4.57±0.63 (n=80)	5.13±0.10 (n=144)	3.53±0.43 (n=80)	3.91±0.65 (n=144)
<i>P</i>	0.001		0.001	

Table 2. Diagnostic performances of qualitative and quantitative US findings alone and in combination

	Sensitivity	Specificity	Accuracy
Qualitative methods			
Gray-scale changes	54%	88%	72%
Doppler changes (neovascularization)	19%	100%	62%
Gray-scale+Doppler changes	54%	88%	72%
Quantitative methods			
Capitellar thickness measurement	52%	80%	67%
Radiocapitellar thickness measurement	38%	85%	63%
Overall methods			
All qualitative methods+capitellar measurement	79%	80%	80%
All qualitative+quantitative methods	93%	91%	92%

Thus, in the present study and in the study by du Toit et al., (4) the presence of findings suggestive of tendinosis were noted in 12% and 10.7% of non-involved tendons, respectively. Bone degeneration was noted in 9% of non-involved tendons, and calcification was seen in 1%. Consistent with other studies, tears, effusions, and neovascularization were detected in a small number of involved tendons (4, 7). Therefore, the performance of gray-scale US findings do not provide the overall pathology picture. The sensitivity and specificity of overall gray-scale US findings in this study and in the studies by du Toit et al. (4) and Lee et al. (7) were 54% and 88%, 81% and 63%, and 76.5% and 76.2%, respectively, suggesting that neither sensitivity nor specificity is entirely satisfactory in terms of the diagnosis and usefulness in planning intervention.

Gray-scale findings are important for practical decision making. Although LET is a clinical entity, US can confirm a diagnosis, reveal the extent and severity of the disease, identify associated abnormalities, and aid in preoperative planning. The detection of partial-complete tears or complications may change the management protocols and may encourage the physician to direct the patient from conservative treatment to interventional approaches, such as surgery and medication, as this type of injury will likely respond favorably to aggressive approaches (12).

One previously mentioned problem with this analysis is the suggestion that including Doppler findings can improve the accuracy rates of the examination (4). Neovascularity was not a common finding in LET, which is itself a chronic tendinopathy (5). In our study, neovascularization was detected in only 19% of LET cases. Further, neovascularization was reported to be a finding of acute, rather than chronic tendinopathy (9, 10). In the present study and in the study by du Toit et al., (4) the sensitivity and specificity of Doppler examinations were 19%–100% and 81%–98%, respectively (4). The addition of gray-scale Doppler findings in the study by du Toit et al. (4) increased the sensitivity to 97% and decreased the specificity to 63%. Interestingly, in the present study, the addition of Doppler findings to the gray-scale findings did not change the overall sensitivity or specificity. Therefore, the

inclusion of Doppler findings to the US exam may not be needed.

Some quantitative evaluation methods, such as the measurement of thickness and area, were attempted in an effort to enhance the diagnostic accuracy of US in LET because of the inadequacy of qualitative US criteria (4, 5, 7). Jaén-Díaz et al. (5) did not evaluate the diagnostic accuracy of the thickness measurements. Lee et al. (7) and du Toit et al. (4) made measurements from the capitellar region only. In the study by du Toit et al., (4) when tendon thickness measurements were included with gray-scale findings, the sensitivity and specificity were 72% and 52%, respectively; however, sensitivity and specificity for the thickness measurements alone were not calculated. In the study by Lee et al., (7) if the area of the tendon was larger than 35 mm² and if thickness was greater than 4.5 mm, the sensitivity and specificity were 76.5% and 88.9%, and 62.75% and 98.41%, respectively. As thickness or area increased, the specificity increased and sensitivity decreased. Therefore, tendinopathies having an insufficient increase in tendon thickness could be missed, resulting in increased false-negative findings. In that study, the inputs of qualitative and quantitative methods were presented separately, but the overall contributions of each to the diagnosis were not explained (7). In the present study, however, the sensitivity and specificity of both capitellar and radiocapitellar measurements were calculated, and their impact on qualitative methods were calculated separately. The sensitivity of these measurements on their own was low (capitellar 52%, radiocapitellar 38%). If only capitellar measurements were added to the qualitative methods, the sensitivity and specificity increased from 54% and 88% to 79% and 80%, respectively, which is consistent with Lee et al. (7) and du Toit et al. (4). Similarly, if radiocapitellar measurements were added, the sensitivity and specificity increased further to 93% and 91%. Thus, the addition of two measurements to qualitative findings consistently leads to better results than the addition of only one.

Sonoelastographic examinations of elbows with LET were reported, and the sensitivity, specificity, and accuracy were 100%, 89%, and 89%,

respectively (14). The diagnostic accuracy of that research was similar to that of the present study. Furthermore, elastography is expensive and not as widespread or conventional as US, and the standards are not yet as well established. Therefore, at present, the use of elastography in the diagnosis of LET is not indicated.

Our study was not without limitations. The use of clinical diagnosis of LET is one of these limitations. However, the diagnosis of LET is commonly made on clinical grounds, and all previous studies have used clinical diagnosis as references (1–7). Radiologists may fall into subjectivity on US analyses, and the addition of inter-reader comparisons may have been useful. However, inter-reader comparisons on thickness measurements were reported to be satisfactory in the study by Lee et al. (7); therefore single measurement was considered sufficient.

As a conclusion, during the evaluation of LET with US, the addition of tendon thickness measurements at the capitellar and radiocapitellar regions to gray-scale findings is recommended, given the resulting increase in overall diagnostic performance. Increased thickness correlates with changes in tendinosis, and increased thickness in the dominant arm has more diagnostic validity. Care should be taken to detect gray-scale findings in complications of LET, such as tears and effusions, as these findings may alter the treatment protocol.

Conflict of interest disclosure

The authors declared no conflicts of interest.

References

1. Zeisig E, Fahlström M, Ohberg L, Alfredson H. A two-year sonographic follow-up after intratendinous injection therapy in patients with tennis elbow. *Br J Sports Med* 2010; 44:584–587.
2. Walz DM, Newman JS, Konin GP, Ross G. Epicondylitis: pathogenesis, imaging, and treatment. *Radiographics* 2010; 30:167–184.
3. Struijs PA, Spruyt M, Assendelft WJ, van Dijk CN. The predictive value of diagnostic sonography for the effectiveness of conservative treatment of tennis elbow. *AJR Am J Roentgenol* 2005; 185:1113–1118.
4. du Toit C, Stieler M, Saunders R, Bisset L, Vicenzino B. Diagnostic accuracy of power Doppler ultrasound in patients with chronic tennis elbow. *Br J Sports Med* 2008; 42:872–876.

5. Jaén-Díaz JI, Cerezo-López E, López-de Castro F, et al. Sonographic findings for the common extensor tendon of the elbow in the general population. *J Ultrasound Med* 2010; 29:1717–1724.
6. Clarke AW, Ahmad M, Curtis M, Connell DA. Lateral elbow tendinopathy: correlation of ultrasound findings with pain and functional disability. *Am J Sports Med* 2010; 38:1209–1214.
7. Lee MH, Cha JG, Jin W, et al. Utility of sonographic measurement of the common tensor tendon in patients with lateral epicondylitis. *AJR Am J Roentgenol* 2011; 196:1363–1367.
8. Khan KM, Cook JL, Kiss ZS, et al. Patellar tendon ultrasonography and jumper's knee in female basketball players: a longitudinal study. *Clin J Sport Med* 1997; 7:199–206.
9. Sengkerij PM, de Vos RJ, Weir A, van Weelde BJ, Tol JL. Interobserver reliability of neovascularization score using power Doppler ultrasonography in midportion achilles tendinopathy. *Am J Sports Med* 2009; 37:1627–1631.
10. Gisslén K, Alfredson H. Neovascularisation and pain in jumper's knee: a prospective clinical and sonographic study in elite junior volleyball players. *Br J Sports Med* 2005; 39:423–428.
11. Levin D, Nazarian LN, Miller TT, et al. Lateral epicondylitis of the elbow: US findings. *Radiology* 2005; 237:230–234.
12. Connell D, Burke F, Coombes P, et al. Sonographic examination of lateral epicondylitis. *AJR Am J Roentgenol* 2001; 176:777–782.
13. Musculoskeletal ultrasound technical guidelines: II. Elbow. European Society of Musculoskeletal Radiology. Available at: www.essr.org/html/img/pool/elbow.pdf. Accessed on January 01, 2012.
14. De Zordo T, Lill SR, Fink C, et al. Real-time sonoelastography of lateral epicondylitis: comparison of findings between patients and healthy volunteers. *AJR Am J Roentgenol* 2009; 193:180–185.