

PEDIATRICS®

OFFICIAL JOURNAL OF THE AMERICAN ACADEMY OF PEDIATRICS

Intravenous Immunoglobulin in Neonates With Rhesus Hemolytic Disease: A Randomized Controlled Trial

Vivianne E. H. J. Smits-Wintjens, Frans J. Walther, Mirjam E. A. Rath, Irene T. M. Lindenburg, Arjan B. te Pas, Christine M. Kramer, Dick Oepkes, Anneke Brand and Enrico Lopriore

Pediatrics published online Mar 21, 2011;
DOI: 10.1542/peds.2010-3242

The online version of this article, along with updated information and services, is located on the World Wide Web at:

<http://www.pediatrics.org>

PEDIATRICS is the official journal of the American Academy of Pediatrics. A monthly publication, it has been published continuously since 1948. PEDIATRICS is owned, published, and trademarked by the American Academy of Pediatrics, 141 Northwest Point Boulevard, Elk Grove Village, Illinois, 60007. Copyright © 2011 by the American Academy of Pediatrics. All rights reserved. Print ISSN: 0031-4005. Online ISSN: 1098-4275.

American Academy of Pediatrics

DEDICATED TO THE HEALTH OF ALL CHILDREN™



Intravenous Immunoglobulin in Neonates With Rhesus Hemolytic Disease: A Randomized Controlled Trial



WHAT'S KNOWN ON THIS SUBJECT: Treatment with intravenous immunoglobulin for hemolytic disease of the newborn has been proposed as an alternative therapy to reduce the incidence of exchange transfusion. However, its efficacy has not yet been definitively demonstrated in large randomized controlled trials.



WHAT THIS STUDY ADDS: Prophylactic intravenous immunoglobulin does not reduce the need for exchange transfusion or the rates of other adverse neonatal outcomes. Our findings do not support the use of intravenous immunoglobulin in neonates with rhesus hemolytic disease.

abstract

BACKGROUND: Despite limited data, international guidelines recommend the use of intravenous immunoglobulin (IVIg) in neonates with rhesus hemolytic disease.

OBJECTIVE: We tested whether prophylactic use of IVIg reduces the need for exchange transfusions in neonates with rhesus hemolytic disease.

DESIGN AND SETTING: We performed a randomized, double-blind, placebo-controlled trial in neonates with rhesus hemolytic disease. After stratification for treatment with intrauterine transfusion, neonates were randomly assigned for IVIg (0.75 g/kg) or placebo (5% glucose). The primary outcome was the rate of exchange transfusions. Secondary outcomes were duration of phototherapy, maximum bilirubin levels, and the need of top-up red-cell transfusions.

RESULTS: Eighty infants were included in the study, 53 of whom (66%) were treated with intrauterine transfusion(s). There was no difference in the rate of exchange transfusions between the IVIg and placebo groups (7 of 41 [17%] vs 6 of 39 [15%]; $P = .99$) and in the number of exchange transfusions per patient (median [range]: 0 [0–2] vs 0 [0–2]; $P = .90$) or in duration of phototherapy (4.7 [1.8] vs 5.1 [2.1] days; $P = .34$), maximum bilirubin levels (14.8 [4.7] vs 14.1 [4.9] mg/dL; $P = .52$), and proportion of neonates who required top-up red-cell transfusions (34 of 41 [83%] vs 34 of 39 [87%]; $P = .76$).

CONCLUSIONS: Prophylactic IVIg does not reduce the need for exchange transfusion or the rates of other adverse neonatal outcomes. Our findings do not support the use of IVIg in neonates with rhesus hemolytic disease. *Pediatrics* 2011;127:680–686

AUTHORS: Vivianne E. H. J. Smits-Wintjens, MD,^a Frans J. Walther, MD, PhD,^a Mirjam E. A. Rath, MD,^a Irene T. M. Lindenburg, MD,^b Arjan B. te Pas, MD, PhD,^a Christine M. Kramer, BE,^c Dick Oepkes, MD, PhD,^b Anneke Brand, MD, PhD,^d and Enrico Lopriore, MD, PhD^a

^aDivision of Neonatology, Department of Pediatrics, ^bDivision of Fetal Medicine, Department of Obstetrics, and ^cSanquin Blood Bank, Southwest Region and Department of Immunohematology and Blood Transfusion, Leiden University Medical Center, Leiden, Netherlands; and ^dSanquin Blood Supply Foundation, Amsterdam, Netherlands

KEY WORDS

rhesus hemolytic disease of the neonate, intravenous immunoglobulin, phototherapy, exchange transfusion, top-up red-cell transfusion

ABBREVIATIONS

HDN—hemolytic disease of the neonate
IVIg—intravenous immunoglobulin
RCT—randomized controlled trial
AAP—American Academy of Pediatrics
IUT—intrauterine transfusion

Dr Smits-Wintjens had full access to all of the data in the study and takes responsibility for the integrity of the data and the accuracy of the data analysis; Drs Walther, te Pas, Oepkes, Brand, Lopriore, and Smits-Wintjens contributed to the study concept and design; Drs Rath, Lindenburg, Lopriore, and Smits-Wintjens contributed to the acquisition of data; Drs Lopriore and Smits-Wintjens contributed to the statistical analysis, the analysis and interpretation of data, and the drafting of the manuscript; Drs Walther, Rath, Lindenburg, and te Pas, Ms Kramer, and Drs Oepkes, Brand, Lopriore, and Smits-Wintjens contributed to the critical revision of the manuscript for important intellectual content; and Drs Walther, Brand, Lopriore, and Smits-Wintjens contributed to study supervision.

This trial has been registered at www.trialregister.nl (trial ID NTR832).

www.pediatrics.org/cgi/doi/10.1542/peds.2010-3242

doi:10.1542/peds.2010-3242

Accepted for publication Jan 10, 2011

Address correspondence to Vivianne E. H. J. Smits-Wintjens, MD, Department of Pediatrics, Division of Neonatology, J6-S, Leiden University Medical Center, PO Box 9600, 2300 RC Leiden, Netherlands. E-mail: v.smits@lumc.nl

PEDIATRICS (ISSN Numbers: Print, 0031-4005; Online, 1098-4275).

Copyright © 2011 by the American Academy of Pediatrics

FINANCIAL DISCLOSURE: The authors have indicated they have no financial relationships relevant to this article to disclose.

Rhesus hemolytic disease of the neonate (HDN) may lead to excessive hyperbilirubinemia and permanent brain damage because of kernicterus. Traditional neonatal treatment of rhesus HDN consists of intensive phototherapy and exchange transfusion. Phototherapy lowers bilirubin through photooxidation, whereas exchange transfusion removes bilirubin and hemolytic antibodies and corrects anemia.¹ However, exchange transfusion is a high-risk invasive procedure associated with a significant rate of adverse effects. Although the mortality rate associated with exchange transfusion is currently reported to be <0.3% in term infants, the morbidity rates can reach 24% and includes catheter-related complications, sepsis, thrombocytopenia, and hypocalcemia.¹⁻⁷ Neonatal treatment with intravenous immunoglobulin (IVIg) has been suggested as an alternative therapy to exchange transfusion for rhesus HDN.⁸ In many Western countries, including the Netherlands, IVIg is widely used.⁹ A few small randomized controlled trials (RCTs) reported that IVIg combined with phototherapy reduces serum bilirubin levels and the need for exchange transfusion in neonates with rhesus HDN compared with phototherapy alone.¹⁰⁻¹³ In these studies, treatment with IVIg reduced the duration of phototherapy and length of hospitalization but increased the need for top-up red-cell transfusions.

Recommendations for the routine use of IVIg are controversial because of various methodologic limitations of the studies. A Cochrane review¹⁴ suggested in 2002 that the results of additional trials of higher quality should be awaited. The American Academy of Pediatrics (AAP) recommended in 2004 the use of IVIg (0.5–1.0 g/kg) for rhesus HDN in cases of failure of phototherapy on the basis of the same limited data.⁸ Given these conflicting recommendations, a well-designed RCT for the use

of IVIg in rhesus HDN was urgently needed. We hypothesized that IVIg reduces the need for exchange transfusion, and we designed an RCT to address this question.

MATERIALS AND METHODS

We performed a prospective randomized, single-center, double-blind, placebo-controlled trial (www.trialregister.nl/trialreg/admin/rctview.asp?TC=832). The Leiden University Medical Center is the national referral center for the management and intrauterine treatment of red-cell alloimmunization in the Netherlands. All neonates of 35 or more weeks' gestation with rhesus HDN, born between 2006 and 2010 and admitted to the neonatal nursery of the Leiden University Medical Center, were eligible. Rhesus HDN was defined as (1) a maternal antibody-dependent cellular cytotoxicity test with a >50% result, a validated functional test predicting severe hemolysis and comparable with a titer of >1:64¹⁵ and (2) a direct anti-globulin test with positive results caused by anti-rhesus D or c antibodies in the fetus/neonate of a rhesus D or c-negative mother. We excluded all neonates with (1) perinatal asphyxia (defined as an Apgar score at 5 minutes of <3 and/or umbilical cord arterial pH <7.0), (2) hemolytic disease other than rhesus D or c, and (3) rhesus HDN presenting >4 hours after birth.

Written informed parental consent was obtained before birth. After stratification into 2 groups (with and without intrauterine transfusion [IUT]), infants were assigned at birth to the IVIg treatment group (IVIg group) or placebo control group (placebo group) through pharmacy-controlled randomization. The method of treatment allocation was a computer-generated randomization sequence, with the randomization code kept by the chief pharmacist. The block size for randomization was 4 in

the IUT group and 2 in the group without IUT (because of the expected smaller proportions of infants in the non-IUT group). The hospital pharmacy provided identical coded drug boxes, and infusion solutions were delivered in sequentially numbered identical vials that contained either IVIg or placebo. To prevent discrepancy between 2 children of the same family, in case of twins the same vial was used for both children. Clinicians, nurses, and parents were blinded to the randomization and allocation.

In the IVIg group, patients received conventional intensive phototherapy plus prophylactic IVIg as a single dose of 0.75 g/kg (administered in ~5–6 hours), starting within the first 4 hours after birth. In the placebo group, patients received conventional intensive phototherapy plus an equal amount of a 5% glucose intravenous infusion.

The IVIg product used in this trial (Nanogam [Sanquin, Amsterdam, Netherlands]) was treated with solvent detergent to inactivate enveloped viruses and subjected to filtration through a 15-nm filter to remove non-enveloped viruses, including parvovirus B19. Nanogam contains >95% monomeric IgG and no aggregates.

All infants with rhesus HDN admitted to our neonatal nursery received intensive phototherapy directly after birth using a white light with an intensity of 12 to 20 $\mu\text{W}/\text{cm}^2$ per nm given by air shield and Ohmeda lamps, in combination with a bilirubin blanket providing blue light 30 $\mu\text{W}/\text{cm}^2$ per nm. During phototherapy, extra fluids (10 mL/kg) are administered. Phototherapy and exchange transfusion were performed according to the latest AAP guidelines.⁸ The criteria for exchange transfusion were (1) total serum bilirubin above (higher) exchange transfusion thresholds and/or (2) the rise of bilirubin >0.5 mg/dL per hour despite intensive phototherapy and/or (3) clinical symp-

toms of acute bilirubin encephalopathy regardless of bilirubin level. Exchange transfusion criteria were not based on fixed bilirubin thresholds but were derived from the nomograms of AAP and varied according to postnatal age (hours/day) of the neonate. Exchange transfusion was performed with double-volume transfusion (160 mL/kg) using irradiated and leukocyte-depleted compatible erythrocytes.

We recorded the following obstetric and neonatal data: fetal hemoglobin concentration and gestational age at first IUT, number of IUTs, gestational age at birth, birth weight, hemoglobin concentration, reticulocyte count and bilirubin level from cord blood at birth, maximum bilirubin level during admission, duration of phototherapy and admission (days), number of exchange transfusions required, number of top-up red-blood cell transfusions received during the first 3 months of life, and hemoglobin levels before top-up transfusion. Hemoglobin levels were measured routinely every week up to 3 months of age. After discharge from our center, top-up transfusions were performed in referring hospitals when hemoglobin levels were <8.0 or <9.6 g/dL in the presence of clinical symptoms of anemia (such as lethargy, feeding problems, need for oxygen, or failure to thrive). Folic acid (50 μ g/day) was administered orally during the first 3 months of life to all neonates. Data on the number of top-up transfusions and hemoglobin levels in infants managed (after discharge) outside our center were collected through correspondence with the local pediatrician or blood transfusion department.

The primary outcome was the rate of exchange transfusion and the number of exchange transfusions per infant. Secondary outcomes were duration of phototherapy and hospital stay, maximum serum bilirubin levels, and the

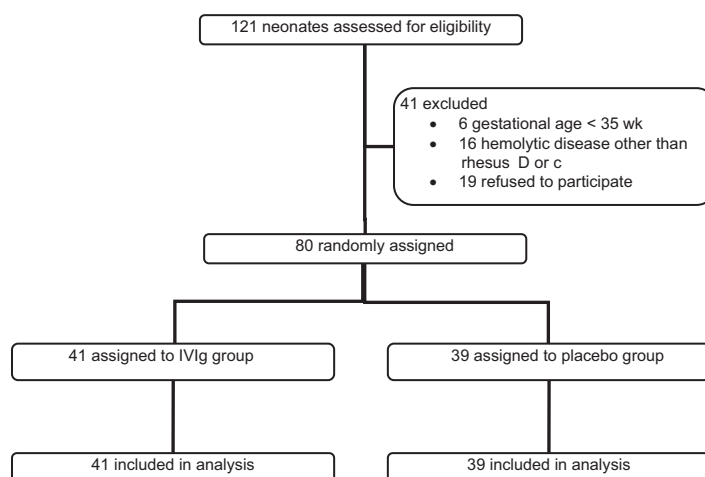


FIGURE 1
Flow diagram of study participants.

need of top-up red-cell transfusions in the first 3 months of life.

On the basis of the available literature, we calculated that a minimum of 40 infants in each study arm were required to demonstrate a fivefold reduction in the need of exchange transfusion between the placebo group and the IVIg group (30% vs 6%) with a significance of 0.05 and a power of 80% by two-tailed analysis. The expected rate (30%) of exchange transfusion in the placebo arm was derived from the recorded incidence on exchange transfusion at our department in 2005–2006. The expected rate (6%) of exchange transfusion in the IVIg group was calculated from the reported data in the literature (Gottstein and Cooke¹¹). According to the meta-analysis from Gottstein and Cooke, the use of IVIg in neonates with rhesus HDN could lead to a fivefold reduction in the incidence of exchange transfusion (relative risk: 0.21 [95% confidence interval: 0.10–0.45]).

Data are reported as means and SDs or as medians and ranges, as appropriate. Statistical analysis was performed using the Student *t* test and Mann-Whitney test for continuous variables. χ^2 and Fisher's exact tests were used for categorical variables, as ap-

propriate. A *P* value of $<.05$ was considered statistically significant. Statistical analysis was performed with SPSS 17.0 (SPSS Inc, Chicago, IL).

RESULTS

A total of 121 neonates with rhesus hemolytic disease were born in the study period, of whom 41 (34%) were excluded (Fig 1). We enrolled 80 patients in the study, 41 patients in the IVIg group and 39 in the placebo group. One pair of twins was included in the IVIg group. Both children received IVIg from the same vial according to the protocol. During infusion of the study medication, no potential adverse effects such as hypotension, tachycardia, or allergic reactions were reported. The baseline characteristics of the 2 treatment groups were similar (Table 1).

Neonatal Outcome: Phototherapy and Exchange Transfusion

All neonates were treated with intensive phototherapy directly after birth. The mean number (SD) of days of phototherapy in neonates in the IVIg group and placebo group was 4.7 (1.8) and 5.1 (2.1), respectively ($P = .34$). At least 1 exchange transfusion was required in 17% (7 of 41) of the neonates in the

TABLE 1 Baseline Characteristics of the Included Patients

	IVIg Group (N = 41)	Placebo Group (N = 39)	P
Gestational age at birth, mean \pm SD, wk	36.7 \pm 1.0	36.5 \pm 0.6	.23
Birth weight, mean \pm SD, g	2994 \pm 485	2953 \pm 424	.68
Male gender, n (%)	29 (71)	25 (64)	.64
Neonates treated with IUT, n (%)	27 (66)	26 (67)	.99
No. of IUTs per neonate, median (range)	1 (0–4)	1 (0–6)	.47
Gestational age at first IUT, mean \pm SD, wk	29 \pm 4	28 \pm 6	.44
Hemoglobin level at first IUT, mean \pm SD, g/dL	6.9 \pm 2.2	6.5 \pm 2.3	.44
Rhesus D immunization, n (%)	36 (88)	35 (90)	.59
Hemoglobin level at birth, mean \pm SD, g/dL	12.2 \pm 2.9	11.9 \pm 2.6	.52
Reticulocyte count at birth, mean \pm SD, %	64 \pm 51	52 \pm 57	.31
Bilirubin level at birth, mean \pm SD, mg/dL	7.0 \pm 3.9	5.7 \pm 2.3	.07

IVIg group compared with 15% (6 of 39) in the placebo group ($P = .99$). The median numbers of exchange transfusions in the IVIg group and placebo group were 0 (range: 0–2) and 0 (range: 0–2), respectively ($P = .90$). The median time from birth to (first) exchange transfusion was 44 hours (range: 9–60) in the IVIg group and 31 hours (range: 22–66) in the placebo group. IVIg or placebo was administered within the first 4 hours after birth.

Maximum mean bilirubin levels during admission were similar in both groups (14.8 \pm 4.7 vs 14.1 \pm 4.9 mg/dL, respectively; $P = .52$). Similar results for the primary and secondary outcomes were observed for the subgroups of neonates after stratification for treatment with or without IUT. Detailed information on neonatal treatment and outcome in both groups, overall and after stratification for IUT, is presented in Table 2.

One included patient developed a *Bacillus cereus* sepsis with brain ab-

cesses a few days after an exchange transfusion performed through an umbilical venous catheter. Because of this serious adverse event, the randomization code for the patient was opened and showed that the infant had received IVIg. Sterility tests on the used IVIg batches were subsequently performed and found to be sterile. In addition, cultures of all donor blood products used for the IUTs and exchange transfusion were examined and found to be sterile. Therefore, the cause of infection remained unclear and may have been related to the umbilical venous catheterization and exchange transfusion. Detailed information on this exceptional case can be found in a case report.¹⁶

Top-up Transfusions

The percentages of neonates requiring a top-up transfusion in the IVIg group and placebo group were 83% (34 of 41) and 87% (34 of 39), respectively ($P = .76$). The median numbers of top-up

transfusions per neonate in the IVIg group and placebo group were 2 (range: 0–6) and 2 (range: 0–6), respectively ($P = .93$). The mean hemoglobin level at first top-up transfusion and the median number of days until first top-up transfusion were similar in both groups. Detailed information on the use of top-up transfusions in the IVIg group and the placebo group is presented in Table 3.

DISCUSSION

In this RCT, we have shown that prophylactic treatment with IVIg in neonates with rhesus hemolytic disease did not reduce the need for exchange transfusion or the rates of other adverse neonatal outcomes. Our results do not support the recommendation to give IVIg in rhesus hemolytic disease, as stated in recent AAP guidelines.⁹ Our study adds to the Cochrane analysis¹⁴ that there is no evidence to recommend routine use of IVIg.

In the past, several studies^{10,12,13,17–19} have suggested a positive effect of IVIg in reducing the rate of hemolysis in rhesus hemolytic disease. Although the exact mechanism of action of IVIg remains unclear, IVIg has been reported to block Fc receptors on macrophages, resulting in a decreased removal of anti-Rh antibody-coated erythrocytes from the circulation. IVIg might increase IgG catabolism, resulting in a shorter half-life of antibodies (including anti-Rh antibodies). A third hypothesis is the presence of anti-

TABLE 2 Neonatal Outcomes in the IVIg and Placebo Groups and According to Stratification for IUT

	Total Group (N = 80)			IUT Group (N = 53)			No-IUT Group (N = 27)		
	IVIg (n = 41)	Placebo (n = 39)	P	IVIg (n = 27)	Placebo (n = 26)	P	IVIg (n = 14)	Placebo (n = 13)	P
Neonates with exchange transfusions, n (%)	7 (17)	6 (15)	.99	7 (26)	4 (15)	0.50	0 (0)	2 (15)	0.22
No. of exchange transfusions per neonate, median (range)	0 (0–2)	0 (0–2)	0.90	0 (0–2)	0 (0–2)	0.54	0 (0–0)	0 (0–1)	0.14
Maximum bilirubin, mean \pm SD, mg/dL	14.8 \pm 4.7	14.1 \pm 4.9	0.52	14.9 \pm 5.2	12.6 \pm 4.8	0.11	14.7 \pm 3.8	17.0 \pm 3.7	0.11
Phototherapy, mean \pm SD, d	4.7 \pm 1.8	5.1 \pm 2.1	0.34	4.4 \pm 1.6	4.5 \pm 2.0	0.74	5.3 \pm 1.9	6.2 \pm 2.0	0.23
Hospitalization, mean \pm SD, d	7 \pm 4	7 \pm 3	0.37	6 \pm 4	7 \pm 3	0.58	7 \pm 4	8 \pm 3	0.45

TABLE 3 Top-up Transfusions in Neonates With Rhesus D or c Hemolytic Disease Treated With or Without IVIg

	Total Group (N = 80)			IUT Group (N = 53)			No-IUT Group (N = 27)		
	IVIg (n = 41)	Placebo (n = 39)	P	IVIg (n = 27)	Placebo (n = 26)	P	IVIg (n = 14)	Placebo (n = 13)	P
Neonates requiring top-up transfusions, n (%)	34 (83)	34 (87)	0.76	23 (85)	24 (92)	0.67	11 (78)	10 (77)	.99
No. of top-up transfusions per neonate, median (range)	2 (0–6)	2 (0–6)	0.93	2 (0–6)	2 (0–6)	0.71	2 (0–5)	1 (0–5)	0.70
1 top-up transfusion, n (%)	8 (20)	10 (26)	0.51	6 (22)	5 (19)	0.79	2 (14)	5 (38)	0.21
2 top-up transfusions, n (%)	12 (29)	8 (21)	0.37	7 (26)	7 (27)	0.93	5 (36)	1 (8)	0.16
3 top-up transfusions, n (%)	6 (15)	9 (23)	0.33	4 (15)	7 (26)	0.28	2 (14)	2 (15)	.99
4 top-up transfusions, n (%)	4 (10)	4 (10)	.99	3 (11)	3 (12)	.99	1 (7)	1 (8)	.99
5 top-up transfusions, n (%)	2 (5)	2 (5)	.99	1 (4)	1 (4)	.99	1 (7)	1 (8)	.99
6 top-up transfusions, n (%)	2 (5)	1 (3)	.99	2 (7)	1 (4)	.99	0 (0)	0 (0)	.99
Days after birth until first top-up transfusion, mean ± SD	12 ± 12	16 ± 15	0.24	12 ± 12	16 ± 16	0.33	13 ± 11	17 ± 15	0.50
Hemoglobin level at first top-up transfusion, mean ± SD, g/dL	8.4 ± 1.3	8.1 ± 1.4	0.38	8.5 ± 1.3	8.1 ± 1.5	0.25	8.0 ± 1.1	8.1 ± 1.0	0.77

idiotypic antibodies in IVIg neutralizing anti-Rh antibodies.^{12,20–22}

Our results are in contrast with the most recent recommendations of the AAP to use 0.5 to 1.0 g/kg IVIg in rhesus hemolytic disease in cases of failure of phototherapy.⁸ These guidelines were published in 2004 on the basis of a limited number of small RCTs. Several important methodologic limitations hampered the interpretation of these studies, including suboptimal study designs and the wide range of inclusion criteria.^{18,19} The Cochrane Collaboration performed a review on 3 studies, in which a total of 189 infants were included.^{10,12–14} Rubo et al¹⁰ included 32 infants with rhesus hemolytic disease in a multicenter RCT. No details on IUT and gestational age were given. Several years later, Dağoğlu et al¹⁵ included 29 preterm and 12 term infants in an RCT. Cutoff for prematurity and criteria for top-up red-cell transfusions were not defined. In 1999, Alpay et al¹² enrolled 116 infants, predominantly with ABO incompatibility (n = 93), but also neonates with rhesus hemolytic disease (n = 16) and both Rh and ABO incompatibility (n = 7) were included. However, results were not given for each group separately. None of the studies described detailed phototherapy guidelines, and none of them

used a placebo in the control group or described any method of blinding the intervention after allocation concealment. According to the Cochrane review, none of the trials fulfilled criteria for a high-quality study. Our study is the first well-designed randomized, double-blind placebo-controlled trial on this topic.

In 4 other studies,^{12,17,18,23} infants with ABO incompatibility were included. In general, compared with rhesus immunization, ABO incompatibility causes less severe hemolysis and therefore less neonatal morbidity.²⁴ For that reason, we included only neonates with rhesus disease. These important methodologic differences between our study and the previous ones may explain the discordant results.

Several other explanations can be envisaged to explain the lack of effect of IVIg in our study. A possible explanation could be the treatment with intensive and prophylactic phototherapy starting immediately after birth, thereby reducing the risk of severe hyperbilirubinemia. In addition, the majority of infants included in our study were treated with IUT. By IUT, rhesus-incompatible erythrocytes of the fetus are replaced by rhesus-compatible cells of the donor. Dependent on the

interval between the last IUT and delivery, these donor cells still are present after birth, resulting in less- or more-delayed hemolysis.^{25,26} However, several groups including ours have shown that even after IUT, neonates with rhesus hemolytic disease still often require exchange transfusion.^{27,28} In our study, IVIg was neither effective in the IUT group or in the group without IUT. However, the number of patients included in the subgroup without IUT (n = 27) may be too small to draw firm conclusions. Recently, a research group from Brazil finalized a similar RCT on IVIg for neonates with rhesus hemolytic disease and, in accordance with our results, found no difference between both groups on the rate of exchange transfusion. It is important to note that in their study, the vast majority of patients (n = 80) had no previous treatment with IUT (ClinicalTrials.gov identifier NCT00288600).²⁹ Therefore, both our RCT and the RCT from the Brazilian research group failed to show any effect of IVIg in infants with rhesus hemolytic disease, irrespective of whether the infants were treated with IUT. Care should be taken when interpreting our results, particularly the subgroup analyses, because of the relatively limited number of patients. In addition, caution should be used be-

fore applying the results of this study to all rhesus-isoimmunized infants. There may be a subset of rhesus-isoimmunized infants with (inappropriate) delayed start of intensive phototherapy, for whom IVIg might be effective. More studies are needed to study the effect of IVIg in this specific subset of infants.

Although IVIg is considered to be an extremely safe product, adverse events can not be totally eliminated. Rare but serious adverse effects such as transfusion-transmitted diseases, anaphylaxis, hypersensitivity, thrombosis, pulmonary emboli, and renal failure have been reported.^{21,22} Recently, Figueras-Aloy et al³⁰ reported a higher incidence of necrotizing enterocolitis in near-term infants with rhesus hemolytic disease treated with IVIg

compared with a control group managed without IVIg. The authors correctly suggest that their results must be interpreted with care given the retrospective nature of the study. Whether occurrence of necrotizing enterocolitis was related to the administration of IVIg or to the fact that infants receiving IVIg were more ill than the control group is not clear. Nevertheless, because potential (but rare) adverse effects associated with the use of IVIg can not be ruled out, the authors call for more caution when using IVIg in neonates with rhesus hemolytic disease. IVIg is a blood product prepared by separating the γ -globulin fraction from the plasma pooled from multiple donors. The manufacturing of IVIg, including fractionation and filtration of viruses, is an extremely intensive and expensive process. Therefore, the use

of IVIg for indications that are not confirmed by well-designed RCTs should be restricted.²²

CONCLUSIONS

Prophylactic treatment with IVIg (in a dosage of 0.75 g/kg) did not reduce the need for exchange transfusion or the rates of other adverse neonatal outcomes. Our findings do not support the current recommendations of the AAP to use IVIg in neonates with rhesus hemolytic disease. In view of the absence of beneficial effects, the use of IVIg for this indication should be discouraged.

ACKNOWLEDGMENT

Nanogam was provided by Sanquin Blood Supply Foundation (Amsterdam, Netherlands).

REFERENCES

- Smits-Wintjens VE, Walther FJ, Lopriore E. Rhesus haemolytic disease of the newborn: postnatal management, associated morbidity and long-term outcome. *Semin Fetal Neonatal Med.* 2008;13(4):265–271
- Keenan WJ, Novak KK, Sutherland JM, Bryla DA, Fetterly KL. Morbidity and mortality associated with exchange transfusion. *Pediatrics.* 1985;75(2 pt 2):417–421
- Patra K, Storfer-Isser A, Siner B, Moore J, Hack M. Adverse events associated with neonatal exchange transfusion in the 1990s. *J Pediatr.* 2004;144(5):626–631
- Jackson JC. Adverse events associated with exchange transfusion in healthy and ill newborns. *Pediatrics.* 1997;99(5). Available at: www.pediatrics.org/cgi/content/full/113/2/e7
- Steiner LA, Bizzarro MJ, Ehrenkranz RA, Gallagher PG. A decline in the frequency of neonatal exchange transfusions and its effect on exchange-related morbidity and mortality. *Pediatrics.* 2007;120(1):27–32
- Thayil S, Milligan DW. Single versus double volume exchange transfusion in jaundiced newborn infants. *Cochrane Database Syst Rev.* 2006;(4):CD004592
- Hovi L, Siimes MA. Exchange transfusion with fresh heparinized blood is a safe procedure: experiences from 1 069 newborns. *Acta Paediatr Scand.* 1985;74(3):360–365
- American Academy of Pediatrics Subcommittee on Hyperbilirubinemia. Management of hyperbilirubinemia in the newborn infant 35 or more weeks of gestation. *Pediatrics.* 2004;114(1):297–316
- New HV, Stanworth SJ, Engelfriet CP, et al. Neonatal transfusions. *Vox Sang.* 2009;96(1):62–85
- Rubo J, Albrecht K, Lasch P, et al. High-dose intravenous immune globulin therapy for hyperbilirubinemia caused by Rh hemolytic disease. *J Pediatr.* 1992;121(1):93–97
- Gottstein R, Cooke RW. Systematic review of intravenous immunoglobulin in haemolytic disease of the newborn. *Arch Dis Child Fetal Neonatal Ed.* 2003;88(1):F6–F10
- Alpay F, Sarici SU, Okutan V, Erdem G, Ozcan O, Gokcay E. High-dose intravenous immunoglobulin therapy in neonatal immune haemolytic jaundice. *Acta Paediatr.* 1999;88(2):216–219
- Dağoğlu T, Ovalı F, Samancı N, Bengisu E. High-dose intravenous immunoglobulin therapy for rhesus haemolytic disease. *J Int Med Res.* 1995;23(4):264–271
- Alcock GS, Liley H. Immunoglobulin infusion for isoimmune haemolytic jaundice in neonates. *Cochrane Database Syst Rev.* 2002;(3):CD003313
- Oepkes D, Van Kamp IL, Simon MJ, Mesman J, Overbeek MA, Kanhai HH. Clinical value of an antibody-dependent cell-mediated cytotoxicity assay in the management of Rh D alloimmunization. *Am J Obstet Gynecol.* 2001;184(5):1015–1020
- Smits-Wintjens VE, Steggerda SJ, Oepkes D, et al. Bacillus cereus cerebral abscesses in a term neonate with rhesus hemolytic disease treated with exchange transfusion. *J Pediatr Inf Dis.* 2010;5(3):277–280
- Nasseri F, Mamouri GA, Babaei H. Intravenous immunoglobulin in ABO and Rh hemolytic diseases of newborn. *Saudi Med J.* 2006;27(12):1827–1830
- Tanyer G, Siklar Z, Dallar Y, Yildirmak Y, Tiras U. Multiple dose IVIg treatment in neonatal immune hemolytic jaundice. *J Trop Pediatr.* 2001;47(1):50–53
- Voto LS, Sexer H, Ferreiro G, et al. Neonatal administration of high-dose intravenous immunoglobulin in rhesus hemolytic disease. *J Perinat Med.* 1995;23(6):443–451
- Kriplani A, Malhotra SB, Mandal K. Fetal intravenous immunoglobulin therapy in rhesus hemolytic disease. *Gynecol Obstet Invest.* 2007;63(3):176–180
- Walsh S, Molloy EJ. Toward evidence based medicine for paediatricians: is intravenous immunoglobulin superior to exchange transfusion in the management of hyperbilirubinaemia in term neonates? *Arch Dis Child.* 2009;94(9):739–741
- Kumar A, Teuber SS, Gershwin ME. Intrave-

- nous immunoglobulin: striving for appropriate use. *Int Arch Allergy Immunol.* 2006;140(3):185–198
23. Miqdad AM, Abdelbasit OB, Shaheed MM, Seidahmed MZ, Abomelha AM, Arcala OP. Intravenous immunoglobulin G (IVIg) therapy for significant hyperbilirubinemia in ABO hemolytic disease of the newborn. *J Matern Fetal Neonatal Med.* 2004;16(3):163–166
 24. Murray NA, Roberts IA. Haemolytic disease of the newborn. *Arch Dis Child Fetal Neonatal Ed.* 2007;92(2):F83–F88
 25. Oepkes D, Adama van SP. Intrauterine fetal transfusions in the management of fetal anemia and fetal thrombocytopenia. *Semin Fetal Neonatal Med.* 2007;12(6):432–438
 26. Egberts J, Van Kamp IL, Kanhai HH, Meerman RH, Giordano PC, Gravenhorst JB. The disappearance of fetal and donor red blood cells in alloimmunised pregnancies: a reappraisal. *Br J Obstet Gynaecol.* 1997;104(7):818–824
 27. De Boer I, Zeestraten EC, Lopriore E, Van Kl, Kanhai HH, Walther FJ. Pediatric outcome in rhesus hemolytic disease treated with and without intrauterine transfusion. *Am J Obstet Gynecol.* 2008;198(1):54
 28. Rath ME, Smits-Wintjens VE, Lindenburg I, et al. Top-up transfusions in neonates with Rh hemolytic disease in relation to exchange transfusions. *Vox Sang.* 2010;99(1):65–70
 29. Santos MC, Sa CA, Gomes SC, Camacho LA, Moreira ME. High-dose intravenous immunoglobulin therapy for hyperbilirubinemia due to Rh hemolytic disease: a randomized clinical trial. Presented at: Pediatric Academic Societies annual meeting; May 1–4, 2010; Vancouver, British Columbia, Canada
 30. Figueras-Aloy J, Rodriguez-Miguel JM, Iriundo-Sanz M, Salvia-Roiges MD, Botet-Mussons F, Carbonell-Estrany X. Intravenous immunoglobulin and necrotizing enterocolitis in newborns with hemolytic disease. *Pediatrics.* 2010;125(1):139–144

BREAKFAST CALORIES: *Just the other day my daughter and I had a lively discussion about the importance of eating breakfast. The background is that she is trying to lose a couple of pounds before lacrosse season begins. During high school biology class, her teacher told her that breakfast was the most important meal of the day. Eating a big breakfast would decrease the total amount of food consumed during the day, ensure wakefulness, and provide essential nutrition for the brain. While I don't doubt the value of a nutritious meal, I told her that eating a big breakfast in the morning was not going to help her lose weight (I opted not to discuss the brain). "You don't know everything" was her retort (which is certainly true). However, recent data would suggest that eating a big breakfast is not helpful to dieters. According to an article in The New York Times (January 28, 2011: Health), eating a large breakfast does not reduce the total number of calories eaten in a day. Over two weeks, German researchers monitored the food intake among 280 obese and 100 normal weight adults. Both groups were instructed to record everything consumed during the time period. For both groups, regardless of how much was consumed at breakfast, the non-breakfast caloric intake remained the same. In other words, a big breakfast only added to the total number of calories consumed. Contrary to popular wisdom (and the advice of high school biology teachers) this means that smaller breakfasts mean fewer daily calories consumed. Breakfast favorites such as bread, eggs, yogurt, cheeses, and butter were responsible for much of the variation seen in the German subjects' daily caloric intake. My daughter still begins the day with a toasted bagel slathered in cream cheese. After all, she is not going to change behavior based on my advice. Still, as a father, I feel a certain amount of vindication that I may actually have been right.*

Noted by WVR, MD

**Intravenous Immunoglobulin in Neonates With Rhesus Hemolytic Disease: A
Randomized Controlled Trial**

Vivianne E. H. J. Smits-Wintjens, Frans J. Walther, Mirjam E. A. Rath, Irene T. M. Lindenburg, Arjan B. te Pas, Christine M. Kramer, Dick Oepkes, Anneke Brand and Enrico Lopriore

Pediatrics published online Mar 21, 2011;

DOI: 10.1542/peds.2010-3242

**Updated Information
& Services**

including high-resolution figures, can be found at:
<http://www.pediatrics.org>

Permissions & Licensing

Information about reproducing this article in parts (figures, tables) or in its entirety can be found online at:
<http://www.pediatrics.org/misc/Permissions.shtml>

Reprints

Information about ordering reprints can be found online:
<http://www.pediatrics.org/misc/reprints.shtml>

American Academy of Pediatrics

DEDICATED TO THE HEALTH OF ALL CHILDREN™

