

CASE REPORT

Open Access

An immunocompetent migrant presenting with neurosyphilis with an unusual unilateral papillitis: a case report

Paolo Turchetti¹, Fernanda Pacella², Elena Pacella², Concetta Mirisola¹ and Ilaria Uccella^{1*}

Abstract

Unilateral papillitis caused by *Treponema pallidum* was found in an immunocompetent homosexual patient with severe vision loss who had received previous antibiotics treatment. Syphilis-related ocular manifestation is more common in the early stages of the disease and it can be associated with a central nervous system localization. In this patient, neurosyphilis was diagnosed on the basis of clinical and laboratory findings. Optical examination revealed unilateral papillitis in the left eye and no relative afferent pupillary defects. The patient underwent visual field examinations with conventional perimetry using the 30-2 program of the Humphrey Visual Field Analyzer, which indicated a blind spot enlargement in the left eye. Optical coherence tomography, visual evoked potentials (VEP), and fluorescein angiograms revealed inflammation of the optic nerve head with edematous and blurred margins. A reactive *T. pallidum* hemagglutination assay with low rapid plasma reagin (RPR) serum titer was performed; an HIV antibody test and MRI of the orbits and head with contrast gave negative results. Resolution of the ocular inflammation after intravenous penicillin treatment was obtained. The reported case illustrates the importance of early recognition of this treatable disease. The rise of syphilis, especially in urban areas, necessitates a high level of suspicion when dealing with patients with intraocular inflammation of unknown origin. Lues serology should be incorporated into routine laboratory diagnostics to aid in the detection of such cases. Considering the re-emergence of syphilis, screening of migrants from countries with high syphilis seroprevalences should be recommended.

Keywords: migrant, papillitis, syphilis, treponema

Introduction

Syphilis represents a global health issue, with an estimated 12 million people infected every year; this infectious disease is prevalent in Africa, Asia and South America. In European countries, syphilis is considered a re-emerging infectious pathology. The European Centre for Disease Prevention and Control (ECDC) has reported that the overall number of syphilis cases increased substantially in most Western European countries between 1998 and 2007, mostly among men [1].

In recent years, most of the reported syphilis cases have been associated with HIV infection [2-5].

In 2007, Italy registered 720 cases of syphilis, 561 among males. No data exist about migrants. The complexity of syphilis diagnosis based on clinical and serological findings is already subject of scientific discussion, and is leading to the revision of treatment guidelines [6,7].

Severe vision loss due to *Treponema pallidum* causing syphilis is a rare manifestation of this disease in the antibiotic era, especially in developed countries [8,9]. The most common ocular manifestation of this infection is uveitis, occurring in 2.5 to 5% of patients with tertiary syphilis [10]. Other ocular manifestations are focal retinitis, papillitis, iritis, keratic precipitates, periphlebitis, vitritis, and serous and exudative retinal detachment [11,12].

The ability of syphilis to mimic different ocular disorders can lead to misdiagnosis and delay in the administration of appropriate antimicrobial therapy, particularly in persons who receive inadequate penicillin therapy. To

* Correspondence: uccella@inmp.it

¹National Institute for Health, Migration and Poverty (INMP/NIHMP), Rome, Italy

Full list of author information is available at the end of the article

the best of our knowledge, few cases of unusual neurosyphilis presentation have been reported in the literature. In the present work, a case of ocular and atypical neurosyphilis in an HIV-negative patient is described.

Case report

A 38-year-old Brazilian transgender patient attending the outpatient department of the National Institute for Health, Migration and Poverty (NIHMP), presented with a sudden decrease of visual acuity in the left eye (visual best-corrected acuity (VBCA) 20/70). The patient's history revealed a previous treatment with antibiotics for a dental infection. The last event of unprotected sexual intercourse dated back to 1 year previously.

An optical examination revealed unilateral papillitis in left eye (Figure 1) and no relative afferent pupillary defect (RAPD). The patient underwent visual field examinations with conventional perimetry using the 30-2 program of the Humphrey Visual Field Analyzer that indicated a slight central sensitivity loss or a paracentral scotoma in the left eye (Figures 2 and 3).

An optical coherence tomography (OCT) scan of the left eye showed some thickening of the retinal pigment epithelium (RPE) layer at initial presentation (Figure 4). The visual evoked potentials (VEPs) revealed a decrease in VEP amplitude with normal latency (Figure 5). Fluorescein angiograms (FA) (Figure 6A, B) revealed inflammation of the optic nerve head with edematous and blurred margins.

On clinical examination, neurological symptoms were excluded. A reactive *Treponema pallidum* hemagglutination assay (TPHA) with low rapid plasma reagin (RPR) titer was performed. An HIV antibody test gave negative results. Different internal localization of syphilis

(gumma) and mucocutaneous lesions were absent. Blood tests to eliminate the suspicion of other infections and systemic disorders were performed. An MRI of the orbits and head with contrast did not show signal alteration.

The patient was treated with 12 million units of aqueous penicillin G intravenously daily (3 million units intravenously every 4 h) for 14 days with resolution of the anterior segment and the optical nerve inflammation. As the antibiotic therapy was administered, the patient's visual acuity gradually fully recovered. He was unfortunately lost to follow up because our hospital accepts and treats patients who have no residence permit and who often are afraid to report for checks.

Conclusions

Papillitis, also known as optic neuritis, is characterized by inflammation and deterioration of the portion of the optic nerve known as the optic disc. This localization is a relatively rare ocular manifestation of syphilis and its incidence is high in HIV-positive individuals [13-15].

Uveitis is more common in early syphilis [16] and may be accompanied by neurosyphilis. Among patients with secondary syphilis, about 5% present with chorioretinitis and 50% of these with bilateral lesions [16,17].

Moreover, granulomatous anterior uveitis could be related to other infectious diseases and autoimmune disorders (tuberculosis, herpes viruses, Lyme disease, Behçet's disease, sarcoidosis) that have to be excluded.

In our patient's case, the diagnosis of papillitis due to *T. pallidum* was performed on the basis of serological positive test and clinical ocular manifestations. The consideration that our patient was young and a congenital

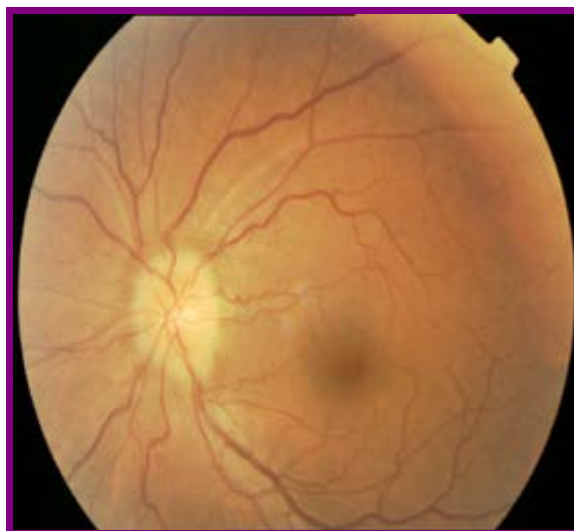

Figure 1 Fundus appearance of the left eye at initial presentation.

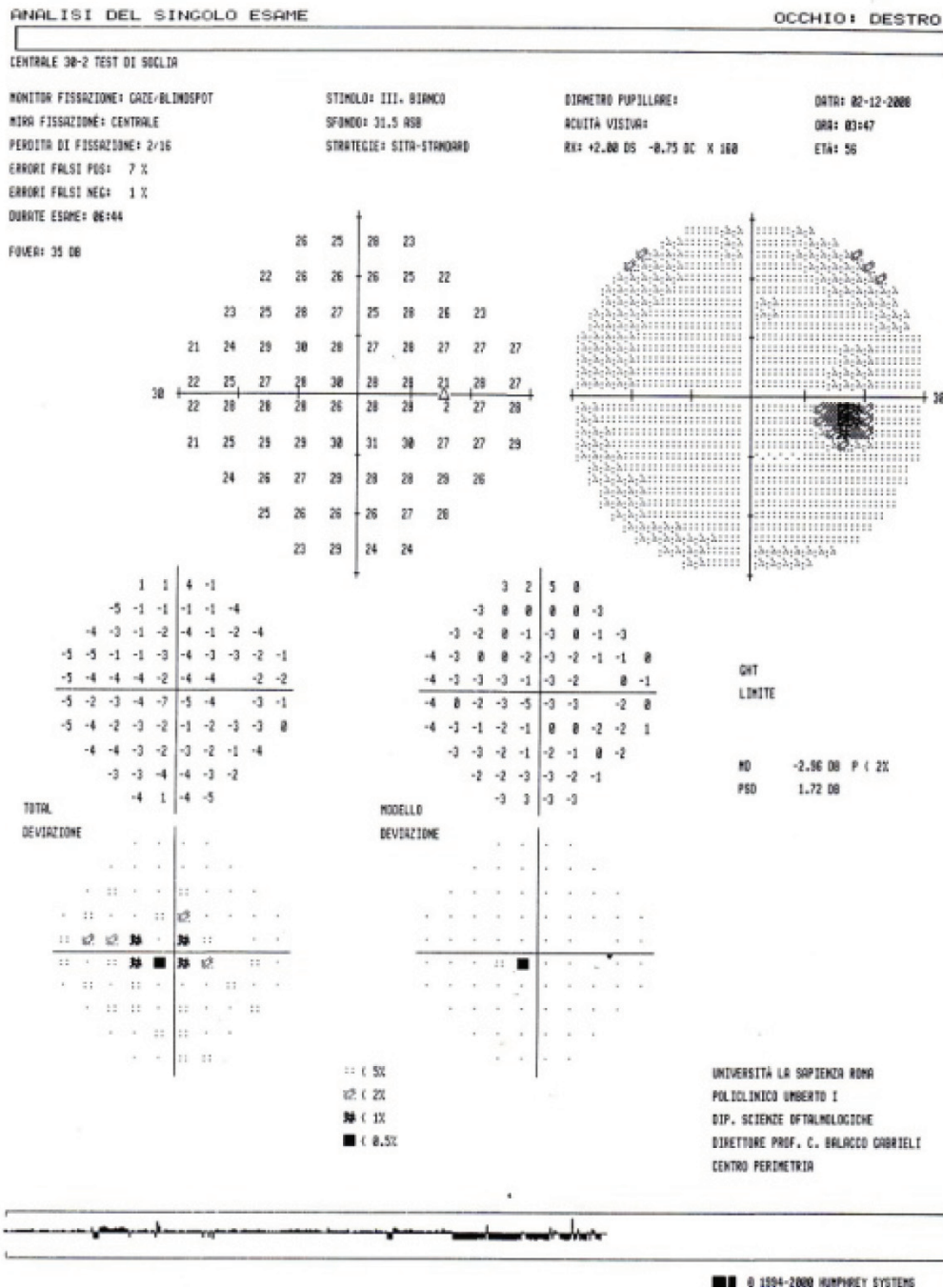


Figure 3 The 30-2 program of the Humphrey Visual Field Analyzer that indicates a slight central sensitivity loss or a paracentral scotoma in the left eye (see also Figure 2).

STRATUS OCT
Retinal Map Analysis Report - 4.0.1 (0056)



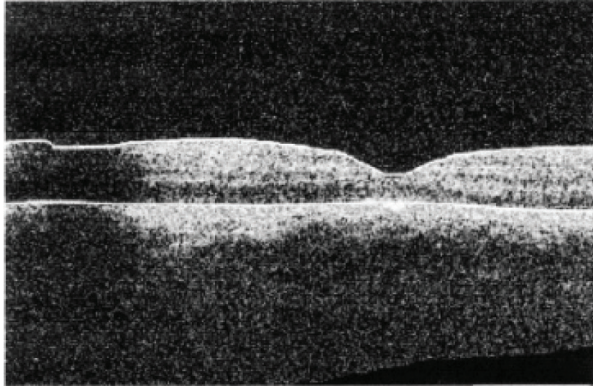
Scan Type: Radial Lines OS

Scan Date:

DOB: 9/9/1996, ID:

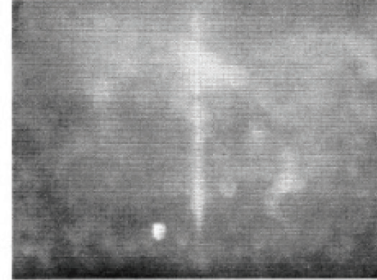
Scan Length: 6.0 mm

OCT Image

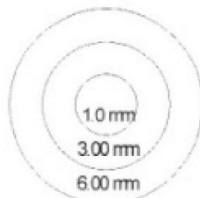
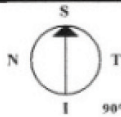


Signal Strength (Max: 10)	4
Missing Data	

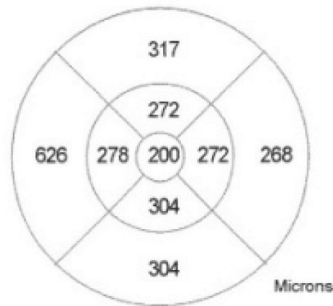
Fundus Image




Center	174 +/- 33 microns
Total Volume	9.97 mm ³



Map Diameters



Microns

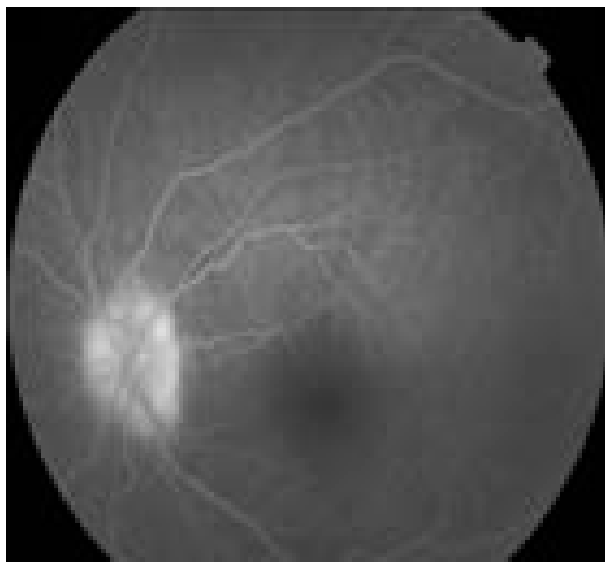

Scans Used: 1, 2, 3, 4, 5, 6

Signature: _____

Figure 4 Optical coherence tomography (OCT) scan of the left eye at initial presentation. There was some thickening of the retinal pigment epithelium (RPE) layer with the inflammation of the optic nerve head with edematous and blurred margins.

A



B

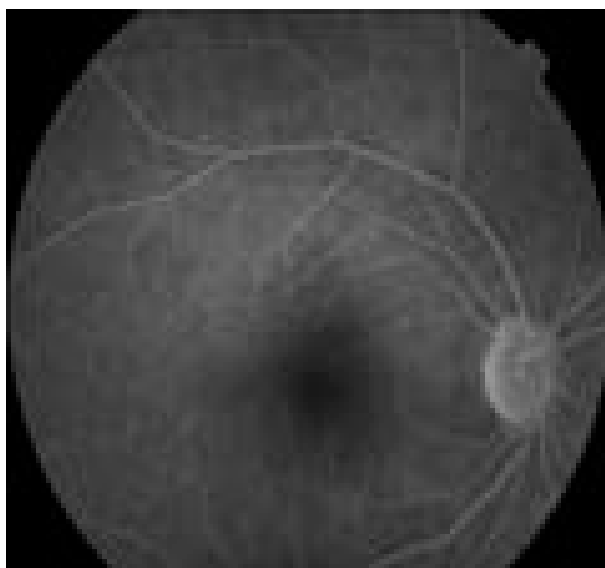


Figure 6 (A) Fundus fluorescein angiogram at presentation of syphilitic papillitis. (B) Fundus fluorescein angiogram 4 weeks after treatment.

Author details

¹National Institute for Health, Migration and Poverty (INMP/NIHMP), Rome, Italy. ²Ophthalmological Science Department, University 'La Sapienza', Rome, Italy.

Authors' contributions

PT conceived the case report and participated in the drafting of the manuscript; FP performed the ophthalmic emergency visit and clinic follow

up; EP performed the OCT; CM participated in the drafting of the manuscript; IU participated in its design and coordination and drafting of the manuscript. All authors read and approved the final manuscript.

Competing interests

The authors declare that they have no competing interests.

Received: 16 December 2011 Accepted: 14 February 2012
Published: 14 February 2012

References

1. Savage EJ, Hughes G, Ison C, Lowndes CM, European Surveillance of Sexually Transmitted Infections Network: **Syphilis and gonorrhoea in men who have sex with men: a European overview.** *Euro Surveill* 2009, **14**(47), pii:19417.
2. Dougan S, Evans BG, Elford J: **Sexually transmitted infections in Western Europe among HIV-positive men who have sex with men.** *Sex Transm Dis* 2007, **34**:783-790.
3. Kuo IC, Kapusta MA, Rao NA: **Vitritis as the primary manifestation of ocular syphilis in patients with HIV infection.** *Am J Ophthalmol* 1998, **125**:306-311.
4. Browning DJ: **Posterior segment manifestations of active ocular syphilis, their response to a neurosyphilis regimen of penicillin therapy, and the influence of human immunodeficiency virus status on response.** *Ophthalmology* 2000, **107**:2015-2023.
5. Stolte IG, Dukers NH, de Wit JB, Fennema JS, Coutinho RA: **Increase in sexually transmitted infections among homosexual men in Amsterdam in relation to HAART.** *Sex Transm Infect* 2001, **77**:184-186.
6. Marra CM: **Update on neurosyphilis.** *Curr Infect Dis Rep* 2009, **11**:127-134.
7. Ronald AR, Silverman M, McCutchan JA, Corey L, Handsfield HH: **Evaluation of new anti-infective drugs for the treatment of syphilis.** *Infectious Diseases Society of America and the Food and Drug Administration. Clin Infect Dis* 1992, **15**(Suppl 1):S140-147, S 99-107.
8. Chao JR, Khurana RN, Fawzi AA, Reddy HS, Rao NA: **Syphilis: re-emergence of an old adversary.** *Ophthalmology* 2006, **113**:2074-2079.
9. Probst LE, Wilkinson J, Nichols BD: **Diagnosis of congenital syphilis in adults presenting with interstitial keratitis.** *Can J Ophthalmol* 1994, **29**:77-80.
10. Aldave AJ, King JA, Cunningham ET Jr: **Ocular syphilis.** *Curr Opin Ophthalmol* 2001, **12**:433-441.
11. Doris JP, Saha K, Jones NP, Sukthankar A: **Ocular syphilis: the new epidemic.** *Eye* 2006, **20**:703-705.
12. Jumper JM, Machemer R, Gallemore RP, Jaffe GJ: **Exudative retinal detachment and retinitis associated with acquired syphilitic uveitis.** *Retina* 2000, **20**:190-194.
13. B'chir Hanzaoui S, Znagui Z, Farah , Bouslama K, Ben Dridi M: **A case of papillitis revealing primary syphilis [in French].** *Med Mal Infect* 2007, **37**:67-68.
14. Shalaby IA, Dunn JP, Semba RD, Jabs DA: **Syphilitic uveitis in human immunodeficiency virus-infected patients.** *Arch Ophthalmol* 1997, **115**:469-473.
15. Tamesis RR, Foster CS: **Ocular syphilis.** *Ophthalmology* 1990, **97**:1281-1287.
16. Kiss S, Damico FM, Young LH: **Ocular manifestations and treatment of syphilis.** *Semin Ophthalmol* 2005, **20**:161-167.
17. Morgan S, Laufer H: **Atypical syphilitic chorioretinitis and vasculitis.** *Retina* 1984, **4**:225-231.
18. Saloojee H, Velaphi S, Goga Y, Afadapa N, Steen R, Lincetto O: **The prevention and management of congenital syphilis: an overview and recommendations.** *Bull World Health Organ* 2004, **82**:424-430.
19. Valderama J, Zacarias F, Mazin R: **Maternal syphilis and congenital syphilis in Latin America: big problem, simple solution [in Spanish].** *Rev Panam Salud Publica* 2004, **16**:211-217.
20. Marra CM, Maxwell CL, Smith SL, Lukehart SA, Rompalo AM, Eaton M, Stoner BP, Augenbraun M, Barker DE, Corbett JJ, Zajackowski M, Raines C, Nerad J, Kee R, Barnett SH: **Cerebrospinal fluid abnormalities in patients with syphilis: association with Clinical and laboratory features.** *J Infect Dis* 2004, **189**:369-376.
21. Dans PE, Cafferty L, Otter SE, Johnson RJ: **Inappropriate use of the cerebrospinal fluid Venereal Disease Research Laboratory (VDRL) test to exclude neurosyphilis.** *Ann Intern Med* 1986, **104**:86-89.
22. Chao JR, Khurana RN, Fawzi AA, Reddy HS, Rao NA: **Syphilis: reemergence of an old adversary.** *Ophthalmology* 2006, **113**:2074-2079.
23. Hart G: **Syphilis tests in diagnostic and therapeutic decision making.** *Ann Intern Med* 1986, **104**:368-376.
24. Chen J, Lee L: **Posterior placoid chorioretinitis: An unusual ocular manifestation of syphilis.** *Clin Ophthalmol* 2008, **2**:669-673.
25. Porstman AU, Marcus U, Pleyer U: **Primary diagnosis of syphilis by the ophthalmologist [in German].** *Klin Monbl Augenheilkd* 2002, **219**:349-352.
26. Ruiz-Veraga Ruiz-Vegara M, Monge-Argilés JA, Turpin-Fenoll L, Marti-Martinez S, Pampliega-Pérez A: **Unilateral papillitis as the presenting symptom of neurosyphilis [in Spanish].** *Rev Neurol* 2008, **46**:188-189.
27. Bialasiewicz AA, Dommer S: **Disseminated choroiditis, papillitis and vasculitis retinae as main findings in lues II-III [in German].** *Klin Monbl Augenheilkd* 1991, **198**:37-43.
28. Dumortier C, Alcaraz I, Tone A, Burban SD, Delesalle F, Maryse F, Melliez H, Viget N, Baclot V, Pavel S, Ajana F, Yazdanpanah Y: **Non-cutaneous manifestations of secondary syphilis [in French].** *Ann Dermatol Venereol* 2008, **135**:451-458.
29. Amirhanian YA, Kelly JA, Kirsanova AV, DiFranceisco W, Khoursine RA, Semenov AV, Rozmanova VN: **HIV risk behaviour patterns, predictors, and sexually transmitted disease prevalence in the social networks of young men who have sex with men in St Petersburg Russia.** *Int J STD AIDS* 2006, **17**:50-56.
30. Burns FM, Mercer CH, Evans AR, Gerry CJ, Mole R, Hart GJ: **Increased attendances of people of eastern European origin at sexual health services in London.** *Sex Transm Infect* 2009, **85**:75-78.
31. Gutiérrez M, Tajada P, Alvarez A, De Julián R, Baquero M, Soriano V, Holguin A: **Prevalence of HIV-1 non-B subtypes, syphilis, HTLV, and hepatitis B and C viruses among immigrant sex workers in Madrid, Spain.** *J Med Virol* 2004, **74**:521-527.
32. Fonollosa A, Giralt J, Pelegrín L, Sánchez-Dalmau B, Segura A, Adan A: **Ocular syphilis back again: understanding recent increases in the incidence of ocular syphilitic disease.** *Ocul Immunol Inflamm* 2009, **17**:207-212.
33. Tavora-Tavira L, Teodosio R, Seixas J, Prieto E, Castro R, Exposto F, Atouguia J: **Sexually transmitted infections in an African migrant population in Portugal: a base-line study.** *J Infect Dev Ctries* 2007, **1**:326-328.

doi:10.1186/2047-783X-17-3

Cite this article as: Turchetti et al.: An immunocompetent migrant presenting with neurosyphilis with an unusual unilateral papillitis: a case report. *European Journal of Medical Research* 2012 **17**:3.

Submit your next manuscript to BioMed Central and take full advantage of:

- Convenient online submission
- Thorough peer review
- No space constraints or color figure charges
- Immediate publication on acceptance
- Inclusion in PubMed, CAS, Scopus and Google Scholar
- Research which is freely available for redistribution

Submit your manuscript at
www.biomedcentral.com/submit

