

SHORT REPORT

Ipecac myopathy and cardiomyopathy

Lee P Dresser, E Wayne Massey, Eric E Johnson, Edward Bossen

Abstract

Two cases of ipecac myopathy, one with associated cardiomyopathy are reported. Both patients were young women with eating disorders who came to medical attention because of diffuse muscle weakness. Clinical and electromyographic data suggested ipecac myopathy and muscle biopsies confirmed this diagnosis. One patient had associated clinical and echocardiographic evidence of significant cardiomyopathy. The myopathy resolved and the echocardiogram returned to normal after discontinuing the use of ipecac.

(*J Neurol Neurosurg Psychiatry* 1992;55:560-562)

The abuse of syrup of ipecac by patients with major eating disorders has been shown to have toxic effects on skeletal and cardiac muscle.¹⁻⁷ These effects are most likely secondary to emetine, one of the major alkaloids in syrup of ipecac. Emetine is well known to produce myopathy in skeletal muscle,⁸ and is toxic to cardiac muscle,⁵ and may produce electrical disturbances and heart failure.⁴ Syrup of ipecac has been responsible for several deaths in patients with the binge-purge type eating pattern of bulimia.^{2,3} The use of syrup of ipecac by bulimic patients to stimulate emesis is now recognised to be widespread.⁶ It is important for physicians to be vigilant in seeking evidence of ipecac-induced myopathy and cardiomyopathy, especially in young women, because these disorders are potentially reversible. This report describes two patients with ipecac-induced myopathy and provides echocardiographic evidence of the reversibility of an associated cardiomyopathy.

Case reports*Patient 1*

This was a 26 year old female admitted for evaluation of progressive muscle weakness. At the time of presentation, she had a two month history of progressive difficulty climbing stairs, carrying a laundry basket, and holding her head up while seated at work. She admitted to mild myalgia and had noted mild atrophy of her thigh and arm musculature. She had occasional palpitations, increased sweating, and mild pedal oedema. She denied chest pain or dyspnoea on exertion. She had a history of asthma, mild hypertension, depression and

anorexia nervosa. At the time of her father's death, four years before evaluation, she had lost 18 kilograms, dropping from 61 kilograms to 43 kilograms. Since then, her weight had increased to 57 kilograms and remained stable (height 165 cm). For the six month period before her evaluation, she had ingested several 30 ml doses of syrup of ipecac (containing approximately 21 mgs of emetine) per week to induce emesis after eating. She claimed only occasional alcohol use.

Her general physical examination revealed a well nourished, young, white woman. Her resting heart rate was 104 with S3 and S4 heart sounds present. Lungs were clear. Ichthyosis was present on the extensor surface of her arms and legs. Her neurological examination was remarkable for diffuse mild extremity atrophy and moderate diffuse weakness, greater proximally. Her sensory examination was normal.

Laboratory evaluation revealed blood counts, serum electrolytes, LDH, SGOT, SGPT, and alkaline phosphatase to all be within normal limits. A rheumatoid factor and antinuclear antibody were negative. A serum creatinine kinase (CK) level was elevated, with a peak at 1027 units/l. An ECG showed sinus tachycardia with a prolonged QT interval and T-wave inversion in the lateral leads. An echocardiogram showed left ventricular dilatation and diffuse hypocontractility with an ejection fraction of 36.5% (see table). Electromyography showed low-amplitude, polyphasic units in proximal muscles, without increased spontaneous activity.

A left deltoid biopsy showed slight variation in fibre size without evidence of inflammation. ATPase and NADH stains showed targetoid changes in both type 1 and 2 fibres with

Divisions of Neurology and Cardiology, Department of Medicine, and the Department of Pathology, Duke University Medical Center, Durham, NC 27710, USA
L P Dresser
E W Massey
E E Johnson
E Bossen

Correspondence to: Dr Dresser, Division of Neurology, Duke University Medical Center, Box 2905, Durham, NC 27710, USA

Received 11 December 1990 and in final revised form 25 February 1992.
Accepted 2 March 1992

Table 1 Echocardiogram results (patient 1)

	Study 1	Study 2 (15 months after discontinuing ipecac)
LVIDd (short axis)	5.1 cm	4.6 cm
LVIDs (short axis)	4.2 cm	3.4 cm
EDV (apical view)	109.4 ml	120.5 ml
ESV (apical view)	69.5 ml	65.1 ml
EF	36.5%	46.0%
FS	17.6%	26.1%

Abbreviations: LVIDd (left ventricular internal dimension, diastole), LVIDs (left ventricular internal dimension, systole), EDV (end diastolic volume), ESV (end systolic volume), EF (ejection fraction), FS (fractional shortening).

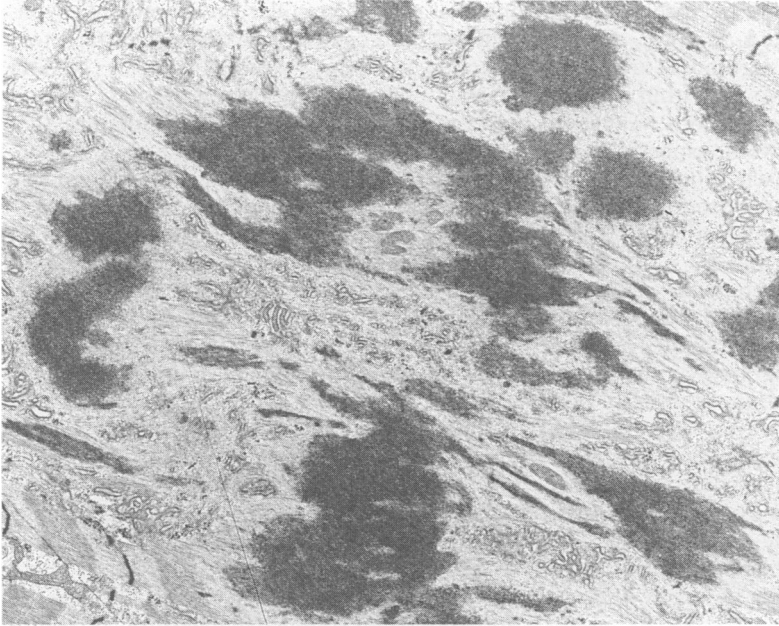


Figure 1 Electron micrograph shows electron-dense aggregates within fibres, which apparently correspond to degenerating Z-band material. (Magnification $\times 6,600$).

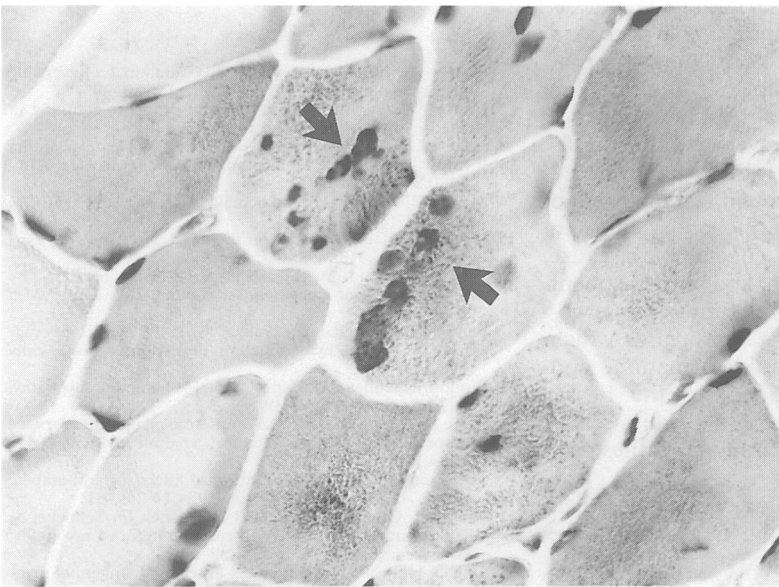


Figure 2 Trichrome stain of muscle biopsy from patient 2 shows aggregations of dense-staining bodies within fibres (arrows). (Magnification $\times 400$).

normal fibre distribution. Phosphorylase, myoadenylate deaminase, congo red, and lipid stains were normal. Electron microscopy showed extensive disorganisation of myofibrils with extreme smudging of Z-band material (fig 1). The patient stopped using ipecac and after three months her strength returned to near normal and she had no further complaints of palpitations or ankle oedema. A repeat echocardiogram performed 15 months after the first study demonstrated normal left ventricular function (see table).

Patient 2

This was a 29 year old, white female who was evaluated for muscle weakness during a psychiatric admission for an eating disorder. She had a several month history of progressive generalised weakness, exercise intolerance and amenorrhoea. For the six months before evaluation, she drank approximately one bottle of wine per day. During this period, she had a pattern of minimal food intake alternating with binge eating, always followed by ipecac-induced emesis. General physical examination showed a thin white female with dry skin. Heart and lungs examination were normal. Diffuse moderate muscle atrophy and weakness were present, more prominent proximally. Sensory examination was normal.

Laboratory evaluation showed blood counts, serum chemistries, thyroid function test, and serum CK to be within normal limits. An ECG showed nonspecific T-wave abnormalities. Electromyography showed long, polyphasic motor units with no increased insertional or spontaneous activity.

A biopsy of the left vastus lateralis muscle showed foci of fibres with increased numbers of internal nuclei with minimal atrophy. Trichrome staining showed focal groups of fibres with blurring of the myofibrillar network and aggregations of dense staining material (fig 2). These aggregates were seen by electron microscopy to represent Z-band streaming. NADH staining also showed loss of the myofibrillar network in many fibres, resulting in a targetoid appearance similar to that seen in patient 1. There was no evidence of inflammation, and phosphorylase and myoadenylate staining showed normal activity.

Discussion

Ipecac is isolated from the root of *Cephalis ipecacuanha*. It contains two major alkaloids, emetine and cephaeline. Cephaeline is primarily responsible for producing nausea and emesis, whereas emetine is more toxic to skeletal muscle and the heart.⁴ Ipecac has long been used by natives of Brazil to treat diarrhoea and has had widespread use in the treatment of amebiasis.⁴ It has also been used in aversive therapy for alcoholism⁹ and has been employed experimentally as an antineoplastic agent. In the USA, the only official use of ipecac is as an emetic to treat accidental poisoning. It is available without prescription only in syrup form. Through experiences with its use as a treatment for amebiasis, ipecac has been shown to cause a myopathy.¹⁰

In one study, nearly 5% of high school age females admitted to bulimic activity.⁵ They may resort to ipecac abuse if they cannot effectively induce mechanical emesis. It is estimated that there are one million bulimic women in America and that 35 000 abuse ipecac.^{6,7}

Ipecac myopathy should be considered in all young women with progressive proximal muscle weakness, atrophy, or stiffness, especially when there is any suggestion of an eating disorder. Both of our patients had dry skin,

and several other cases have been reported in which patients were noted to have dry or erythematous skin.¹⁻⁷ The serum CK level may be elevated, but it can also be within normal limits in the presence of significant weakness. The electromyogram shows nonspecific myopathic changes, but a muscle biopsy will help distinguish ipecac myopathy from inflammatory or alcohol-induced myopathy.¹⁻¹³ Nerve conduction velocity is normal.

If ipecac abuse is suspected, an evaluation for cardiomyopathy is warranted. Historical or physical evidence of cardiac failure may be present. The electrocardiogram may show resting tachycardia, prolongation of the QT and PR intervals, inverted T-waves, and ST segment abnormalities.⁴ As in the case of patient 1, significant depression of left ventricular function may be detected by echocardiogram or radionuclide tests. The serial echocardiograms performed on our patient demonstrated that ipecac cardiomyopathy is largely reversible.

The lethal dose of emetine has been estimated to be 10 to 25 mgs, or approximately 1.25 grams for an adult.¹⁰ Death is usually caused by ventricular arrhythmias or heart failure.⁴ Emetine is so slowly excreted from the body that doses may accumulate over time to approximate the lethal dose, even when emesis is stimulated.⁴ Syrup of ipecac is available in 30 ml doses, each dose containing approximately 21 mgs of emetine. It is therefore possible to accumulate a lethal amount of emetine within the body over several months when ipecac is used daily. It has been proposed that emetine inhibits protein synthesis and mitochondrial oxidative phosphorylation in skeletal muscle. These effects may cause decreased ATP formation and a subsequent increased release of calcium into the sarcoplasm that, in turn, activates proteases which cause Z-band lysis, granule formation, and myofilament disorganization.⁹ In the heart, emetine is thought to depress glycolysis and Krebs's cycle, as well as inhibit synthesis of contractile proteins.⁴

The microscopic pathological changes seen in the muscle biopsies from our patients are very similar to those reported in previous cases of ipecac myopathy^{1,7,9} and experimental emetine-induced myopathy in rats.⁸ Light microscopy reveals variation in fibre size,

internal nuclei, granular breakdown of myofibrils, and central core changes or targetoid changes in fibres with ATPase or NADH stains. Electron microscopy shows Z-band streaming and dense bodies.¹¹ Inflammatory infiltrates are not seen.¹ These findings are characteristic of ipecac myopathy, but are also seen in a variety of other conditions.¹² Although patient 2 was a heavy consumer of alcohol, her muscle biopsy was quite similar to that of patient 1 and demonstrated the characteristic targetoid changes and Z-band streaming of emetine myopathy. The characteristic type II fibre atrophy of chronic alcoholic myopathy¹³ was absent and therefore her myopathy was likely predominately due to emetine toxicity. The effects on cardiac muscle are not as well documented, but interstitial oedema, inflammation, and degenerative change of myocardial fibres have been reported.³

Therapy consists of discontinuing ipecac use and employing supportive measures. If cardiomyopathy is significant, inotropic and afterload reducing agents may be used. As shown in patient 1, both the cardiomyopathy and myopathy improved after discontinuing ipecac abuse. Electrical and pathological evidence of muscle recovery has also been demonstrated.^{9,12}

- 1 Mateer JE, Farrell BJ, Chou SM, Gutmann L. Reversible ipecac myopathy. *Arch Neurol* 1985;42:188-90.
- 2 Dawson JA, Yager J. A case of syrup of ipecac resulting in death. *J Amer Coll Health* 1986;34:280-2.
- 3 Adler AG, Walinsky P, Krall RA, Cho S. Death resulting from ipecac syrup poisoning. *J of Amer Med Assoc* 1980;243:1927-8.
- 4 Manno BR, Manno JE. Toxicology of ipecac: a review. *Clin Tox* 1977;10:221-42.
- 5 Isner JM. Effects of ipecac on the heart. (Letter). *New Engl J Med* 1986;313:1253-5.
- 6 Pope HG, Hudson JJ, Nixon RA, Herridge PL. The epidemiology of ipecac abuse. (Letter) *New Engl J Med* 1986;245-6.
- 7 Bennett HS, Spiro AJ, Pollock MA, Zueker P. Ipecac-induced myopathy simulating dermatomyositis. *Neurol* 1982;32:91-4.
- 8 Bindoff L, Cullen MJ. Experimental (-) emetine myopathy. *J Neurol Sciences* 1978;39:1-15.
- 9 Sugie H, Russin R, Verity AM. Emetine myopathy: two case reports with pathobiochemical analysis. *Muscle Nerve* 1984;7:54-9.
- 10 Anderson HH, Reed AC. Untoward affects of anti-ambeic drugs. *Am J Trop Med Hygiene* 1934;14:269-81.
- 11 Halbig L, Gutmann L, Goebel HH, Brick JF, Schochet S. Ultrastructural pathology in emetine-induced myopathy. *Acta Neuropath* 1988;75:577-82.
- 12 Goebel HH. Neuropathological aspects of congenital myopathies. *Prog Neuropath* 1980;6:231-48.
- 13 Hanid A, Slavin G, Mair W *et al.* Fibre type changes in straited muscles of alcoholics. *J Clin Pathol* 1981;34:991-7.