

Mucormycosis as a complication of LONG COVID: A case series

Divit Shah¹, Dhruv Talwar¹✉, Sunil Kumar², Sourya Acharya³, Ayush Dubey¹

To Cite:

Shah D, Talwar D, Kumar S, Acharya S, Dubey A. Mucormycosis as a complication of LONG COVID: A case series. *Medical Science*, 2021, 25(112), 1331-1337

Author Affiliation:

¹Post Graduate Resident, Department of Medicine, Jawaharlal Nehru Medical College, Datta Meghe Institute of Medical Sciences (Deemed to be University), Wardha, Maharashtra, India

²Professor, Department of Medicine, Jawaharlal Nehru Medical College, Datta Meghe Institute of Medical Sciences (Deemed to be University), Wardha, Maharashtra, India

³Professor and Head of Department, Department of Medicine, Jawaharlal Nehru Medical College, Datta Meghe Institute of Medical Sciences (Deemed to be University), Wardha, Maharashtra, India

✉Corresponding author

Post Graduate Resident, Department of Medicine, Jawaharlal Nehru Medical College, Datta Meghe Institute of Medical Sciences (Deemed to be University), Wardha, Maharashtra, India
Email: dhruv.talwar2395@gmail.com

Peer-Review History

Received: 03 May 2021

Reviewed & Revised: 04/May/2021 to 29/May/2021

Accepted: 30 May 2021

Published: June 2021

Peer-review Method

External peer-review was done through double-blind method.

ABSTRACT

Severe coronavirus disease (COVID-19) has a profound inflammatory phenomenon thus calling for management with high dose corticosteroids. This along with immunomodulation with the SARS-CoV2 has led to increase in opportunistic fungal infections. While aspergillosis associated with COVID-19 is a well documented association we report a case series of COVID-19 induced Mucormycosis in patients who had COVID-19 more than 3 months ago. The term used for increased inflammation for more than 3 months after COVID-19 is known as "LONG COVID" and is emerging as a entity of great concern in the recent times due to recognition of increased number of complications in patients who had earlier recovered from COVID-19. It is important to note that Diabetes Mellitus has been recognized as an important co-factor with COVID-19 in inducing mucormycosis infections. Concurrent use of glucocorticoid not only hampers the sugar control but also has immunosuppressant effect leading to predisposition to mucormycosis as an important post covid sequelae. High level of vigilance with immediate management is required to prevent adverse outcome of this serious long covid complication.

Keywords: Mucormycosis, Long covid, COVID-19

1. INTRODUCTION

Ever since its conception the COVID-19 pandemic has proven to be a problem of concern worldwide (Jain et al., 2020). While the treatment modalities for COVID-19 are still under trial, Glucocorticoids are an essential component of treatment (Talwar et al., 2021). However, glucocorticoids are a double edged sword as they do reduce the profound inflammation caused due to the cytokine storm of COVID-19 thus preventing fatal complications but it also causes immunosuppression and predisposed the patient to various secondary fungal and bacterial infections. Invasive aspergillosis leading to pulmonary involvement is a well documented complication of COVID-19 however; another emerging complication of great concern is mucormycosis.

"Long Covid" also known case chronic covid syndrome is a long term sequelae of COVID-19 which involves various organs of the body. There is persistent inflammation effecting the nervous system, respiratory system and



the cardiovascular system. A wide range of problems like myalgia, fatigue, anosmia, cognitive dysfunction and low grade fever might persist in Long Covid. It is compelling to note that though Long Covid is being reported post infection it has not been described post vaccination.

Long Covid is continued to be reported by all categories of COVID-19 infections i.e the mild, moderate and severe category thus complicating the understanding of its pathophysiology. As COVID-19 is a newly discovered disease the complications associated with Long Covid are still under research and are not clearly understood. Mucormycosis refers to any infection caused by the fungi of the order mucorales (Jain et al., 2011). Although seeming to be docile it may lead to fatal complications through its angioinvasion properties (Dronamraju et al., 2021). Rhino cerebral mucormycosis may present with sinusitis along with swelling of the eye (Rajeshwari et al., 2012).

In the few cases reported of Mucormycosis in COVID-19 most of the cases are reported during or within 10-14 days of COVID-19, however we report a case series focusing on the Mucormycosis associated with LONG Covid that is more than 3 months after contracting COVID-19. Thus, we report a case series of four patients reporting with symptoms which persisted even after 14 days of COVID-19 and ultimately developed mucormycosis as long covid sequelae.

2. CASE SERIES

CASE 1

A 45 year old male presented with the chief complaint of pain in the right eye and face since a week. Patient had history of COVID-19 infection four months ago when had a CT Severity Score of 21/25 with CORAD 6 and had received remdesavir, steroids along with other supportive measures. Patient had persistent bodyache and intermittent cough even after recovering from COVID-19. He had history of Diabetes Mellitus Type 2 since five years for which he was on oral hypoglycemics. There was no history of hypertension, bronchial asthma or any other chronic medical illness. On physical examination pulse was 74 beats per minute, blood pressure was 140/80 mm hg in right arm in supine position and spo2 was 95 on room air. On systemic examination chest was bilaterally clear, heart sounds were normal, patient was conscious and oriented and abdomen was soft and non tender with no organomegaly.

CT Paranasal Sinus was suggestive of rhino orbital mucormycosis and debridement was done and biopsy showed features of mucormycosis (figure 1 and 2). Lab investigations are mentioned in table 1. Liposomal amphotericin B was initiated. After 28 days of admission patient was discharged on oral posiconazole and is doing well on follow up.

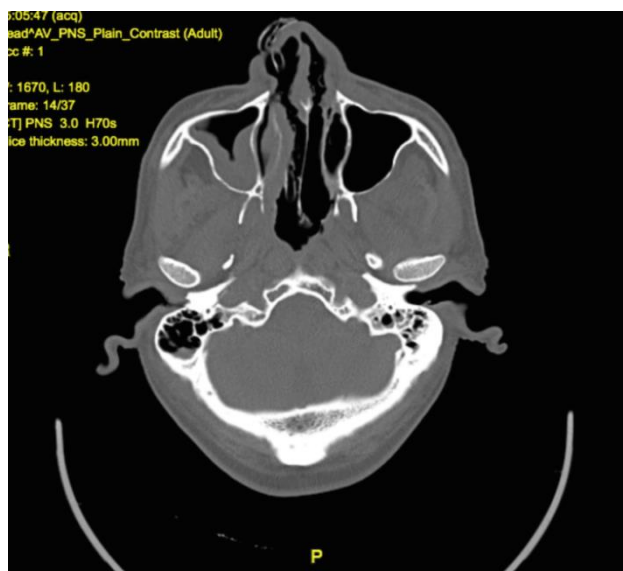


Figure 1 CT Paranasal Sinus showing features suggestive of right sided rhino-orbital mucormycosis

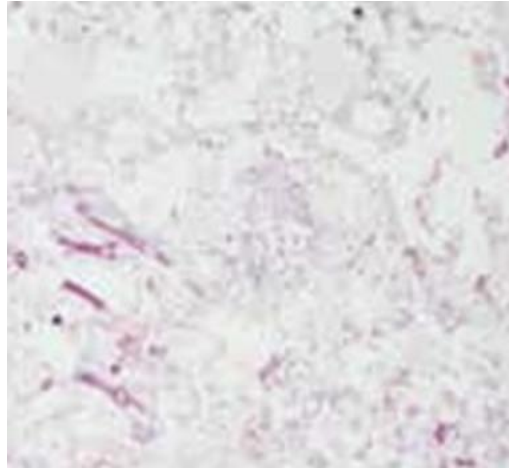


Figure 2 Biopsy showing features of mucormycosis

CASE 2

A 50 year old male presented with the chief complaint of pain in the right eye along with redness, swelling and ptosis with loss of sensation of face of right side. Patient had history of COVID-19 infection 3 months ago when he had a CT severity score of 19/25 and CORAD 6. There was no history of Diabetes Mellitus, Hypertension or any other chronic illness in the past. On examination pulse was 68/min, regular, blood pressure was 128/88 mm hg in right arm supine position and spo2 was 96 on room air. On systemic examination chest was bilateral clear on auscultation, heart sounds were normal, patient is conscious and oriented and abdomen was soft and non tender. Patient had severe chemosis in right eye, ptosis of right eye along with blackening under the right eye (figure 3) and there was right sided facial paralysis.

HRCT was suggestive of bilateral ground glass opacities (figure 4). Lab investigations are mentioned in table 1. Nasal swab was sent for culture which showed growth of mucor species (figure 5). Surgical Debridement was done. Patient was managed with liposomal amphotericin B and finally discharged after 25 days of admission on oral posiconazole.

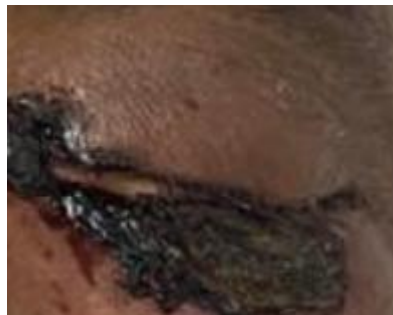

Figure 3 Showing ptosis of right eye

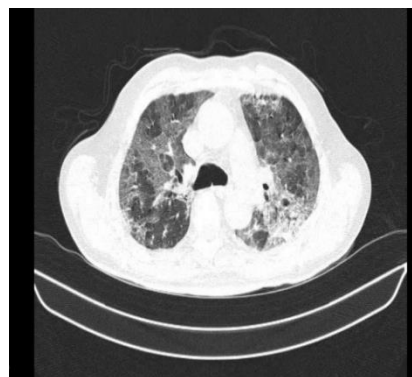

Figure 4 HRCT of case 2 showing bilateral ground glass opacity

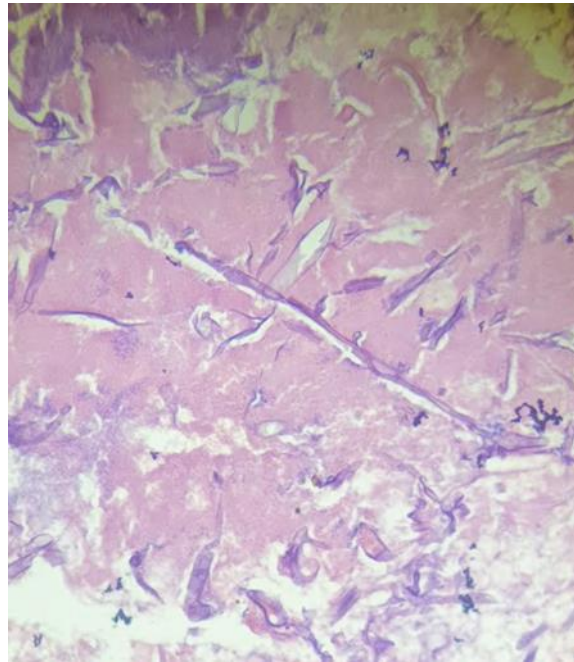


Figure 5 Showing growth of mucor species on culture

CASE 3

A 60 year old female presented with the chief complaint of pain in the right eye and face since a week and swelling of right cheek since 9 days which was gradual. Patient had history of COVID-19 infection five months ago when had a CT Severity Score of 18/25 with CORAD 6 and had received remdesavir, steroids along with other supportive measures. Patient had persistent bodyache and intermittent dry cough even after recovering from COVID-19. She had history of Diabetes Mellitus Type 2 since nine years for which she was on oral hypoglycemics, and on regular monitoring of blood sugar levels. There was no history of hypertension, bronchial asthma or any other chronic medical illness. On physical examination pulse was 86 beats per minute, blood pressure was 110/70 mm hg in right arm in supine position and spo2 was 93 on room air. On systemic examination chest was bilaterally clear, heart sounds were normal, patient was conscious and oriented and abdomen was soft and non tender with no organomegaly. CT was suggestive of right fronto maxillary sinusitis with adjacent sinus wall changes s/o fungal origin (Figure 6) and debridement was done and biopsy showed features of mucormycosis (figure 7). Lab investigations are mentioned in table 1. Liposomal amphotericin B was initiated. After 30 days of admission patient was discharged on oral posiconazole and supportive management and is doing well on follow up .

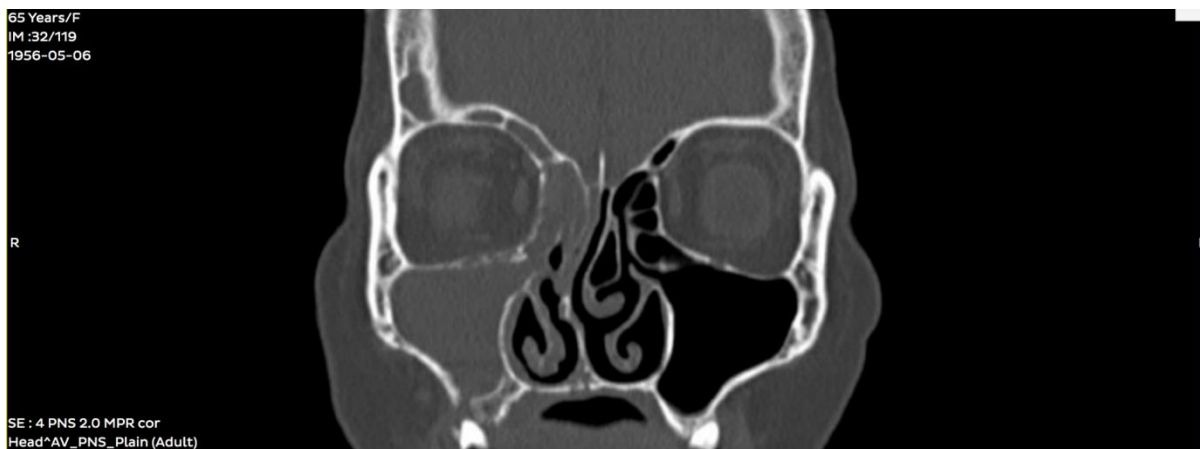

Figure 6 CT Paranasal Sinus showing features of muormycosis in Right Fronto Maxillary Sinus

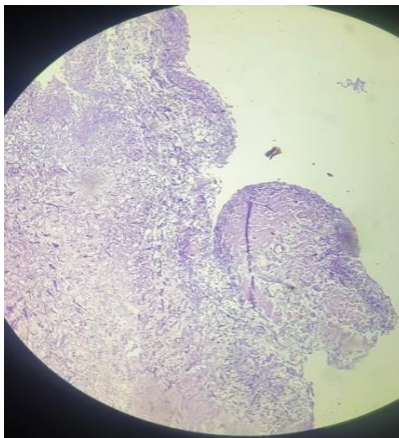


Figure 7 microscopy showing mucor species

CASE 4

A 65 year old male presented with the chief complaint of pain in and around left eye along with redness, swelling and partial loss of sensation of face of left side. Patient had history of COVID-19 infection 2 months ago when he had a CT severity score of 23/25 and CORAD 6. There was no history of Diabetes Mellitus, Hypertension or any other chronic illness in the past. On examination pulse was 91/min, regular, blood pressure was 118/78 mm hg in right arm supine position and spo2 was 97 on room air. On systemic examination chest was bilateral crepts on auscultation, heart sounds were normal jvp normal no pedal edema, patient is conscious and oriented and abdomen was soft and non tender. Patient had swelling around left eye and cheek. CT paranasal sinus was done suggestive of left frontomaxillary, ethmoid, sinusitis with inflammatory changes in premaxillary, retro maxillary and infratemporal spaces suggestive of fungal etiology (Figure 8). Lab investigations are mentioned in table 1. Surgical Debridement was done and biopsy was sent for analysis which showed features of mucormycosis. Patient was managed with liposomal amphotericin B and finally discharged after 35 days of admission on oral posiconazole and other supportive management

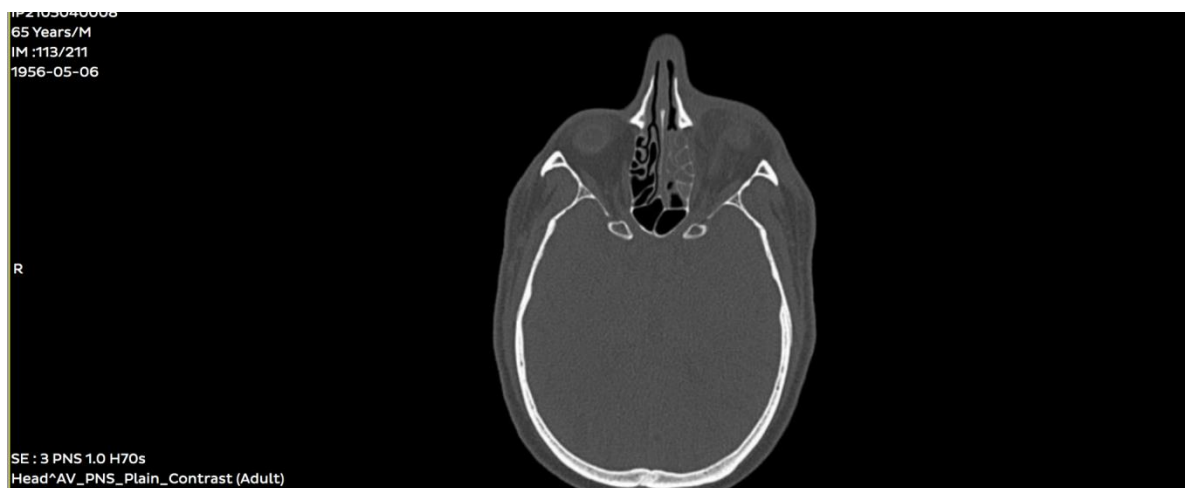


Figure 8 CT Paranasal Sinus showing features of Mucormycosis in case 4

3. DISCUSSION

COVID-19 has claimed more than 3 million lives worldwide and continued to cause devastation around the globe. In the absence of a sure shot cure, Glucocorticoids along with antiviral drugs like remdesavir play a pivotal role in the management of COVID-19 pneumonia. In contrast to costly antiviral drugs, glucocorticoids are readily available, inexpensive and highly effective in hypoxia induced by COVID-19. However, increased use of Glucocorticoids has led to emergence of opportunistic secondary fungal and bacterial infections in patients. Immunomodulatory drugs such as monoclonal antibodies against IL-6 like tocilizumab have further increased the risk of opportunistic infections in patients of COVID-19. It is important to point out that all three of the cases reported here have significant pulmonary involvement due to COVID-19 with respiratory distress while they were infected with COVID-19. They persisted to have symptoms like myalgia, low grade fever and cough even after recovery and reported with mucormycosis later on as a sequelae of long COVID.

Table 1 Showing Lab investigations of all cases

| Lab Parameter | Case 1 AGE-45 SEX-MALE | Case 2 AGE- 50 SEX-MALE | Case 3 AGE-60 SEX-FEMALE | Case 4 AGE-65 SEX-MALE |
|---------------------|--|--|--|---|
| CBC | Hb- 9.2gm/dl MCV- 86.2 fl Platelet count -2.7/dl WBC Count-19400/dl | Hb- 14gm/dl, MCV: 94.4fl, Platelet count-1.7/dl, WBC Count- 8700/dl | Hb- 10.1gm/dl, MCV- 83.1fl, Platelet count- 3.1/dl, WBC Count- 20100/dl | Hb- 12.2gm/dl, MCV- 89.9fl, Platelet count- 1.9/dl, WBC Count- 10400/dl |
| LFT | Total Protein-5.2gm/dl, Albumin- 2.2gm/dl, Globulin- 3.0gm/dl, Aspartate aminotransferase- 44 units/l , Alanine aminotransferase- 46 units/l, Alkaline phosphatase- 300 IU/l, Total Bilirubin :0.9mg/dl | Total Protein- 7.3gm/dl, Albumin- 3.5gm/dl, Globulin- 3.8gm/dl, Aspartate aminotransferase- 46units/l , Alanine aminotransferase- 30 units/l ,Alkaline phosphatase- 197 IU/l, Total Bilirubin : 0.9mg/dl | Total Protein- 5.1gm/dl, Albumin- 3.1gm/dl, Globulin-2.0gm/dl, Aspartate aminotransferase- 51units/l , Alanine aminotransferase- 49units/l, Alkaline phosphatase- 280 IU/l, Total Bilirubin- 1.2mg/dl, | Total protein- 7.8gm/dl, Albumin- 3.3gm/dl, Globulin- 4.5gm/dl, Aspartate aminotransferase-45 units/l, Alanine aminotransferase-38 units/l Alkaline phosphatase- 188 IU/l, Total Bilirubin- 0.8mg/dl, |
| KFT | Creatinine :0.7mg/dl, Urea- 47mg/dl, Sodium- 132mmol/l, Potassium- 4.3mmol/l | Creatinine: 0.5mg/dl, Urea- 51mg/dl, Sodium- 144mmol/l, Potassium- 5.2 mmol/l | Creatinine: 0.9mg/dl, Urea-34 mg/dl, Sodium- 133 mmol/l, Potassium-5.0 mmol/l | Creatinine: 1.2mg/dl, Urea- 58mg/dl, Sodium-141 mmol/l, Potassium- 4.7mmol/l |
| CRP | 9.0mg/l | 27.0mg/l | 13.mg/l | 22mg/l |
| D-Dimer | 1.40 | 1.08 | 1.30 | 1.05 |
| Serum Ferritin | 1360ng/ml | 1000ng/ml | 1430ng/ml | 1140ng/ml |
| HRCT Score CORAD | 21/25;CORADS 6 | 19/25;CORADS 6 | 18/25;CORADS 6 | 23/25;CORADS 6 |
| IL-6 | 19.5 | 12.5 | 24.0 | 15.0 |
| HBsAg | Negative | Negative | Negative | Negative |
| HCV | Negative | Negative | Negative | Negative |
| HIV | Negative | Negative | Negative | Negative |

Mucormycosis is a deadly disease under recognized with its association with COVID-19. Keeping the challenges of managing the ongoing pandemic in mind, it can be said that this association of COVID-19 with mucormycosis in its long covid phase has undergone ignorance and needs to be reported. The under recognition of mucormycosis in the long covid phase might be attributed to lack of suspicion by the treating physicians or due to the great difficulty encountered in isolating the causative fungi. Absence of biomarkers for mucormycosis is another contributing factor making mucormycosis the invisible layer in the ongoing difficult times of COVID-19 pandemic.

Diabetes Mellitus is increasingly associated with COVID-19 being an important comorbidity. It is also seen that patients with Diabetes Mellitus are at increased risk of renal dysfunction and mucormycosis. Thus multiple risk factors or comorbidities like diabetes mellitus along with COVID-19 infection lead to an increased duration of inflammation leading to the long covid phase. These patients when predisposed to glucocorticoids and immunomodulatory drugs like tocilizumab have immunosuppression leading to promotion of growth of moulds resulting in mucormycosis. Thus use of glucocorticoids should be avoided in mild to moderate cases of COVID-19 as their indiscriminate use can lead to dangerous outcomes. Also in absence of clear indications use of immunomodulatory drugs like tocilizumab should be avoided. All of our cases were started on liposomal amphotericin B and responded well to therapy.

In systematic review conducted in India it was found that diabetes and immunosuppression was the biggest risk factor for Mucormycosis and middle age was more likely to develop mucormycosis (Garg et al., 2021). However in our case series we have found that even in absence of risk factors like diabetes mellitus even young patients might develop mucormycosis as a complication of Long Covid syndrome. While many reports have focused on post covid mucormycosis this is the first case series to highlight mucormycosis as part of Long Covid Syndrome.

4. CONCLUSION

Thus we conclude that the physicians on the front line managing COVID-19 should be well aware of the long term complications of COVID-19 and the long covid sequelae. A high degree of suspicion along with prompt diagnosis and management is required in mucormycosis to prevent mortality. Also the physicians should be warned against indiscriminate use of glucocorticoids and immunomodulatory drugs in COVID-19 as they may lead to complications later in the course of the disease.

Acknowledgement

We thank all the participants who have contributed in this Study.

Conflict of interest

The Authors have no conflicts of interest that are directly relevant to the content of this clinic-pathological case

Financial Resources

There are no financial resources to fund this study

Informed Consent

Informed Consent was obtained from the patient.

Author's Contribution

All the authors contributed equally to the case report.

Data and materials availability

All data associated with this study are present in the paper.

REFERENCES AND NOTES

1. Dronamraju S, Nimkar S, Damke S, Agrawal S, Kumar S. Angioinvasion of anterior cerebral artery by rhinocerebralmucormycosis leading to intraparenchymal hemorrhage: A rare case report. *Medical Science* 2021; 25(111), 1088-1091
2. Garg D, Muthu V, Sehgal IS, Ramachandran R, Kaur H, Bhalla A, Puri GD, Chakrabarti A, Agarwal R. Coronavirus Disease (Covid-19) Associated Mucormycosis (CAM): Case Report and Systematic Review of Literature. *Mycopathologia* 2021; 186(2):289-298
3. Jain A, Talwar D, Kumar S. Spectrum of Respiratory Involvement in COVID 19 Era; An Overview. *Indian J of Forensic Med & Toxicol* 2020; 14(4), 6593-6599.
4. Jain S, Kumar S, Kaushal A. Rhinocerebralmucormycosis with isolated sixth nerve palsy in an immunocompetent patient. *Med J Malaysia* 2011; 66(4):376-8.
5. Rajeshwari A, Gangadhara Somayaji K. S. Rhinocerebralmucormycosis: an Unusual Presentation. *Am J Med Sci* 2012; 2(1): 16-19.
6. Talwar D, Kumar S, Madaan S, Khanna S, Annadatha A. Intractable Singultus: Atypical presentation of COVID 19. *Medical Science* 2021; 25(111), 1183-1187