

RESEARCH ARTICLE

Relationships Between Clinical Behavior of Laryngeal Squamous Cell Carcinomas and Expression of VEGF, MMP-9 and E-Cadherin

Onder Akdeniz¹, Davut Akduman^{1*}, Mehmet Haksever¹, Haluk Ozkarakas², Bahar Müezzinoğlu³

Abstract

The biological mechanisms of cancer and associations with behavior of tumours need to be studied to understand progression and determine appropriate treatments. Here we investigated expression of VEGF, MMP-9 and E-cadherin in laryngeal SCCs and their relations with clinical behavior. This prospective study was based on 38 surgical specimens from patients with primary laryngeal SCC and data recorded in their cards. Expression of the three factors in tumor tissue was examined using immunohistochemistry and correlations with clinical parameters of primary tumors, regional lymph node metastases, stage of disease, histopathologic differentiation, and vascular/cartilage invasion were investigated. Regarding the cases with positive MMP-9 expression, the difference between well and moderately/poorly differentiated tumors was statistically significant. However, differences between early stage (stage I and II) and late-stage (stage III and IV) tumours, and between positive and negative for pLN metastasis were not. No significant relationship between positive VEGF and tumor differentiation or stage was apparent, but E-cadherin levels significantly differed between well and moderately/poorly differentiated tumours and with the presence of pLN metastasis. E-cadherin staining did not vary between MMP-9 positive and negative cases. In conclusion, MMP-9 may be a negative predictor of differentiation in laryngeal SCC, while E-cadherin is a predictor of differentiation and nodal metastases. Even if the difference between VEGF expression and tumor stage was not statistically significant, it seems that there exists some relationship, which might be clarified with a greater number of cases.

Keywords: Laryngeal squamous cell carcinoma - MMP-9 - VEGF - E-cadherin - metastases - prognosis

Asian Pac J Cancer Prev, 14 (9), 5301-5310

Introduction

The incidence rate of larynx cancer is 3.4 per 100000 men and women per year based on cases diagnosed in 2005-2009 from 18 SEER geographic areas. The death rate is 1.2 per 100000 men and women per year in US (Howlader et al., 2011).

The prognostic factors of a cancer are related to the localization, stage and grade (degree of differentiation) of primary tumor, regional and distant metastasis and capsular invasion (Jakobsson et al., 1973; 1975). The biological mechanisms of local development and nodal invasion of cancer are still unexplained (Pilch et al., 1996). Specific interactions between tumor cells and normal cells occur with a wide spectrum of adhesion molecules which are located on the cellular surface (Behrens et al., 1989).

The tumor with a size greater than 1-2 mm in diameter, require the vascular system to be fed. Angiogenesis is a process, which requires the formation of a new basement

membrane with the basement membrane damage, migration of endothelial cells and formation of new blood vessels (Roomi et al., 2009). It is now generally accepted that tumor angiogenesis is important both for the growth of a primary neoplastic tumor and also for the development of metastasis (Folkman, 1990). Vascular endothelial growth factor (VEGF) family are polypeptide growth factors those have mitogenic activity specific for endothelial cells. They have the functions to enhance existent ability of endothelial cell, to promote mitosis and the ability to increase chemotaxis and vascular permeability (Zhongliang et al., 2002). VEGF induces the proliferation, differentiation, and migration of vascular endothelial cells; increases the permeability of the capillaries; and enhances the survival of endothelial cells by preventing their apoptosis (Ferrara and Davis-Smyth, 1997; Gupta et al., 1999; Kyzas et al., 2004). It is suggested that VEGF plays an important role in lymph node metastasis through induction of angiogenesis in primary nasopharyngeal

¹Department of Otorhinolaryngology, Bursa SevketYılmaz Training and Research Hospital, Bursa, ²Department of Otorhinolaryngology, Acıbadem University, KadıköyAcıbadem Hospital, Istanbul, ³Department of Pathology, Kocaeli University, School of Medicine, Kocaeli, Turkey *For correspondence: dr.akduman@gmail.com

carcinomas (Wakisaka et al., 1999).

Matrix metalloprotease (MMP)-9 is a part of a group of enzymes that degrades type IV collagen in the basal membrane and are involved in the invasion mechanism (Klein et al., 2011). An increase in immunoreactivity of such enzymes has been correlated with a greater risk of metastases in many cancer types including breast cancer, prostate cancer, brain cancer and melanoma (Talvensaari-Mattila and Turpeenniemi-Hujanen, 2005; Roomi et al., 2009; Zhao et al., 2009).

The cadherins (named for “calcium-dependent adhesion”) are Ca²⁺ dependent cell-cell adhesion in vertebrate tissues. Cadherin superfamily is composed by *i*) classical cadherins, the major components of cell-cell adhesive junctions; *ii*) non-classical cadherins, which include desmosomal cadherins; and *iii*) protocadherins, which are implicated in neuronal plasticity (Cavallaro et al., 2004; Gerrow and El-Husseini, 2006). E- and P-cadherins belong to the subfamily of classical/type I cadherins that comprises only four members: the non-neuronal epithelial (E-) and placental (P-) cadherins, and the neuronal neural (N-) and retinal (R-) cadherins (Nollet et al., 2000). Cadherins have been recognized as tumor suppressor genes/proteins (Mareel et al., 2009), since their loss of expression, abnormal function, or both, leads to an increased ability of cells to invade neighbouring tissues, as verified in cancer (Bex and Van Roy, 2001). A reduction in cadherin expression, as well as functional alterations, such as tyrosine phosphorylation, decrease cell-cell adhesion and are associated with tumor progression (Soler et al., 1997). E-cadherin is a transmembrane glycoprotein, involved in cell-cell adhesion and epithelial mesenchymal transition (Nijkamp et al., 2011).

The expression of VEGF, MMPs and E-cadherin in cancer cells is pointed out to be changed during the steps of lymph node metastasis (Wakisaka et al., 1999; Talvensaari-Mattila and Turpeenniemi-Hujanen, 2005; Roomi et al., 2009; Zhao et al., 2009; Klein et al., 2011).

While the research on the expression of adhesion molecules in head and neck cancers is still in progress, the goal of present study was to investigate the expression adhesion molecules and the relationship with the clinical behavior of tumor. We evaluated the immunohistochemical expressions of VEGF, MMP-9 and E-cadherin in laryngeal squamous cell carcinoma (SCC), and their correlation with the behavior of tumor. As well the work carried out to contribute the molecular mechanisms of cancer behavior.

Materials and Methods

The study was performed prospectively, and IRB approval was provided by ethic committee of study center. Thirty eight patients with primary laryngeal SCC included the study. The diagnosis of carcinoma based on the pathologic report of direct laryngoscopy which performed preoperatively. Each patient had a pathologically confirmed SCC report. None of patients had distant metastases, and none of patients had previously received preoperative chemotherapy or radiotherapy. All of the patients were treated with surgery as total or partial laryngectomy. Bilateral or unilateral, radical or modified

types of radical neck dissections were performed to the patients, depending on the status of neck with preoperative physical examination. Surgical specimens were processed for routine histopathological analysis. Also, another pathologic specimen was obtained from the surgical specimen including the portion of cancer tissues and healthy mucosa near the advancing edge of the cancer, avoiding its necrotic center to evaluate the expressions of VEGF, MMPs and E-cadherin. After excision, the tissues were immediately snap-frozen and stored in liquid nitrogen until use.

The clinical and pathological data recorded to patient’s charts. The details of operations performed to the patients are shown in Table 1.

Laryngeal cancer was staged according to the UICC TNM classification, 5th edition (Hermanek and Sobin, 1997). The mode of cancer invasion (MI) was histologically classified as described previously by Jakopsson et al. (1973).

The patients allotted to two groups regarding to the pathologic matastases of lymph nodes (pN). The association between the pN and clinical parameters as tumor (T), node (N), stage and the localization (side) of the lesion investigated. Also the relationship between the pN (+/-) and histopathologic parameters as differentiation, vascular and cartilage invasion evaluated.

Histopathologically, SCC of larynx is divided well differentiated (grade 1), moderately differentiated (grade 2), and poorly differentiated (grade 3) disease according to the degree of differentiation, cellular pleomorphism, and mitotic activity. Regarding to the histopathology the specimens classified in two groups (well and moderately/ poorly differentiated) like two-tier grading to make comparisons easier.

The tumoral invasion of the cartilage is based on the destruction of thyroid and/or cricoid cartilage at the level of perichondrium. Also vascular and soft tissue invasion of the tumor studied for each case.

Immunohistochemistry

The specimens of paraffin-embedded tissue blocks were cut into 5-µm sections and attached to poly-L-lysine coated glass slides. Immunohistochemical assays were performed using the biotin streptavidin method. Sections were dewaxed, hydrated and treated using a high temperature antigen retrieval technique (microwave

Table 1. The Distribution of Laryngectomy Types and Neck Dissection Operations to 38 Patients

		n (%)
Laryngectomy	Total Laryngectomy	14 (36.85)
	Supraglottic Laryngectomy	19 (50.00)
	Supracricoid Laryngectomy	2 (5.26)
	Near-total Laryngectomy	2 (5.26)
	Laryngopharyngectomy	1 (2.63)
Neck Dissection	Bilateral RND	1 (2.63)
	Unilateral RND	2 (5.26)
	Bilateral FND	14 (36.85)
	Unilateral FND	3 (7.89)
	RND+FND	15 (39.48)
	No neck dissection	3 (7.89)

*RND: Radical Neck Dissection, FND: Functional Neck Dissection

heating for VEGF, and autoclave heating for MMP-9, E-cadherin). Following deparaffinization the sections were treated respectively with xylol, absolute alcohol, and 96% alcohol for 20 each minute. Washed with tap water and included in Tris-HCl (Merck, Germany) pH 7.6 buffer solution. The endogenous peroxide was blocked with 0.3% hydrogen peroxide for 20 min. Washed with distilled water and included again in Tris-HCl solution. This process was followed by microwave (750W) treatment for 4×10 min in citrate buffer (pH=6.0) to retrieve the antigens present. Left in a humid atmosphere at room temperature for 20 min. Washed with distilled water and included again in Tris-HCl solution. After washing the slides, sections were incubated with primary antibodies. The incubation for MMP-9 (Neo Marker, USA, California predilue, Clone VII C2) and VEGF (Takara, Japan 1:200) at room temperature for 60 min, and E-cadherin (Takara, Japan 1:50) at +4°C for 1 night. After the incubation the specimens washed with distilled water and Tris-HCl solution and incubated with 10% biotinized goat anti-polyvalent serum for 20 min to eliminate non-specific staining. Sections were incubated with streptavidin peroxides for 20 min, and washed with distilled water and Tris-HCl solution. Biotinylated anti-mouse antibody for 30 min and treated with streptavidin reagent for 30 min. In all cases, 3-Amino-9-Ethylcarbozole was used as a chromogen for 20 min. The slides were then counterstained with Mayer's haematoxylin for 3 min, and covered with glycerin gel.

The slides were viewed randomly, without clinical data under the light microscope by the same trained pathologist. Although the results of immunohistochemical analysis are graded semiquantitatively, the results of MMP-9 were specified as *positive* and *negative* for statistical calculations. *Positive* result is defined as MMP-9 expression or staining level in the epithelium is higher than normal epithelium, and *negative* result is defined as the same or less than normal epithelium. VEGF staining was classified into two groups: negative staining, as normal epithelia and positive staining as in cancer cell (intracytoplasmic granular staining pattern). The staining for E-cadherin was predominantly membranous with some cytoplasmic staining. A staining score was given based on the percentage of cells stained (0-100%). A score less than 30% accepted as low staining pattern (+), a score between 31-60% as decreased staining pattern (++), and a score more than 61% as increased staining pattern (+++).

The expression indexes of VEGF, MMP-9 and E-cadherin laryngeal SCC, compared with the clinical parameters (primary tumor-T, the involvement of regional lymph nodes-N, the stage and localization of the tumor). Also the relationship between the pN (+/-) and histopathologic parameters as differentiation, vascular and cartilage invasion evaluated.

Statistical analysis

The correlation between the clinicopathologic parameters and the expressions of VEGF, MMP-9 and E-cadherin were evaluated using linear chi-square (X²) test. A p value less than 0.05 was considered to be significant in statistical analyses. All statistical analyses

were conducted with SPSS-6.1 (Statistical Package for Social Sciences, SPSS Inc., Chicago, IL, USA).

Results

The study included 38 patients with larynx SCC. Each specimen allocated in two parts, one for routine histopathological analysis and the other for the expressions of VEGF, MMP-9 and E-cadherin. There were 36 males and 2 females with a median age of 55 years (range: 48-73 years). All of the patients treated with laryngectomy along with neck dissection(s). The distribution of operations to the patients is shown in Table 1.

While 18 (47.37%) patients had clinical LN (+) in the preoperative physical examination, the histopathologic evaluation revealed the regional lymph node metastases (pLN) in 15 patients (39.47%).

Clinical parameters evaluated in terms of TNM classification, and their association with the neck involvement. There was statistically significant difference between T and N stage (p<0.05), as T stage of the tumor increased, the stage of neck involvement showed statistically increment as a matter of course. The pathologic neck involvement rates for stage I-IV were 0%, 6.67%, 40%, and 87.5% respectively (Table 2).

Histopathological evaluation revealed that as the differentiation of tumor decreases, a tendency of increased lymph node metastases is observed. Involvement of lymph nodes detected in 21.05% for well differentiated, 64.29% for moderately differentiated, and 40% for poorly differentiated tumors. Of the 5 cases that had cartilage invasion, 2 cases (40%) had regional lymph node

Table 2. The Relationship between Clinical and Histological Parameters and Regional Lymph Node Metastasis.

Parameter	pN				Total (n=38)
	(n=15)		(n=23)		
	(n=15)		(n=23)		n (100%)
	n	(%)	n	(%)	
Primary Tumor (T)**					
1	2	(5.26)	0	(0)	2
2	16	(42.1)	3	(18.75)	13 (81.25)
3	9	(23.68)	5	(55.55)	4 (44.45)
4	11	(28.94)	7	(63.64)	4 (36.36)
Clinical Regional Lymph Node**					
0	20	(52.63)	2	(10)	18 (90)
1	6	(15.79)	2	(33.33)	4 (66.67)
2	10	(26.32)	9	(90)	1 (10)
3	2	(5.26)	2	(100)	0 (0)
Stage**					
I	2	(5.26)	0	(0)	2 (100)
II	15	(39.47)	1	(6.67)	14 (93.33)
III	5	(13.16)	2	(40)	3 (60)
IV	16	(42.1)	14	(87.5)	2 (12.5)
Localization					
Glottic	1	(2.63)	0	(0)	1 (100)
Supraglottic	22	(57.89)	6	(27.27)	16 (72.73)
Transglottic	15	(39.47)	15	(100)	0 (0)
Histologic Differentiation					
Well	19	(50)	4	(21.05)	15 (78.95)
Moderately	14	(36.84)	9	(64.29)	5 (35.71)
Poorly	5	(13.16)	2	(40)	3 (60)
Histologic invasion					
Cartilage	5	(13.16)	2	(40)	3 (60)
Vascular	2	(5.26)	0	(0)	2 (100)

*n: Number of patients and pN: Pathological Regional Lymph Node; **p<0.05

metastases. However, 2 patients with vascular invasion did not have lymph node involvement in histopathological evaluations. The other features related to neck lymph node involvement are also summarised in Table 2.

All layers of the normal squamous epithelium and the epithelium of the upper respiratory tract showed diffuse nuclear staining according to the immunohistochemical evaluation of MMP-9 (Figure 1a). MMP-9 was positive in germinal center cells of lymphoid follicles and stroma. MMP-9 also showed nuclear staining in tumor cells. The intensity of staining in the tumor islands was generally similar, but a little more intense staining of tumor cells observed in the periphery of the cell groups in some cases (Figure 1b).

The semiquantitative analysis of specimens for the expression of MMP-9 revealed that, 16 cases (42.11%) stained diffusely (+) and 22 (57.89%) cases stained in weak or lower (-) levels.

The relationship between MMP-9 expression and tumor differentiation revealed that, 26.32% (5/19) of well-differentiated tumors, and 57.89% (11/19) of moderately/poorly differentiated tumors were positive for MMP-9 expression. The difference between the two groups was statistically significant (p=0.048, p<0.05) (Table 3).

The investigation of the relationship between MMP-9 expression and pathologic LN metastasis revealed that, 46.67% (7/15) of metastatic cases, and 39.13% (9/23) of non-metastatic cases stained positive for MMP-9. Despite the detection of higher rate of MMP-9 positive staining in the metastatic cases that was not statistically significant (p=0.645, p>0.05) (Table 3).

The evaluation of MMP-9 staining levels and tumor stage revealed that, early stage (stage I) tumors and

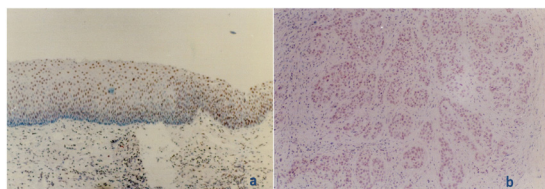


Figure 1. The Staining of Normal Epithelial Tissue. a) MMP-9 and b) Positive Staining for MMP-9. (Original Magnification X100)

Table 3. The Relationship between the MMP-9 Expression and Tumor Differentiation, Lymphatic Metastasis, Tumor Stage

Parameter	n (%)	MMP-9 Expression		Total (n=38)
		(+) n (%)	(-) n (%)	
Differentiation**				
Well	19 (50)	5 (26.32)	14 (73.68)	19
Moderately	14 (36.84)	8 (57.14)	6 (42.86)	14
Poorly	5 (13.16)	3 (60)	2 (40)	5
pN***				
(+)	15 (39.48)	7 (46.67)	8 (53.33)	15
(-)	23 (60.52)	9 (39.13)	14 (60.87)	23
Stage***				
I	2 (5.26)	1 (50)	1 (50)	2
II	15 (39.47)	6 (40)	9 (60)	15
III	5 (13.16)	2 (40)	3 (60)	5
IV	16 (42.1)	7 (43.75)	9 (56.25)	16

*pN: Pathological Regional Lymph Node; n: Number of all patients; N: number of patients in the subgroup; MMP: Matrix metalloprotease; **p<0.05; ***p>0.05

late-stage (stage III and IV) tumors stained positive in 41.18% and 42.86% respectively. The difference was not statistically significant (p=0.9, p>0.05) (Table 3).

VEGF was negative in normal squamous and respiratory epithelium, but the ductal epithelial cells, stromal cells and vascular endothelium stained positive focally. The positive staining of tumor cells was in the style of granular cytoplasmic staining. Of the 19 cases with (+) VEGF Expression, diffuse positive staining observed in 2 cases, and a small number of common focal positivity observed in 17 cases (Figure 2).

The expression of VEGF was (+) in 52.63% of well-differentiated, and 60% of moderately/poorly differentiated tumors. The relationship between VEGF expression and tumor differentiation was not statistically significant (p=0.2, p>0.05) (Table 4).

The relationship between VEGF and cervical metastases evaluated, and a highly positive (+) staining pattern observed in 2 of the 5 cases with metastasis. Statistical analysis could not be made because the number of cases was insufficient.

The relationship between VEGF expression and tumor stage revealed that, the rate of the patients with (+) VEGF expression in early stage (stage I and II) tumors was 43.75%, and it was 66.67% in late-stage (stage III and IV) tumors. The difference was not statistically significant (p=0.17, p>0.05) (Table 4).

E-cadherin showed cytoplasmic staining in normal squamous and respiratory epithelium with respect to the immunohistochemical staining (Figure 3a). The basal layer of squamous epithelium stained weaker than the other layers. Squamous cell carcinoma tumor cells showed cytoplasmic staining. In general, the more intense staining pattern observed in the middle of the tumor cell groups, whereas weaker staining observed in peripheral areas and deeply invasive tumor cells (Figure 3b-d). (+), (++) , (+++)

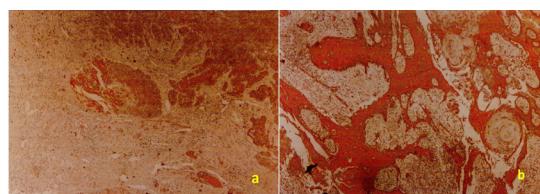


Figure 2. a) Positive Staining (+) for VEGF and b) Diffuse Staining (++) for VEGF. Original magnification X40

Table 4. The Relationship of VEGF Expression According to Differentiation and Stage of Tumor

Parameter	n (%)	VEGF Expression		Total (n=34)
		(+) n (%)	(-) n (%)	
Differentiation**				
Well	19 (55.88)	10 (52.63)	9 (47.37)	19
Moderately	11 (32.35)	8 (72.73)	3 (27.27)	11
Poorly	4 (11.76)	1 (25)	3 (75)	4
Stage**				
I	2 (5.88)	1 (50)	1 (50)	2
II	14 (41.17)	6 (42.86)	8 (57.14)	14
III	5 (14.71)	4 (80)	1 (20)	5
IV	13 (38.24)	8 (61.54)	5 (38.46)	13

*VEGF: Vascular endothelial growth factor; **p>0.05

staining patterns for E-cadherin were 51.43%, 22.86%, and 25.71% respectively.

E-cadherin staining patterns with respect to the differentiation of tumor were studied. Well-differentiated tumors showed (+), (++) and (+++) staining patterns in 38.89%, 38.89% and 22.22% respectively. Moderately/poorly differentiated tumors showed (+), (++) and (+++) staining patterns in 64.71%, 5.88% and 29.41% respectively. The difference was statistically significant ($p < 0.05$) (Table 5).

The relationship between E-cadherin staining level and lymphatic metastasis examined. In the presence of pLN metastasis, (+), (++) and (+++) E-cadherin levels were in 69.23%, 0% and 30.77% respectively. In patients without pLN metastasis (+), (++) and (+++) E-cadherin levels were 40.91%, 36.36% and 22.73% respectively. The difference was statistically significant ($p = 0.045$, $p < 0.05$) (Table 5).

The relationship between E-cadherin staining level and tumor stage studied. In early stage (stage I and II) tumors; (+), (++) and (+++) E-cadherin levels were 50%, 25% and 25% respectively. The rates of E-cadherin staining levels in late-stage (stage III and IV) tumors were 52.63%, 21.05% and 26.32%, respectively. There was no statistically significant difference ($p = 0.4$, $p > 0.05$) (Table 5).

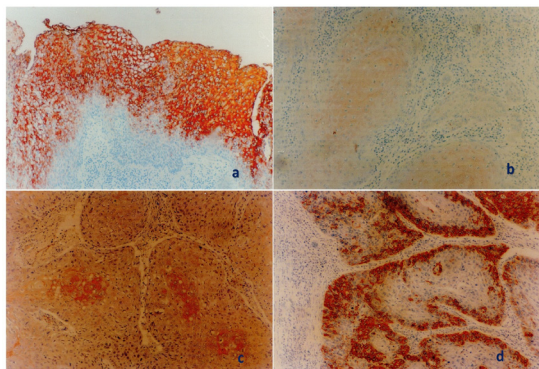


Figure 3. a) The Staining of Normal Epithelial Tissue for E-cadherin; b) The Staining of Normal Epithelial Tissue Negatively for E-cadherin; c) (+) Staining for E-cadherin; and d) (++) Staining for E-cadherin. Original magnification $\times 100$

Table 5. The Relationship of E-cadherin Expression According to Differentiation, Lymphatic Metastasis and Stage of Tumor

Parameter	E-cadherin Expression				Total (n=35)
		(n=18)	(n=8)	(n=9)	
	n (%)	(+) n (%)	(++) n (%)	(+++) n (%)	n (100%)
Differentiation**					
Well	18 (51.43)	7 (38.89)	7 (38.89)	4 (22.22)	18
Moderately	13 (37.14)	9 (69.23)	0 (0)	4 (30.77)	13
Poorly	4 (11.43)	2 (50)	1 (25)	1 (25)	4
pN**					
Positive	13 (37.15)	9 (69.23)	0 (0)	4 (30.77)	13
Negative	22 (62.85)	9 (40.91)	8 (36.36)	5 (22.73)	22
Stage***					
I	2 (5.72)	1 (50)	1 (50)	0 (0)	2
II	14 (40)	7 (50)	3 (21.43)	4 (28.57)	14
III	5 (14.29)	1 (20)	1 (20)	3 (60)	5
IV	2 (5.72)	9 (64.28)	3 (21.43)	2 (14.29)	14

*LN: LymphNode. pN: Pathological Regional Lymph Node; ** $p < 0.05$; *** $p > 0.05$

Table 6. The Relationship Between the Expressions of E-cadherin and MMP-9

E-cadherin Expression	MMP-9 Expression		Total (n=34)	
	(+)	(-)		
	n (%)	n (%)	n (100%)	
(+)	17 (50)	9 (52.94)	8 (47.06)	17
(++)**	8 (23.53)	2 (25)	6 (75)	8
(+++)	9 (26.47)	3 (33.33)	6 (66.67)	9
Total	14 (41.17)	20 (58.83)	34	

*MMP: Matrix metalloprotease; ** $p > 0.05$

Immunohistochemical staining of MMP-9 and E-cadherin were compared. The rates of E-cadherin staining levels in MMP-9 positive cases were 52.94%, 25%, and 33.33% respectively. The rates of E-cadherin staining levels in MMP-9 negative cases were 47.06%, 75%, and 66.67% respectively. There was no statistically significant relationship between the groups ($p = 0.2$, $p > 0.05$) (Table 6).

Discussion

Laryngeal cancer plays an important place in the overall body and head and neck cancers. The clinical course of patients with laryngeal cancer diagnosis depends on parameters such as, age, gender, nutritional status and tumor characteristics (stage, localisation, histological pattern, nuclear grade). Well known prognostic factors are the increase in tumor size, lymph node metastasis, and the presence of capsular invasion (Stell, 1990).

TNM classification allows you to determine the extensiveness of cancer, and an objective assessment for patient groups. TNM staging is insufficient to show the prognosis of tumor, and N stage is a more prognostic indicator than T stage (Haksever et al., 2012). In fact the most important prognostic indicator in laryngeal cancer is the presence or absence of metastasis in cervical lymph nodes. The comparison between preoperative physical examination findings and postoperative microscopic examination of specimen may not correlate in terms of lymph node metastasis (Jakobsson, 1975). In our study, cLN(+) was detected in 18 (47.3%) patients, and histological lymph node metastasis were detected in 15 (39.4%) patients. Pathological lymph node (+) positivity is an important determinant of the decision of postoperative radiotherapy. Pathologic lymph node positivity is also a significant predictor for patients' survival.

Supraglottic tumors cause early cervical lymph node involvement, because of the lymphatic density of this region, anatomical structure of epiglottis and abundance of lymphatic nature of preepiglottic space. In our study, pLN positivity detected in 27.27% (6/22) of supraglottic tumors, and 100% (15/15) of transglottic tumors. None of glottic tumors had pLN positivity. When the histopathology, one of the most important parameters of the prognostic factors of tumor is taken into account; the rates of pLN positivity for well, and moderately/poorly differentiated tumors in our study were half-and-half. The lymphatic metastasis rates with regard to differentiation of tumor; well, and moderately/poorly differentiated tumors were 21.09%, 57.89% respectively. Of the five

cases with cartilage invasion, 2 cases had histologically positive LN, and two cases with vascular invasion did not have LN metastasis.

Crissman and Zarbo (1990) reported that the histological evaluation criteria (the degree of keratinization, nuclear grade, mitotic index, inflammatory response, desmoplastic response, pattern of invasion, vascular invasion) were very useful in demonstrating the prognosis of cancer. By contrast the complexity of the method makes it difficult for the applicability.

The immunohistochemical studies in the molecular level which performed to date tend to investigate the presence of a major prognostic factor, except the clinic of cancer and histopathological parameters, such as tumor differentiation, lymphatic metastasis, vascular/cartilage invasion. Sometimes it is not possible to determine the prognosis of cancer metastasis with the clinicopathological factors, and we are faced with unexpected surprises about the tumor behavior. In this study MMP-9 (It has destructive proteolytic activity against extracellular matrix), E-cadherin (It is responsible from the interaction and adhesion between the epithelial cells) and VEGF (It is a key element of angiogenesis) in cancer tissue were studied using immunohistochemical staining. The relationship between these molecules with differentiation, lymphatic metastasis, and stage of tumor were investigated.

Enzymatic proteolysis takes place with the cell motility and cell adhesion. Integrins, selectins, and CD44 take place in the process of cell adhesion. The initial step of metastasis is dependent on the cell motility, cell differentiation, and interaction between cancer cells (Shiozaki et al., 1991).

Tumor cells should pass the extracellular matrix and penetrate through the basement membrane in order to metastasis. Therefore it is necessary to describe the components of extracellular matrix to understand the mechanisms of metastasis.

The degradation of the extracellular matrix has a key role for tumor invasion. MMPs are zinc-dependent endopeptidases, belong to family of proteases which is known as the metzincin superfamily (Page-McCaw et al., 2007). Members of this family can be listed as; interstitial collagenase (MMP-1), neutrophil collagenase, stromelysin-1 (MMP-3), stromelysin-2 (MMP-10), stromelysin-3, matrilizin (MMP-7), MMP-2 (gelatinase A), and MMP-9 (type IV collagenase). The progression and invasion capacity of tumor is associated to with the degradations of basement membrane (which is formed by Type IV collagen), and the fibrous capsule (which is formed by Type I and Type III collagen). Due to the proteolytic activity of MMP-9 enzyme that degrades type IV collagen, it increases tumor invasion and progression (Shima et al., 1992; Kusakawa et al., 1993; Sato et al., 1999)

Hong et al. (2000) found the significant relationship between MMP-9 expression and cervical metastatic disease. The increased expression of MMP-9 in patients with oral squamous cell carcinoma was stated as 73.7% in contrast with our study, and any correlation with decrease in histological differentiation has not been established.

A recent study investigating the correlation of matrix metalloproteinase-9 (MMP-9) expression with histopathologic and clinical characteristics of laryngeal SCC assessed the role of MMP-9 expression in patient survival. They found that the level of MMP-9 expression has showed a statistically significant correlation with the disease histopathologic grade, stage, metastatic potential, recurrence potential, and survival. They concluded MMP-9 expression as a biological marker and has showed a potential predictive value in laryngeal SCC (Colović et al., 2013).

In our study, semi-quantitative assessment of MMP-9 expression was observed in 42% (16/38) in positive staining pattern, whereas negative staining pattern was observed in 58% (22/38) of cases. The relationship between the expression of MMP-9 and tumor differentiation evaluated. Positive staining detected in 26.32% (5/19) of well-differentiated tumors, and 57.89% (11/19) of moderately/poorly differentiated tumors. This statistically significant ($p < 0.05$) difference means that MMP-9 expression increases with decreasing tumor differentiation. This leads us to hypothesis that the increased expression of MMP-9 is directly proportional to the increase in the invasiveness of tumor.

In parallel to our study, MMP-9 expression identified 85% in the study of Charouset al. (1997) with 27 cases of squamous cell carcinoma of the hypopharynx. They reported a significant relationship between the increase in MMP-9 expression and the primary tumor histopathology, clinical stage, lymphatic invasion, and extracapsular extension.

Kusakawa et al. (1993) in oral squamous cell carcinoma, reported the 67% relationship between lymph node metastasis and increase in MMP-2 expression, but the expression of MMP-2 was not correlated with clinical stage and histopathological differentiation. Friguglietti et al. (2000) showed that type IV collagenase (MMP-9) increases the capsular invasion in follicular thyroid carcinoma.

The results of our study did not show any significant relationship between lymph node metastasis and the expression of MMP-9. Positive (+) expression of MMP-9 detected in the patients with and without lymph node metastasis as 46.67% and 39.13% respectively. Although there was no statistically significant difference, it suggests that there may be an enhancing feature of MMP-9 on tumor invasion and progression. Also, the relationship between MMP-9 expression and tumor stage was not statistically significant ($p > 0.05$).

The distinction of tumor progression and invasiveness is reported to be determined by a number of post-translational modifications, or changes in the exon combinations in MMP-9 encoding gene (Charous et al., 1997). Increased expression of MMP-2 and MMP-9 in cancer cells, give rise to basement membrane invasion, and it raises the potential for the spread of tumor cells (Miyajima et al., 1995). In another study, the increase in the expression of MMP-9 in patients with renal adenocarcinoma has been reported to have been rising metastasis and invasion potential (Kugler et al., 1998).

Recently, a significant relationship is reported between

MMP-9 transcription and adjusted survival in HNSCC patients treated with radiotherapy or chemoradiotherapy. In that study, the authors suggested that MMP-9 transcription might serve as a marker of treatment response to radiotherapy or chemo-radiotherapy (Virós et al., 2013).

The regulation of MMP-9 has been shown to depend upon a large number of cytokines and growth factors (Mook et al., 2004). In recent studies, all-trans retinoic acid is reported to down-regulate pro-MMP-9 activity, and iron is suggested to be a factor that causes an increase of MMP-9, which is necessary for the development and progression of head and neck squamous cell carcinoma (Kaomongkolgit et al., 2008; Dutta et al., 2010).

For the metastasis of tumor, angiogenesis that provides the formation of new blood vessels outside the vascular bed should begin. VEGF is responsible for vasculogenesis, endothelial cell proliferation and migration. Beginning of the angiogenic process, the activation of some proteolytic enzymes causes stromal decomposition, thereby it increases vascular permeability and causes tumor invasion (Andrews et al., 1997; Mineta et al., 2000). VEGF is a dimeric polypeptide growth factor that have mitogenic activity specific for endothelial cells, and implicated in pathological angiogenesis associated with tumors. VEGF is the main regulator of tumor angiogenesis (Klagsbrun et al., 1993; Eisma et al., 1999). VEGF directly does not affect the tumoral growth and transformation. It is thought to stimulate the growth and spread of tumor by angiogenesis via indirect proliferation (Borgström et al., 1996; Mineta et al., 2000). Tumors of diameter 1-2 mm or less is fed mostly by diffusion, but the tumors with a greater size require the vascular system. Angiogenesis is a process, which requires the formation of a new basement membrane with the basement membrane damage, migration of endothelial cells and formation of new blood vessels (Roomi et al., 2009). Borgström et al. (1996) studied the relationship between tumor angiogenesis and metastasis in patients with invasive prostate carcinoma. The rate of microvessel formation were significantly lower in patients without metastasis. In that study, the relationship of tumor angiogenesis and metastasis was investigated, microvessel formation rate was markedly lower in patients without metastasis. The disease free interval was found to correlate with the increase in the number of microvessels, in another study with the breast cancer patients (Basset et al., 1990).

In our study the relationship between VEGF and cervical metastases was evaluated. Similar to those studies, in two of the five metastatic cases, a highly positive (+) staining pattern was observed. But the statistical analysis could not be made, because the number of cases was insufficient.

Kim et al. (1993) advocates that monoclonal VEGF inhibitors are not effective in inhibiting tumor growth in tissue culture, whereas Bengstrom et al. (1996) showed that anti-VEGF neutralizing antibodies inhibit angiogenesis and tumor growth in mice. The increased expression of VEGF in laryngeal carcinoma was reported 56% in accordance with our study, in a study designed with 60 cases of head and neck squamous cell carcinoma by Takeichi (1991). A close correlation was reported between

VEGF expression and lymph node metastasis in primary laryngeal carcinomas, suggesting a role in metastasis (Wang et al., 2012). In our study, the positive expression of VEGF was 52.63% in well-differentiated tumors, and 60% in moderate/poorly differentiated tumors. The difference between groups was not statistically significant.

Mineta et al. (2000) examined the clinical significance of VEGF expression in head and neck squamous cell carcinomas. They reported the highest rate of increase in VEGF expression in oropharyngeal cancers (71%), while increased expression in carcinoma of larynx, hypopharynx, oral cavity, and maxillary sinus were reported 56%, 45%, 40%, and 8% respectively.

The effort to increase angiogenesis to provide oxygen need for the growth of tumor, also the idea of these vessels prepare the ground for metastasis reveals the function of VEGF much better.

Considering the relationship between VEGF expression and tumor stage, late stage (stage III and IV) tumors had positive expression rate of 66.67%. Positive (+) staining pattern was observed 43.75% in early stage tumors (stages I and II). Even if the difference was not statistically significant ($p>0.05$), it seems that the expression of VEGF increases with the increase of tumor stage, and with the increasing numbers of cases we think more accurate results can be expected. If the future studies with larger case series show the higher levels of VEGF increase the incidence of tumor recurrence, TNM stage, and shorten disease free period; the treatment to suppress cytokines in the tumor tissue may open new horizons in the cancer treatment.

The other step of the metastasis is the liberalisation of tumor cells to the tissue. At this point, the suppression of intercellular adhesion molecules between epithelial cells may play role in triggering, particularly the suppression of E-cadherin expression. Cadherins are intercellular transmembrane glycoproteins, which are major components of Ca^{2+} dependent cell-cell adhesion molecules. They are responsible from the various cell-cell adhesions.

E-cadherin (ovomorulin, L-CAM) is a transmembrane glycoprotein expressed in adult epithelial tissues, embryogenesis, tumorigenesis, and plays a role in various morphogenetic events (Eidelman et al., 1989; Takeichi, 1991). It acts in cell differentiation as a mediator for the cell-cell adhesion. E-cadherin has invasion suppressor role in expressed tumors (Frixen et al., 1991). Frixen et al. (1991) also indicated that the selective loss of E-cadherin expression generates dedifferentiation and invasiveness of human carcinoma cells. E-cadherin is a transmembrane glycoprotein, involved in cell-cell adhesion and epithelial mesenchymal transition. The loss of E-cadherin may be associated with enhanced migration of tumour cells, leading to higher metastatic risk of head and neck SCC patients (Nijkamp et al., 2011).

E-cadherin provides intercellular adhesion of cancer cells. Suppression of E-cadherin expression in the primary lesion plays a role as a trigger for liberalization of the cancer cells. Decreased expression of E-cadherin may be due to more than one cause. Reduced transcription or suppression in the gene of E-cadherin, and binding cadherin peptides to the proteases may cause decreased

expression of E-cadherin (Shiozaki et al., 1991; Behrens, 1994; Bagutti et al., 1998; Jawhari et al., 1999).

The expression of E-cadherin may change due to allele missing in short arm of chromosome 16 (16q) that E-cadherin gene is localized or a defect in translocation. The lymphatic invasion and tumor morphology may become more aggressive in case of the reduction of E-cadherin expression in tissue (Nagafuchi et al., 1989; Navarro et al., 1991). However, this reduction triggers expansive growth more than infiltrative growth. Basset et al. (1990) reported that the expression of proto-oncogene c-erbB-2 in breast cancer results in a reduction of E-cadherin gene transcription, and causes the rapid growth and poor prognosis of tumor.

Acs et al. (2001) studied E-cadherin expression pattern in invasive and *in situ* carcinomas by immunohistochemistry. They found a highly significant correlation of E-cadherin membrane expression with the histologic phenotype of the tumors. Moderate to strong membrane expression of E-cadherin was seen in all invasive and *in situ* ductal carcinomas. The majority of invasive and *in situ* lobular carcinomas showed complete loss of expression. All *in situ* carcinomas diagnosed histologically as showing mixed ductal and lobular features demonstrated complete loss of staining.

A recent study by Rosado et al. (2013) studied E-cadherin expression in normal oral mucosa and in oral squamous cell carcinomas immunohistochemically. E-cadherin was significantly associated with histological grade. However, it was not an independent prognostic factor in the disease-specific survival analysis. Mattijssen et al. (1993) studied the level of E-cadherin expression in primary head and neck squamous-cell carcinomas. They reported a significant correlation between the level of E-cadherin expression in the primary tumor and the degree of differentiation, and no relation was found with tumor size or regional lymph-node classification. The patients surviving ≥ 30 months without evidence of disease had significantly higher levels of E-cadherin expression in primary tumors than patients with unfavorable clinical course clearly related to recurrent and/or metastatic disease. In accordance with our study, they concluded that E-cadherin expression has prognostic importance in the patients with head and neck squamous-cell carcinomas. In our study, well-differentiated tumors showed (+), (++) , (+++) staining patterns in 38.89%, 38.89% and 22.22% respectively. Moderately/poorly differentiated tumors showed (+), (++) , (+++) staining patterns in 64.71%, 5.88% and 29.41% respectively. The difference was statistically significant ($p < 0.05$). Also, the suppression of E-cadherin expression in the tissue samples of metastatic lymph nodes showed significant decrease compared with non metastatic lymph nodes ($p < 0.05$). This reduction in expression of E-cadherin reflects the increased tendency to metastasize. The strong E-cadherin expression was significantly associated with increase in degree of differentiation, and decrease in lymph node involvement. It suggests that E-cadherin may be a predictor of differentiation and nodal metastases in laryngeal squamous cell carcinomas.

Shiozaki et al. (1991) investigated the expression

of E-cadherin in human carcinoma samples. The expression of E-cadherin was reduced in primary tumors of esophagus, stomach, and breast were 73%, 25%, and 45% respectively, and 68% of all samples displayed heterogeneous E-cadherin expression. The immunohistopathologic studies for prostate, esophagus, stomach, breast, head and neck squamous cell carcinomas revealed that the decrease in the expression of E-cadherin increases the lymph node metastasis (Hiraki et al., 1996).

E-cadherin expression did not show a statistically significant difference between early and late stage tumors according to our study. It suggests that, there is a weak correlation between primary tumor size and tumor characteristics. There was a statistically significant difference between well and moderately/poorly differentiated tumors. This information suggests that there is a relationship between the expression of E-cadherin and the degree of differentiation, and this relationship is probably due to E-cadherine.

The absence of a standardisation for monoclonal antibodies used in such studies or the differences in immunohistochemical methods may lead to conflicting results. Likewise, the studies with a small number of cases may result in a controversial.

The invasive and metastatic ability of carcinomas mostly depends on the degree of epithelial differentiation of the tumors. Poorly differentiated tumors are more invasive than well-differentiated ones. The selective loss of E-cadherin expression is associated with dedifferentiation and invasiveness of human carcinoma cells. E-cadherin expression can be used as a marker for tumor invasion. New drugs to activate the transcription of E-cadherin may result in a decrease in the differentiation of tumor cells. Thus, the invasion and metastasis formation can be prevented (Frixen et al., 1991). cAMP expression and transcription of E-cadherin can be prevented *in vitro* by the use of anti-E-cadherin monoclonal antibodies, and the invasiveness of epithelial cells can be avoided (Jawhari et al., 1999).

In conclusion, MMP-9 expression increases with decreasing tumor differentiation. The increased expression of MMP-9 is directly proportional to the increase in the invasiveness of tumor. It suggests that MMP-9 expression may be a negative predictor in the prognosis of laryngeal SCC. The high E-cadherin expression was associated with increase in degree of differentiation, and decrease in lymph node involvement. It suggests that E-cadherin is an predictor of differentiation and nodal metastases in laryngeal SCC, and it may be considered as a precursor of positive prognosis. The relation between the expression of VEGF and differentiation of tumor revealed no significant differences. Although the difference between VEGF expression and tumor stage was not statistically significant, it seems that the expression of VEGF increases with the increase of tumor stage, and with the increasing numbers of cases we think more accurate results can be expected.

References

Acs G, Lawton TJ, Rebeck TR, LiVolsi VA, Zhang PJ (2001).

- Differential expression of E-cadherin in lobular and ductal neoplasms of the breast and its biologic and diagnostic implications. *Am J Clin Pathol*, **115**, 85-98.
- Andrews NA, Jones AS, Helliwell TR, Kinsella AR (1997). Expression of the E-cadherin-catenin cell adhesion complex in primary squamous cell carcinomas of the head and neck and their nodal metastases. *Br J Cancer*, **75**, 1474-80.
- Bagutti C, Speight PM, Watt FM (1998). Comparison of integrin, cadherin, and catenin expression in squamous cell carcinomas of the oral cavity. *J Pathol*, **186**, 8-16.
- Basset P, Bellocq JP, Wolf C, et al (1990). A novel metalloproteinase gene specifically expressed in stromal cells of breast carcinomas. *Nature*, **348**, 699-704.
- Behrens J, Mareel MM, Van Roy FM, Birchmeier W (1989). Dissecting tumor cell invasion: epithelial cells acquire invasive properties after the loss of uvomorulin-mediated cell-cell adhesion. *J Cell Biol*, **108**, 2435-47.
- Behrens J (1994). Cadherins as determinants of tissue morphology and suppressors of invasion. *Acta Anat (Basel)*, **149**, 165-9.
- Berx G, Van Roy F (2001). The E-cadherin/catenin complex: an important gatekeeper in breast cancer tumorigenesis and malignant progression. *Breast Cancer Res*, **3**, 289-93.
- Borgström P, Hillan KJ, Sriramarao P, Ferrara N (1996). Complete inhibition of angiogenesis and growth of microtumors by anti-vascular endothelial growth factor neutralizing antibody: novel concepts of angiostatic therapy from intravitral videomicroscopy. *Cancer Res*, **56**, 4032-9.
- Cavallaro U, Christofori G (2004). Cell adhesion and signalling by cadherins and Ig-CAMs in cancer. *Nat Rev Cancer*, **4**, 118-32.
- Charous SJ, Stricklin GP, Nanney LB, Nettekville JL, Burkey BB (1997). Expression of matrix metalloproteinases and tissue inhibitor of metalloproteinases in head and neck squamous cell carcinoma. *Ann Otol Rhinol Laryngol*, **106**, 271-8.
- Colović Z, Pesutić-Pisac V, Poljak NK, et al (2013). Expression of matrix metalloproteinase-9 in patients with squamous cell carcinoma of the larynx. *Coll Antropol*, **37**, 151-5.
- Crissman JD, Zarbo RJ (1990). Squamous cell carcinoma of the upper aerodigestive tract: histologic parameters with prognostic value. In: Fee W.E. Jr, Goepfert H, Johans ME. et al (eds). *Head and Neck Cancer*, Vol. 2, Decker, Toronto.
- Dutta A, Sen T, Chatterjee A (2010). All-trans retinoic acid (ATRA) downregulates MMP-9 by modulating its regulatory molecules. *Cell Adh Migr*, **4**, 409-18.
- Eidelman S, Damsky CH, Wheelock MJ, Damjanov I (1989). Expression of the cell-cell adhesion glycoprotein cell-CAM 120/80 in normal human tissues and tumors. *Am J Pathol*, **135**, 101-10.
- Eisma RJ, Spiro JD, Kreutzer DL (1999). Role of angiogenic factors: coexpression of interleukin-8 and vascular endothelial growth factor in patients with head and neck squamous carcinoma. *Laryngoscope*, **109**, 687-93.
- Ferrara N, Davis-Smyth T (1997). The biology of vascular endothelial growth factor. *Endocr Rev*, **18**, 4-25.
- Friguglietti CU, Mello ES, Castro IV, Filho GB, Alves VA (2000). Metalloproteinase-9 immunorexpression and angiogenesis in thyroid follicular neoplasms: relation to clinical and histopathologic features. *Head Neck*, **22**, 373-9.
- Frixen UH, Behrens J, Sachs M, et al (1991). E-cadherin-mediated cell-cell adhesion prevents invasiveness of human carcinoma cells. *J Cell Biol*, **113**, 173-85.
- Folkman J (1990). What is the evidence that tumors are angiogenesis dependent? *J Natl Cancer Inst*, **82**, 4-6.
- Gerrow K, El-Husseini A (2006). Cell adhesion molecules at the synapse. *Front Biosci*, **11**, 2400-19.
- Gupta K, Kshirsagar S, Li W, et al (1999). VEGF prevents apoptosis of human microvascular endothelial cells via opposing effects on MAPK/ERK and SAPK/JNK signaling. *Exp Cell Res*, **247**, 495-504.
- Haksever M, Inançlı HM, Tunçel U, et al (2012). The effects of tumor size, degree of differentiation, and depth of invasion on the risk of neck node metastasis in squamous cell carcinoma of the oral cavity. *Ear Nose Throat J*, **91**, 130-5.
- Hermanek P, Sobin LH (1997). UICC TNM Classification Of Malignant Tumors, 5th ed. New York, John Wiley
- Hiraki A, Shinohara M, Ikebe T, et al (1996). Immunohistochemical staining of desmosomal components in oral squamous cell carcinomas and its association with tumour behaviour. *Br J Cancer*, **73**, 1491-7.
- Hong SD, Hong SP, Lee JI, Lim CY (2000). Expression of matrix metalloproteinase-2 and -9 in oral squamous cell carcinomas with regard to the metastatic potential. *Oral Oncol*, **36**, 207-13.
- Howlader N, Noone AM, Krapcho M, et al (2011). National Cancer Institute. Bethesda, MD. based on November 2011 SEER data submission, posted to the SEER web site, April 2012.
- Jakobsson PA, Eneroth CM, Killander D, Moberger G, Mårtensson B (1973). Histologic classification and grading of malignancy in carcinoma of the larynx. *Acta Radiol Ther Phys Biol*, **12**, 1-8.
- Jakobsson PA (1975). Histologic grading of malignancy and prognosis in glottic carcinoma of the larynx. *Can J Otolaryngol*, **4**, 885-92.
- Jawhari AU, Farthing MJ, Pignatelli M (1999). The E-cadherin/epidermal growth factor receptor interaction: a hypothesis of reciprocal and reversible control of intercellular adhesion and cell proliferation. *J Pathol*, **187**, 155-7.
- Kaomongkolgit R, Cheepsunthorn P, Pavasant P, Sanchavanakit N (2008). Iron increases MMP-9 expression through activation of AP-1 via ERK/Akt pathway in human head and neck squamous carcinoma cells. *Oral Oncol*, **44**, 587-94.
- Kim KJ, Li B, Winer J, et al (1993). Inhibition of vascular endothelial growth factor-induced angiogenesis suppresses tumour growth *in vivo*. *Nature*, **362**, 841-4.
- Klagsbrun M, Soker S (1993). VEGF/VPF: the angiogenesis factor found? *Curr Biol*, **3**, 699-702.
- Klein T, Bischoff R (2011). Physiology and pathophysiology of matrix metalloproteases. *Amino Acids*, **41**, 271-90.
- Kugler A, Hemmerlein B, Thelen P, et al (1998). Expression of metalloproteinase 2 and 9 and their inhibitors in renal cell carcinoma. *J Urol*, **160**, 1914-8.
- Kusukawa J, Sasaguri Y, Shima I, Kameyama T, Morimatsu M (1993). Expression of matrix metalloproteinase-2 related to lymph node metastasis of oral squamous cell carcinoma. A clinicopathologic study. *Am J Clin Pathol*, **99**, 18-23.
- Kyzas PA, Stefanou D, Agnantis NJ (2004). Immunohistochemical expression of vascular endothelial growth factor correlates with positive surgical margins and recurrence in T1 and T2 squamous cell carcinoma (SCC) of the lower lip. *Oral Oncol*, **40**, 941-7.
- Mareel M, Oliveira MJ, Madani I (2009). Cancer invasion and metastasis: interacting ecosystems. *Virchows Arch*, **454**, 599-622.
- Mattijssen V, Peters HM, Schalkwijk L, et al (1993). E-cadherin expression in head and neck squamous-cell carcinoma is associated with clinical outcome. *Int J Cancer*, **55**, 580-5.
- Mineta H, Miura K, Ogino T, et al (2000). Prognostic value of vascular endothelial growth factor (VEGF) in head and neck squamous cell carcinomas. *Br J Cancer*, **83**, 775-81.
- Miyajima Y, Nakano R, Morimatsu M (1995). Analysis of expression of matrix metalloproteinases-2 and -9 in hypopharyngeal squamous cell carcinoma by in situ

- hybridization. *Ann Otol Rhinol Laryngol*, **104**, 678-84.
- Mook ORF, Frederiks WM, Noorden CV (2004). The role of gelatinases in colorectal metastasis. *Biochim Biophys Acta*, **1705**, 69-89.
- Nagafuchi A, Takeichi M (1989). Transmembrane control of cadherin-mediated cell adhesion: a 94 kDa protein functionally associated with a specific region of the cytoplasmic domain of E-cadherin. *Cell Regul*, **1**, 37-44.
- Navarro P, Gómez M, Pizarro A, et al (1991). A role for the E-cadherin cell-cell adhesion molecule during tumor progression of mouse epidermal carcinogenesis. *J Cell Biol*, **115**, 517-33.
- Nijkamp MM, Span PN, Hoogsteen IJ, et al (2011). Expression of E-cadherin and vimentin correlates with metastasis formation in head and neck squamous cell carcinoma patients. *Radiother Oncol*, **99**, 344-8.
- Nollet F, Kools P, van Roy F (2000). Phylogenetic analysis of the cadherin superfamily allows identification of six major subfamilies besides several solitary members. *J Mol Biol*, **299**, 551-72.
- Page-McCaw A, Ewald AJ, Werb Z (2007). Matrix metalloproteinases and the regulation of tissue remodelling. *Nat Rev Mol Cell Biol*, **8**, 221-33.
- Peralta Soler A, Knudsen KA, Tecson-Miguel A, et al (1997). Expression of E-cadherin and N-cadherin in surface epithelial-stromal tumors of the ovary distinguishes mucinous from serous and endometrioid tumors. *Hum Pathol*, **28**, 734-9.
- Pilch BZ, Dorfman DM, Brodsky GL (1996). Goodman M. Pathology of laryngeal malignancies. In: Fried MP. ed. The larynx; A multidisciplinary Approach. 2nd ed. St Louis, CV Mosby, 425-36
- Roomi MW, Monterrey JC, Kalinovsky T, Rath M, Niedzwiecki A (2009). Distinct patterns of matrix metalloproteinase-2 and -9 expression in normal human cell lines. *Oncol Rep*, **21**, 821-6.
- Rosado P, Lequerica-Fernández P, Fernández S, et al (2013). E-cadherin and β -catenin expression in well-differentiated and moderately-differentiated oral squamous cell carcinoma: relations with clinical variables. *Br J Oral Maxillofac Surg*, **51**, 149-56.
- Sato F, Shimada Y, Watanabe G, et al (1999). Expression of vascular endothelial growth factor, matrix metalloproteinase-9 and E-cadherin in the process of lymph node metastasis in oesophageal cancer. *Br J Cancer*, **80**, 1366-72.
- Shima I, Sasaguri Y, Kusukawa J, et al (1992). Production of matrix metalloproteinase-2 and metalloproteinase-3 related to malignant behavior of esophageal carcinoma. A clinicopathologic study. *Cancer*, **70**, 2747-53.
- Shiozaki H, Tahara H, Oka H, et al (1991). Expression of immunoreactive E-cadherin adhesion molecules in human cancers. *Am J Pathol*, **139**, 17-23.
- Stell PM (1990). Prognosis in laryngeal carcinoma: tumour factors. *Clin Otolaryngol Allied Sci*, **15**, 69-81.
- Takeichi M (1991). Cadherin cell adhesion receptors as a morphogenetic regulator. *Science*, **251**, 1451-5.
- Talvensaari-Mattila A, Turpeenniemi-Hujanen T. (2005). Preoperative serum MMP-9 immunoreactive protein is a prognostic indicator for relapse-free survival in breast carcinoma. *Cancer Lett*, **217**, 237-42.
- Wakisaka N, Wen QH, Yoshizaki T, et al (1999). Association of vascular endothelial growth factor expression with angiogenesis and lymph node metastasis in nasopharyngeal carcinoma. *Laryngoscope*, **109**, 810-4.
- Wang Z, Chen Y, Li X, et al (2012). Expression of VEGF-C/ VEGFR-3 in human laryngeal squamous cell carcinomas and its significance for lymphatic metastasis. *Asian Pac J Cancer Prev*, **13**, 27-31.
- Virós D, Camacho M, Zarranonandia I, et al (2013). Prognostic role of MMP-9 expression in head and neck carcinoma patients treated with radiotherapy or chemoradiotherapy. *Oral Oncol*, **49**, 322-5.
- Zhao YG, Xiao AZ, Ni J, Man YG, Sang QX (2009). Expression of matrix metalloproteinase-26 in multiple human cancer tissues and smooth muscle cells. *Ai Zheng*, **28**, 1168-75.
- Zhongliang W, Yao C, Rueixiang L (2002). Advanced in the researches for vascular endothelial growth factor (VEGF)-C and vascular endothelial growth factor receptor (VEGFR)-3. *China J Cancer Prev Treat*, **9**, 454.