



CE

Article #3 (1.5 contact hours)

Refereed Peer Review

KEY FACTS

- Abnormalities in brachycephalic dogs restrict their breathing and can have life-threatening effects.
- Because anesthesia is risky for brachycephalic patients, as many diagnostic and therapeutic steps as possible should be planned and executed in the same narcosis.
- Early correction of stenotic nares and elongated soft palates results in a favorable prognosis.

Brachycephalic Syndrome in Dogs

University of Zurich

Daniel A. Koch, DrMedVet, DECVS

Susanne Arnold, PD, DrMedVet, DECAR

Madeleine Hubler, DrMedVet, DECAR

Pierre M. Montavon, Prof DrMedVet

ABSTRACT: Stenotic nares and elongated soft palates seem to be the initiating events of brachycephalic syndrome in dogs. As a result of increased negative pressure during inspiration, the soft tissues of the upper airway are sucked into the lumen, aggravating the condition. The most common signs of brachycephalic syndrome are stress and heat intolerance, inspiratory stridor, and asphyxia. Severely affected animals are prone to life-threatening attacks. Surgical corrections include wedge resection of stenotic nares, shortening of the soft palate, and removal of laryngeal sacculles.

Brachycephalic breeds tend to have respiratory problems that come under the term *brachycephalic syndrome*. The typical anatomic abnormalities are stenotic nares, enlarged tonsils, elongated soft palate, everted lateral sacculles of the larynx, narrowed rima glottidis, and collapse of the larynx and trachea.¹ These findings occur singularly or in various combinations and degrees in each dog. These abnormalities narrow the lumen of the upper respiratory tract, thereby restricting breathing, which often leads to asphyxiation and collapse during excitement or heat resulting from the weather or activity. This article provides a review of the predisposition and anatomic and pathophysiologic particularities of the respiratory tract in connection with brachycephalic syndrome.

PREDISPOSITION

The term *brachycephalia* refers to a local chondrodysplasia that occurs as a result of domestication. Early ankylosis occurs in the cartilage of the base of the skull, leading to a shortened longitudinal axis of the skull. Breeders have deliberately kept this chondrodysplasia.^{2,3}

The division of dogs into dolichocephalic, mesocephalic, and brachycephalic is based on skull measurements (Figure 1). According to Evans,³ dogs with a short and broad facial skull and skull width:length ratio of 0.81 and greater are brachycephalic. However, German authors^{4,5} based their classification on the relationship of cranial length to skull length; the length:length ratio of brachycephalic dogs is 1.60 to 3.44. Alternative measurements⁶ are based on the angle between the base of the skull (basilar axis) and facial skull (facial axis). Brachycephalic dogs have craniofacial angles of 9° to 14°, mesocephalic dogs 19° to 21°, and dolichocephalic greyhounds 25° to 26°.

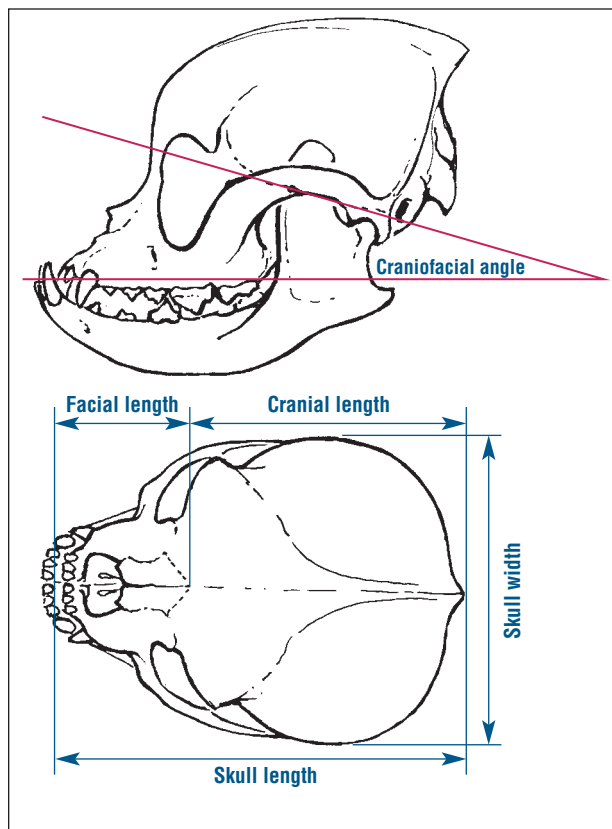


Figure 1—Skull measurements in brachycephalic dogs: craniofacial angle of the basilar and facial axes (*top*⁶), skull width to skull length (*bottom*³), and cranial length to skull length (*bottom*^{4,5}).

Depending on the division modality, the following breeds are typically brachycephalic: Chihuahua, bulldog, King Charles spaniel, pug, Boston terrier, Maltese, Pekingese, miniature pinscher, shih tzu, Yorkshire terrier, and boxer. Because of the shape of their skull, these breeds not only suffer from respiratory problems but are also predisposed to hydrocephalus, facial nerve paralysis, skinfold dermatitis, eye-bulb prolapse, and false positioning of the teeth.⁷⁻⁹

PARTICULARITIES OF THE UPPER AIRWAY

The wings of the nostrils are very maneuverable because they contain the fibers of the maxillary levator labii and nasolabial levator muscles. Widening the nostrils improves airflow through the vestibulum and is most often observed during sniffing or labored breathing.

Both nasal cavities comprise the dorsal, ventral, and ethmoidal conchae (Figure 2), which create four main corridors: the common nasal, dorsal, middle, and ventral meatuses. The meatuses continue as nasopharyngeal ducts and end as choanae in an oblique oval.³ The paranasal sinuses are usually missing in brachycephalic dogs.⁴

The shape and size of the conchae determine the path of the air stream through the nasal cavities. During inspiration, air flows mainly through the ventral and middle meatus toward the nasopharynx. Only with high inspiratory pressure is the dorsal meatus also ventilated, bringing the air into more intimate contact with the olfactory epithelium. During expiration, air first passes the choanae and thereafter all meatuses before leaving the nasal respiratory tract. While sniffing, air is kept in place around the olfactory epithelium with short, repeated breaths and pauses and is only slowly exhaled. This study was conducted using smoke in isolated canine skulls.¹⁰

Lateral to the nasopharyngeal meatus, the eustachian tubes enter on both sides. They connect the pharynx to the middle ear, equalizing pressure differences on either side of the tympanic membrane.³ The transition from hard to soft palate is caudal to the last molar in dolichocephalic and mesocephalic dogs, whereas it is more caudal in brachycephalic dogs. The soft palate normally extends to the top of the epiglottis. The muscular-cartilaginous larynx controls the airflow within the trachea and takes part in vocalization. The narrowest passage of the airflow is the rima glottidis, which is formed dorsally by the paired arytenoid cartilages and ventrally by the paired vocal folds. The laryngeal saccule is situated between the vocal and ventricular folds.

Passage through the nasal cavities accounts for 76.5% of total airflow resistance. In comparison, the larynx (4.5% of resistance) and the more distally situated trachea, bronchus, and bronchioli (19% of resistance) contribute only a modest amount. In contrast to humans, the values of airflow resistance in dogs barely differ between expiration and inspiration. If airflow is increased, nasal cavity resistance increases up to 80%.¹¹ Even if nasal resistance is artificially increased, dogs still try to breathe through their noses. Either their ability to smell is extremely important to dogs or a reflex suppresses open-mouthed breathing. Only when both nasal cavities are chronically obstructed do intrapleural pressure and pulmonary changes occur.¹²

PATHOPHYSIOLOGY

Traditional explanations of the pathophysiology of brachycephalic syndrome are based on the shortened noses of brachycephalic breeds.^{1,13-15} Through breeding, the anatomy of the respiratory tract has been changed, which in turn has increased resistance during inspiration. The narrowed nostrils^{1,13} and anatomy of the endoturbinaria are considered to be possible stenoses. To obtain sufficient oxygen, brachycephalic dogs must produce higher negative pressure by increasing labored breathing distal to the resistance. With this negative pressure, the soft tissues are drawn into the lumen and become hyperplastic. Significant differences have been found in breathing patterns

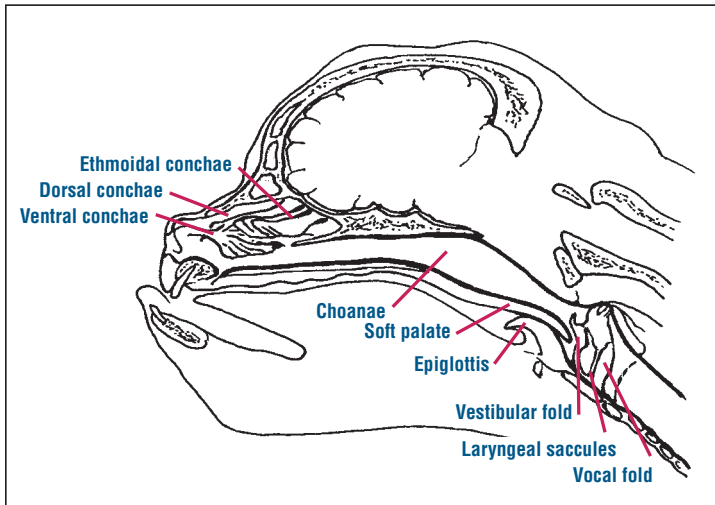


Figure 2—Anatomy of the upper airway in the sagittal plane of a brachycephalic dog. Note the elongated soft palate, which lies dorsal to the epiglottis and impinges on the larynx.

between nonbrachycephalic and brachycephalic dogs as well as the type of obstruction (fixed or not fixed) in brachycephalic dogs.¹⁶ If negative pressure in the lumen is high enough, it might even exceed the resistance of the tissues, causing these structures to collapse.¹⁷

Secondary manifestations of brachycephalic syndrome, such as everted laryngeal saccules or tonsils, partial collapse of the dorsonasal pharynx, a narrowed rima glottis, and collapse of the cartilaginous respiratory tract, constrict the lumen even more. This increases the clinical signs and leads to further deterioration that may ultimately cause death from suffocation.^{1,14}

Whether the elongated soft palate is a primary or secondary event has not been determined.^{1,15,18} However, the soft palate can be so elongated or pushed caudally against the maxillary bone that breathing is heavily impeded. During inspiration, the soft palate audibly flutters. It may even be caught dorsal to the epiglottis (Figure 2), near the rima glottidis, inciting suffocation.^{19,20}

The trachea of bulldogs is clearly hypoplastic. Other brachycephalic breeds also have narrower tracheas compared with those of dolichocephalic or mesocephalic dogs. However, this is thought to be due to an abnormal embryogenesis²¹ and is not a sequela of a more cranially situated stenosis.²²

Affected dogs try to interrupt or prevent acute attacks of respiratory compromise. During excitement, a sympathetically controlled mechanism causes vasoconstriction, reducing resistance for a short time.^{23,24} During inspiration, the wings of the nostrils are actively dilated.³ If signs of dyspnea occur, the dogs stretch their necks upward to dilate the nasopharynx and larynx and, if necessary, move

the elongated soft palate below the epiglottis. If the elongated soft palate is held above the epiglottis, the dogs lie down on their sides, which releases the soft palate by allowing it to glide laterally to the epiglottis.^{25,26} Panting helps the dogs expel surplus heat. Air is inhaled rapidly through the nose, where it is moistened in the conchae, and exhaled through the mouth. To provide enough moisture, the lateral nasal salivary glands increase production.²⁷ Even if the upper respiratory tract is severely obstructed, some dogs resist breathing fully through the mouth even though their oxygen demand could be met using mouth breathing.¹²

Mesocephalic breeds (e.g., golden retriever, spaniel, dachshund, Norwich terrier) develop clinical signs similar to those of dogs with brachycephalic syndrome,^{28,29} including inspiratory stridor, exercise intolerance, and asphyxia while sleeping.²⁸ In addition, elongated soft palates, everted laryngeal saccules, and other protruded soft tissues are observed, but narrowing of the nostrils is rare. On the other hand, pugs and cats³⁰ often have narrowed nostrils without elongated soft palates or partial pharyngeal collapse. Therefore, a short nose and narrow nostrils cannot be the only causes of brachycephalic syndrome. Other causes could include malformation of the conchae, a changed shape of the whole head,⁶ loss of rigidity of cartilage or upper respiratory tract soft tissue (as described in children),³¹ or vascular abnormalities.¹²

The respiratory tract is not the only organic structure exposed to increased negative pressure during inspiration. Because of their close vicinity to the airways, the esophagus, auditory canals, central nervous system, and lower respiratory tract should also be examined. An enlarged tongue, difficulty in swallowing, hiatal hernia, gastric bloating, otitis media, neurologic signs, and bronchiectasia are not uncommon in brachycephalic breeds.³²⁻³⁵

The respiratory tract is not the only organic structure exposed to increased negative pressure during inspiration. Because of their close vicinity to the airways, the esophagus, auditory canals, central nervous system, and lower respiratory tract should also be examined. An enlarged tongue, difficulty in swallowing, hiatal hernia, gastric bloating, otitis media, neurologic signs, and bronchiectasia are not uncommon in brachycephalic breeds.³²⁻³⁵

CLINICAL SIGNS

Patients with brachycephalic syndrome often have severe dyspnea. Some are also hyperactive and hyperthermic. Therefore, the initial examination should preferably be performed without restraint or anesthesia. In an emergency, animals must be sedated, given oxygen, and cooled down with alcohol.

The history will show heat stress and exercise intolerance. Suffocation is mainly observed during sleep because the general muscular relaxation narrows the respiratory passages.¹⁸ If the upper respiratory tract is obstructed, inspiratory stridor is the dominant clinical sign. With each inspiration, thoracic volume increases and pressure subsequently decreases in the lungs and respiratory passages.

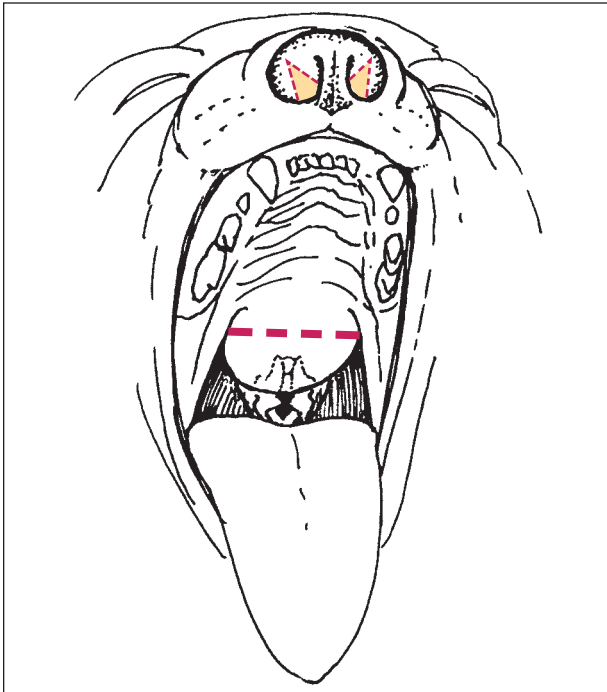


Figure 3—Two surgical treatment options in brachycephalic syndrome. Stenotic nares can be widened by excision of a wedge, or the elongated soft palate can be corrected by shortening it to the level of the tip of the epiglottis.

The resulting airflow leads to an additional pressure reduction in the respiratory passages (law of Bernoulli). This, in turn, brings the edges of the soft tissues close together in the stenotic area, causing the typical breathing sound. As a result of the positive pressure during expiration, the edges of the soft tissues come together only if stenosis is severe.³¹ On inspection of the nose, narrow nares are noticeable. In brachycephalic dogs, the wings of the nostrils barely move outward during inspiration but are sucked into the airflow.

DIAGNOSIS

Before anesthesia is administered, blood samples should be taken for a complete blood count and serum biochemical analysis. Blood gas analysis from a venous blood sample provides important information about blood pH, bicarbonate, and carbon dioxide partial pressure values. The oxygen saturation of the blood can be measured by oxymetry. Chest radiographs are taken to estimate secondary changes to the lungs, such as bronchiectasis, and to diagnose a probable hypoplastic trachea.^{1,18,25}

Once the patient is anesthetized, all diagnostic and therapeutic steps should be performed. Anesthetizing brachycephalic dogs is particularly challenging because almost all sedatives and anesthetic drugs relax the muscles of the upper respiratory tract. However, the diaphragm is still

able to generate negative pressure necessary for breathing, thereby promoting collapse of upper airway soft tissue.²⁰ We recommend preoxygenation for a couple of minutes, premedication with a tranquilizer and an opioid, and rapid induction of anesthesia with thiopental or propofol. First, the oropharynx is examined with a laryngoscope. The tongue is then displaced ventrally with the blade of the laryngoscope. Ideally, the caudal border of the soft palate and the tip of the epiglottis should just touch each other. Nevertheless, the soft palate is often too long and can even prevent ventral displacement of the epiglottis. Both abnormalities disturb airflow through the oropharynx. Negative pressure within the air passages leads to edema and wave-like protrusions of the soft tissues at the roof of the nasopharynx and (sometimes) to enlargement and protrusion of the tonsils. Next, the blade of the laryngoscope displaces the epiglottis ventrally. The everted laryngeal sacculles may be seen between the vestibular folds and vocal cords. The movement of the rima glottidis is examined during inspiration and expiration. The vocal cords and arytenoid cartilage should abduct during inspiration. If there are advanced pathologic changes, the soft tissues and their supporting cartilaginous regions of the larynx may collapse, additionally restricting the air passages. Laryngeal collapse is characterized by plastic deformation of the laryngeal entrance. It must be distinguished from laryngeal paralysis, in which abduction of the arytenoid cartilage is compromised during inspiration. The inner lumen and trachea can be visualized only by endoscopy. In some brachycephalic dogs, tracheal collapse may be observed as a result of continuing negative pressure.

THERAPY

If treatment is provided immediately following the diagnostic workup, anesthesia should be maintained with isoflurane and oxygen. Securing the endotracheal tube to the lower jaw ensures free access to the soft palate. For some procedures, such as removal of the laryngeal sacculles, we temporarily extubate patients. Short-acting steroids may help prevent life-threatening postoperative swelling resulting from intubation and surgical manipulation. In critical cases, transtracheal intubation may be required.

According to the literature, brachycephalic syndrome should be treated from front to back; therefore, widening stenotic nostrils is the first step^{1,18,25,36} (Figure 3). This should prevent secondary changes, such as protrusion of soft tissue of the nasopharynx or collapse of the larynx and trachea. Aron and Crowe¹ assume that prolongation of the soft palate is a sequela of stenotic nares. Therefore, they recommend widening the nostrils at 3 to 4 months of age. The entrance to the vestibulum nasi is increased by removing a triangle of the nostril wings and adapting the wound edges. Hemorrhage is normally severe but tran-

sient. Only one to three stitches with nonabsorbable thread are necessary to close the wound, stop the bleeding, and prevent scarring.

An elongated soft palate should be shortened to the correct length to prevent interference with the epiglottis^{19,26} (Figure 3). To determine the correct length, the tip of the epiglottis or middle of the tonsils can be used as the caudal landmark. The soft palate can be shortened by cutting the excess tissue and suturing it with a rapidly absorbable material. Stepwise cutting and continuous suturing control hemorrhage and improve visibility during surgery. The soft palate can also be cut using a laser technique.³⁷ After widening the nostrils and shortening the soft palate, prognosis is generally quite good, especially in younger patients.^{19,38}

Everted laryngeal sacculles and laryngeal collapse are considered sequelae of more rostral stenoses. The everted laryngeal sacculles are cut off with long scissors.^{13,39} In cases of laryngeal collapse, a permanent tracheostomy is the treatment of choice because partial laryngectomies caused too many deaths postoperatively.^{38,40,41}

Removing the tonsils is controversial.^{18,25,42} They are usually removed if they protrude (as a result of irritation or negative pressure in the air passages) into the oropharynx. However, they can usually be left intact because they rarely interfere with breathing.

A large study on therapy for brachycephalic syndrome³⁸ concluded that most brachycephalic dogs with dyspnea at a young age have stenotic nares. Widening the nostrils and possibly shortening the soft palate provide a favorable prognosis. The laryngeal area is often not yet affected.^{1,36} If brachycephalic dogs have dyspnea due to brachycephalic syndrome as an adult, they tend to have soft palates that are too long, everted laryngeal sacculles, and a narrow rima glottidis or laryngeal collapse.³⁸ Presumably, nonbrachycephalic dogs with similar clinical signs, such as Norwich terriers,²⁸ belong to this group.

Postoperative care includes late extubation, an analgesic protocol, nasal oxygen supplementation for up to 24 hours, and close monitoring of the breathing pattern.

ACKNOWLEDGMENTS

The authors thank the Swiss Federal Veterinary Office (Bundesamt für Veterinärmedizin) in Berne, Switzerland, for its financial support of this study; Adrian Fairburn and Gillian Nussbaum for their translations; and Mathias Haab for his graphical work.

REFERENCES

- Aron DN, Crowe DT: Upper airway obstruction: General principles and selected conditions in the dog and cat. *Vet Clin North Am Small Anim Pract* 15(5):891-917, 1985.
- Dahme E: Stütz und Bewegungsapparat, in Dahme E, Weiss E (eds): *Grundriss der speziellen Anatomie der Haustiere*. Stuttgart, Enke Verlag, 1988, pp 314-351.
- Evans HE: *Miller's Anatomy of the Dog*, ed 3. Philadelphia, WB Saunders, 1993.
- Brehm H, Loeffler K, Komeyli H: Schädelformen beim Hund. *Zbl Vet Med C Anat Histol Embryol* 14:324-331, 1985.
- Nickel R, Schummer A, Wille KH: Passiver Bewegungsapparat, Skelettsystem, in Nickel R, Schummer A, Seiferle E (eds): *Lehrbuch der Anatomie der Haustiere, Band 1, Bewegungsapparat*, ed 5. Berlin, Hamburg, Paul Parey, 1984, pp 11-229.
- Regodon S, Vivo JM, Franco A, et al: Craniofacial angle in dolicho-, meso- and brachycephalic dogs: Radiological determination and application. *Anat Anz* 175(4):361-363, 1993.
- Scott D, Miller W, Griffin C: Environmental skin diseases, in Scott D, Miller W, Griffin C (eds): *Muller & Kirk's Small Animal Dermatology*, ed 6. Philadelphia, WB Saunders, 2001, pp 1073-1111.
- Toombs JP, Hardy RM: Neurologic signs associated with congenital anomalies in a Yorkshire terrier. *Vet Med Small Anim Clin* 76(2):207-214, 1981.
- Wegner W: Genetisch bedingte Zahnanomalien. *Der praktische Tierarzt* 68(5):19-22, 1987.
- Dawes JDR: The course of the nasal airstreams. *J Laryngol Otol* 66:583-593, 1952.
- Ohnishi T, Ogura JH: Partitioning of pulmonary resistance in the dog. *Laryngoscope* 79:1847-1878, 1969.
- Ohnishi T, Ogura JH, Nelson JR: Effects of nasal obstruction upon the mechanics of the lung in the dog. *Laryngoscope* 81:220-225, 1971.
- Leonard HD: Eversion of the lateral ventricles of the larynx in the dog. *JAVMA* 13:83-84, 1957.
- Cook WR: Observations on the upper respiratory tract of the dog and cat. *J Small Anim Pract* 5:309-329, 1964.
- Hobson HP: Brachycephalic syndrome. *Semin Vet Med Surg Small Anim* 10(2):109-114, 1995.
- Amis TC, Kurpershoek C: Pattern of breathing in brachycephalic dogs. *Am J Vet Res* 47(10):2200-2204, 1986.
- Thews G: Lungenatmung, in Schmidt R, Thews G (eds): *Physiologie des Menschen*. Berlin, Springer Verlag, 1983, pp 500-536.
- Farquharson J, Smith DW: Resection of the soft palate in the dog. *JAVMA* 100:427-430, 1942.
- Harvey CE: Upper airway obstruction surgery 2: Soft palate resection in brachycephalic dogs. *JAAHA* 18:538-544, 1982.
- Hendricks JC: Recognition and treatment of congenital respiratory tract defects in brachycephalics, in Bonagura JD (ed): *Kirk's Veterinary Therapy XII*. Philadelphia, WB Saunders, 1995, pp 892-894.
- Coyne BE, Finland RB: Hypoplasia of the trachea in dogs: 103 cases (1974-1990). *JAVMA* 201(5):768-772, 1992.
- Harvey CE, Fink E: Tracheal diameter: Analysis of radiographic measurements in brachycephalic and nonbrachycephalic dogs. *JAAHA* 18:570-576, 1982.
- Lung MA, Phipps RJ, Wang JC, et al: Control of nasal vasculature and airflow resistance in the dog. *J Physiol* 349:535-551, 1984.
- Woolcock AJ, Macklem PT, Hogg JC, et al: Effect of vagal stimulation on central and peripheral airways in dogs. *J Appl Physiol* 26(6):806-813, 1969.
- Knecht CD: Upper airway obstruction in brachycephalic dogs. *Compend Contin Educ Pract Vet* 1:25-31, 1979.
- Singleton WB: Partial velum palatiectomy for relief of dyspnea in brachycephalic breeds. *J Small Anim Pract* 3:215-216, 1962.
- Schmidt-Nielsen K, Bretz WL, Taylor CR: Panting in dogs:

Unidirectional airflow over evaporative surfaces. *Science* 169:1102–1104, 1970.

28. Hecht P, Reichler I, Arnold S, et al: Beobachtungen am oberen Atemapparat bei einer Population von Norwich-Terriern. *Schweiz Arch Tierheilk*, in preparation, 2003.
 29. Wilson FD, Rajendran EI, David G: Staphylotomy in a dachshund. *Indian Vet J* 37:639–642, 1960.
 30. Harvey CE: Surgical correction of stenotic nares in a cat. *JAAHA* 22:31–32, 1985.
 31. Greusing B, Grossenbacher R: Inspiratory stridor: A review. *Schweiz Rundsch Med Prax* 75(19):543–547, 1986.
 32. Hardie E, Ramirez O, Clary EM, et al: Abnormalities of the thoracic bellows: Stress fractures of the ribs and hiatal hernia. *J Vet Intern Med* 12:279–287, 1998.
 33. Montavon PM: Le syndrome brachycephalique. *Proc Jèrés rencontres Franco-Suisses*, 2000.
 34. Stolovitzky JP, Todd NW: Head shape and abnormal appearance of tympanic membranes. *Otolaryngol Head Neck Surg* 102:322–325, 1990.
 35. Venker-van Haagen A: Chronische Erkrankungen der oberen Atemwege. *Proc SVK Tage*:111–113, 1992.
 36. Harvey CE: Upper airway obstruction surgery 1: Stenotic nares surgery in brachycephalic dogs. *JAAHA* 18:535–537, 1982.
 37. Clark GN, Sinibaldi KR: Use of a carbon dioxide laser for treatment of elongated soft palate in dogs. *JAVMA* 204(11):1779–1781, 1994.
 38. Harvey CE: Upper airway obstruction surgery 8: Overview of results. *JAAHA* 18:567–569, 1982.
 39. Harvey CE: Upper airway obstruction surgery 3: Everted laryngeal sacculle surgery in brachycephalic dogs. *JAAHA* 18:545–547, 1982.
 40. Harvey CE: Upper airway obstruction surgery 4: Partial laryngectomy in brachycephalic dogs. *JAAHA* 18:548–550, 1982.
 41. Harvey CE, O'Brien JA: Upper airway obstruction surgery 7: Tracheotomy in the dog and cat: Analysis of 89 episodes in 79 animals. *JAAHA* 18:563–566, 1982.
 42. Lorinson D, Bright RM, White RAS: Brachycephalic airway obstruction syndrome: A review of 118 cases. *Canine Pract* 22:18–21, 1997.
2. Which breed shows signs similar to those of brachycephalic syndrome even though it is not classified as brachycephalic?
 - a. flat-coated retriever
 - b. Norfolk terrier
 - c. Norwich terrier
 - d. miniature poodle
 - e. bullterrier
 3. The common nasal meatus
 - a. lies on the lateral side of the nasal cavity.
 - b. communicates with all meatuses but the dorsal one.
 - c. continues as nasopharyngeal meatus, which ends at the choanae.
 - d. carries the olfactory epithelium.
 - e. normally ends at the level of the last molar.
 4. Which statement regarding airway resistance and labored breathing is correct?
 - a. Airway resistance increases with higher airflow rates.
 - b. Airway resistance is mainly produced in the larynx.
 - c. Sympathetic response causes increased airway resistance.
 - d. Dogs easily switch to mouth breathing when their airways are obstructed.
 - e. Changes in airway resistance are not reported to cause pulmonary changes.
 5. Which of the following characteristics is not part of brachycephalic syndrome?
 - a. everted laryngeal sacculles
 - b. an elongated soft palate
 - c. enlarged tonsils
 - d. hyperplastic soft tissue in the oropharynx
 - e. laryngeal paralysis
 6. Panting indicates
 - a. air inflow through the nose and outflow through the mouth.
 - b. air inflow and outflow through the mouth.
 - c. dead-space ventilation.
 - d. heat loss by evaporation over the oral mucosa.
 - e. increasing oxygen consumption.
 7. The secondary characteristics of brachycephalic syndrome are predominantly caused by
 - a. an anatomically induced mismatch between bone and soft tissue.
 - b. increased negative pressure in the upper airways.
 - c. pulmonic tissue alterations, which change the breathing pattern.
 - d. direct contact of the elongated soft palate with the oropharyngeal region.
 - e. inflammation of the soft tissue in the oropharynx.
1. According to Evans,³ dogs are classified as brachycephalic when the
 - a. skull length:width ratio is less than 1.6.
 - b. skull width:length ratio is more than 0.81.
 - c. cranial length:skull length ratio is more than 3.44.
 - d. craniofacial angle is 9° to 14°.
 - e. craniofacial angle is less than 9°.

ARTICLE #3 CE TEST

The article you have read qualifies for 1.5 contact hours of Continuing Education Credit from the Auburn University College of Veterinary Medicine. Choose the best answer to each of the following questions; then mark your answers on the postage-paid envelope inserted in *Compendium*.

8. Which initial measure(s) is(are) recommended for stabilizing heat stress and exercise intolerance caused by brachycephalic syndrome?
- a. oxygen, sedation, alcohol
 - b. propofol narcosis
 - c. tracheotomy
 - d. erythropoietin
 - e. muscle relaxants
9. Anesthesia is particularly risky in brachycephalic dogs because
- a. the diaphragm quickly stops contracting.
 - b. their narrow nostrils do not allow enough airflow.
 - c. transtracheal intubation is difficult to perform.
 - d. the oropharyngeal muscles relax quickly, allowing rapid collapse of upper airway tissue.
 - e. sedation is not advisable.
10. When performing surgery on brachycephalic dogs, which of the following guidelines are preferred?
- a. Early and delayed correction of stenotic nares have the same prognosis.
 - b. The elongated soft palate should be cut at the height of the arytenoid cartilage.
 - c. Tonsillectomy consistently improves the general outcome.
 - d. Surgical correction is started at the larynx and ends at the nostrils.
 - e. Permanent tracheostomy is a salvage procedure for unresolved brachycephalic syndrome.
-