

## HEPATOPROTECTIVE ACTIVITY FROM ETHANOL EXTRACT OF PUGUN TANO'S LEAVE (*CURANGA FEL-TERRAE* [LOUR.] MERR.)

URIP HARAHAP<sup>1\*</sup>, MARIANNE<sup>1</sup>, SRI YULIASMI<sup>2</sup>, DADANG IRFAN HUSORI<sup>1</sup>, POPI PATILAYA<sup>3</sup>, LIA LAILA<sup>4</sup>

<sup>1</sup>Department of Pharmacology Pharmacy, Faculty of Pharmacy, Universitas Sumatera Utara, Padang Bulan, Medan 20155, Indonesia.

<sup>2</sup>Department of Pharmaceutical Chemistry, Faculty of Pharmacy, Universitas Sumatera Utara, Padang Bulan, Medan 20155, Indonesia.

<sup>3</sup>Department of Pharmaceutical Biology, Faculty of Pharmacy, Universitas Sumatera Utara, Padang Bulan, Medan 20155, Indonesia.

<sup>4</sup>Department of Pharmaceutical Technology, Faculty of Pharmacy, Universitas Sumatera Utara, Padang Bulan, Medan 20155, Indonesia.

Email: uripharahap@usu.ac.id

Received: 13 April 2017, Revised and Accepted: 13 July 2017

### ABSTRACT

**Objective:** The aim of this study is to observe the activity of ethanol extract of *Curanga fel-terrae* leave in preventing the damaged of liver which is induced by high dose of paracetamol.

**Methods:** This research was conducted using Wistar rat divided into six groups. Group 1 was the normal group. Groups 2, 3, 4, 5, and 6 received carboxymethyl cellulose-Na 0.5% (negative control), *C. fel-terrae* ethanolic extract (CFEE) at the doses of 125, 250 and 500 mg/kg, catechin 2 mg/kg (positive control), respectively, during 7 days continued and followed by given paracetamol dose of 2.5 g/kg 8 hrs. After that, hepatoprotective activity was carried out toward parameter of aspartate aminotransferase (AST), alanine aminotransferase (ALT) as well as histopathology of the liver.

**Results:** The results showed that high dose paracetamol dose of 2.5g/kg bw can cause liver damaged which can be seen by the increasing of the level of AST and ALT compared to the normal group ( $p < 0.05$ ). The usage of three doses of CFEE for 7 days showed the prevention of the increasing of the level of AST and ALT compared to negative control group ( $p < 0.05$ ). Furthermore, the histopathology study revealed that the three doses of extract could protect the liver.

**Conclusion:** The CFEE at the doses of 125, 250 and 500 mg/kg bw which was given for 7 days can prevent the liver from the damage caused by a high dose of paracetamol.

**Keywords:** *Curanga fel-terrae* (Lour.) Merr., Paracetamol, Liver, Hepatoprotective.

© 2017 The Authors. Published by Innovare Academic Sciences Pvt Ltd. This is an open access article under the CC BY license (<http://creativecommons.org/licenses/by/4.0/>) DOI: <http://dx.doi.org/10.22159/ajpcr.2017.v10i11.19127>

### INTRODUCTION

The liver plays an important role in body metabolism activity, which is the main organ for detoxification. The liver can experience damage which caused by some toxic chemicals and drugs, therefore it could be a very serious problem [1]. Herbal drugs have been known to have a significant role in some diseases treatments. The research of effective hepatoprotective drug has been continued although some of the herbal drugs had been reported could accelerate the natural healing process of liver disease [2].

In this world, particularly Indonesia has the variety of plants which is a potential source in the finding of the new drug, especially as marker compound [3]. One group of the plant which has potential as the source of the new drug is *Scrophulariaceae* family. The pharmacological activity investigation to this family included antiviral [4-6], antimicrobials [7,8], antioxidant [7,9], analgesic [4,10], anti-inflammation [4,11,12], immunomodulator [11], antidepressant [13], diuretic [4,14], antidiabetic [4,15], antimalarial, anticancer, inotropic [4], hepatoprotective [16], antispasmodic, anticholinesterase, antiulcerogenic, antileishmanial [17], antiarrhythmic [18], and antitumor [19].

Pugun tano (*Curanga fel-terrae* (Lour.) Merr.) is a plant from *Scrophulariaceae* family which grow in Asian regions such as China, India, Indonesia, Philippine, Malaysia, and Myanmar. In Indonesia, this plant is spread in Sumatera, Java, Kalimantan, and Maluku [20]. Some researchers showed that this plant contained glycoside [21,22], flavonoid [23], saponin [24], terpenoid [25], curangin, and bitter compound [26]. The pharmacological activity of this plant also has been studied such as anthelmintic [27], antidiabetic [28], anti-breast

cancer [29-31], diuretic effect [32], cardioprotective effect [33], and antimuscarinic receptor [34]. In this study, the effect of ethanol extract of pugun tano was examined for the hepatoprotective activity since this plant in *Scrophulariaceae* family.

### METHODS

#### Plant materials

Pugun tano (*C. fel-terrae* (Lour.) Merr.) plant was collected from Pancur Batu Subdistrict, Deli Serdang District, North Sumatera Province. Taxonomic identification was made from Biology Research Centre of Herbarium Bogoriense. A voucher specimen (No:1553/IPH.1.02/ if.8/IX/2013) has been deposited at the herbarium of the Botany Department.

#### Plant extraction

The leaves were washed and dried at 30-35°C, then ground until dried powder was obtained. The dried powder was percolated using 96% ethanol then the obtained crude extract was evaporated and kept at 4°C refrigerator.

#### Animals

The animals used in this study were male Wistar rats (150-200 g). The rats were bred in the colony in the Animal House of Faculty of Pharmacy (University of Sumatera Utara). They were fed a standard pellet diet and water *ad libitum*. Before their use in the experiment, rats were kept in standard environment condition. Ethical clearance was obtained from Animal Research Ethics Committee, University of Sumatera Utara (approved number: 100/KEPH-FMIPA/2014) before initiating the experiments.

**Hepatoprotective activity**

The animals were divided into six groups, and each group consisted of five animals. The hepatoprotective activity of the extract was examined using a high dose of paracetamol (2.5 g/kg bw) as hepatotoxicity inducer. The tested extract was given for 7 days, and then paracetamol was given at day 8. The experiment groups were tabulated in Table 1.

**Biochemistry measurement parameter**

On the day 9 or 24 hrs after paracetamol had been given, blood and livers were taken from all animals. The obtained blood was centrifuged and serum was taken, then aspartate aminotransferase (AST) and alanine aminotransferase (ALT) measurements were conducted at Health Laboratorium Bureau, Medan.

**Liver histopathology**

Livers from the experiment animals were taken and immersed in 10% formalin buffer. The livers were processed using the routine histology procedure and made a section with 4-6 µm widths. The tissues were stained with hematoxylin-eosin and observed under a microscope.

**Data analysis**

The results were expressed as a mean value±standard error of mean. Analysis of variance was used to compare the results of experiments. The significance of the interactions between groups was determined using Tukey HSD *post hoc* test with the p<0.05 considered to be significant.

**RESULTS AND DISCUSSION**

**Effect of *C. fel-terrae* ethanolic extract (CFEE) on ALT level**

ALT is enzyme normally most distributed in the liver cell. In ALT measurement, liver positively damages if the number of this enzyme in plasma more than the normal level. The result of ALT level after treatments for each group can be seen in Table 2.

**Table 1: Group of treatments**

Group	Treatment
I	Animals were given standard food and water <i>ad libitum</i> without tested extract and paracetamol (normal control)
II	Animals were given CMC-Na for 7 days and paracetamol on day 8 (negative control)
III	Animals were given CFEE with a dose of 125 mg/kg bw for 7 days and paracetamol on day 8
IV	Animals were given CFEE with a dose of 250 mg/kg bw for 7 days and paracetamol on day 8
V	Animals were given CFEE with a dose of 500 mg/kg bw for 7 days and paracetamol on day 8
VI	Animals were given catechin with dose of 2 mg/kg bw for 7 days and paracetamol on day 8 (positive control/reference)

CFEE: *Curanga fel-terrae* ethanolic extract, CMC: Carboxymethyl cellulose

**Table 2: ALT level after extract treatment and high dose paracetamol induction.**

Group	ALT level (U/L)
Normal	38.60±3.172 <sup>a</sup>
Negative control (CMC-Na)	330.00±139.421
CFEE 125 mg/kg	71.00±9.778 <sup>ab</sup>
CFEE 250 mg/kg	71.40±11.847 <sup>ab</sup>
CFEE 500 mg/kg	46.20±9.107 <sup>ab</sup>
Positive control (catechin 2 mg/kg)	47.00±11.305 <sup>ab</sup>

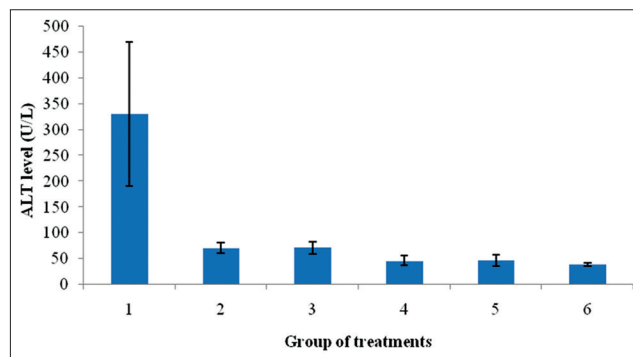
<sup>a</sup>Significant difference with negative control (p<0.05). <sup>b</sup>Not significant difference with normal group (p≥0.05). Data were presented as mean±standard error of mean (n=5). CFEE=*Curanga fel-terrae* ethanol extract, CMC: Carboxymethyl cellulose, ALT: Alanine aminotransferase

Based on Fig. 1, it showed that the negative control group (given carboxymethyl cellulose [CMC]-Na only for 7 days before high dose paracetamol) had a very significant increase of ALT level compared to the normal group. It showed that the given of high dose paracetamol caused liver damage. Liver damage leads to high level of serum markers in the blood, among these, AST, ALT represents 90% of total enzyme, and high level of ALT in the blood is a better index of liver damage [35]. The given of CFEE with doses of 125, 250 and 500 mg/kg BW did not show a significant increase of ALT level compared to normal group (p≥0.05) and significantly different with negative control (p<0.05). It showed that all the doses of CFEE could inhibit the liver damage.

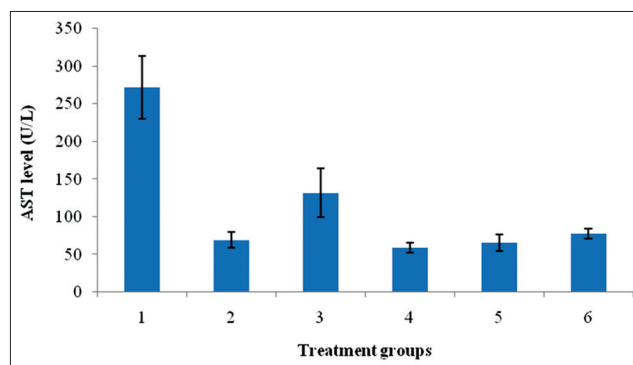
**Effect of CFEE on AST level**

AST or aspartate aminotransferase is an enzyme normally found in liver and heart. AST is released into the blood stream if liver or heart experiences damage. Based on the experiment, the AST level for each group after treatment was shown in Table 3.

Based on Table 3 and Fig. 2, the tested animals are given CFEE with doses of 125, 250 and 500 mg/kg BW could inhibit the increase of AST level caused by high dose paracetamol induction. A very well inhibition was occurred and significantly difference with the negative control group (p<0.05). Although the extract treatment groups had shown similar AST level with the normal control group (p≥0.05), it could be said that the CFEE could protect the liver cells from the damage induced by high dose paracetamol. While the increase of CFEE dose from 125 to 250 and 500 mg/kg did not show a significant effect. All doses had similar strength to protect the liver.



**Fig. 1: Alanine aminotransferase level of the treatment groups after *Curanga fel-terrae* ethanolic extract (CFEE) and high dose paracetamol given. 1 - Negative control, 2 - CFEE of 125 mg/kg, 3 - CFEE of 250 mg/kg, 4 - CFEE of 500 mg/kg, 5 - Catechin 2 mg/kg, and 6 - Normal group**

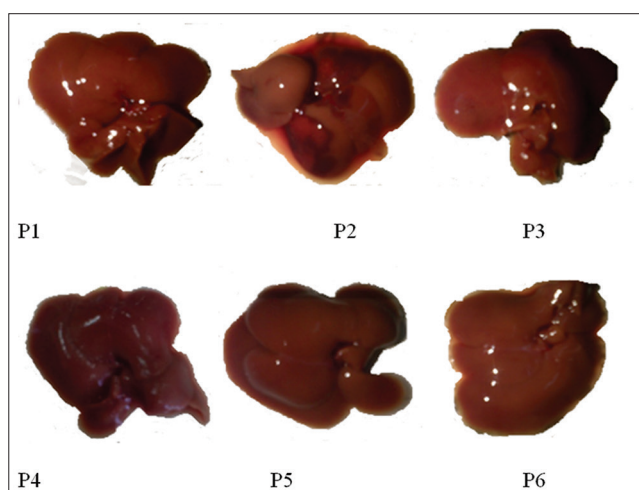


**Fig. 2: Aspartate aminotransferase level of the treatment groups after *Curanga fel-terrae* ethanolic extract (CFEE) and high dose paracetamol were given. 1 - Negative control, 2 - CFEE of 125 mg/kg bw, 3 - CFEE of 250 mg/kg bw, 4 - CFEE of 500 mg/kg BW, 5 - Catechin 2 mg/kg bw, and 6 - Normal group**

In this study, rats were given with a high dose of paracetamol, 2.5 g/kg BW. Paracetamol was metabolized in the liver resulting radical metabolite which is called N-acetyl-p-benzoquinone imine (NAPQI). In normal condition, NAPQI will be rapidly detoxed by the glutathione from the liver. However, in the high dose of paracetamol, the liver will not be able to detox the excessive NAPQI. The radical metabolite will damage the liver. Antioxidant activity from various secondary metabolite in the plant like pugun tano is expected to stimulate the endogen antioxidant like glutathione. Glutathione with the assistance of glutathione-S-transferase enzyme could conjugate the reactive paracetamol metabolite, NAPQI, by bonding with the sulfhydryl group to form unradical compounds such as mercapturic acid and cysteine conjugate.

Beside the endogen antioxidant enhancement mechanism, the plant secondary metabolite could also protect the liver from various ways. One of the flavonoids from seed and fruit of *Silybum marianum* (Compositae) called silymarin had been known the mechanism in protecting the liver. Silymarin was reported could increase the hepatocyte proliferation in damage liver [36]. Furthermore, this compound could control the permeability and integrity of cell membrane, inhibited the leukotriene and reactive oxygen species entrapping, suppressed the nuclear factor-κB activity, and several other mechanisms [37]. Therefore, pugun tano with the high content of the flavonoids is suggested to be able to protect the liver by the same mechanism like silymarin.

Apart from flavonoid, glycoside also had a role in protecting the liver. The mechanism was assumed by the conjugation of the first phase metabolite with the sugar molecule which will be easily eliminated from the body.



**Fig. 3: Macroscopic of rat liver organ. P1 - Normal rat liver, P2 - Negative control rat liver, P3 - Positive control rat liver, P4 - 125 mg/kg bw *Curanga fel-terrae* ethanol extract (CFEE) rat liver, P5 - 250 mg/kg bw CFEE rat liver, P6 - 500 mg/kg bw CFEE rat liver**

**Table 3: AST level after extract treatment and high dose paracetamol induction**

Kelompok	AST level (U/L)
Normal	77.40±6.875 <sup>a</sup>
Negative control (CMC-Na)	271.80±41.470
CFEE 125 mg/kg	69.20±10.632 <sup>ab</sup>
CFEE 250 mg/kg	132.00±32.862 <sup>ab</sup>
CFEE 500 mg/kg	59.00±6.434 <sup>ab</sup>
Positive control (catechin 2 mg/kg)	65.40±10.652 <sup>ab</sup>

<sup>a</sup>Significant difference with negative control (p<0.05). <sup>b</sup>Not significant difference with normal group (p≥0.05). Data were presented as mean±standard error of mean (n=5). CFEE=*Curanga fel-terrae* ethanol extract, CMC: Carboxymethyl cellulose, AST: Aspartate aminotransferase

**Effect of CFEE on liver organ**

The macroscopical observation of liver organ showed the difference between the normal, negative control, positive control and CFEE with doses of 125, 250 and 500 mg/kg group included the color and texture of liver. The results were presented in Table 4 and Fig. 3.

**Histopathology result for liver tissue**

Histopathology observation was done on day 8 or 24 hrs after paracetamol had been given. The rats were neck dislocated then the livers were taken. This observation result was used to determine the level of liver cells damage caused by paracetamol and the hepatoprotective effect of the given extract (CFEE). Through this histopathology observation, it could be seen the tissue damage which could not be determined by macroscopical observation.

It can be seen in Table 5 that the normal, positive control and CFEE doses of 125, 250 and 500 mg/kg BW group showed no hepatocyte damage, while the negative control group showed the hydropic degeneration and necrotic. It showed that the given of 2 g/kg BW paracetamol could damage the liver through the NAPQI metabolite formation and the decrease of liver glutathione level, therefore the liver macromolecule cell bonding by NAPQI metabolite occurred whereby damage the liver cell. The results of liver histopathology could be seen in Fig. 4.

Normal group (P1) showed normal central vein. Central vein is a vein surrounded by compact endothelium cell and located at central lobule with circled hepatocyte to the central vein. In the hepatocyte, there is complete cytoplasm with circle nucleus. Along the hepatocyte, there is blood vessel as a place for blood to flow then will be collected by central vein. The negative control group (P2) showed an indication of liver structure damage which assigned by the congested central vein caused by the endothelium cell lysis, therefore the circle became incomplete and at the end became unclear. The damage to the central vein related to its function on the circulation, whereby the central vein received blood from the blood vessels. Therefore, the central vein will collect most of the toxic or non-toxic nutrients and metabolites. The more volume of blood collected by central vein will cause the toxic substances concentration

**Table 4: Macroscopically observation of liver tissue after treatment for each group**

Treatment	Macroscopic of liver	
	Color	Texture
Normal	Red	Smooth
Negative control (CMC-Na)	Pale red with black spot	Smooth
CFEE 125 mg/kg	Pale red with brown-black spot	Smooth
CFEE 250 mg/kg	Dark red with red spot	Smooth
CFEE 500 mg/kg	Red	Smooth
Positive control (catechin 2 mg/kg)	Dark red	Smooth

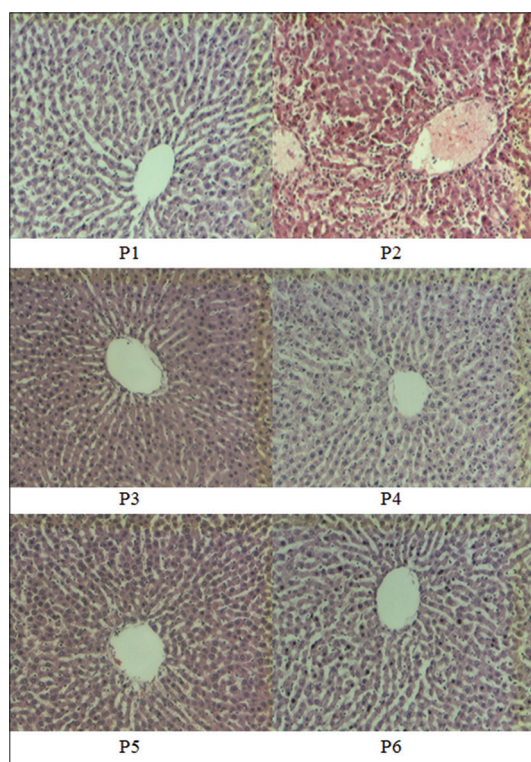
CFEE: *Curanga fel-terrae* ethanol extract, CMC: Carboxymethyl cellulose

**Table 5: Histopathology result based on hepatocyte damage**

Group	Type of hepatocyte damage	
	Hydropic degeneration	Necrotic
P1	-	-
P2	+	+
P3	-	-
P4	-	-
P5	-	-
P6	-	-

P1: Normal, P2: Negative control, P3, P4, P5: Doses of 125, 250 and 500 mg/kg bw CFEE, P6: Positive control. -: Normal, +: Damage, CFEE: *Curanga fel-terrae* ethanol extract





**Fig. 4:** Rat liver histopathology after the treatment for each group. P1 - Normal rat liver, P2 - Negative control rat liver, P3 - 125 mg/kg bw *Curanga fel-terrae* ethanolic extract (CFEE) rat liver, P4 - 250 mg/kg bw CFEE rat liver, P5 - 500 mg/kg bw CFEE rat liver, P6 - Positive control rat liver

higher than it will damage the central vein. In the hepatocyte cell, it was seen the liver cell also occurred necrotic which had shown by the small nuclei and black in color (pyknotic nuclei), lysis nuclei (carcys), and destroy nuclei (karyolysis). The P2 group showed the hydropic degeneration cell. The cell inflamed and the vacuole became large. This phenomenon was aligned with the theory which stated that the hydropic degeneration was the first sign of cell damage because the cell membrane permeability disruption caused by the decrease of ATP number. The figure of liver histology of positive control group (P3), CFEE with doses of 125, 250 and 500 mg/kg bw (P4, P5, and P6) did not show a significant damage compared to the negative control group. The histological changes induced by paracetamol treatment as evidenced by the congested central vein and hepatic necrosis and its protection to normalcy by the treatment with the plant extract were indicative of the hepatoprotection of the extract [38]. It proved that the CFEE could protect the liver from damage and had hepatoprotective activity on rat liver induced by paracetamol.

## CONCLUSION

This study concluded that pugun tano ethanolic extract had hepatoprotective activity with the parameter of ALT and AST level inhibition in rat liver induced by high dose paracetamol.

## ACKNOWLEDGMENT

This research was supported by Fundamental Research Grant from DIPA University of Sumatera Utara year 2014 No. 1084/UN5.1.R/KEU/2014.

## REFERENCES

- Vadivu R, Suresh AJ, Girinath K, Kannan PB, Vimala R, Kumar NS. Evaluation of hepatoprotective and *in-vitro* cytotoxic activity of leaves of *Premna serratifolia* Linn. J Sci Res 2008;24:145-52.

- Singh DW, Mehta S, Neoliya NK, Shukla YN, Mishra M. Hepatoprotective activity of *Sarcostemma brevistigma* against carbon tetrachloride-induced hepatic damage in rats. Curr Sci 2003;10:22.
- Kobarfard F. Tuberculosis and traditional medicine: Fighting the oldest infectious disease using the oldest source of medicines. Iran J Pharm Res 2004;3:71-2.
- Murti K, Panchal M, Taya P, Singh R. Pharmacological properties of *Scoparia dulcis*: A review. Pharmacologia 2012;3:344-7.
- Ivancheva S, Nikolova M, Tsvetkova R. Pharmacological activities and biologically active compounds of Bulgarian medicinal plants. In: Filippo I, editor. Phytochemistry: Biologically Active Compounds. Kerala, India: Research Signpost; 2006. p. 87-103.
- Bermejo P, Abad MJ, Diaz AM, Fernández L, De Santos J, Sanchez S, et al. Antiviral activity of seven iridoids, three saikosaponins and one phenylpropanoid glycoside extracted from *Bupleurum rigidum* and *Scrophularia scorodonia*. Planta Med 2002;68(2):106-10.
- Ozcan B, Yilmaz M, Caliskan M. Antimicrobial and antioxidant activities of various extracts of *Verbascum antiochium* Boiss. (*Scrophulariaceae*). J Med Food 2010;13(5):1147-52.
- Guarino C. Antimicrobial activity of *Verbascum macrurum* Ten. (*Scrophulariaceae*). Boll Chim Farm 2002;141(3):238-42.
- Cervellati R, Speroni E, Govoni P, Guerra MC, Costa S, Arnold UW, et al. *Wulfenia carinthiaca* Jacq. Antioxidant and pharmacological activities. Z Naturforsch C 2004;59(3-4):255-62.
- Pal D, Nandi M. CNS activities of *Celestia coromandeliana* Vahl. in mice. Acta Pol Pharm 2005;62(5):355-61.
- Smit HF, Kroes BH, van den Berg AJ, van der Wal D, van den Worm E, Beukelman CJ, et al. Immunomodulatory and anti-inflammatory activity of *Picrorhiza scrophulariiflora*. J Ethnopharmacol 2000;73(1-2):101-9.
- Fernández MA, Sáenz MT, García MD. Anti-inflammatory activity in rats and mice of phenolic acids isolated from *Scrophularia frutescens*. J Pharm Pharmacol 1998;50(10):1183-6.
- Sairam K, Dorababu M, Goel RK, Bhattacharya SK. Antidepressant activity of standardized extract of *Bacopa monniera* in experimental models of depression in rats. Phytomedicine 2002;9(3):207-11.
- Navarro E, Alonso PJ, Alonso SJ, Trujillo J, Pérez C, Toro MV, et al. Cardiovascular activity of a methanolic extract of *Digitalis purpurea* spp. *heywoodii*. J Ethnopharmacol 2000;71:437-42.
- Okhale SE, Amanabo MO, Jegede IA, Egharevba HO, Muazzan IW, Kunle OF. Phytochemical and pharmacognostic investigation of antidiabetic *Scoparia dulcis* Linn. *Scrophulariaceae* whole plant grown in Nigeria. Researcher 2010;2:7-16.
- Lee EJ, Kim SR, Kim J, Kim YC. Hepatoprotective phenylpropanoids from *Scrophularia buergeriana* roots against  $\text{CCl}_4$ -induced toxicity: Action mechanism and structure-activity relationship. Planta Med 2002;68:407-11.
- Bammidi SR, Volluri SS, Chippada SC. A review on pharmacological studies of *Bacopa monniera*. J Chem Biol Phys Sci 2011;1:250-9.
- Hossain H, Howlader MS, Dey SK, Hira A, Ahmed A. Evaluation of analgesic, antiarrhoeal and cytotoxic activities of ethanolic extract of *Bacopa monnieri* (L). Br J Pharm Res 2012;2:188-96.
- Vasconcellos MC, Bezerra DP, Fonseca AM, Pereira MR, Lemos TL, Pessoa OD, et al. Antitumor activity of biflorin, an o-naphthoquinone isolated from *Capraria biflora*. Biol Pharm Bull 2007;30(8):1416-21.
- van Valkenburg JL, de Padua LS, Bunyapraphatsara N, Lemmens RH. Medicinal and Poisonous Plants. Part 2. Leiden, Netherlands: Backhuys, The University of Michigan; 2001.
- Zou JM, Wang LS, Ma XM, Shi RB, Guo YJ. Isolation and identification of a new cucurbitacin from *Picria fel-terrae*. Yao Xue Xue Bao 2004;39(11):910-2.
- Huang YDe Bruyne T, Apers SMA, YClaeys M, van den Berghe DHuang Y, De Bruyne T, Apers S, Ma Y, Claeys M, Vanden Berghe D, et al. Complement-inhibiting cucurbitacin glycosides from *Picria fel-terrae*. J Nat Prod 1998;61(6):757-61.
- Huang Y, de Bruyne T, Apers S, Ma Y, Claeys M, Pieters L, et al. Flavonoid glucuronides from *Picria fel-terrae*. Phytochemistry 1999;62:1701-3.
- Fang H, Ning DS, Liang XY. Studies on technology optimization for extracting triterpenoid saponins from *Picria felterrae* by multi-target grading method. Zhong Yao Cai 2009;32(12):1902-5.
- Wang LS, Li SH, Zou JM, Guo YJ, Sun HD. Two new triterpenoids from *Picria fel-terrae*. J Asian Nat Prod Res 2006;8(6):491-4.
- AgroMedia R. Buku Pintar Tanaman Obat. Cetakan 1. Jakarta: Agromedia Pustaka; 2008.
- Patilaya P, Husori DI. Preliminary study on the anthelmintic activity of the leaf ethanolic extract of Indonesian *Curanga fel-terrae* (Lour.)

- Merr. Int J Pharm Technol Res 2015;8:347-51.
28. Sitorus P, Harahap U, Pandapotan M, Barus T. Isolation of  $\beta$ -sitosterol from n-hexane extract of *Picria fel-terrae* Lour. Leave and study of its antidiabetic effect in alloxan induced diabetic mice. Int J Pharm Technol Res 2014;6:137-41.
  29. Lestari P, Hadisahputra S, Ilyas S, Satria D. Combinational effects of n-hexane extract of poguntano leaves (*Picria fel-terrae* Lour.) with doxorubicin on MCF-7 breast cancer cells. J Chem Pharm Res 2015;7:353-5.
  30. Satria D, Furqan M, Hadisahputra S, Rosidah. Combinational effects of ethylacetate extract of *Picria fel-terrae* Lour and doxorubicin on T47D breast cancer cells. Int J Pharm Pharm Sci 2015;7:73-6.
  31. Furqan M, Hadisahputra S, Rosidah. Effects of inhibition cell cycle and apoptosis of poguntano leaves ethylacetate extract (*Picria fel-terrae* Lour.) on breast cancer cells. Int J Pharm Technol Res 2014;6:1096-9.
  32. Dalimunthe A, Harahap U, Rosidah G, Pandapotan NM. Evaluation of diuretic activity of *Picria fel-terrae* Lour leaves extracts. Asian J Pharm Clin Res 2015;8:204-5.
  33. Sihotang Y, Silalahi J, Hadisahputra S, Anjelisa P, Satria D. Cardioprotective effect of ethylacetate extract of poguntano (*Picria fel-terrae* Lour.) against doxorubicin-induced cardiotoxicity in rats. Int J Pharm Clin Res 2016;8:466-70.
  34. Harahap U, Husori DI, Marianne, Yuliasmi S, Patilaya P, Laila L, et al. Inhibitory effect of ethanolic extract of *Curanga fel-terrae* (pugun tano) leaves on acetylcholine muscarinic-3 receptors induced on isolated guinea pig tracheal. Asian J Pharm Clin Res 2017;10:95-8.
  35. Sivakrishnan S, Kottaimuthu A. Hepatoprotective activity of ethanolic extract of aerial parts of *Albizia procera* Roxb (Benth.) against paracetamol induced liver toxicity on Wistar rats. Int J Pharm Pharm Sci 2014;6(1):233-8.
  36. Freitag AF, Cardia GF, da Rocha BA, Aguiar RP, Silva-Comar FM, Spironello RA, et al. Hepatoprotective effect of silymarin (*Silybum marianum*) on hepatotoxicity induced by acetaminophen in spontaneously hypertensive rats. Evid Based Complement Alternat Med 2015;2015:538317.
  37. He Q, Kim J, Sharma RP. Silymarin protects against liver damage in BALB/c mice exposed to fumonisin B1 despite increasing accumulation of free sphingoid bases. Toxicol Sci 2004;80(2):335-42.
  38. Latha B, Latha MS. Antioxidant and curative effect of *Leucas aspera* methanolic extract against carbon tetra chloride induced acute liver injury in rats. Int J Pharm Pharm Sci 2013;5(4):374-8.