

Exacerbation of Psoriasis under Efalizumab Therapy

Efstathios Rallis, Constantinos Verros, Evmorfia Karanikola, Argyro Valaskatzi, and Markos Papaconstantis

Background: Efalizumab is a recombinant humanized IgG1 kappa isotype monoclonal antibody that binds to CD11a, inhibiting T-cell activation. It has been approved for the treatment of moderate to severe plaque psoriasis. Efalizumab has been associated with the development of skin eruptions during the administration period, and this probably represents the potential psoriasis events observed during its administration.

Objective: We report a case of exacerbation of psoriasis under efalizumab administration. A reversible increase in lymphocyte count with normal total white blood cell count was also noticed.

Conclusion: Larger series are probably needed to establish clinical and histopathologic criteria and to determine the terminology used regarding the psoriasis adverse events seen with efalizumab treatment.

Antécédents: L'efalizumab est un anticorps monoclonal humanisé recombinant de type IgG1 kappa qui se lie à la sous-unité CD11a inhibant ainsi l'activation des lymphocytes T. L'utilisation de l'efalizumab a été approuvée dans le traitement des plaques de psoriasis modéré à grave. Des éruptions cutanées, associées à des poussées de psoriasis, peuvent survenir durant le traitement.

Objectif: Nous rapportons un cas d'exacerbation du psoriasis durant un traitement à l'efalizumab. On a également noté une augmentation réversible des lymphocytes avec un niveau normal de leucocytes.

Conclusion: Des cas additionnels sont probablement nécessaires pour établir les critères cliniques et histopathologiques et déterminer la terminologie utilisée pour décrire les événements de psoriasis indésirables durant un traitement à l'efalizumab.

EFALIZUMAB is a recombinant humanized IgG1 kappa isotype monoclonal antibody that binds to CD11a, the alpha subunit of lymphocyte function-associated antigen 1, inhibiting T-cell activation. It has been approved for the treatment of moderate to severe plaque psoriasis and is currently administered as a weekly subcutaneous injection.^{1,2}

Efalizumab has been associated with the development of skin eruptions during the administration period; however, the terminology of these eruptions varies and has not been determined. We present a case of exacerbation of psoriasis that occurred under efalizumab therapy.

Case Report

A 22-year-old male with psoriasis recalcitrant to topical treatment, acitretin, and cyclosporine was referred to our clinic. The disease initially involved the scalp, the trunk (Figure 1), and the extremities. He was informed about

efalizumab treatment and was started on weekly subcutaneous injections (0.7 mg/kg; body weight 60.4 kg).

The disease seemed to respond during the first 2 weeks of administration; however, approximately 6 weeks after the initial injection of efalizumab, the development of a few new, erythematous, scaly, psoriatic lesions was observed. An increase in lymphocyte count with normal total white blood cell was also noticed. The new lesions developed on previously unaffected areas of the trunk and extremities, whereas the initial ones deteriorated (Figure 2). Pustular lesions were not observed, and no signs of underlying infections were noticed at that time.

A 3 mm punch biopsy was taken from a new lesion of the trunk, and a histologic examination showed acanthosis of the epidermis with regularly elongated and club-shaped rete ridges, absence of a granular layer, thin suprapapillary epidermal plates, elongation and edema of the dermal papillae with tortuous capillaries, and confluent parakeratosis with pyknotic nuclei of neutrophils (Munro microabscess) (Figure 3). These findings were compatible with psoriasis. No immunohistochemical examination was performed.

The weekly dose of efalizumab was then increased to 1.0 mg/kg of body weight, topical corticosteroids were applied, and the new psoriatic lesions initially improved.

From the Departments of Dermatology and Pathology, Army General Hospital, Athens, Greece; and Private practice, Tripolis, Greece.

Address reprint requests to: Efstathios Rallis, 11 Pafsaniou Str, GR-11635, Athens, Greece; e-mail: efrall@otenet.gr.

DOI 10.2310/7750.2008.07087

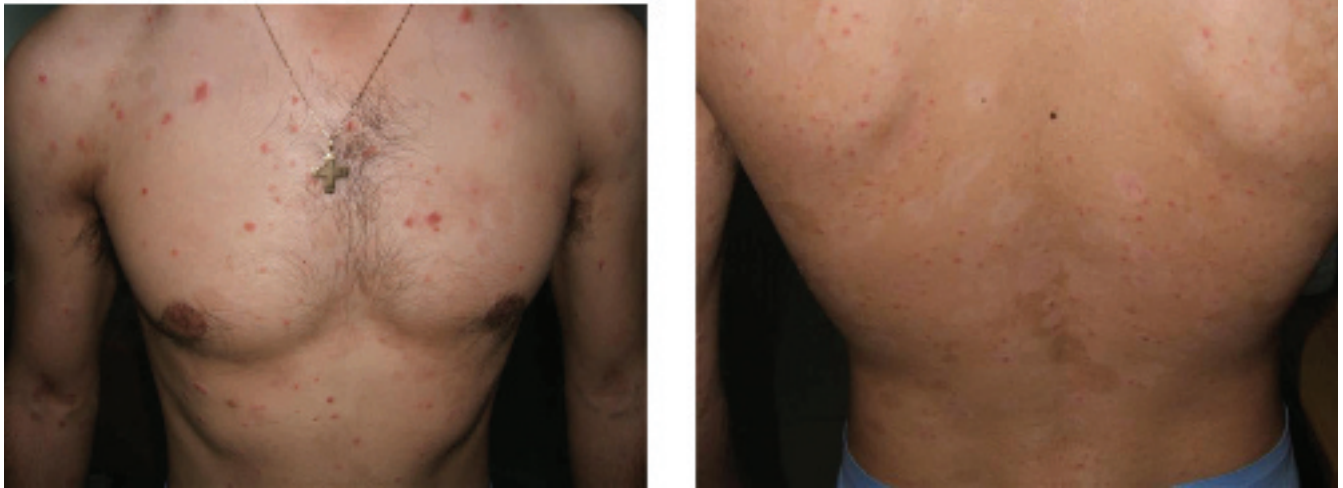

Figure 1. This is the third week after the initiation of efalizumab. No meaningful response is seen.

2

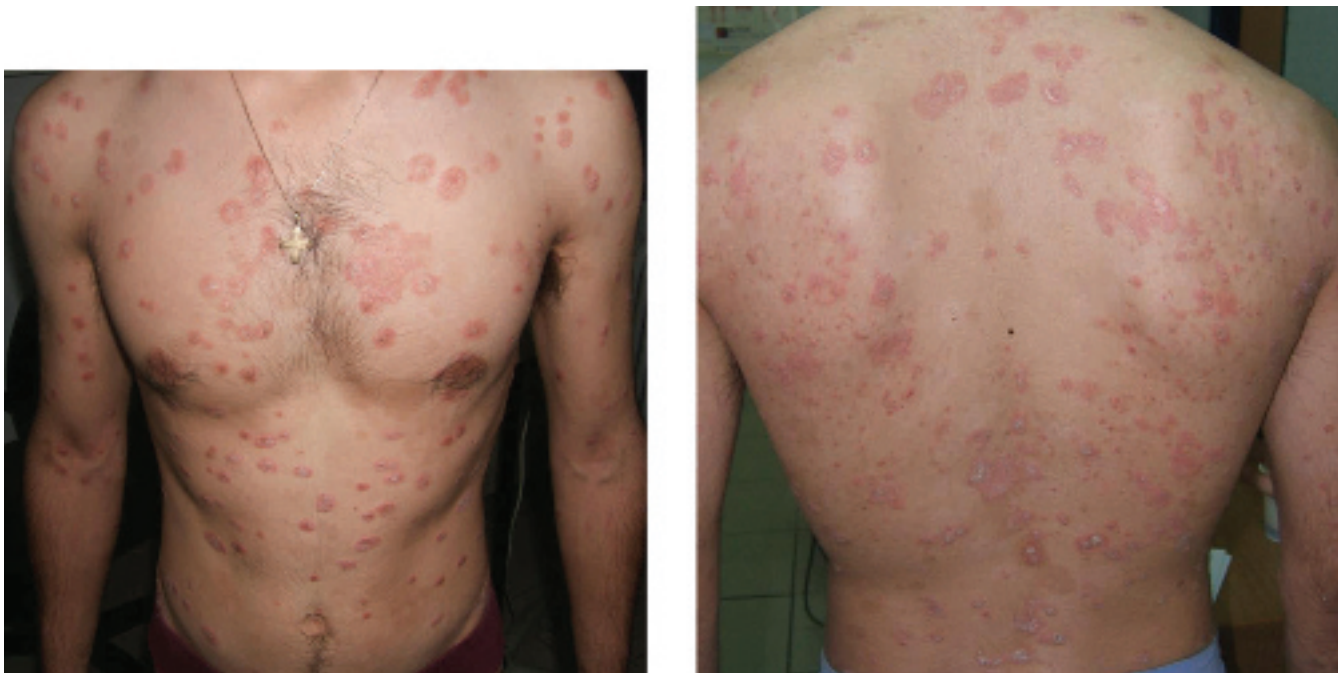

Figure 2. This is the eleventh week of treatment with efalizumab. The exacerbation of papular psoriasis can be noticed by comparison with Figure 1.

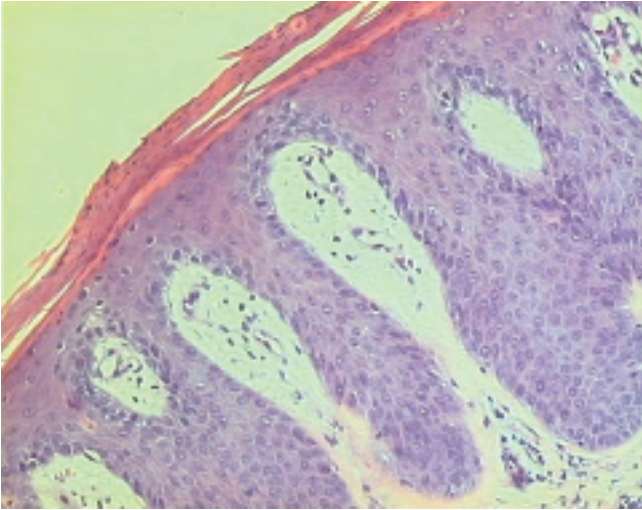


Figure 3. Histopathologic features consistent with psoriasis (hematoxylin-eosin stain; $\times 100$ original magnification).

However, they soon relapsed, gradually increasing in number and involving the patient's face.

After 12 weeks of continuous administration with efalizumab, no response was seen, efalizumab was discontinued, and methotrexate 25 mg once a week was initiated. Improvement was noticed after the first two doses, and the increase in lymphocyte count returned to the normal range.

Discussion

Efalizumab (Raptiva) is a targeted T-cell modulator that has demonstrated safe and long-term efficacy in patients with chronic plaque psoriasis.³ Health-related quality of life has also been significantly improved in patients receiving efalizumab.

The most common side effects of this drug include headache, chills, fever, nausea, and myalgia within 2 days following the first two injections; arthralgia, arthritis, peripheral edema, and rebound flare reaction after the cessation; reversible increases in lymphocyte count and total white blood cell; immunomediated thrombocytopenia; hemolytic anemia; and hypersensitivity reaction.^{1,2}

Two types of cutaneous responses during efalizumab therapy have been described: a transient localized papular eruption (localized mild breakthrough) and a generalized inflammatory exacerbation.⁴ Hassan and colleagues described the four cases of efalizumab-associated papular psoriasis as similar to localized mild breakthrough but with a longer course.⁵ It seems that localized mild breakthrough, generalized inflammatory exacerbation,

and efalizumab-associated papular psoriasis probably represent the potential psoriasis events observed during efalizumab administration.⁶

Erythrodermic or pustular psoriasis as a rebound phenomenon has been well documented in approximately 1.2 to 5% of patients after the discontinuation of efalizumab and is more commonly observed in patients with a lower Psoriasis Area and Severity Index response to therapy (nonresponders).^{2,6} Efalizumab has also been associated with psoriatic arthritis and infrequent new onset or recurrent severe arthritis in clinical trials and postmarketing surveillance.²

In our case, based on histologic examination, an exacerbation of psoriasis was noticed during efalizumab administration. Although the noninflammatory nature of psoriasis worsening and the subsequent response to methotrexate is more compatible with inadequate therapy in a patient experiencing normal deterioration of psoriasis and not with efalizumab-induced psoriasis, efalizumab administration did not prove to be helpful.

Efalizumab-associated psoriatic flare has been reported to be treated with narrowband ultraviolet B phototherapy or methotrexate without discontinuation of efalizumab therapy.^{7,8} However, in cases analogous to ours, close monitoring or even cessation of the medication should be seriously considered. A well-known, reversible increase in the circulating lymphocyte count was also observed in our patient, and it is speculated that this adverse reaction may be associated with psoriasis flare.⁵

The induction of papular, psoriatic lesions on clinically uninvolved skin in patients with psoriasis under other than efalizumab systemic therapies is not uncommon. It has been reported with the administration of anti-tumor necrosis factor blockers (adalimumab, etanercept, and infliximab),^{9,10} the abrupt cessation of methotrexate¹¹ or cyclosporine,^{12,13} and the withdrawal of systemically administered corticosteroids.¹⁴

Our case highlights the importance of observing and reporting serious side effects associated with biologic agents. Larger series are probably needed to establish clinical and histopathologic criteria and to determine the terminology used regarding the psoriasis adverse events seen with efalizumab treatment.

References

1. Papp KA, Camisa C, Stone SP, et al. Safety of efalizumab in patients with moderate to severe chronic plaque psoriasis: review of clinical data. Part II. *J Cutan Med Surg* 2005;9:313–23.

2. Scheinfeld N. Efalizumab: a review of events reported during clinical trials and side effects. *Expert Opin Drug Saf* 2006;5:197–209.
3. Gupta AK, Cherman AM. Efalizumab in the treatment of psoriasis. *J Cutan Med Surg* 2006;10:57–68.
- 3 4. Carey W, Glazer S, Gottlieb AB, et al. Relapse, rebound and psoriasis adverse events: an advisory group report. *J Am Acad Dermatol* 2006;54:S171–81.
5. Hassan AS, Simon D, Simon HU, et al. Efalizumab-associated papular psoriasis. *Arch Dermatol* 2007;143:900–6.
6. Raptiva [efalizumab] [package insert]. South San Francisco (CA): Genentech Inc; June 2005.
7. Carrascosa JM, Soria X, Ferrándiz C. Effective management of a psoriatic flare with narrowband UVB phototherapy during efalizumab therapy without discontinuing treatment. *J Eur Acad Dermatol Venereol* 2007;21:828–9.
8. Gisoni P, Giglio MD, Girolomoni G. Effective management of psoriasis symptom worsening during efalizumab therapy without discontinuing treatment: a case study. *J Dermatolog Treat* 2006;17: 172–5.
9. Goiriz R, Daudén E, Pérez-Gala S, et al. Flare and change of psoriasis morphology during the course of treatment with tumour necrosis factor blockers. *Clin Exp Dermatol* 2007;32:176–9.
10. Wollina U, Hansel G, Koch A, et al. Tumor necrosis factor-alpha inhibitor-induced psoriasis or psoriasiform exanthemata: first 120 cases from the literature including a series of six new patients. *Am J Clin Dermatol* 2008;9:1–14.
11. Yamauchi PS, Lowe NJ. Etanercept therapy allows the tapering of methotrexate and sustained clinical responses in patients with moderate to severe psoriasis. *Int J Dermatol* 2008;47:202–4.
12. Georgala S, Koumantaki E, Rallis E, Papadavid E. Generalized pustular psoriasis developing during withdrawal of short-term cyclosporin therapy. *Br J Dermatol* 2000;142:1057–8.
13. Kamarashev J, Lor P, Forster A, et al. Generalised pustular psoriasis induced by cyclosporin a withdrawal responding to the tumour necrosis factor alpha inhibitor etanercept. *Dermatology* 2002;205: 213–6.
14. Abel EA, DiCicco LM, Orenberg EK, et al. Drugs in exacerbation of psoriasis. *J Am Acad Dermatol* 1986;15:1007–22.

4

Authors Queries

Journal: **Journal of Cutaneous Medicine and Surgery**

Paper: **JMS_2008_07087**

Title: **Exacerbation of Psoriasis under Efalizumab Therapy**

Dear Author

During the preparation of your manuscript for publication, the questions listed below have arisen. Please attend to these matters and return this form with your proof. Many thanks for your assistance

RETURN VIA FAX TO BC DECKER PROOFING, CHARLESWORTH CHINA + 86 (0) 106779 9806 OR SCAN AND RETURN VIA EMAIL TO bcdeckerproofing@charlesworth.com

Query	Remarks
1	AU: Pls provide your degrees.
2	AU: Given that you have provided only two legends for four figures, I have labeled Figs 1 and 2 Fig 1 and Figs 3 and 4 Fig 2. The two parts can go side by side.
3	AU: Is ref 4 from a suppl?
4	AU: Please confirm the title for ref 13.