



Acetabular labral tears following pregnancy

Joseph F. BAKER, Ciara M. MCGUIRE, Kevin J. MULHALL

From the Sports Surgery Clinic, Dublin, Ireland

Acetabular labral tears are usually seen in individuals in whom the hip is exposed to elevated axial and torsional forces. In our experience we have encountered a series of female patients in whom symptom onset was during pregnancy or obstetric labour. We reviewed our patient database to identify all patients who had undergone hip arthroscopy in our hospital. The records of female patients who had a labral tear on arthroscopy and in whom symptom onset was clearly documented to be during pregnancy or labour were identified.

We report three cases of acetabular labral tear occurring during pregnancy or labour. This represents 7% of all female patients undergoing hip arthroscopy during a two-year period. Ligamentous laxity and altered cartilage matrix during pregnancy may predispose to acetabular labral injury. Clinicians need to be aware of this possible intra-articular lesion in peripartum patients presenting with hip or buttock pain, and manage appropriately.

Keywords: acetabular labrum ; labrum tears ; pregnancy.

INTRODUCTION

Pregnancy represents a unique physiological state in a woman's life. The musculoskeletal system undergoes a variety of changes with an associated increase in ligamentous laxity. While back and pelvic pain are commonly reported musculoskeletal complaints, an increased risk of hip pain during pregnancy has also been identified (6,14). Hip

pathologies encountered during this period include spontaneous osteonecrosis and pregnancy related osteopenia (with or without fracture) (12,13). While these hip problems have been reviewed well by Steib-Furno *et al* and Smith *et al*, neither report the occurrence of acetabular labral pathology during pregnancy or labour (12,13).

Labral tears are classically seen in individuals in whom the hip is exposed to greater than normal axial and torsional forces (9). The onset of symptoms is most likely insidious and associated with other underlying abnormalities but a single traumatic episode can sometimes be identified (4). Activities involving extremes of flexion and rotation, particularly internal, of the hip appear to predispose to the development of these lesions (11).

We report a case series of three women presenting with acetabular labral injury. In each woman,

-
- Joseph F. Baker, Research Registrar.
Sports Surgery Clinic and Mater Misericordiae University Hospital, Dublin.
 - Ciara M. McGuire, Registrar.
Sports Surgery Clinic, Dublin.
 - Kevin J. Mulhall, Consultant.
Sports Surgery Clinic and Mater Misericordiae University Hospital, Dublin.

Correspondence : Dr Joseph F. Baker, Suite 4, Sports Surgery Clinic, Santry Demesne, Dublin 9, Ireland. Phone : 00 353 87 945 2829. E-mail : joseph.f.baker@gmail.com

© 2010, Acta Orthopædica Belgica.

the onset of symptoms was immediately after delivery or during pregnancy. This series represents a previously unreported association and identifies a potentially overlooked patient group.

MATERIALS AND METHODS

We reviewed our patient database and identified all female patients undergoing hip arthroscopy over an 18-month period. Medical records were reviewed to identify patients who presented with hip symptoms with onset around the time of labour and who subsequently had a definitive labral tear identified on arthroscopy. Presenting symptoms, clinical examination findings, radiological findings and treatment outcomes were recorded.

Institutional review board approval was obtained for this study.

RESULTS

One hundred and thirty-eight patients had undergone hip arthroscopy during the review period (95 male, 43 female). We identified three cases meeting the above criteria. These accounted for 2.2% of all patients undergoing hip arthroscopy and 7.0% of all females.

Case 1

A 42-year-old female noted persistent right groin pain following her first pregnancy one year prior to presentation. She had generalized pelvic girdle pain during the pregnancy. She underwent a planned Caesarean section under epidural anaesthesia five weeks before term. Following delivery she experienced more localised bilateral groin pain. However, while the pain in the left settled, it failed to do so on the right.

On examination she had mild tenderness over the greater trochanter and positive signs for labral pathology on the right. Radiographs of the pelvis did not reveal any evidence of osteoarthritis or evidence of acetabular retroversion and there was normal coverage of the femoral head (Centre-Edge angle 40°) and normal Tönnis angle. A magnetic resonance (MR) arthrogram of the right hip suggested a small tear at the base of the anterosuperior labrum. The α -angle measured 45°.

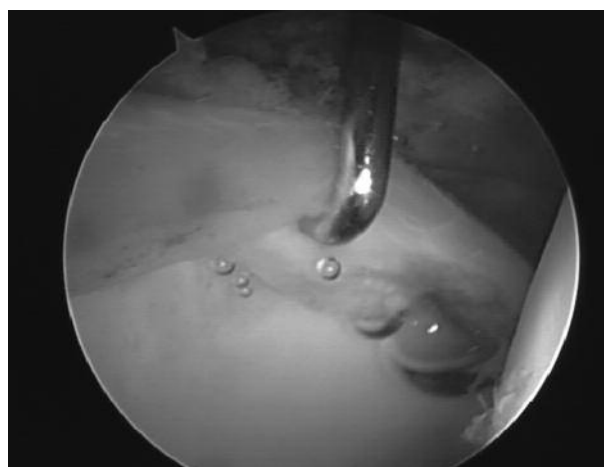

Fig. 1. — View from the lateral portal displaying an extensive anterosuperior labral tear.

Arthroscopy of the hip revealed an extensive anterosuperior labral tear (fig 1) with grade I-II chondral defects on both femoral and acetabular surfaces. Six months since surgery she has noticed steady improvement but still has a painless clicking sensation, clinically consistent with a psoas snap, that she did not have before delivery.

Case 2

A 36-year-old female presented complaining of gradually increasing left buttock pain that began following delivery of her last child five years earlier. She had a difficult vaginal delivery requiring forceps and episiotomy. Epidural anaesthesia was used during delivery. At presentation she was complaining principally of increasing left buttock and groin pain. She was also experiencing night pain and described a history of locking.

On clinical examination, passive flexion of the left hip with abduction and internal rotation was painful. Assessment of the spine was unremarkable.

Plain radiographs of the hip did not show any evidence of degeneration or acetabular retroversion. Femoral head coverage was adequate with a normal Centre-Edge angle. MR arthrography of the left hip confirmed a small superolateral labral tear and the α -angle was 48°. There was no acetabular retroversion.

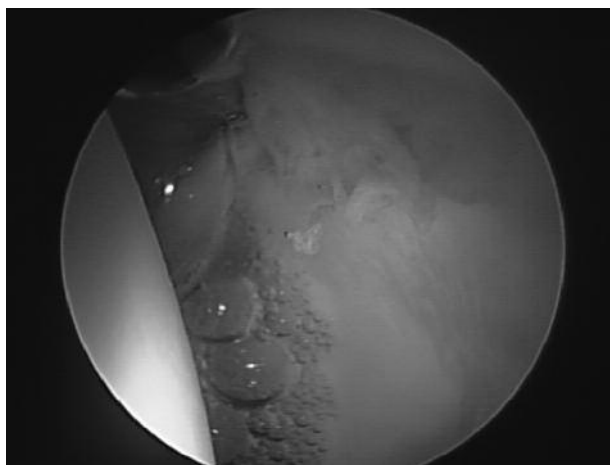

Fig. 2. — View from the lateral portal showing the degenerative labral tear.

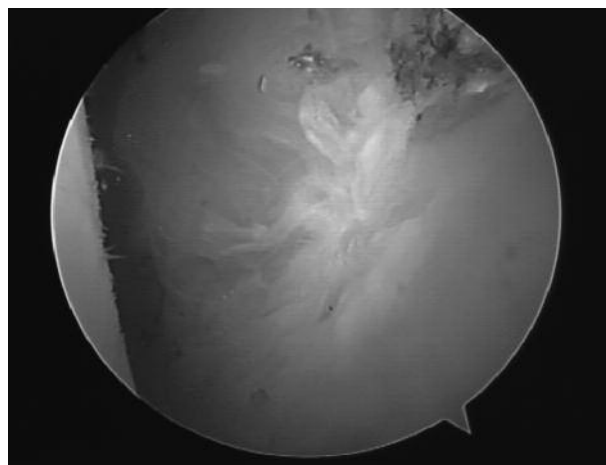


Fig. 3. — Degenerative changes to the acetabular articular surface.

A radioisotope bone scan showed increased uptake at the medial aspect of the acetabulum.

At arthroscopy, full thickness chondral lesions on the anterior femoral head were identified and required some limited debridement. An extensive anterior labral tear was also identified and debrided (fig 2). Eight months since the operation she has had great improvement in her symptoms.

Case 3

A 40-year-old female presented complaining of left hip pain that had persisted for three years since pregnancy. Her last child was a normal vaginal delivery and no epidural was required. The pain was first noticed after delivery, radiated into the groin and was associated with a decreased range of movement at the hip joint. She had not previously had problems with her hips or spine.

On examination, while full flexion of the left hip was comfortable, passive internal and external rotation caused significant discomfort.

Plain radiography of the pelvis was normal with preservation of the joint space, adequate coverage of the femoral head and no evidence of a retroverted acetabulum. MR arthrography suggested a small superolateral labral tear. The α -angle measured 50° . Hip arthroscopy showed widespread degenerative changes and a degenerative acetabular

labrum with an unstable tear needing debridement (fig 3). There was no evidence of dysplasia. Three months since debridement she has significant pain reduction and no restriction in mobility.

DISCUSSION

We have reported three cases of acetabular labral tear presenting late following pregnancy with associated intra-articular lesions. In one case more diffuse pelvic pain became very localized and was exacerbated by mobilization following delivery and in two others the onset of hip pain was clearly during the time of labour. Orthopaedic problems such as transient osteoporosis and osteonecrosis of the hip are well reported (3,12). We believe there may exist an association between pregnancy and the onset of acetabular labrum symptoms in 7% of a consecutive series of female patients undergoing hip arthroscopy.

Classically the athletic hip, exposed to significant axial and torsional forces, is considered prone to injury to the labrum (9). Hormones such as relaxin are markedly upregulated during pregnancy resulting in increased ligamentous laxity (12,14). We hypothesize that this increase in ligamentous laxity, coupled with the potential for reduced collagen levels in cartilaginous tissues, may predispose to

acetabular labral injury in the pregnant patient (8,10). Excessive range of movement with subsequent impingement can lead to greater than normal shear forces across a labrum that has its normal composition altered.

The loss of joint apposition can lead to impingement of the fibrocartilaginous labrum and shearing of its attachment (7). Epidural anaesthesia, as was administered in two of the three cases, might play a role in allowing greater than normal movements at the hip joint and could also mask early symptoms that would be present in a non-anaesthetized individual who is more aware of an initiating event. It is also possible that in some of these women there was a pre-existing asymptomatic labral or chondral abnormality in the hip that was exacerbated and rendered acutely symptomatic by the events around labour.

Pincer type femoro-acetabular impingement (FAI) is more common in women (2,7). However, there was no radiologically apparent increased head coverage or retroversion of the acetabulum in this series. Neither was there evidence of cam type lesions to predispose to labral injury. We do note the significant chondral injuries present in each case. It is known that labral tears predispose to early degenerative change and the advancement of these lesions is further evidence that the diagnosis of intra-articular hip disease can be missed when plain radiographs are normal (5,9).

This series suggests that the diagnosis of an acetabular labral tear should be considered in postpartum women presenting with symptoms and signs of hip disease. Routine MRI of the hip may not detect subtle chondral defects or labral tears and MR arthrography should be the first line investigation to assess for the presence of a labral tear (1).

In summary, we have reported a small case series of women presenting with labral tears coming to symptoms during pregnancy or after delivery. This is a new association not previously reported. The exact aetiology and nature of this association is not known and may be an area for future investigation. We conclude that the diagnosis of labral and chondral pathology should be considered in women presenting with hip symptoms following pregnancy.

Acknowledgements

We would like to acknowledge support from the Orthopaedic Research and Innovation Foundation in the creation of this manuscript (www.orif.ie).

REFERENCES

1. **Anderson LA, Peters CL, Park BB et al.** Acetabular cartilage delamination in femoroacetabular impingement. Risk factors and magnetic resonance imaging diagnosis. *J Bone Joint Surg* 2009 ; 91-A : 305-313.
2. **Beck M, Kalhor M, Leunig M, Ganz R.** Hip morphology influences the pattern of damage to the acetabular cartilage : femoroacetabular impingement as a cause of early osteoarthritis of the hip. *J Bone Joint Surg* 2005 ; 87-B : 1012-1018.
3. **Brooks GG, Thomas BV, Wood MJ.** Hip pain in late pregnancy. *J Reprod Med* 1990 ; 35 : 969-970.
4. **Bruckner PD, Crossley KM, Morris H, Bartold SJ, Elliott B.** Recent advances in sports medicine. *Med J Aust* 2006 ; 184 : 188-193.
5. **Clohisey JC, Knaus ER, Hunt DM et al.** Clinical presentation of patients with symptomatic anterior hip impingement. *Clin Orthop Relat Res* 2009 ; 467 : 638-644.
6. **Colliton J.** Managing back pain during pregnancy. *Medscape Womens Health* 1997 ; 2 : 2.
7. **Ganz R, Parvizi J, Beck M et al.** Femoroacetabular impingement : a cause for osteoarthritis of the hip. *Clin Orthop Relat Res* 2003 ; 417 : 112-120.
8. **Hashem G, Zhang Q, Hayami T et al.** Relaxin and beta-estradiol modulate targeted matrix degradation in specific synovial joint fibrocartilages : progesterone prevents matrix loss. *Arthritis Res Ther* 2006 ; 8 : R98.
9. **McCarthy JC, Noble PC, Schuck MR, Wright J, Lee J.** The Otto E. Aufranc Award : The role of labral lesions to development of early degenerative hip disease. *Clin Orthop Relat Res* 2001 ; 393 : 25-37.
10. **Samuel CS, Coghlan JP, Bateman JF.** Effects of relaxin, pregnancy and parturition on collagen metabolism in the rat pubic symphysis. *J Endocrinol* 1998 ; 159 : 117-125.
11. **Shindle MK, Voos JE, Heyworth BE et al.** Hip arthroscopy in the athletic patient : current techniques and spectrum of disease. *J Bone Joint Surg* 2007 ; 89-A ; Suppl 3 : 29-43.
12. **Smith MW, Marcus PS, Wurtz LD.** Orthopedic issues in pregnancy. *Obstet Gynecol Surv* 2008 ; 63 : 103-111.
13. **Steib-Furno S, Luc M, Pham T et al.** Pregnancy-related hip diseases : incidence and diagnoses. *Joint Bone Spine* 2007 ; 74 : 373-378.
14. **Vullo VJ, Richardson JK, Hurvitz EA.** Hip, knee, and foot pain during pregnancy and the postpartum period. *J Fam Pract* 1996 ; 43 : 63-68.