

CASE REPORT

Hydrocarbon Pneumonitis Following Diesel Siphonage

Puneet Khanna, S.C. Devgan¹, V.K. Arora² and Ashok Shah

*Department of Respiratory Medicine, Vallabhbai Patel Chest Institute, University of Delhi, Delhi;
Department of Medicine, Hindu Rao Hospital¹, Delhi; and
Department of Pathology, University College of Medical Sciences and GTB Hospital², Delhi*

ABSTRACT

In our country, siphoning of diesel/petrol from fuel tanks is a common practice. We describe a 50-year-old farmer, who accidentally aspirated fuel while siphoning from his tractor. A diagnosis of diesel induced aspiration pneumonitis was confirmed by the presence of foam cells on bronchial biopsy. The patient showed gradual recovery with the symptomatic therapy. However two weeks later, he developed sudden chest pain and irregularly irregular pulse that proved fatal. Diesel aspiration leading to bilateral pneumonitis is yet to be reported in our country.

Key words : *Aspiration pneumonitis, Diesel, Hydrocarbon pneumonitis, Siphonage.*

[Indian J Chest Dis Allied Sci 2004; 46 : 129-132]

INTRODUCTION

Diesel is one of the several distillates prepared by fractionation of crude oil and is commonly used as a vehicle fuel in our country. Aspiration of diesel/petrol may occur accidentally while siphoning from fuel tanks¹⁻⁵. It was in 1897, that Hamilton first described pneumonitis due to hydrocarbon aspiration⁶. Since then accidental poisoning has been reported with kerosene, dry-cleaning fluids and mineral seal oil present in liquid polishes and waxes^{7,8}. Aspiration of hydrocarbon products, particularly in children, elderly and debilitating persons, usually results from vomiting that occurs after accidental ingestion⁸. However, in the literature, case reports pertaining to aspiration of diesel/petrol during siphonage are

sparse, and at best, sketchy. A MEDLINE search from 1966 till date revealed a report of diesel aspiration in the English literature from Taiwan⁴. The authors described 12 cases of pneumonitis consequent to siphonage of diesel from trucks. In addition, there are two case reports published in the Russian literature^{1, 5}. Siphoning of petrol leading to right middle lobe pneumonitis has been documented from United Kingdom² and a similar report of three patients with right middle lobe aspiration pneumonitis after siphoning petrol has been published from United States of America³. Although standard textbooks on respiratory medicine carry a description of pneumonitis caused by hydrocarbon aspiration, the consequences of aspiration of diesel/petrol following siphonage find no mention^{9, 10}.

[Received : March 25, 2003; accepted after revision : July 10, 2003]

Correspondence and reprints request: Dr Ashok Shah, Professor, Department of Respiratory Medicine, Vallabhbai Patel Chest Institute, University of Delhi, Delhi-110 007, P.O. Box: 2101, India; Telefax: 91-11-27667420; E-mail: <ashokshah99@yahoo.com>.

The rarity of such an account prompted this report of a 50-year-old farmer who developed bilateral pneumonitis as a consequence of accidental diesel aspiration. To our knowledge, diesel aspiration leading to bilateral pneumonitis is yet to be documented in our country.

CASE REPORT

A 50-year-old farmer was referred to our Institute with a history of accidental diesel aspiration while siphoning from the fuel tank of a tractor, which occurred three days prior to presentation. The patient complained of progressively increasing breathlessness at rest without wheeze, along with mild, non-radiating pain on the right side of the chest. He developed a productive cough with pinkish frothy expectoration that was non-foul smelling. The patient had nausea but there was no history of hemoptysis, hematemesis, dysphagia or hoarseness of voice. He had received symptomatic treatment at a district hospital for three days without relief.

On examination, the patient was febrile with a pulse rate of 104/min, regular, good volume with a blood pressure of 102/68 mmHg. He was dyspnoeic with a respiratory rate of 32/min. There was no cyanosis or pedal edema and JVP was not raised. Respiratory movements were equal on both sides of the chest. However, the percussion note was impaired bilaterally in the inframammary, infraxillary and infrascapular areas. On auscultation, vesicular breath sounds, though audible, were greatly diminished in intensity in these areas along with coarse, basal, inspiratory crepitations that were more pronounced on the right side.

The haemogram revealed a total leucocyte count of 14,000 cells/mm³ with 96% polymorphs and 4% lymphocytes. A chest roentgenogram revealed bilateral, non-segmental, homogeneous opacities in the lower zones (Figure 1). Blood gas analysis showed a pH of 7.32, pCO₂ 52 mm, and pO₂ 56 mm with bicarbonates of 19.6 mmol. ECG was within normal limits. A provisional diagnosis of aspiration pneumonitis was made and the patient was treated with

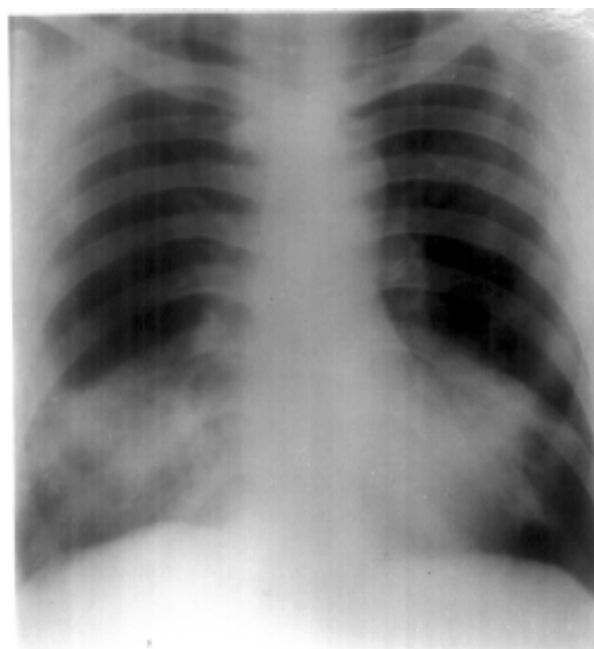


Figure 1. Chest roentgenogram (PA view) showing bilateral, non-segmental, homogeneous opacities in the lower zones.

oxygen inhalation, analgesics and amoxycillin 500 mg thrice daily along with oral prednisolone 20 mg, once daily. A fiberoptic bronchoscopy done one week following the episode of aspiration showed greyish patches over the mucosa of the right intermediate and lower lobe bronchi. A biopsy from the region revealed features of acute bronchitis with few foam cells, which were consistent with the diagnosis of diesel induced aspiration

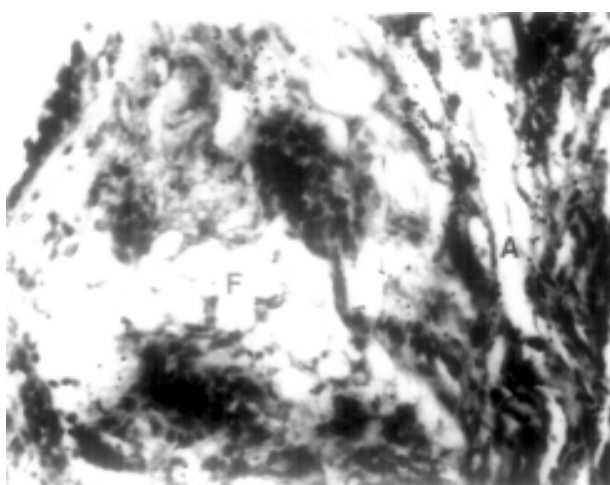


Figure 2. Bronchial biopsy showing atelectasis (A) and focal pulmonary oedema with foam cells (F) and vacuolations (H & E × 100).

pneumonitis (Figure 2). The patient improved symptomatically with the treatment and was no longer febrile. He, however, complained of occasional chest pain on the right side that was relieved by analgesics.

Two weeks after inhalation, the patient had a sudden episode of chest pain and palpitations. An irregularly irregular pulse rate of 110/min with a blood pressure of 90/60 mm of Hg was recorded. ECG showed atrial fibrillation with a fast ventricular rate and left ventricular decompensation. The patient was referred to a cardiac centre where he had a fatal cardiac arrest.

DISCUSSION

Siphonage of fuel from the motor vehicles is a very common practice in our country. Accidental aspiration of diesel/petrol during siphoning can result as a result of direct inhalation or may follow ingestion¹¹. Symptomatic involvement of the pulmonary system occurs in the form of pulmonary oedema, atelectasis and consolidation, and is often the most common presentation of hydrocarbon toxicity¹².

Mineral oil pneumonia has been "defined as the inflammatory, granulomatous and fibrotic reaction of the lung to the aspiration of mineral oil"⁸. This is thought to be an indolent and benign process resembling low-grade bronchopulmonary infection with nonspecific clinical findings⁸. The characteristic histopathological picture of gasoline aspiration is the presence of 'lipoid' cells, or foamy cells in fine state of subdivision¹³, and this was well demonstrated in our patient.

The most common radiological pattern following aspiration of hydrocarbons is predominately bilateral, basal involvement as they elicit very little cough and thus can be aspirated directly into the lower lobes¹⁴. The radiological lesions are typically unchanging in nature and out of proportion to the clinical findings⁸. However, right middle lobe pneumonitis, following aspiration of diesel/petrol during siphonage has been seen in 16 of the 17 patients documented so far²⁻⁵. In none of

the 17 patients was the left lung involved. The selective involvement of the middle lobe is hypothesized to be characteristic of aspiration pneumonia following siphonage, as the accident usually occurs while the person bends forward to siphon the fuel³. In contrast, our patient had non-segmental, homogeneous opacities in both the lower zones with relative sparing of the right middle lobe. This may be explained by the fact that Indians usually squat rather than bend forward.

The clinical presentation of hydrocarbon pneumonitis is often nonspecific and includes breathlessness, cough, chest pain and hemoptysis^{4, 8, 12}. The role of bronchoscopy in the diagnosis by means of biopsy and in treatment by performing saline lavage has been reported earlier^{4, 5}. In all cases of hydrocarbon pneumonitis induced by siphonage of diesel/ petrol that have been reported so far, a favourable clinical outcome has been observed²⁻⁵. The treatment is usually empirical, as there is insufficient data advocating the utility of corticosteroids and antibiotics¹⁵. Our patient showed clinical improvement with the symptomatic therapy. Although, cardiac abnormalities like arrhythmia and cardiomyopathy following hydrocarbon intoxication have been mentioned in standard textbooks^{12, 16}, a literature search did not reveal any report of cardiac involvement following diesel aspiration subsequent to siphonage.

Ingestion of motor fuels that occurs following siphonage has also been reported to cause acute hydrocarbon poisoning. The central nervous system, the gastrointestinal tract and the lungs are most commonly involved¹¹. Hydrocarbon pneumonitis in professional 'fire-eaters' due to accidental aspiration of kerosene has been described in our country¹⁷. Two patients of tongue and palatal cancer following repeated siphonage of machine oils, diesel and petrol have also been documented from our country¹⁸.

Our case highlights the fact that hydrocarbon pneumonitis can occur due to accidental diesel aspiration while siphoning. Pulmonologists should be aware of such a possibility so as to reduce morbidity that can arise following siphoning of motor fuel.

REFERENCES

1. Kirsanov IuV. Pneumonia as a consequence of diesel fuel aspiration. *Ter Arkh* 1970; **42** : 109-10.
2. Lee TH, Seymour WM. Pneumonitis caused by petrol siphoning. *Lancet* 1979; **2** : 149.
3. Carlson DH. Right middle lobe aspiration pneumonia following gasoline siphonage. *Chest* 1981; **80** : 246-47.
4. Lee CH, Chiang YC, Lan RS, Tsai YH, Wang WJ. Aspiration pneumonia following diesel oil siphonage: Analysis of 12 cases. *Chang Gung Med J* 1988; **11** : 180-84.
5. Vertkin Iul, Platunov SK. A case of pneumonia caused by aspiration of diesel fuel. *Gig Tr Prof Zabol* 1989; **3** : 41-44.
6. Hamilton WC. Death from drinking coal oil. *Med News* 1897; **71** : 214.
7. Eade NR, Taussig LM, Marks MI. Hydrocarbon pneumonitis. *Pediatrics* 1974; **54** : 351-59.
8. Miller A, Bader RA, Bader ME, Teirstein AS, Selikoff IJ. Mineral oil pneumonia. *Ann Intern Med* 1962; **57** : 627-34.
9. Bartlett JG. Aspiration disease and anaerobic infection. In : Fishman AP, Elias JA, Fishman JA, Grippi MA, Kaiser CR, Senior RM, eds *Fishman's Pulmonary Diseases and Disorders*; 3rd edn. New York: McGraw-Hill; 1998: 2011-19.
10. Fraser RS. Pulmonary disease caused by aspiration of solid foreign material and liquids. In: Fraser RG, Pare JAP, Pare PD, Fraser RS, Genereux GP, eds *Diagnosis of the Diseases of the Chest*; 3rd edn. Philadelphia: WB Saunders Company; 1990: 2398-2406.
11. Rouse TE, Weese WC, Kazemi H. Gasoline ingestion. *New Engl J Med* 1974; **290** : 1092-93.
12. Olsen KR. Poisoning. In: Tierney LM, McPhee SJ, Papadakis MA, eds *Current Medical Diagnosis and Treatment*; 39th edn; International edition; McGraw-Hill Company; 2000: 1567-68.
13. Frieman DG, Engelberg H, Merritt WH. Oil aspiration (lipoid) pneumonia in adults. *Arch Intern Med* 1940; **66** : 11-38.
14. Bonte FJ, Reynolds J. Hydrocarbon pneumonitis. *Radiology* 1958; **71** : 391-97.
15. Steele RW, Conklin RH, Mark HM. Corticosteroids and antibiotics in the treatment of fulminant hydrocarbon aspiration. *JAMA* 1972; **219** : 1434-37.
16. Linden CH, Burns MJ. Poisoning and drug overdose. In: Braunwald E, Fauci AS, Kasper DL, Hauser SL, Longo DL, Jameson JL, eds *Harrison's Principles of Internal Medicine*; 15th edn. McGraw-Hill Company; 2609.
17. Agrawal PK, Srivastava DK. Hydrocarbon pneumonitis: A hazard in fire-eaters. *J Assoc Physicians India* 1986; **34** : 752.
18. Sengupta P, Ray DN, Poddar SP. Cancer of the tongue and palate following occupational exposure to petroleum products. *J Indian Med Assoc* 1984; **82** : 59-61.