

Teaching Point (Section Editor: W. Herrington)

Imported bugs, not beasts: extensively drug-resistant tuberculosis and acute kidney injury

Caroline Bell¹, Kassiani Skordilis², Fouad Al-Baqi^{1,3} and Andrew Bentall^{1,3,4}

¹Department of Nephrology, University Hospitals Birmingham NHS Foundation Trust, Birmingham, UK, ²Department of Histopathology, University Hospitals Birmingham NHS Foundation Trust, Birmingham, UK, ³Department of Nephrology, Sandwell and West Birmingham Hospital, Birmingham, UK and ⁴School of Immunity and Infection, University of Birmingham, UK

Correspondence and offprint requests to: Andrew Bentall; E-mail: andrew.bentall@uhb.nhs.uk

Keywords: acute kidney injury; multi-drug-resistant tuberculosis; zebra bodies

Background

The latest UK annual tuberculosis (TB) report shows that the rates of TB have remained at a more consistent level in the UK over recent years; however, the incidence of TB in the UK remains high (13.9 per 100 000 population) in comparison to most other Western European Countries. The proportion of multi-drug-resistant (MDR-TB) cases is stable at 1.6% with two cases of extensively drug-resistant tuberculosis (XDR-TB) reported in 2012 [1]. However, worldwide, 10% of MDR-TB cases are XDR-TB [2]. XDR-TB is defined as resistance *in vitro* to isoniazid, rifampicin, any fluoroquinolone and at least one of three injectable second-line drugs (amikacin, kanamycin or capreomycin) used to treat TB. Treatment with at least five drugs to which the organism is susceptible is recommended [3, 4]. Treatment of XDR-TB is only successful in 40% [5]. The incidence of drug-resistant TB is higher in patients who have had previous TB treatment and in individuals born outside of the UK [1]. The treatment for TB continues to be a balance of benefit and risk to the patient and the wider population and is outlined in Table 1. Inadequate treatment leads to an increased risk of further resistance and increases morbidity and mortality. XDR-TB is best treated with six agents in the intensive phase (6–9 months) and then four agents during the continuation phase (21–25 months) [5]. Regimes for anti-TB therapies are guided by local microbiology advice, based on sensitivities and there is still considerable toxicity from current TB therapy, especially agents used to treat XDR-TB.

We present a case of acute kidney injury (AKI) secondary to capreomycin toxicity in a young female receiving treatment for XDR-TB.

Case

A 19-year-old student from India was referred to the haematologists with left cheek swelling which on ultrasound revealed an enlarged left sided intraparotid lymph node

and bilateral cervical lymphadenopathy. Her chest X-ray demonstrated clear lung fields but right hilar and paratracheal lymphadenopathy. She had no history of previous treatment for TB and no known recent TB contacts. She had just started her studies, recently arriving in the UK. She had no other systemic symptoms. Her initial weight was 70.5 kg.

Early referral for lymph node biopsy was performed with pus on aspiration and acid fast bacilli present on microscopy. She was started on anti-tuberculous treatment with rifampicin, ethambutol and isoniazid pending culture sensitivities. The culture grew mycobacterium TB, which was resistant to isoniazid, rifampicin, pyrazinamide, kanamycin, prothionamide, moxifloxacin and ofloxacin, but sensitive to ethambutol, amikacin and capreomycin. No mutations to aminoglycosides/cyclic peptides were detected by the Mycobacterium Reference Unit, London. Her anti-TB therapy was therefore changed to a combination of pyrazinamide, cycloserine, prothionamide, moxifloxacin, P-aminosalicylate sodium granules, ethambutol and capreomycin. Her HIV and hepatitis screens were negative.

Four weeks into her treatment clofazimine was added, and another 2 weeks later linezolid was started due to concerns about increasing weight loss. Pyrazinamide was stopped. Nine weeks into treatment she had an emergency hospital admission with stage 3 AKI and significant electrolyte abnormalities [6]. Her renal function declined from a creatinine of 59 (eGFR >90 mL/min) at the start of treatment to a creatinine of 245 (eGFR 22 mL/min) with associated hypokalaemia and hypomagnesaemia and she experienced tetany due to hypocalcaemia (see Figure 1). Her appetite was reduced, but she had no vomiting or diarrhoea, and her weight had fallen to 66.7 kg. She had taken no other medications and was clinically euvolaemic. The initial blood results demonstrated a normal leukocyte count; however her eosinophils had risen since starting anti-TB treatment from 0.1 to $2.20 \times 10^9/L$. Soluble immunology associated with AKI was negative. Her urine dipstick did not demonstrate significant proteinuria or haematuria and her albumin creatinine ratio was 3.9 mg/mmol. An ultrasound of her renal tract showed two normal sized kidneys without obstruction.

Table 1. Groups of drugs to treat MDR-TB taken from the Treatment of Tuberculosis Guidelines, 4th edition. World Health Organisation 2010 URL: http://whqlibdoc.who.int/publications/2010/9789241547833_eng.pdf

Group	Drugs (abbreviations)
Group 1 First-line oral agents	Pyrazinamide (Z) Ethambutol (E) Rifabutin (Rfb)
Group 2 Injectable agents	Kanamycin (Km) Amikacin (Am) Capreomycin (Cm) Streptomycin (S)
Group 3 Fluoroquinolones	Levofloxacin (Lfx) Moxifloxacin (Mfx) Ofloxacin (Ofx)
Group 4 Oral bacteriostatic second-line agents	Para-aminosalicylic acid (PAS) Cycloserine (Cs) Terizidone (Trd) Ethionamide (Eto) Protionamide (Pto) Clofazimine (Cfz)
Group 5 Agents with unclear role in treatment of drug-resistant TB	Linezolid (Lzd) Amoxicillin/clavulanate (Amx/Clv) Thioacetazone (Thz) Imipenem/cilastatin (Ipm/Cln) High-dose isoniazid (high-dose H) ^a Clarithromycin (Clr)

^aHigh-dose isoniazid is defined as 16–20 mg/kg/day. Some experts recommend using high-dose isoniazid in the presence of resistance to low concentrations of isoniazid (>1% of bacilli resistant to 0.2 µg/mL but susceptible to 1 µg/mL of isoniazid), whereas isoniazid is not recommended for high-dose resistance (>1% of bacilli resistant to 1 µg/mL of isoniazid).

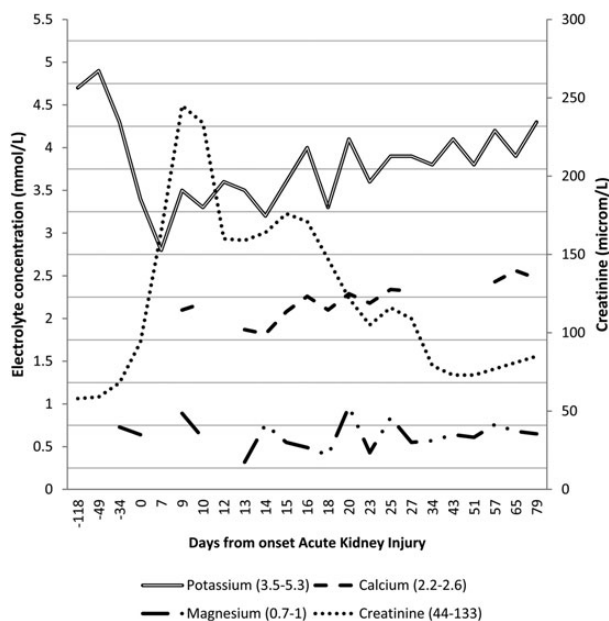


Fig. 1. The impact on creatinine and other electrolytes following TB therapy, and clinical improvement. The resolution of the AKI occurred in the first 30 days, with improvement in electrolytes. At 231 days post AKI, the creatinine has returned to baseline at 59 µM/L (Local laboratory values in parentheses).

All her anti-TB medications were stopped and fluid management and electrolytes replacement were addressed, but there was no improvement in her kidney function and a

renal biopsy was performed. The light microscopy histology displayed acute tubular injury without any interstitial inflammation, which was supported by the electron microscopy (see Figure 2a). However, in the electron microscopy, several intracytoplasmic myeloid bodies within epithelial cells, known as 'Zebra bodies', were seen (see Figure 2b). Unlike in Fabry's disease where they are diffuse in the glomeruli, the Zebra bodies were limited to the tubules. There was no family history of renal disease and no systemic clinical signs of Fabry's disease. This finding was attributed to capreomycin, inducing an acquired enzyme deficiency of the epithelial cells.

AKI induced by the use of anti-TB therapy was explained to the patient, along with the need to treat effectively her XDR-TB, which carried a high mortality (rate of 7–36% [7]). The risks of chronic kidney disease and the possibility of requiring renal replacement therapy as a result of her ongoing anti-microbial treatment were also clearly explained to her. Following this, her anti-tuberculous regime was restructured to include para-aminosalicylic acid, cycloserine, co-amoxiclav, meropenem, clofazimine and linezolid. Her renal function improved, but with residual hypocalcaemia, hypomagnesaemia and hypophosphataemia that required ongoing oral electrolyte replacement. No renal replacement therapy was required at any point. To facilitate self-administration of intravenous anti-microbials, a tunnelled central line was inserted. Due to the extended resistance of her TB, de-bulking surgery is still under consideration to reduce disease burden. Capreomycin has been re-introduced successfully at a lower drug dose. Manufacturer guidelines are a maximum of 20 mg/kg/day of capreomycin, which this patient had not exceeded. This patient's renal function and eosinophil count has returned to baseline without any further renal impairment.

Discussion

This case highlights the need for a multi-disciplinary team approach to optimizing care for a young patient at high risk of mortality with a diagnosis of XDR-TB and renal complications from therapy. 'Zebra bodies' are a descriptive term for lysosomes containing broad transversely-stacked myelinoid membranes. They are most commonly recognized with Anderson-Fabry disease, a lysosomal storage disorder of glycosphingolipid catabolism caused by deficiency of α -galactosidase; however, they also occur in iatrogenic interstitial phospholipidosis (PL) from various pharmacological agents, including aminoglycosides (Table 2) [8–10]. There are significantly fewer classically lamellated podocyte inclusions in iatrogenic PL, compared with Fabry's disease [11].

In this patient, drug induced PL was likely to be due to the capreomycin, inducing an acquired enzyme deficiency of the renal epithelial cells. Capreomycin is a cyclic polypeptide, which is similar but not identical to aminoglycosides, a class of anti-microbial well known for their nephrotoxic side effects, but appropriate for culture sensitivities in this patient [12]. In addition, the use of capreomycin for MDR-TB has been associated with less ototoxicity and less AKI than those with ototoxicity from aminoglycosides [13]. While capreomycin has a recognized nephrotoxic, the effect may not be from toxic levels, but an adaptive immune response to therapy. Many of the drugs that cause PL are cationic, amphiphilic drugs and the nephrotoxic effects result from retention of a small, but significant

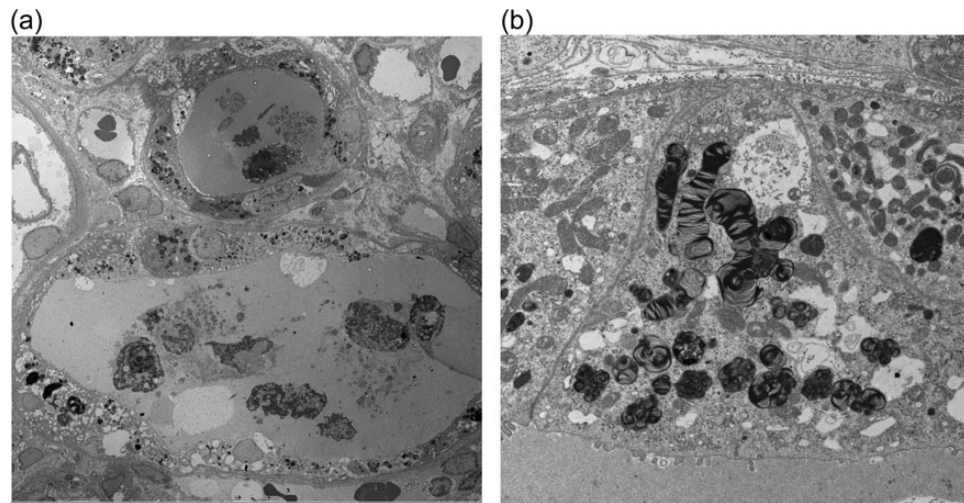


Fig. 2. Histological changes of electron microscopy in AKI following anti-TB therapy. (a) Tubular injury displayed in several tubules with dense granules. (b) Several intracytoplasmic myeloid bodies within epithelial cells are identified within tubules.

Table 2. Pharmacological agents associated with drug-induced phospholipidosis

Drug	Therapeutic class
Amiodarone	Antiarrhythmic drugs
Amodiaquine	Anti-malarial and Anti-inflammatory agent
Chloroquine	Anti-malarial
4,4'-Diethylaminoethoxyhexestrol Dihydrochloride	Coronary dilator
Gentamicin, tobramycin	Aminoglycoside antibiotic
2-(2,2-dicyclohexylethyl)piperidine	Prophylactic antianginal agent
4':4'-Diamidino Stilbene	Anti-protozoal agent
Tilorone	Antiviral
Desipramine	Anti-depressant
Pentamidine	Anti-microbial

(approximately 5%) proportion of the administered dose in the epithelial cells of the proximal tubule, mainly within endosomal and lysosomal vacuoles. This results in accumulation of phospholipids in, and enlargement of, the lysosomes with inhibition of lysosomal phospholipases. Decreased reabsorption and/or intracellular lysosomal sequestration and digestion of filtrated, low-molecular weight proteins follow, with shedding of brush border enzymes and release of lysosomal enzymes. Each drug induces its own phospholipid composition and selectively targets different organs [14]. In the kidney this can result in increased phospholipid excretion, proteinuria, a reduction in glomerular filtration, and wasting of potassium, magnesium and calcium from the tubules [10]. Currently, there are no biomarkers in current use that recognize the phenomena prior to organ injury; however, this is the research goal for therapeutic monitoring [15, 16].

The risk of nephrotoxicity can be reduced by monitoring drug levels to guide dose adjustments to maintain levels within a therapeutic range; however, AKI can still occur within therapeutic levels. Iatrogenic PL in tissue is reversible on termination of the drug. Renal function in this case improved from recovering acute tubular injury and no further renal biopsies have been performed.

Anti-TB therapy strategies have not introduced new agents into clinical practice; however, there are agents

(bedaquiline, delamanid) registered for the treatment of TB which are undergoing phase III clinical trials at present (Clinical trials identifier: NCT01424670, NCT01600963, respectively) [17, 18].

This case highlights the first reported case of capreomycin induced PL in a high-risk XDR-TB patient and mechanisms of PL. The reduction in dose after a period of cessation allowed effective therapy to occur and renal function to return to baseline.

Learning points

1. XDR-TB carries a high mortality risk, and thus appropriate anti-microbial agents need to be used to effectively treat the patient and prevent both individual and population resistance developing.
2. Drug reaction should be suspected with a rising eosinophil count, and renal biopsy will guide clinical decision-making regarding further therapies.
3. Phospholipidosis, while recognized as a drug reaction, has not previously been reported with capreomycin although capreomycin may in general be less nephrotoxic than aminoglycosides.
4. Electrolyte losses with capreomycin are recognized, with an acquired Bartter's-like syndrome recognized in both capreomycin and the aminoglycosides and therefore need monthly monitoring of renal function and electrolytes to prevent complications.

Authors' contributions

C.B., K.S., F.A.-B. and A.B. participated in research design. C.B., K.S., F.A.-B. and A.B. participated in the writing of the paper. C.B., K.S., F.A.-B. and A.B. participated in the performance of the research. C.B., K.S. and A.B. participated in data analysis.

Conflict of interest statement. None declared.

References

1. Public Health England. Tuberculosis in the UK: 2013 report. 2013

2. Gunther G. Multidrug-resistant and extensively drug-resistant tuberculosis: a review of current concepts and future challenges. *Clin Med* 2014; 14: 279–285
3. Falzon D, Jaramillo E, Wares F et al. Universal access to care for multidrug-resistant tuberculosis: an analysis of surveillance data. *Lancet Infect Dis* 2013; 13: 690–697
4. World Health Organisation. <http://www.who.int/tb/challenges/mdr/tdrfaqs/en/>
5. Falzon D, Gandhi N, Migliori GB et al. Resistance to fluoroquinolones and second-line injectable drugs: impact on multidrug-resistant TB outcomes. *Eur Respir J* 2013; 42: 156–168
6. Mehta RL, Kellum JA, Shah SV et al. Acute Kidney Injury Network: report of an initiative to improve outcomes in acute kidney injury. *Crit Care* 2007; 11: R31
7. Sotgiu G, Ferrara G, Matteelli A et al. Epidemiology and clinical management of XDR-TB: a systematic review by TBNET. *Eur Respir J* 2009; 33: 871–881
8. Bracamonte ER, Kowalewska J, Starr J et al. Iatrogenic phospholipidosis mimicking Fabry disease. *Am J Kidney Dis* 2006; 48: 844–850
9. Woywodt A, Hellweg S, Schwarz A et al. A wild zebra chase. *Nephrol Dial Transplant* 2007; 22: 3074–3077
10. Mingeot-Leclercq MP, Tulkens PM. Aminoglycosides: nephrotoxicity. *Antimicrob Agents Chemother* 1999; 43: 1003–1012
11. Loh AH, Cohen AH. Drug-induced kidney disease—pathology and current concepts. *Ann Acad Med Singapore* 2009; 38: 240–250
12. Via LE, Cho SN, Hwang S et al. Polymorphisms associated with resistance and cross-resistance to aminoglycosides and capreomycin in Mycobacterium tuberculosis isolates from South Korean Patients with drug-resistant tuberculosis. *J Clin Microbiol* 2010; 48: 402–411.
13. Sturdy A, Goodman A, Jose RJ et al. Multidrug-resistant tuberculosis (MDR-TB) treatment in the UK: a study of injectable use and toxicity in practice. *J Antimicrob Chemother* 2011; 66: 1815–1820
14. Anderson N, Borlak J. Drug-induced phospholipidosis. *FEBS Lett* 2006; 580: 5533–5540
15. Berridge BR, Chatman LA, Odin M et al. Phospholipidosis in nonclinical toxicity studies. *Toxicol Pathol* 2007; 35: 325
16. Sawada H, Takami K, Asahi S. A toxicogenomic approach to drug-induced phospholipidosis: analysis of its induction mechanism and establishment of a novel in vitro screening system. *Toxicol Sci* 2005; 83: 282–292
17. Tiberi S, De Lorenzo S, Centis R et al. Bedaquiline in MDR/XDR-TB cases: first experience on compassionate use. *Eur Respir J* 2014; 43: 289–292
18. Gler MT, Skripconoka V, Sanchez-Garavito E et al. Delamanid for multidrug-resistant pulmonary tuberculosis. *N Engl J Med* 2012; 366: 2151–2160

Received for publication: 14.5.14; Accepted in revised form: 8.9.14