

See discussions, stats, and author profiles for this publication at: <https://www.researchgate.net/publication/16232003>

# Modulation of Immunological Competence in 1,2-Dimethylhydrazinesensitive SWR/J Mice during Colorectal Carcinogenesis

Article in Cancer Research · August 1980

Source: PubMed

CITATIONS

6

READS

23

3 authors, including:



**Andras K Szakal**

Virginia Commonwealth University

110 PUBLICATIONS 6,646 CITATIONS

[SEE PROFILE](#)

Some of the authors of this publication are also working on these related projects:



FDC Biology [View project](#)

## Modulation of Immunological Competence in 1,2-Dimethylhydrazinesensitive SWR/J Mice during Colorectal Carcinogenesis

A. K. Szakal, B. A. Diwan and K. E. Blackman

*Cancer Res* 1980;40:2475-2485. Published online July 1, 1980.

### Updated Version

Access the most recent version of this article at:  
<http://cancerres.aacrjournals.org/content/40/7/2475>

### E-mail alerts

[Sign up to receive free email-alerts](#) related to this article or journal.

### Reprints and Subscriptions

To order reprints of this article or to subscribe to the journal, contact the AACR Publications Department at [pubs@aacr.org](mailto:pubs@aacr.org).

### Permissions

To request permission to re-use all or part of this article, contact the AACR Publications Department at [permissions@aacr.org](mailto:permissions@aacr.org).

# Modulation of Immunological Competence in 1,2-Dimethylhydrazine-sensitive SWR/J Mice during Colorectal Carcinogenesis<sup>1</sup>

A. K. Szakal, B. A. Diwan, and K. E. Blackman<sup>2</sup>

Department of Anatomy, Medical College of Virginia, Virginia Commonwealth University, Richmond, Virginia 23298 [A. K. S.], and Meloy Laboratories, Inc., Springfield, Virginia 22151 [B. A. D., K. E. B.]

## ABSTRACT

Morphologically defined stages of 1,2-dimethylhydrazine (DMH)-induced colorectal carcinogenesis were correlated with concomitant changes in the immunological competence of susceptible SWR/J mice. The morphogenesis of colorectal tumors and the cellular changes occurring in the spleen, draining (mesenteric) lymph node, thymus, liver, and lung of mice were studied during and after chronic s.c. administration of the carcinogen (15 mg DMH per kg body weight per week for 20 weeks). The immunological competence of T- and B-lymphocytes of spleens and draining lymph nodes was measured biweekly by tritiated thymidine incorporation in response to *in vitro* stimulation with concanavalin A and bacterial endotoxin.

A triphasic modulation of the regional (draining lymph node) and systemic (splenic) immunocompetence was demonstrated in DMH-treated mice during colorectal carcinogenesis. The three phases of modulation correlated with the latency of appearance of colorectal lesions, tumor progression, and the development of invasive adenocarcinomas. Cellular changes in the draining lymph node and the spleen reflected the mitogen reactivity of T- and B-lymphocytes in Phases I and III. In Phase II, however, splenic mitogen reactivity did not reflect the morphologically detectable enhancement of the splenic immune response due to the dilution effect of the extensive myeloid metaplasia in the red pulp.

In Phase I, a depression of the regional immunocompetence and an enhancement of the systemic immunocompetence initiated by DMH preceded the development of the initial colorectal lesions. In Phase II, an enhanced regional and systemic immunity corresponded to morphogenetic changes in the colorectal epithelium representing a transition from hyperplasia to neoplasia. In Phase III, a reduction in both regional and systemic immunocompetence was associated with the growth of adenocarcinomas. Subsequently, systemic immunity, as indicated by the continued depression of mitogen reactivity and the depletion of the splenic white pulp, was abrogated concomitantly with the increase in tumor burden. Regional immunity, however, recovered and became enhanced simultaneously with the appearance of invasive adenocarcinomas.

The observations indicated a DMH-initiated, tumor development-mediated modulation of immunocompetence. This modulation resulted in a compromise, a dynamic tumor-host interaction which favors the ultimate development of invasive colorectal adenocarcinomas.

## INTRODUCTION

Experimental models for the study of colon tumor development have been described for rats, mice, and hamsters (4, 8, 9, 22, 29). Currently, models utilize DMH<sup>3</sup> or azoxymethane, the synthetic analogs of cycasin, for the induction of colorectal tumors (9, 10, 29, 35, 46, 47, 50). The histological similarity of the induced lesions to colon tumors of humans emphasizes the relevance of these tumor models in the study of colon tumor development (10, 24, 25, 32, 47).

A recent report from our laboratory on the sensitivity of 5 different strains of mice to DMH-induced colon tumor development supports the functional role of genetic factors in the determination of susceptibility to chemical carcinogenesis (9). Among the mice studied, SWR/J and P/J mice were the most susceptible, with colorectal tumor incidences of 85 and 80%, respectively. The high incidence of colorectal adenocarcinomas, associated with only occasional anal tumors, makes the SWR/J model especially suitable for the study of the morphogenesis and immunology of colorectal tumor development.

Information on the influence of DMH or tumor growth on the immune system of animals during colorectal carcinogenesis is not yet available. Chemical carcinogens and the progressive growth of tumors are both known to depress immunological competence (2, 23, 37, 38, 43, 44). While carcinogen-induced immunosuppression is not an absolute requirement of chemical carcinogenesis (39-41), the results of some recent studies imply that immunocompetence during colorectal carcinogenesis is depressed. Immunological surveillance, which theoretically incorporates the necessity of immunosuppression for the successful development of antigenic tumors, has recently been reported to be functional during DMH-induced colon carcinogenesis in rats (2). Similarly, *Bacillus Calmette-Guérin* immunotherapy, which requires for its success immunological competence (19, 20, 26), has been unsuccessful in DMH-treated animals (36). The results of these studies indicate an immunological deficiency in animals undergoing DMH-induced colon carcinogenesis.

To study the possibility of DMH- and/or tumor growth-induced modulation of host immunity, we examined systematically the morphogenesis of colon tumors as related to concomitant changes in the immunological competence of SWR/J mice during and after treatment with DMH. The histological study of neoplastic development in the colon, the histological evaluation of cellular changes in the organs of the immune system, and the monitoring of the mitogenic responses of T- and B-lymphocytes during carcinogenesis were utilized for this purpose.

<sup>1</sup> Research conducted at Meloy Laboratories, Inc.

<sup>2</sup> To whom requests for reprints should be addressed, at Meloy Laboratories, Inc., 6715 Electronic Drive, Springfield, Va. 22151.

Received August 24, 1979; accepted April 15, 1980.

<sup>3</sup> The abbreviations used are: DMH, 1,2-dimethylhydrazine; Con A, concanavalin A; LPS, lipopolysaccharide W (*Escherichia coli*, serotype O111:B4:H).

## MATERIALS AND METHODS

**Animals.** Male SWR/J mice (The Jackson Laboratory, Bar Harbor, Maine), 4 to 5 weeks old, were used for the carcinogenesis studies. The SWR/J strain was selected because of its known susceptibility for colon tumor induction by DMH (9). The mice were maintained 5/cage and were given free access to food and water.

**Carcinogen Treatment.** DMH·2HCl (Aldrich Chemical Company, Milwaukee, Wis.) was used to induce colon tumors by chronic administration. One hundred twenty-five mice were given s.c. injections of 15 mg DMH per kg body weight per week for 20 weeks. An equal number of mice treated with 0.9% NaCl solution for 20 weeks served as age-matched controls. Before injection, DMH·2HCl was dissolved in 0.9% NaCl solution; this solution also contained 1.5 mg EDTA per 100 ml. The pH was adjusted to 6.5 with 0.25 M NaOH.

**Histology.** Three DMH-treated and 3 control mice were necropsied every 2 weeks during the study. After gross examination of the organs for tumors, the colorectal segment of the intestine, mesenteric lymph nodes, spleen, thymus, liver, lungs, and kidneys were prepared for histological study, using routine techniques (9). The criterion for malignancy of colorectal lesions was the invasion of the lesion through the muscularis mucosae.

**Blastogenesis Assays.** Lymphocyte blastogenesis was assayed according to previously described protocols (16, 17). Lymphocyte cultures were stimulated with Con A (Calbiochem, Los Angeles, Calif.) for T-cell blastogenesis and with bacterial endotoxin (LPS; Difco, Detroit, Mich.) for B-cell blastogenesis. Control experiments conducted in our laboratory with spleen cells of conventional and athymic nude mice confirmed the mitogenic specificity of Con A for T-cells and LPS for B-cells.

To monitor the immunological competence of mice, lymphocytes from spleens and mesenteric lymph nodes were isolated for blastogenesis assays biweekly from 3 carcinogen-treated and 3 control mice. The tritium content of cells was assayed according to standard procedures (16, 17). The results were calculated by subtracting the cpm obtained for nonstimulated cultures from the cpm of mitogen-stimulated cultures. Tritiated thymidine incorporation per  $10^6$  Con A-stimulated cells from control mice ranged from  $8,689 \pm 1,032$  (S.D.) to  $27,147 \pm 3,312$  cpm for splenic lymphocytes and from  $464 \pm 167$  to  $78,940 \pm 8,093$  cpm for lymph node lymphocytes. For LPS-stimulated cells of controls, the counts ranged from  $2,411 \pm 364$  to  $11,510 \pm 800$  cpm for splenic lymphocytes and from  $184 \pm 32$  to  $7,961 \pm 1,071$  cpm for lymph node cells. Since the mitogenic response of vehicle control mice varied considerably during the period of study, the mitogenic response of DMH-injected animals was plotted as the percentage of tritiated thymidine incorporation by lymphocytes obtained from vehicle-treated animals. The significance of differences in the blastogenic response between carcinogen-treated and control animals was determined according to Student's *t* test.

## RESULTS

### Histopathology of DMH-induced Colorectal Carcinogenesis

DMH-induced morphological changes occurring in the colorectal mucosa during tumorigenesis were divided into 4 stages.

Each successive stage represented a histologically identifiable qualitative or quantitative change in the morphogenesis of colorectal adenocarcinomas.

**Stage 1. Development of Hyperplasia.** Comparison of the colorectal mucosa of DMH- and vehicle-treated mice showed no significant alterations in morphology during the first 6 DMH treatments. Hyperplasia of the colorectal epithelium became apparent after 8 DMH injections. At this time, 1 of 3 DMH-treated animals had moderate hyperplasia of the colorectal epithelium (Figs. 1 and 4). The height of colonic crypts was approximately 1.5 times the height of the crypts in controls.

**Stage 2. Appearance of Atypia.** By the 12th DMH treatment, large segments of the colon showed diffuse epithelial hyperplasia in all animals, and 1 of 3 mice had small focal atypia associated with the hyperplastic colonic surface epithelium. Between 12 and 18 DMH treatments, the number of atypical lesions increased and were present at multiple sites in all colons examined (Fig. 2).

Atypias associated with the hyperplastic colorectal epithelium varied in size. Small areas of atypias, restricted in their extent to the surface epithelium, were referred to as focal atypias. Cytologically focal atypias were indistinguishable from more extensive atypias with branching epithelial folds which sometimes extended deep into the mucosa. These neoplastic lesions were composed of hyperchromatic columnar cells of increased height, which had enlarged, elongated nuclei and a luminal brush border. The epithelium in these areas lacked mucin droplets characteristic of the presence of goblet cells. Atypical lesions with minimal development of glandular structures were classified as *in situ* carcinomas, because they apparently gave rise to the more extensive noninvasive adenocarcinomas.

**Stage 3. Development of Noninvasive Carcinomas.** By the termination of DMH injections at the 20th week, the neoplastic lesions developed a glandular structure extending in many cases to the muscularis mucosae. These noninvasive adenocarcinomas tended to protrude into the lumen of the colon, often forming grossly identifiable nodules (Fig. 5). Between the 20th and 38th weeks, *in situ* carcinomas and/or adenocarcinomas were readily identifiable in all histological preparations of the colon. Eighty-three % of the mice examined had grossly visible lesions. During this period, hyperplasia of the epithelium adjacent to the neoplastic lesions was less pronounced and appeared to be regressive.

**Stage 4. Appearance of Invasive Carcinomas.** Between the 32nd and 38th weeks, 3 of 9 animals examined histologically already developed invasive adenocarcinomas, and 6 had noninvasive adenocarcinomas. Of the invasive adenocarcinomas, 2 consisted of well-differentiated glandular structures, some of which penetrated through the muscularis mucosae into the submucosa. The third invasive adenocarcinoma also contained masses of free malignant cells which had metastasized to the surrounding areas (Fig. 3). These free malignant cells retained their epithelial polarity, as indicated by the presence of a striate border at a defined segment of their plasma membrane (Fig. 6). No mucinous adenocarcinomas were observed in this study.

### Immune Responses during DMH-induced Colorectal Carcinogenesis

Significant overall changes in the immunological profile of DMH-treated mice occurred in 3 phases. In Phase I (1 to 12

weeks), the immunological profile was characterized by a convergent change in the proliferative responses of the spleen and draining lymph nodes. This resulted from the return of the mitogen reactivity of the spleen and lymph nodes to control levels from a previously enhanced state in the spleen and from an initially depressed state in the mesenteric lymph nodes. During Phase II (Weeks 12 to 28), the proliferative responses in these organs tended to continue the opposing trend, resulting in a somewhat depressed immunological profile in the spleen and its enhancement in the draining lymph nodes. In Phase III (Weeks 28 to 38), the inverse tendency in the mitogenic responses of the spleen and lymph nodes was further exaggerated by a permanent depression in the spleen and its renewed enhancement in the draining lymph node.

#### Phase I

**Blastogenesis.** Changes in the mitogenic responses of T- and B-cells, as reflected by their reactivity to Con A and LPS, respectively, were enhanced in the spleen. Splenic T-cell responses were 100% greater after 2 DMH injections than in controls (Chart 1A). By the sixth DMH injection, the response declined to control levels and remained there through the tenth week.

Although the profile of splenic B-lymphocyte reactivity was similar to that of T-cells, the initial increase after 2 DMH injections was not significant (Chart 1B). At the tenth treatment, B-cell blastogenesis was 2-fold greater than in controls but dropped below control levels by the 12th week.

In contrast to the initial enhancement of splenic mitogen reactivity, T- and B-lymphocyte reactivity in the mesenteric lymph node was significantly depressed by the second DMH injection. Recovery from this depression was complete by the tenth week, with the Con A reactivity of T-cells recovering slightly earlier than the LPS reactivity of B-cells.

**Histology.** The increased blastogenic activity of splenic lymphocytes after the initial DMH injections was reflected in the histological appearance of the spleen. Before the first DMH injection, only a few primary follicles and germinal centers were visible in the splenic white pulp (Fig. 14). By the second and third DMH injections, the number of primary lymphoid follicles and germinal centers had approximately doubled per longitudinal sections of the spleen (Table 1). The germinal centers were well developed and active as judged by the large numbers of mitotic figures. The thymus-dependent areas of lymphocytes surrounding the central arterioles were also prominent (Fig. 15). In control mice during this phase, the white pulp was well defined but contained only occasional small lymphoid follicles with inactive germinal centers. In comparison to controls, in the splenic red pulp an increase in the number of mononuclear cells and an increase in granulopoiesis became apparent after the fourth DMH injection (Fig. 18).

The depressed blastogenic activity of lymphocytes in the mesenteric lymph nodes, in spite of considerable variation of lymph node histology, could be correlated with the relative sparsity of cells in the paracortical areas and the absence of germinal centers in the cortex after the first few DMH injections. At that time, lymph node morphology in carcinogen-treated mice was characterized by the sharp demarcation of the cortex and medulla typically seen in the mesenteric lymph node of controls (Fig. 10).

In Phase I, Peyer's patches associated with the colorectal

CHANGE IN BLASTOGENIC RESPONSE FROM CONTROL LEVEL (%)

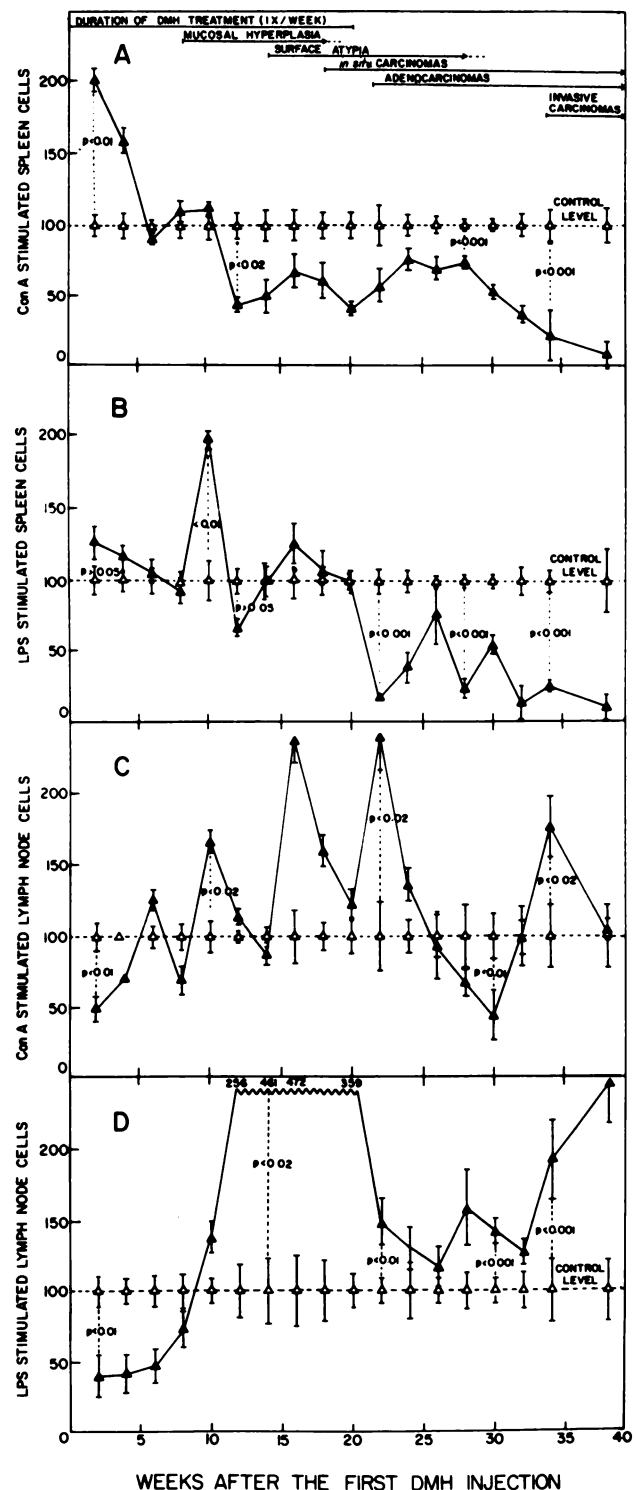


Chart 1. Percentage of changes in the Con A- and LPS-induced responses of splenic and regional (mesenteric) lymph node lymphocytes in DMH (▲) and vehicle (△)-injected mice during colorectal tumor development. Control responses were considered to be 100%. Changes in the blastogenic response of DMH-treated animals were plotted as the percentage of the control response. Observe the tendency for contrasting changes in the spleen and the draining lymph node. Bars, S.D.

segment of the intestine were morphologically similar in control and DMH-treated mice. These Peyer's patches were characterized by large active germinal centers and dense crowns of lymphocytes (Fig. 7).



Table 1  
Representative numbers of germinal centers per spleen and lymph node sections of control and carcinogen-treated mice

Organ	Treatment	No. of germinal centers at indicated times after first DMH treatment						
		0-1 wk	1-6 wk	6-12 wk	12-20 wk	20-26 wk	26-32 wk	32-38 wk
Spleen <sup>a</sup>	Vehicle	1-2 <sup>b</sup>	2-3	2-4	2-4	2-4	3-5	2-4
	DMH	1-2	3-7	6-8	4-6	1-3	0-1	0
Lymph node <sup>c</sup>	Vehicle	0	0	0-1	0-1	0-1	0-1	0-1
	DMH	0	0	1-2	1-3	0-1	0-2	1-2

<sup>a</sup> Number of germinal centers observed per midsagittal section.

<sup>b</sup> Values indicate the range for the number of germinal centers counted in sections from 3 mice biweekly.

<sup>c</sup> Number of germinal centers observed in the cortex per equivalent cortical area.

## Phase II

**Blastogenesis.** After the 12th DMH injection, at the beginning of the second phase, the mitogenic response of splenic T-cells dropped and was less than 50% of the control response. With minor fluctuations, the mitogenic response of splenic T-cells remained near this level until the end of this phase at the 28th week (Chart 1A).

Between the 11th and 20th DMH injections, the B-cell response fluctuated around control levels. Toward the end of Phase II, the fluctuation became greater; after the last (20th) DMH injection and again at the 28th week, the LPS reactivity of B-cells became depressed and was only 80 to 85% of the control responses (Chart 1B).

In contrast to the depression observed in splenic lymphocyte reactivity to mitogens, the blastogenic responses of mesenteric lymphocytes were primarily enhanced in Phase II (Chart 1, C and D). T-cell responses were characterized by increasing periodic enhancements, which began at the tenth DMH injection and continued after the termination of the carcinogen treatment. Periodic enhancements of 137 and 140% above control levels were observed toward the end of Phase II.

The mitogenic response of mesenteric lymph node B-cells was also enhanced in Phase II. This enhancement occurred rapidly, reaching 256% after the 12th DMH injection, reaching a peak of 472% at the 16th DMH injection and declining to control levels at the end of Phase II (Chart 1D).

**Histology.** Early in Phase II, in the spleens of carcinogen-treated mice, there was a 2- to 3-fold increase in germinal center activity in comparison to controls. Subsequently, the number of germinal centers in the spleen fluctuated and drastically declined by the 26th week. This was accompanied by a general reduction in the splenic white pulp, which correlates especially with the depression of the mitogen reactivity of splenic B-lymphocytes during the second part of this phase.

The gradual reduction in the splenic white pulp began simultaneously with the rapid development of extensive granulopoiesis in the red pulp. The spleens of control animals were characterized throughout the study by the presence of occasional germinal centers in the white pulp and hemopoietic islands, a few granulocytes, and megakaryocytes in the red pulp (Figs. 14 and 17). The moderate increase in red pulp granulopoiesis, first observed after 4 DMH injections, became extensive. By the 12th DMH injection, hemopoietic islands were considerably reduced, and the splenic red pulp was crowded with granulocytes in various phases of their differentiation (Fig. 19). The splenic red pulp of DMH-treated mice

remained granulopoietic through the 30th week of the study.

During this period, the division between cortex and medulla in the mesenteric lymph nodes became less distinct. This was apparently due to an increase in the concentration of paracortical and medullary lymphocytes (Fig. 11). The medullary cords of control mice contained mostly plasma cells and large lymphocytes while, in DMH-injected mice, small to medium-sized lymphocytes were predominant in the paracortex, medullary cords, and sinuses. The germinal centers in carcinogen-treated mice were slightly more numerous than in controls (Table 1). These germinal centers appeared larger and more active as judged by the number of mitotic figures.

Between 12 and 14 DMH treatments, Peyer's patches increased in size in the carcinogen-treated mice. This increase coincided with the appearance of atypia in the colonic epithelium. In several instances, the lymphocytes of Peyer's patches appeared to infiltrate the hyperplastic epithelium. At foci associated with extensive lymphocytic infiltration, the hyperplastic or neoplastic epithelium appeared to be disrupted, exfoliative, or necrotic (Fig. 8). By the end of the period of carcinogen treatment, Peyer's patches appeared smaller, and solitary lymphoid nodules were seen less frequently. In general, the morphological changes observed in Peyer's patches tended to follow the rise and fall pattern observed for the blastogenic changes of B-lymphocytes in the spleen and mesenteric lymph node.

## Phase III

**Blastogenesis.** After the 28th week of the study, the blastogenic responses of both T- and B-cells progressively diminished. By the 38th week, the Con A and LPS reactivity of splenic lymphocytes constituted only about 10% of the control response (Chart 1, A and B).

In the early part of Phase III, the mesenteric lymph node T-cell responses became temporarily depressed. After recovery and a temporary enhancement, the blastogenic response of T-cells returned to control levels by the 38th week of the study (Chart 1C).

The blastogenic responses of mesenteric lymph node B-cells, which fluctuated near control levels at the start of Phase III, increased progressively after the 32nd week. At the termination of the study, the blastogenic response of B-cells was 145% greater in tumor-bearing mice than in controls (Chart 1D).

**Histology.** The reduction of the splenic white pulp initiated in Phase II continued in Phase III at an accelerated rate. In

general, by the 30th week, the white pulp was reduced to a sparsely cellular cuff of lymphocytes around the central arterioles (Fig. 16).

The red pulp of DMH-treated mice remained granulopoietic through the 30th week of the study. However, by the 35th week, the red pulp regained its normal hemopoietic appearance. The morphology of the red pulp in several animals with adenocarcinomas of the colon was similar to that of controls at the end of the study.

In Phase III, the morphology of the mesenteric lymph node continued to vary. The cortex was poorly defined, and the number of germinal centers was only slightly greater than in controls (Table 1). The medullary sinuses were dilated and appeared edematous. The medullary cords contained accumulations of plasmacytic cells.

Peyer's patches and solitary lymphoid nodules were seen infrequently in Phase III. Inflammatory infiltrates were primarily associated with invasive malignant lesions and consisted of accumulations of plasma cells, neutrophils, and a few lymphocytes (Figs. 12 and 13).

The morphology of the thymus, lung, kidney, and liver, which was monitored throughout the study, showed no significant alterations. These organs appeared to be free of pathological lesions in both DMH-treated and control mice.

## DISCUSSION

Modulation of immunocompetence was demonstrated in DMH-treated SWR/J mice in a correlative study, utilizing mitogenic stimulation of T- and B-lymphocytes, histological parameters of lymphoid tissue immune responses, and morphogenetic changes during DMH-induced colorectal tumor development. The morphogenesis of colorectal tumors in this DMH-sensitive mouse strain closely paralleled the developmental stages of chemically induced intestinal carcinomas in rats and other mouse strains (4, 10, 22, 32, 35, 46, 49, 50). The observed modulation of immunocompetence appeared to be a DMH-initiated, tumor development-mediated process. This modulation involved significant alterations in the normal regional (draining lymph node) and systemic (splenic) immunity in 3 distinct phases. The triphasic pattern of this modulation was correlated with the latency of appearance of colorectal lesions, tumor progression, and the development of invasive adenocarcinomas.

The observed *in vitro* changes in lymphocyte mitogen reactivity and the corresponding histological parameters of *in vivo* immune responses indicate an active role for the immune system during DMH-induced colorectal carcinogenesis. However, correlations between tumor development and the modulation of the immunological profile of SWR/J mice would be significant only if colon tumor development is at least partially influenced by immunity.

That colorectal tumor growth is controlled by host immunity was suggested by preliminary transplantation studies. According to these studies, the survival time of DMH-induced colorectal tumor transplants doubled in immunosuppressed mice as compared to normal syngeneic recipients.<sup>4</sup> The increase in survival time from approximately 14 to 31 days indicated the immunogenicity of the colorectal tumors. It is presumed that at

least some developing DMH-induced tumors would also be immunogenic in the original host. This assumption is supported by the demonstration of the controlling influence of immunity on the DMH-induced development of colon tumors in rats by Bansal *et al.* (2). They reported that prolonged DMH treatment of immunosuppressed animals resulted in reduced tumor latency, increased multiplicity, and tumor incidence of colon carcinomas. An additional report dealing with the immunological characterization of DMH-induced colon tumors in rats demonstrated the existence of colon tumor-associated antigens (15). Therefore, it is reasonable to expect interaction between colorectal tumor development and host immunity.

Phase I modulation, the transient depression of the regional and the temporary enhancement of systemic immunocompetence, preceded the development of diffuse colorectal hyperplasia. Diffuse colorectal hyperplasia is a constant feature of DMH-induced colon carcinogenesis in SWR/J mice, but it varied in the extent of its development in other animal models (32, 47). It can also be elicited by a variety of irritants (3, 31, 34). Diffuse colorectal hyperplasia, while proliferative, does not form adenomatous polyps in SWR/J mice as do the suspected precancerous lesions in the colon or rectum of humans and other experimental models (49–51). However, recent reports confirmed the tumor-promoting role of colonic hyperplasia and nonspecific injury in colon carcinogenesis (4, 31). Furthermore, epithelial atypia, a precursor to colorectal carcinoma, consistently developed in the hyperplastic colorectal mucosa of SWR/J mice. Thus, the temporal relationship of the earliest stages of colorectal tumor development to the Phase I modulation of immunocompetence suggests that the DMH-induced perturbation of the normal profile of the regional and systemic immunity supports the subsequent stages of tumorigenesis.

Specifically, since draining lymph nodes normally function in the initiation and maintenance of cell-mediated immune responses to tumors (11, 12), the temporary suppression of regional immunocompetence in Phase I would create a deficiency in the afferent arm of the immune system. This would prevent recognition of developing antigenic DMH-induced neoplastic clones in the hyperplastic mucosa. Depending on the immunogenicity of such clones, this hypothesis would be consistent with the theory of immunosurveillance (6).

The Phase I enhancement of systemic immunity was also detectable before tumorigenesis. Therefore, it must also be related to the influence of the initial DMH treatments. This increase in splenic immune reactivity consisted of: (a) the successive enhancement of splenic T- and B-cell mitogen reactivity; and (b) the increase in the number of active splenic germinal centers along with an increase in the cellularity of thymus-dependent areas. These functional and morphological components together indicate that the enhanced mitogen reactivity is due primarily to an increase in the T- and B-cell fraction of the nucleated spleen cells tested.

An increase in the number and activity (mitotic index) of splenic germinal centers and in the cellularity of thymus-dependent areas, like that observed during Phase I, has been associated with specific humoral immune responses to exogenous antigens in mice (1, 18, 28, 30, 42, 48). Thus, the increased germinal center development in Phase I is interpreted as an indication of a DMH-initiated splenic immune response. Since this response occurs before the development of neo-

<sup>4</sup> A. K. Szakal and B. A. Diwan, unpublished observations.

plastic lesions, it is not expected to represent an immunological host resistance against colorectal carcinogenesis.

Active splenic germinal centers also persisted into the second phase of modulation, which was associated with the transition of hyperplasia to neoplasia. Thus, the splenic immune response is not as short-lived as indicated by mitogen reactivity. The reason for this discrepancy between splenic lymphocyte mitogen reactivity and white pulp morphology in Phase II was suggested by the extensive granulopoietic activity in the splenic red pulp.

An increase in the nucleated cells of the red pulp is known to dilute the mitogenic response of splenic lymphocytes during *in vitro* stimulation (17). Therefore, on the basis of histological approximations of granulocyte/lymphocyte ratios in experimental and control spleens, it was estimated that a minimum of 30 to 50% reduction in the mitogenic response of spleen lymphocytes occurred *in vitro*. Consequently, the sudden reduction in the mitogenic responses of splenic T- and B-cells at the beginning of Phase II (see Chart 1) may be at least partially due to a dilution effect caused by the increase in the number of splenic granulocytes in DMH-treated animals. Since the accuracy of blastogenesis assays was jeopardized by the dilution effect, we utilized morphological criteria for the interpretation of the immunological status of the spleen during this phase.

We estimated that in Phase II (between 12 and 26 weeks) T-cell activity in the spleen was within the control range (*i.e.*, size and cellularity of thymus-dependent areas were similar to those of the controls). On the other hand, B-cell activity (*i.e.*, number of active germinal centers) between 12 and 22 weeks was greater in the spleen than in controls and between 22 and 26 weeks was less than in controls. On the basis of these morphological estimates, we concluded that, at least in the first half of the Phase II modulation, splenic immune reactivity was enhanced and that it declined by the end of Phase II.

Tumor progression occurring during the first half of Phase II modulation consisted of: (a) the transition of the hyperplastic to the neoplastic atypical epithelium; (b) the development of *in situ* carcinomas; and (c) the growth of *in situ* carcinomas into noninvasive adenocarcinomas. The transition of the hyperplastic to the atypical epithelium was characterized by qualitative changes as indicated by the increased basophilia and hyperchromasia of epithelial cells. Pozharisski (32) classified morphologically similar neoplastic lesions (atypia) in rats as *in situ* carcinomas. He based this on the presence of aerobic glycolysis in these lesions, which is inherent in malignant cells. In the SWR/J model, we reserved the term *in situ* carcinoma for the more advanced atypical lesions, which showed the initial development of glandular structures. These *in situ* carcinomas were qualitatively similar to surface atypia and differed only quantitatively from the larger noninvasive adenocarcinomas.

The morphological expression of neoplastic transformation, therefore, corresponded to the first half of the Phase II modulation, when both regional and systemic immunity was enhanced. The growth of adenocarcinomas, however, was closely associated with the second half of Phase II, which was characterized by a declining regional and systemic immunocompetence.

The temporal association of the enhanced regional and systemic immunity with tumor progression in Phase II suggests

that the functionally and histologically detectable proliferative activities in the draining lymph node and in the spleen reflect a tumor progression-induced stimulation of host immunity. As proposed by the theory of "immunostimulation" (33), a mild degree of antitumor immunity may benefit tumor growth. The enhanced proliferative activity, especially in the draining lymph node, however, represents an extensive cellular response in the afferent arm of the immune system of SWR/J mice to tumor progression. The morphologically observable immune reactivity associated at that time with colorectal lesions (see Figs. 8 and 9) and the less than 100% (85%) tumor incidence in this model coupled with a significant proliferative activity in the lymphoid organs could represent at least a partially successful immunological host defense mechanism.

The role of the spleen in DMH-induced colorectal carcinogenesis should also be considered from the point of view of the extensive myeloid metaplasia, especially since similar granulopoietic activity is known to occur during the growth of a variety of transplanted tumors in the spleen and/or the bone marrow (5, 13, 17, 21). We have accounted for the *in vitro* effects of red pulp granulopoiesis on mitogenic stimulation in Phase II; however, its *in vivo* effects need clarification. *In vivo*, the extensive red pulp granulopoiesis may contribute to host defense, or it may have a detrimental microenvironmental influence on the splenic immune response.

Granulocytes have been implicated in nonspecific resistance against tumor growth (7, 14, 27, 45). A possible expression of this capability is seen in the prominent granulocytic infiltrations associated with the colorectal carcinomas in their invasive stage of development (see Figs. 6 and 13). The time of infiltration of these lesions correlated well with the disappearance of granulocytes from the splenic red pulp. Aside from the possible tumoricidal or bacteriocidal role of this response in carcinogenesis, the red pulp congestion resulting from the myelopoietic metaplasia is suspected to impede splenic circulation.<sup>5</sup> Such an effect of this proliferative response can be detrimental in that it would hinder the expression of a potential splenic antitumor immune response.

Phase III modulation of immunocompetence began with the simultaneous reduction in regional and systemic immunity (see Chart 1; 28 to 31 weeks). A general reduction in the cellularity and size of the splenic white pulp and in the cellularity of the paracortical areas in the draining lymph node accompanied the reduced mitogen reactivity. Peyer's patches and solitary lymphoid nodules associated with the colorectal intestine were also less prominent than before. This overall decline in immunocompetence occurred nearly 6 weeks after the termination of carcinogen administration and correlated with the progressive increase in tumor burden. It is unlikely, therefore, that this reduction was due to DMH, but it may be related to the effects of the increasing tumor burden. This contention is supported by reports on the immunosuppressive effects of tumor growth (16, 17, 23, 37, 44).

In spite of the continued increase in tumor burden and the abrogation of splenic immunocompetence, the proliferative capacity of lymph node lymphocytes recovered and increased

<sup>5</sup> D. Z. Wyler, T. C. Quinn, and L. T. Chen. Host defense in rodent malaria: relationship of alterations in splenic microcirculation to resolution of acute infection, submitted for publication.



significantly during Phase III. This increase corresponded to the development of invasiveness in adenocarcinomas. The progressive increase in B-cell mitogen reactivity, the accumulation of plasmacytic cells in the medulla of the draining lymph node and along the invasive fronts of adenocarcinomas (see Fig. 13) appears to represent a regional humoral immune response.

Regardless of the various immune reactivities observed during colorectal carcinogenesis of SWR/J mice, tumor development succeeds. Thus, the DMH-initiated modulation of immunity appears to represent a compromise, a dynamic tumor-host interaction, which ultimately favors the development of invasive colorectal adenocarcinomas.

## ACKNOWLEDGMENTS

The authors wish to thank Adrienne Fox, John Smith, and Alice Dempster for valuable technical assistance; Gregg Crumley for the statistical analysis; and Valerie Coleman for the typing of the manuscript.

## Note Added in Proof

A recent publication (Belnap, L. P., Cleveland, P. H., Colmerauer, M. E. M., Barone, R. M., and Pilch, Y. H. Immunogenicity of chemically induced murine colon cancers. *Can. Res.*, 39: 1174-1179, 1979.) deals with the antigenicity and immunogenicity of DMH and *N*-methyl-*N*-nitrosourea-induced BALB/c colorectal carcinomas. The demonstration, that mouse colon tumors possess weak to moderately strong, individually unique tumor-specific transplantation antigens, emphasizes the relevance of the DMH-initiated, tumor development-mediated modulation of host immunity to colorectal tumorigenesis in mice.

## REFERENCES

1. Ada, G. L. Specialized cell function in the lymphoid and reticuloendothelial series. In: E. Mihich (ed.), *Immunity, Cancer, and Chemotherapy*. New York: Academic Press, Inc., 1967.
2. Bansal, S. C., Mark, R., Bansal, B. R., and Rhodas, E., Jr. Immunologic surveillance against chemically induced primary colon carcinoma in rats. *J. Natl. Cancer Inst.*, 60: 667-675, 1978.
3. Barthold, S. W. Autoradiographic cytokinetics of colonic mucosal hyperplasia in mice. *Cancer Res.*, 39: 24-29, 1979.
4. Barthold, S. W., and Jonas, A. M. Morphogenesis of early 1,2-dimethylhydrazine-induced lesions and latent period reduction of colon carcinogenesis in mice by a variant of *Citrobacter freundii*. *Cancer Res.*, 37: 4352-4360, 1977.
5. Boggs, D. R., Malloy, E., Boggs, S. S., Chervenick, P. A., and Lee, R. E. Kinetic studies of a tumor induced leukemoid reaction in mice. *J. Lab. Clin. Med.*, 89: 80-92, 1977.
6. Burnet, F. M. The concept of immunologic surveillance. *Prog. Exp. Tumor Res.*, 13: 1-27, 1970.
7. Clark, R. A., and Klebanoff, S. J. Neutrophil mediated tumor cell cytotoxicity: role of peroxidase system. *J. Exp. Med.*, 141: 1442-1447, 1975.
8. Deschner, E. E. Experimentally induced cancer of the colon. *Cancer (Phila.)*, 34: 824-828, 1974.
9. Diwan, B. A., Meier, H., and Blackman, K. E. Genetic differences in the induction of colorectal tumors by 1,2-dimethylhydrazine in inbred mice. *J. Natl. Cancer Inst.*, 59: 455-458, 1977.
10. Druckrey, H. Production of colonic carcinomas by 1,2-dialkylhydrazines and azoxyalkanes. In: W. J. Burdette (ed.), *Carcinoma of the Colon and Antecedent Epithelium*, pp. 267-279. Springfield, Ill.: Charles C Thomas, Publisher, 1970.
11. Fisher, B., and Fisher, E. R. Studies concerning the regional lymph node in cancer. I. Initiation of immunity. *Cancer (Phila.)*, 27: 1001-1004, 1971.
12. Fisher, B., Saffer, E., and Fisher, E. R. Studies concerning the regional lymph node in cancer. IV. Tumor inhibition by regional lymph node cells. *Cancer (Phila.)*, 33: 631-636, 1974.
13. Fisher, W. F. Immunology and histopathology of the hamster-SV40 tumor system. A. Correlations of host response and antigen processing. B. Prophylactic and therapeutic effects of BCG on transplantation immunity, pp. 18-22. Ph.D. Dissertation, University of Tennessee, Knoxville, Tennessee, 1973.
14. Gale, R. P., and Zighelboim, J. Modulation of polymorphonuclear leukocyte-mediated antibody-dependent cytotoxicity. *J. Immunol.*, 113: 1793-1800, 1974.
15. Garmaise, A. B.-K., Rogers, A. E., Saravis, C. A., Zamcheck, N., and Newberne, P. M. Immunologic aspects of 1,2-dimethylhydrazine-induced colon tumors in rats. *J. Natl. Cancer Inst.*, 54: 1231-1235, 1975.
16. Gillette, R. W., and Boone, C. W. Changes in phytohemagglutinin response due to presence of tumors. *J. Natl. Cancer Inst.*, 50: 1391-1393, 1973.
17. Gillette, R. W., and Boone, C. W. Changes in the mitogen response of lymphoid cells with progressive tumor growth. *Cancer Res.*, 35: 3774-3779, 1975.
18. Hanna, M. G., Jr. Germinal center changes and plasma cell reaction during the primary immune response. *Int. Arch. Allergy Appl. Immunol.*, 26: 230-251, 1965.
19. Hanna, M. G., Jr., Snodgrass, M. J., Zbar, B., and Rapp, H. J. Histopathology of tumor regression after intralesional injection of *Mycobacterium bovis*. IV. Development of immunity to tumor cells and to BCG. *J. Natl. Cancer Inst.*, 51: 1897-1908, 1973.
20. Hanna, M. G., Jr., Szakal, A. K., and Peters, L. C. The balance of host immunocompetence in chemical carcinogenesis and "nonspecific" immunotherapy. *Recent Results Cancer Res.*, 52: 114-135, 1975.
21. Kodama, T., Sendo, F., and Kobayashi, H. Leukemoid reaction in BALB/c mice bearing transplanted tumors. *Cancer Res.*, 34: 176-180, 1974.
22. Lev, R., and Herp, A. Pathogenesis of rat colon carcinomas induced by *N*-methyl-*N*-nitrosourea. *J. Natl. Cancer Inst.*, 61: 779-786, 1978.
23. Linder, O. E. A. Survival of skin homografts in methylcholanthrene treated mice and mice with spontaneous mammary cancers. *Cancer Res.*, 22: 380-383, 1962.
24. Lipkin, M. Proliferative changes in the colon. *Am. J. Dig. Dis.*, 19: 1029-1032, 1974.
25. Lohrs, U., Wiebecke, B., and Eder, M. Morphologische und autoradiographische Untersuchung der Darmschleimhaut veränderungen nach einmaliger Injektion von 1,2-Dimethylhydrazin. *Z. Gesamte Exp. Med.*, 151: 297-307, 1969.
26. Morton, D. L., Eilber, F. R., Malmgren, R. A., and Wood, W. C. Immunological factors which influence response to immunotherapy in malignant melanoma. *Surgery*, 68: 158-163, 1970.
27. Nakayama, M., Sendo, F., Miyake, T., Fuyama, S., Arai, S., and Kobayashi, H. Nonspecific inhibition of tumor growth by allosensitized lymphocytes. I. Participation of polymorphonuclear leukocytes. *J. Immunol.*, 120: 619-623, 1978.
28. Nossal, G. J. V., Abbot, A., Mitchell, J., and Lummus, Z. Antigens in immunity. XV. Ultrastructural features of antigen capture in primary and secondary lymphoid follicles. *J. Exp. Med.*, 127: 277-290, 1968.
29. Oswald, H., and Kruger, F. W. Die carcinogene Wirkung von 1,2-Dimethylhydrazin beim Goldhamster. *Arzneim. Forsch.*, 19: 1891-1892, 1969.
30. Parrott, D. M. V., de Sousa, M. A. B., and East, J. Thymus-dependent areas in the lymphoid organs of neonatally thymectomized mice. *J. Exp. Med.*, 123: 191-209, 1965.
31. Pozharisski, K. M. The significance of nonspecific injury for colon carcinogenesis in rats. *Cancer Res.*, 35: 3824-3830, 1975.
32. Pozharisski, K. M. Morphology and morphogenesis of experimental epithelial tumors of the intestine. *J. Natl. Cancer Inst.*, 54: 1115-1135, 1975.
33. Pohn, R. T. The immune reaction as a stimulator of tumor growth. *Science (Wash. D. C.)*, 176: 170-171, 1972.
34. Ranken, R., Wilson, R., and Bealmeier, P. M. Increased turnover of intestinal mucosal cells of germ-free mice induced by cholic acid. *Proc. Soc. Exp. Biol. Med.*, 138: 270-272, 1971.
35. Reddy, B. S., Narisawa, T., Wright, P., Vukusich, D., Weisburger, J. H., and Wynder, E. L. Colon carcinogenesis with azoxymethane and dimethylhydrazine in germ-free rats. *Cancer Res.*, 35: 287-290, 1975.
36. Rogers, A. E., and Gildin, J. Effect of BCG on dimethylhydrazine induction of colon tumors in rats. *J. Natl. Cancer Inst.*, 55: 385-391, 1975.
37. Rowland, G. F., Edwards, A. J., Hurd, C. M., and Summner, M. R. Changes in lymphoreticular tissues during growth of a murine adenocarcinoma. III. Plaqueforming cell response in lymph nodes and spleen. *J. Natl. Cancer Inst.*, 47: 321-327, 1971.
38. Stjernsward, J. Effect of noncarcinogenic and carcinogenic hydrocarbons on antibody-forming cells measured at the cellular level *in vitro*. *J. Natl. Cancer Inst.*, 36: 1189-1195, 1966.
39. Stutman, O. Carcinogen-induced immune depression: absence in mice resistant to chemical oncogenesis. *Science (Wash. D. C.)*, 166: 620-621, 1969.
40. Stutman, O. Resistance to oncogenesis: antigenic tumors and absence of immunosuppression. *Proc. Am. Assoc. Cancer Res.*, 11: 77, 1970.
41. Stutman, O. Immunological aspects of resistance to the oncogenic effect of 3-methylcholanthrene in mice. *Isr. J. Med. Sci.*, 9: 217-228, 1973.
42. Szakal, A. K., and Hanna, M. G., Jr. The ultrastructure of antigen localization and virus-like particles in mouse spleen germinal centers. *Exp. Mol. Pathol.*, 8: 75-89, 1968.
43. Szakal, A. K., and Hanna, M. G., Jr. Immune suppression and carcinogenesis in hamsters during topical application of 7,12-dimethylbenz[a]anthracene. *Natl. Cancer Inst. Monogr.*, 34: 173-182, 1972.
44. Szakal, A. K., and Hanna, M. G., Jr. Cell-mediated immune response of hamsters to alloantigen and tumor antigens of isologous and autochthonous

- origin during chemical carcinogenesis. *Cancer Res.*, 34: 138-145, 1974.
45. Takasugi, M., Akira, D., and Kinoshita, K. Granulocytes as effectors in cell-mediated cytotoxicity of adherent target cells. *Cancer Res.*, 35: 2169-2176, 1975.
46. Takizawa, S., Watanabe, H., Naito, Y., Terada, Y., Fujii, I., and Hirose, F. Strain differences in susceptibility of rat colon to 1,2-dimethylhydrazine carcinogenesis. *Gann*, 69: 719-722, 1978.
47. Thurnherr, N., Deschner, E., Stonehill, E. M., and Lipkin, M. Induction of adenocarcinomas of the colon in mice by weekly injections of 1,2-dimethylhydrazine. *Cancer Res.*, 33: 940-945, 1973.
48. Turk, J. L., and Willoughby, D. A. An analysis of the multiplicity of the effects of antilymphocyte serum—a comparison with the action of other immunosuppressive agents in the cell-mediated immune response and non-specific inflammation. *Antibiot. Chemother.*, 15: 267-294, 1969.
49. Ward, J. M. Morphogenesis of chemically induced neoplasms of the colon and small intestine in rats. *Lab. Invest.*, 30: 505-513, 1974.
50. Ward, J. M., Yamamoto, R. S., and Brown, C. A. Pathology of intestinal neoplasms and other lesions in rats exposed to azoxymethane. *J. Natl. Cancer Inst.*, 51: 1029-1039, 1973.
51. Weiss, O. Polyp controversy. *Am. J. Proctol.*, 24: 481-485, 1973.

- 
- Fig. 1. Section of the colorectal mucosa from a vehicle-treated mouse. H & E,  $\times 100$ .
- Fig. 2. Section through the hyperplastic colorectal mucosa showing surface atypia of the epithelium after 12 DMH injections. H & E,  $\times 100$ .
- Fig. 3. Section showing the invasive front of an adenocarcinoma 36 weeks after the first DMH injection. The areas indicated by the arrows contain accumulations of individual malignant cells. H & E,  $\times 50$ .
- Fig. 4. Section of hyperplastic colorectal mucosa from a mouse after 8 DMH injections. Compare the height of mucosa with that in Fig. 1. H & E,  $\times 100$ .
- Fig. 5. Section showing the localized development of noninvasive adenocarcinoma in the colon of a mouse after 20 DMH injections. LN, lymphatic nodule. H & E,  $\times 50$ .
- Fig. 6. Metastatic individual malignant cells in the submucosa of the lesion illustrated in Fig. 3. Arrows, area of cell surface with a striate border. Note the granulocytic infiltration. H & E,  $\times 500$ .
- Fig. 7. Section demonstrating the morphology of Peyer's patches in vehicle-treated mice. GC, germinal center. H & E,  $\times 50$ .
- Fig. 8. Section illustrating the spatial relationship of a Peyer's patch to the hyperplastic epithelium of the colon in a mouse after 14 DMH injections. Observe the continuity between the lymphoid tissue and the stroma of the mucosa. Note the "exfoliating" surface epithelium (arrows). GC, germinal center. H & E,  $\times 50$ .
- Fig. 9. Section through an early adenocarcinoma 26 weeks after the first DMH injection showing intense lymphocytic infiltration and necrosis. H & E,  $\times 50$ .
- Fig. 10. Section through part of a mesenteric lymph node from a vehicle-treated mouse. Observe the clear demarcation of the cortex and medulla. GC, germinal center. H & E,  $\times 50$ .
- Fig. 11. Section illustrating the densely cellular paracortical area of a draining mesenteric lymph node from a mouse after 16 DMH injections. Observe the enlarged primary and secondary follicles in the cortex. GC, germinal center. H & E,  $\times 50$ .
- Figs. 12 and 13. Micrographs illustrating the cytology of areas with plasmacytic (Fig. 12) and granulocytic (Fig. 13) infiltration along the invasive fronts of a colorectal adenocarcinoma in a mouse 36 weeks after the first DMH injection. Arrows, invasive edge of the carcinoma. H & E,  $\times 500$ .
- Fig. 14. Section of the spleen representative of white pulp and red pulp morphology in vehicle-treated mice during the first 4 weeks of the study. Arrows, boundary of the white pulp. H & E,  $\times 50$ .
- Fig. 15. Section of the spleen representative of mice after 4 DMH injections. Observe the well-developed primary and secondary lymphoid follicles and the distinct thymus-dependent area of white pulp around the central arteriole (CA). GC, germinal center. H & E,  $\times 50$ .
- Fig. 16. Section representative of splenic white pulp morphology between 30 and 38 weeks after the first DMH injection. Arrows, remnant of the sparsely cellular white pulp. The red pulp is filled with proliferating (see Fig. 19 for mitotic figures) nucleated cells. H & E,  $\times 50$ .
- Fig. 17. Section through a representative area of splenic red pulp from a vehicle-treated mouse (corresponding to Fig. 14) populated mainly with erythrocytes, hemopoietic precursors, and some large lymphocytes. Note megakaryocyte in center. H & E,  $\times 500$ .
- Fig. 18. Section through a representative area of splenic red pulp from a mouse after 4 DMH injections (corresponding to Fig. 15). Observe the increase in the number of large mononuclear cells in comparison to Fig. 17. Many of the large cells are myelocytic precursors. H & E,  $\times 500$ .
- Fig. 19. Section illustrating the presence of large numbers of granulocytic precursors in the red pulp (section corresponds to Fig. 16). This morphology is representative of the red pulp of mice between 12 and 30 weeks after the first DMH injection. Arrows, mitotic figures. H & E,  $\times 500$ .



