Toxicologic Pathology
http://tpx.sagepub.com/

Vaginal Fold Histology Reduces the Variability Introduced by Vaginal Exfoliative Cytology in the Classification of Mouse Estrous Cycle Stages

Arnon Gal, Po-Ching Lin, Anne M. Barger, Amy L. MacNeill and Ko CheMyong

Toxicol Pathol published online 3 April 2014
DOI: 10.1177/0192623314526321

The online version of this article can be found at:
http://tpx.sagepub.com/content/early/2014/04/02/0192623314526321

Published by:
SAGE
http://www.sagepublications.com

On behalf of:
Society of Toxicologic Pathology

Additional services and information for *Toxicologic Pathology* can be found at:

Email Alerts: http://tpx.sagepub.com/cgi/alerts

Subscriptions: http://tpx.sagepub.com/subscriptions

Reprints: http://www.sagepub.com/journalsReprints.nav

Permissions: http://www.sagepub.com/journalsPermissions.nav

>> OnlineFirst Version of Record - Apr 3, 2014

What is This?

Downloaded from tpx.sagepub.com at COLORADO STATE UNIV LIBRARIES on April 9, 2014

Toxicologic Pathology, XX: 1-9, 201X
Copyright © 2014 by The Author(s)
ISSN: 0192-6233 print / 1533-1601 online
DOI: 10.1177/0192623314526321

Vaginal Fold Histology Reduces the Variability Introduced by Vaginal Exfoliative Cytology in the Classification of Mouse Estrous Cycle Stages

Arnon Gal[1], Po-Ching Lin[2], Anne M. Barger[1], Amy L. MacNeill[1], and Ko CheMyong[1,2]

[1]*Department of Pathobiology, College of Veterinary Medicine, University of Illinois at Urbana–Champaign, Urbana, Illinois, USA*
[2]*Department of Comparative Biosciences, College of Veterinary Medicine, University of Illinois at Urbana–Champaign, Urbana, Illinois, USA*

Abstract

Vaginal exfoliative cytology is commonly used in biomedical and toxicological research to classify the stages of the rodent estrous cycle. However, mouse vaginal exfoliative cytology is commonly used as a stand-alone tool and has not been evaluated in reference to vaginal histology and serum sex hormone levels. In this study, the direct and Giemsa-stained methods of vaginal exfoliative cytology were compared in reference to vaginal fold histology and serum sex hormone levels. Both methods predicted the estrous stages similarly with mean discordance rates of 55%, 77%, 46%, and 31%, for diestrus, proestrus, estrus, and metestrus, respectively. From these results, we conclude that vaginal exfoliative cytology may be used as a general guide to determine the desired estrous stage end point and that a definitive confirmation of the estrous stage should be obtained from evaluation of vaginal fold histology. Confirmation of the stage of the estrous cycle by vaginal fold histology will decrease the variability otherwise introduced by misclassification of estrous cycle stages with vaginal exfoliative cytology.

Keywords: mouse; cytology; estrous cycle; histology; vaginal smear; reproduction.

Introduction

Vaginal exfoliative cytology is a well-established tool for the assessment and classification of the rat estrous cycle stages (Martins, Pereira, and Silva 2005; Pessina 2005; Marcondes, Bianchi, and Tanno 2002; Spornitz, Socin, and Dravid 1999; Gupta, Vijayasaradhi, and Reddy 1989; Montes and Luque 1988; Kalra and Kalra 1974; Parakkal 1974; Yoshinaga, Hawkins, and Stocker 1969). However, in comparison to the rat, the mouse estrous cycle is more irregular and only few scientific reports link stage-dependent vaginal exfoliative cytology with serum sex hormone levels or with histology (Nelson et al. 1981; Rubio 1976). The estrous cycle of the mouse is approximately 4 to 5 days long (Caligioni 2009; Goldman, Murr, and Cooper 2007) and during this period, the vaginal mucosa undergoes remarkable structural changes (Rendi et al. 2011; Li and Davis 2007). Based on vaginal exfoliative cytology, the mouse estrous cycle is divided into 4 stages: proestrus, estrus, metestrus, and diestrus. These estrous stages have been previously characterized by direct (nonstained) cytology, stained cytology, histologically, and by scanning electron microscopy (McLean et al. 2012; Rendi et al. 2011; Li and Davis 2007; Marcondes, Bianchi, and Tanno 2002; Spornitz, Socin, and Dravid 1999; Rubio 1976; Parakkal 1974). During proestrus, the vaginal smear contains many nucleated epithelial cells and few leukocytes, whereas during estrus there is marked cornification of the cells and disappearance of leukocytes. In the course of metestrus, the cornified layer is sloughed and mucosal invasion by leukocytes occurs, whereas throughout diestrus the vaginal contents consistently lack cornified cells and leukocytes predominate (McLean et al. 2012; Martins, Pereira, and Silva 2005; Marcondes, Bianchi, and Tanno 2002; Montes and Luque 1988).

The histologic and cytologic changes that the vaginal mucosa undergoes are sex steroid hormone dependent. The main hormone that drives vaginal mucosal change is estradiol (Gupta, Vijayasaradhi, and Reddy 1989). Under the influence of estradiol, the vaginal mucosal epithelium stratifies and becomes cornified. On the other hand, withdrawal of estradiol leads to extensive desquamation of the mucosal epithelium to the vaginal lumen (Gupta, Vijayasaradhi, and Reddy 1989). The roles of progesterone and testosterone on the vaginal mucosal epithelium are less clear, but data suggest that they may have a mild antagonistic effect of estradiol effects on the vaginal mucosa (Pessina 2005).

Mouse vaginal exfoliative cytology is used as an indicator for a stage-specific research end point in which messenger RNA or proteins are expressed in certain populations of cells,

The author(s) declared no potential conflicts of interest with respect to the research, authorship, and/or publication of this article.

This study was supported by NIH P01 ES022848 and EPA RD-83459301.

Address correspondence to: CheMyong Ko, Department of Comparative Biosciences, College of Veterinary Medicine, University of Illinois at Urbana-Champaign, 2001 Lincoln Ave., Urbana, IL 61802; e-mail: jayko@illinois.edu.

Abbreviations: ANOVA, analysis of variance; DRG, diagnosis-related group; EIA kits, enzyme immunoassay kits; FSH, follicle-stimulating hormone; LH, luteinizing hormone; PBS, phosphate buffer saline; UIUC, University of Illinois at Urbana–Champaign.

Downloaded from tpx.sagepub.com at COLORADO STATE UNIV LIBRARIES on April 9, 2014

in specific tissues, or for evaluation of serum or hematological variables (Spencer et al. 2008; Cohen et al. 2002). The reliance on vaginal exfoliative cytology as an indicator of estrous stage is then absolute, and no other diagnostic measures are taken to ensure that the vaginal cytology results in correct classification of the estrous cycle (Spencer et al. 2008; Cohen et al. 2002). Therefore, our goal was to test the hypothesis that vaginal cytology may not adequately predict the stages of the mouse estrous cycle. More specifically, because different methods of vaginal exfoliative cytology have been used to classify mouse estrous stages (McLean et al. 2012; Goldman, Murr, and Cooper 2007), we compared the direct and Giemsa-stained cytological methods for their accuracy.

Consequently, the purpose of this research was to test which of the 2 methods of vaginal exfoliative cytology predicts more accurately the mouse estrous cycle stages. Specifically, our hypothesis was that Giemsa-stained smears will have a better predictive accuracy than direct smears because of increased recognition of cellular detail. A secondary goal of this work was to characterize the hormonal profile of the female C57BL/6 mouse estrous cycle because there are few reports of these data in the literature (Nelson et al., 1981; Kovacic and Parlow 1972).

MATERIALS AND METHODS

Animals

Three-month-old wild-type C57BL/6 female mice were used for all experiments. Mice were housed at the University of Illinois at Urbana–Champaign (UIUC) animal care facility under 12-hr light/dark cycles. Animals were fed commercial rodent diet and had free access to water. Animal handling and procedures were approved by the UIUC Institutional Animal Care and Use Committee.

Vaginal Exfoliative Cytology

Vaginal smears were performed as previously described (Caligioni 2009) with a slight modification. Briefly, mice were smeared daily for 16 days, at 0900 hrs by application of 100 µl of phosphate buffer saline (PBS) into the distal aspect of the vagina followed by aspiration of the flushed fluids. Samples were immediately placed into a 96-well plate and were processed within 1 hr. A drop of PBS was added to each well of the 96-well plate to separate and stir the cells and then smears were immediately read by a single, well-experienced technician (P.L.), at 4× magnification using an inverted microscope (Olympus CKX41, Center Valley, PA). Immediately after reading the direct smears, 10 µl from each well were taken and applied on a clean plain glass slide (Thermo Scientific, Waltham, MA) and allowed to dry at room temperature. Dried smears were stained in one batch with Giemsa using a commercial slide stainer (Hema-tek 1000; Miles Laboratories Inc. (Bayer), Elkhart, IN) at the Clinical Pathology Section of the UIUC Veterinary Diagnostic Laboratory. Samples on the edge of slides that were not stained by the commercial slide stainer were re-stained manually by Diff-quick (Fisher Diagnostics, Waltham, MA), according to the manufacturer recommendations. All samples were read by a single board-certified pathologist (A.G.).

Evaluation of Precision of Vaginal Exfoliative Cytology and Vaginal Fold Histology

Twenty representative direct smears, Giemsa-stained smears, and vaginal fold histological sections were randomized 4 times by a third party. A.G. blindly read Giemsa-stained smears and vaginal fold histological sections, and P.L. blindly read the direct smears, and the results were recorded. Intraobserver coefficients of variability for each of the cytological methods were calculated from 80 vaginal exfoliative cytology smears, and the intraobserver coefficient of variability for histology was calculated from 80 vaginal fold histological sections.

Vaginal Fold Histology

Histologic evaluation of vaginal tissues was used as the "gold standard" for determining estrous stage and was performed as previously described (Rendi et al. 2011; Li and Davis 2007). After 14 days of cytological evaluation of the estrous cycle, mice were euthanized immediately after cytological sample collection at predetermined assigned estrous stages. Euthanasia was performed by CO_2 asphyxia and cervical dislocation. Vaginal tissue was surgically excised and fixed in 4% paraformaldehyde for a minimum period of 24 hr. Once fixed, the tissue was trimmed sagittally near the cervix so that the vaginal folds lateral to the cervix would be included in the tissue block. The tissues were then manually processed in the following manner: the tissues were incubated for 30 min each in 70%, 80%, 90%, 95%, and twice in 100% ethanol, then 50%/50% and 70%/30% xylene/ethanol, and twice in 100% xylene. Tissues were then incubated for 90 min in 50%/50% xylene/paraffin at 60°C and for additional 90 min in pure paraffin at 60°C and were then embedded. Paraformaldehyde-fixed, paraffin-embedded tissue blocks were sectioned 4 µm thick, mounted on glass slides and manually stained with hematoxylin and eosin (Richard Allen) in the following manner: deparaffinization was achieved by drying the slides in an oven at 60°C for 20 min followed by incubation for 2 min 3 times in xylene, twice in 100% alcohol, once in 90% and 70% alcohol, and once in running tap water. Slides were then incubated for 2 min in hematoxylin and washed under running tap water for 2 min. Slides were briefly dipped 4 times in acid alcohol (0.5% HCl in 70% EtOH) to remove excess hematoxylin and then washed under running water for 1 min. Next slides were briefly dipped in ammonia water (0.1% ammonium hydroxide in H_2O) and then washed under running water for 1 min. Slides were then incubated twice in 95% ethanol for 1 min, once in eosin for 30 sec, twice in 95% ethanol for 1 min, twice in 100% ethanol for 2 min, and 3 times in xylene for 2 min, and the coverslip was placed on the slide.

Downloaded from tpx.sagepub.com at COLORADO STATE UNIV LIBRARIES on April 9, 2014

Blood Collection

Blood was collected at 0930 hr after collection and analysis of vaginal exfoliative cytological samples. Immediately following euthanasia, blood was collected from the abdominal vena cava into serum separator tubes (BD 365959 Plastic Capillary Blood Collection Microtainer Tube, Burlington, NC) and allowed to clot for 15 min. Then, serum separated tubes containing clotted blood were centrifuged at 4°C for 15 min at maximum speed (Eppendorf Centrifuge 5804, Hauppauge, NY). Separated sera were transferred to cryotubes (Thermo Scientific), immediately frozen in liquid nitrogen, and stored at −80°C, pending further analysis.

Serum Hormone Measurement

Measurements of serum estradiol and testosterone were performed in triplicates using commercial enzyme immunoassay (EIA) kits (Craig et al. 2010; DRG, Marburg, Germany), according to the manufacturer recommendations with a slight modification. For estradiol, the 25 pg/ml company standard was diluted with the company 0 pg/ml standard to final concentrations of 12.5 pg/ml and 6.25 pg/ml. For the testosterone, the company 0.2 ng/ml standard was diluted with the company 0 ng/ml standard to a final concentration of 0.1 ng/ml. The assay detection limit for estradiol was 0.156 pg and for testosterone 0.0025 ng. No samples were below the detection limit of the estradiol assay and 4 samples were below the detection limit of the testosterone assay (1 in proestrus, 1 in estrus, and 2 in metestrus). The results for testosterone that were below the detection limit of the assay were recorded as the lowest detection limit of the assay (0.05 ng/ml). For both estradiol and testosterone kits, the intraassay coefficient of variation was less than 10%. Serum luteinizing hormone (LH) and follicle-stimulating hormone (FSH) levels were measured as previously reported (Brothers et al. 2010). The assay detection limit for LH was 0.0012 ng and for FSH 0.0008 ng. No samples were below the detection limit of the assay.

Statistical Analysis

Data analyses were performed using statistical software (SPSS, New York, NY). All normally distributed continuous data were analyzed with a parametric test (analysis of variance [ANOVA]) and a post hoc test (least significant difference [LSD] test). All nonnormally distributed continuous data were analyzed with a nonparametric test (Kruskal–Wallis). For all analyses, the α value was set at .05.

Results

Histological and Cytological Characteristics of the Stages of the Mouse Estrous Cycle

In Figures 1 and 2, the histological and cytological characteristics of the mouse estrous cycle stages are presented. The proestrus stage is characterized histologically by a 10- to 13-cell thick mucosa of which the stratum mucification layer stain lightly with eosin, whereas the stratum corneum layer becomes keratinized resulting in a "pink line." Mitoses are frequent, and few leukocytes are present. During proestrus, Giemsa-stained cytology smears have a predominance of nucleated epithelial cells approximately 25 to 30 μm in diameter that have lightly basophilic fibrillar cytoplasm and a single, relatively small, central round nucleus. In the direct smear, proestrus is characterized by a predominance of round to polygonal cells, approximately 20 to 25 μm in diameter, that occasionally have a discernible small round nucleus. The estrus stage is characterized histologically by an approximately 12-cell thick mucosa of which the superficial nucleated layer (stratum mucification) is lost and the cornified layer (stratum corneum) has become superficial. Rare mitoses and leukocytes are absent. During estrus, Giemsa-stained cytology smears show a predominance of polygonal anucleate epithelial cells approximately 35 to 50 μm in diameter, which have a denser basophilic fibrillar cytoplasm. In the direct smear, estrus is characterized by a predominance of anucleate polygonal cells, approximately 25 to 40 μm in diameter. The metestrus stage is characterized histologically by delamination of the cornified mucosal layer (stratum corneum) and by infiltration of leukocytes through the mucosa. During metestrus, Giemsa-stained cytology smears show a combination of even numbers of leukocytes and polygonal anucleate epithelial cells, approximately 35 to 50 μm in diameter with a basophilic fibrillar cytoplasm, and fewer nucleated epithelial cells, approximately 25 to 30 μm in diameter, which have lightly basophilic fibrillar cytoplasm and a single, relatively small, central round nucleus. In the direct smear, metestrus is characterized by a combination of even numbers of leukocytes and anucleate polygonal cells, approximately 25 to 40 μm in diameter, and fewer round to polygonal cells, approximately 20 to 25 μm in diameter, which occasionally have a discernible small round nucleus. The diestrus stage is characterized histologically by a 4- to 7-cell thick mucosa that contains mucified surface epithelial cells (stratum mucification), and luminal mucus, leukocytes, and desquamated cells. During diestrus, Giemsa-stained cytology smears show a predominance of round cells with segmented nucleus (neutrophils) that is often condensed (pyknotic). In the direct smear, diestrus is characterized by predominance of cells with a size of approximately 10 μm in diameter.

Evaluation of Precision of Vaginal Exfoliative Cytology and Vaginal Fold Histology Readings

The ability of the authors to consistently reproduce the same cytological and histological results (precision) was determined. The authors read 20 direct (P.L.) and Giemsa-stained (A.G.) vaginal exfoliative cytological smears, and 20 vaginal fold histological sections (A.G.), 4 times following randomization and blinding. The calculated intraobserver coefficients of variation for direct and Giemsa-stained cytology and vaginal fold histology were 9.5%, 5.6%, and 0%, respectively.

Downloaded from tpx.sagepub.com at COLORADO STATE UNIV LIBRARIES on April 9, 2014

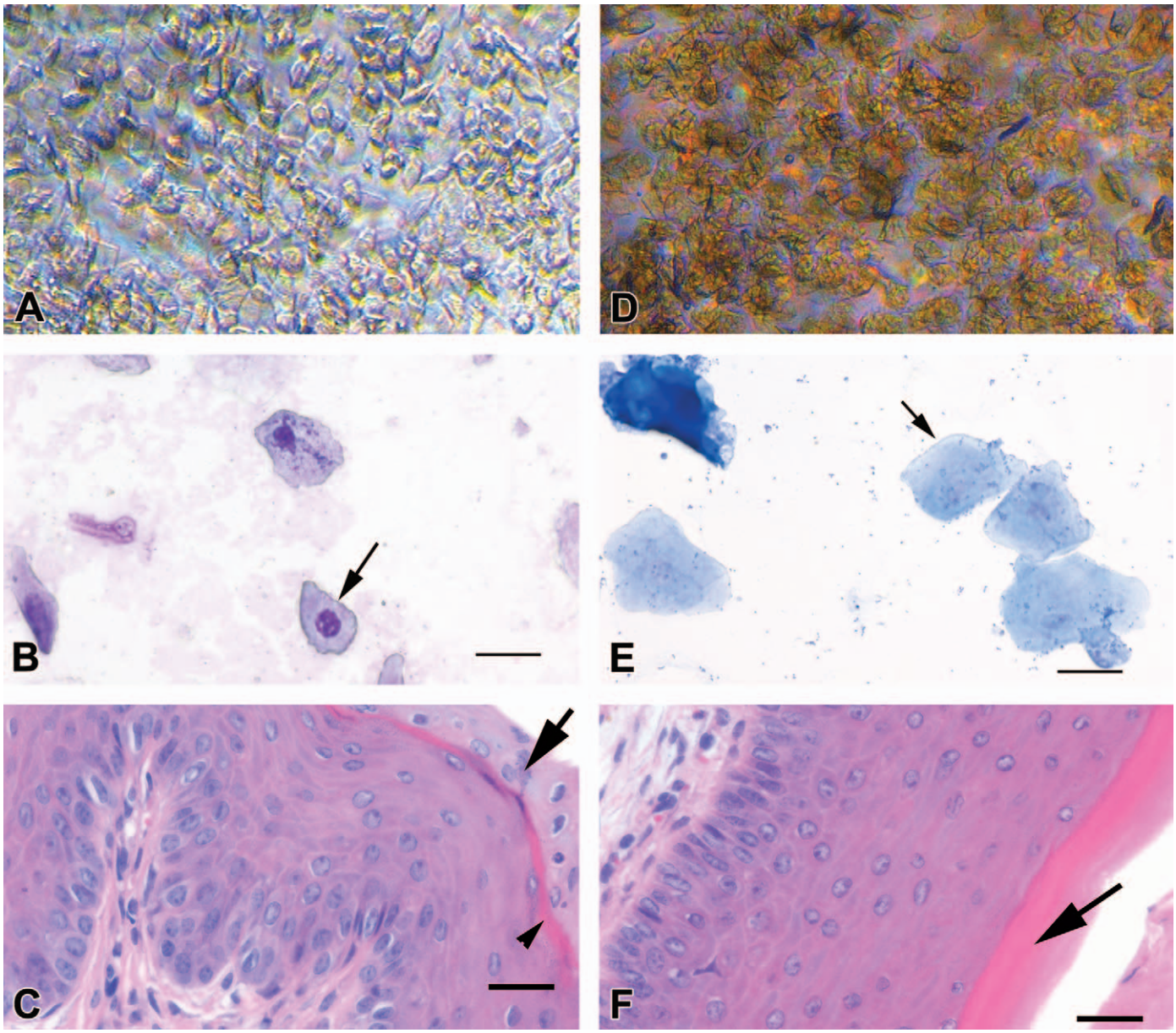

FIGURE 1.—Direct and Giemsa-stained vaginal exfoliative cytology, and vaginal fold histology of proestrus and estrus stages of the estrous cycle from 3-month-old naturally cycling C57BL/6 female mice. Proestrus stage (A–C): the direct smear (A) has a predominance of round to polygonal cells (20–25 µm in diameter) that occasionally have a discernible small round nucleus. The Giemsa-stained cytology smear (B) has a predominance of nucleated epithelial cells (25–30 µm in diameter) that have lightly basophilic fibrillar cytoplasm and a single, relatively small, central round nucleus (black arrow). Histologically (C) the mucosa is 10- to 13-cell thick, the stratum mucification stain lightly with eosin (black arrow), whereas the stratum corneum layer becomes keratinized resulting in a "pink line" (black arrowhead). Estrus stage (D–F): the direct smear (D) has a predominance of anucleate polygonal cells (25–40 µm in diameter). The Giemsa-stained cytology smear (E) has a predominance of polygonal anucleate epithelial cells (35–50 µm in diameter; black arrow) that have a denser basophilic fibrillar cytoplasm. Histologically (F) the mucosa is 12-cell thick, the superficial nucleated layer is lost (stratum mucification), and the cornified layer (stratum corneum) has become superficial (black arrow). Leukocytes are absent. Bar = 25 µm.

Comparison of Direct and Giemsa-stained Cytology to Vaginal Fold Histology

First, we sought to determine the accuracy of the cytological analysis of vaginal smears in comparison to histology of the vaginal folds (Rendi et al. 2011; Li and Davis 2007; Walmer et al. 1992; Table 1). To achieve that, the respective direct and Giemsa-stained vaginal exfoliative cytology were compared to the vaginal fold histology that was obtained from each animal at the day of euthanasia ($n = 50$). There were 60% (6/10) and 50% (5/10) agreement between direct and Giemsa-stained cytology and histology in the classification of the diestrus stage. In addition, there were 73% (8/11) and 82% (9/11)

Downloaded from tpx.sagepub.com at COLORADO STATE UNIV LIBRARIES on April 9, 2014

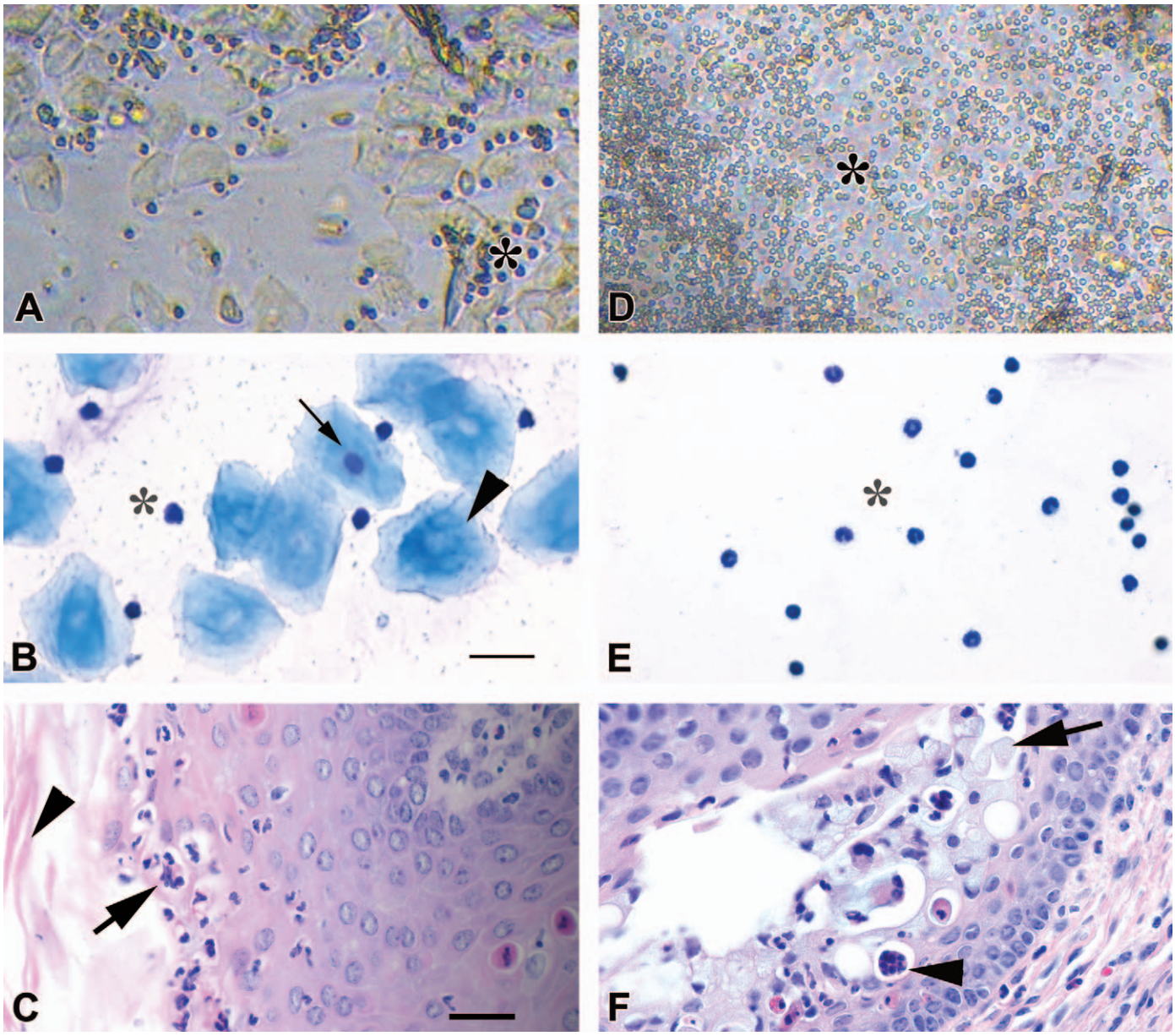

FIGURE 2.—Direct and Giemsa-stained vaginal exfoliative cytology and vaginal fold histology of metestrus and diestrus stages of the estrous cycle from 3-month-old naturally cycling C57BL/6 female mice. Metestrus stage (A–C): the direct smear (A) has a combination of approximately even numbers of leukocytes, anucleate polygonal cells (25–40 μm in diameter) and fewer round to polygonal cells (20–25 μm in diameter) that occasionally have a discernible small round nucleus (black arrowhead). Giemsa-stained cytology smear (B) has a combination of approximately even numbers of leukocytes (asterisk) and anucleate polygonal epithelial cells (35–50 μm in diameter; black arrowhead) with a basophilic fibrillar cytoplasm, and fewer nucleated epithelial cells (25–30 μm in diameter; black arrow) that have lightly basophilic fibrillar cytoplasm and a single, relatively small, central round nucleus. Histologically (C) there is delamination of the cornified mucosal layer (stratum corneum; black arrowhead) and infiltration of leukocytes through the mucosa (black arrow). Diestrus stage (D–F): the direct smear (D) has a predominance of leukocytes (10 μm in diameter; asterisk). The Giemsa-stained cytology smear (E) has a predominance of round cells with segmented nucleus (neutrophils) that is often condensed (pyknotic; asterisk). Histologically (F) the mucosa is 4- to 7-cell thick and contains mucified surface epithelial cells (stratum mucification; black arrow), and luminal mucus, leukocytes (black arrowhead), and desquamated cells.
Note: FSH = follicle-stimulating hormone. LH = luteinizing hormone.

agreement between direct and Giemsa-stained cytology and histology in the classification of proestrus, and 46% (6/13) agreement between direct and Giemsa-stained cytology and histology in the classification of estrus. Finally, there were 25% (4/16) and 38% (6/16) agreement between direct and Giemsa-stained cytology and histology in the classification of metestrus. The pattern of misclassification of the correct estrous stage by cytology was as follows: Diestrus was

Downloaded from tpx.sagepub.com at COLORADO STATE UNIV LIBRARIES on April 9, 2014

TABLE 1.—Direct and Giemsa-stained vaginal exfoliative cytology classification of estrous cycle stages relative to vaginal fold histology in 3-month-old, naturally cycling female C57BL/6 mice.

Target stages	Diestrus	Proestrus	Estrus	Metestrus
n	10	11	13	16
Direct smear—accuracy of classification	60% (6/10)	73% (8/11)	46% (6/13)	25% (4/16)
Target stage misclassified as	Proestrus (3/10) Metestrus (1/10)	Metestrus (1/11) Diestrus (2/11)	Metestrus (3/13) Diestrus (2/13) Proestrus (2/13)	Diestrus (12/16)
Giemsa-stained smear—accuracy of classification	50% (5/10)	82% (9/11)	46% (6/13)	38% (6/16)
Target stage misclassified as	Proestrus (3/10) Estrus (1/10) Metestrus (1/10)	Estrus (1/11) Metestrus (1/11)	Metestrus (6/13) Proestrus (1/13)	Diestrus (9/16) Proestrus (1/16)

TABLE 2.—Rate of disagreement between direct and Giemsa-stained exfoliative cytology in classification of estrous cycle stages in 3-month-old female C57BL/6 mice.

Disagreements between	Rate ($n = 49$)
Diestrus–Metestrus	36.7% (18/49)
Proestrus–Estrus	32.7% (16/49)
Diestrus–Proestrus	14.3% (7/49)
Estrus–Metestrus	8.2% (4/49)
Proestrus–Metestrus	6.1% (3/49)
Diestrus–Estrus	2.0% (1/49)
Total disagreement rate	26% ($n = 186$)

misclassified as proestrus and metestrus, and proestrus was misclassified as metestrus (by both cytological methods), as diestrus (by direct cytology), or as estrus (by Giemsa-stained cytology). Estrus was misclassified as either metestrus or proestrus (by both cytological methods) or as diestrus (by direct smear). Finally, metestrus was misclassified as diestrus (by both cytological methods) or proestrus (by Giemsa-stained smear).

Multiple Comparisons between Direct and Giemsa-stained Vaginal Exfoliative Cytology

We then determined how different the 2 methods of cytological evaluation of vaginal smears are from each other (Table 2). To attain that goal, daily direct and Giemsa-stained vaginal exfoliative cytology ($n = 12$) collected over a period of 16 days were compared to one another. In total, 186 out of 192 smears were available for analysis. We found that out of 186 smears, the classification of estrous stage was different between direct and Giemsa-stained smears 49 times (26%). The highest disagreements were between classification of diestrus and metestrus (18/49; 36.7%), and proestrus and estrus (16/49; 32.7%). The 2 lowest disagreements were between classification of diestrus and estrus (1/49; 2.0%) and proestrus and metestrus (3/49; 6.1%). Moderate levels of disagreements were present between classification of diestrus and proestrus (7/49; 14.3%) and estrus and metestrus (4/49; 8.2%).

Serum Hormone Levels of Estradiol, Testosterone, LH, and FSH

Finally, we sought to correlate the estrous stages as classified by vaginal histology with the serum hormone levels of estradiol, testosterone, LH, and FSH (Figure 3). Individual sex hormones levels, other than testosterone, have been previously correlated with the mouse estrous cycle (Achiraman et al. 2011; Nelson et al. 1981). However, to the best of our knowledge, a complete sex hormone profile that is correlated to the C57BL/6 mouse estrous cycle has not been published. To accomplish that, serum was obtained at the time of euthanasia. The results of serum hormone analyses were crossed against the corresponding estrous stage as determined by vaginal fold histology and then hormone levels were compared between the different estrous stages. Serum estradiol progressively increased from metestrus through proestrus (ANOVA p value $< .001$). Proestrus estradiol serum concentration was higher than all other estrus stages (p value $< .001$). During estrus, estradiol serum concentration was significantly lower than proestrus (p value $< .001$) and higher than metestrus (p value $= .005$). During metestrus, estradiol serum concentration was significantly lower than proestrus (p value $< .001$), estrus (p value $= .005$), and diestrus (p value $= .034$). During diestrus, estradiol serum concentration was lower than proestrus (p value $< .001$) and higher than metestrus (p value $= .034$). Serum testosterone was low during metestrus and estrus, peaked during diestrus, and then started to decrease during proestrus. However, it was not statistically different between the estrous stages (ANOVA p value $= .253$). Serum LH and FSH concentrations were not statistically different across the entire estrous cycle (Kruskal–Wallis test p values $= .333$ and $.643$, respectively). LH concentration tended to be higher during proestrus and metestrus and FSH concentration tended to be higher during proestrus.

DISCUSSION

The aim of this study was to determine if Giemsa-stained vaginal exfoliative cytology is superior to direct vaginal exfoliative cytology in predicting the correct estrous stage. Therefore, the estrous stage predicted by each cytological method was compared with estrous stage classified by vaginal fold histology. This work is novel because in previous publications

Downloaded from tpx.sagepub.com at COLORADO STATE UNIV LIBRARIES on April 9, 2014

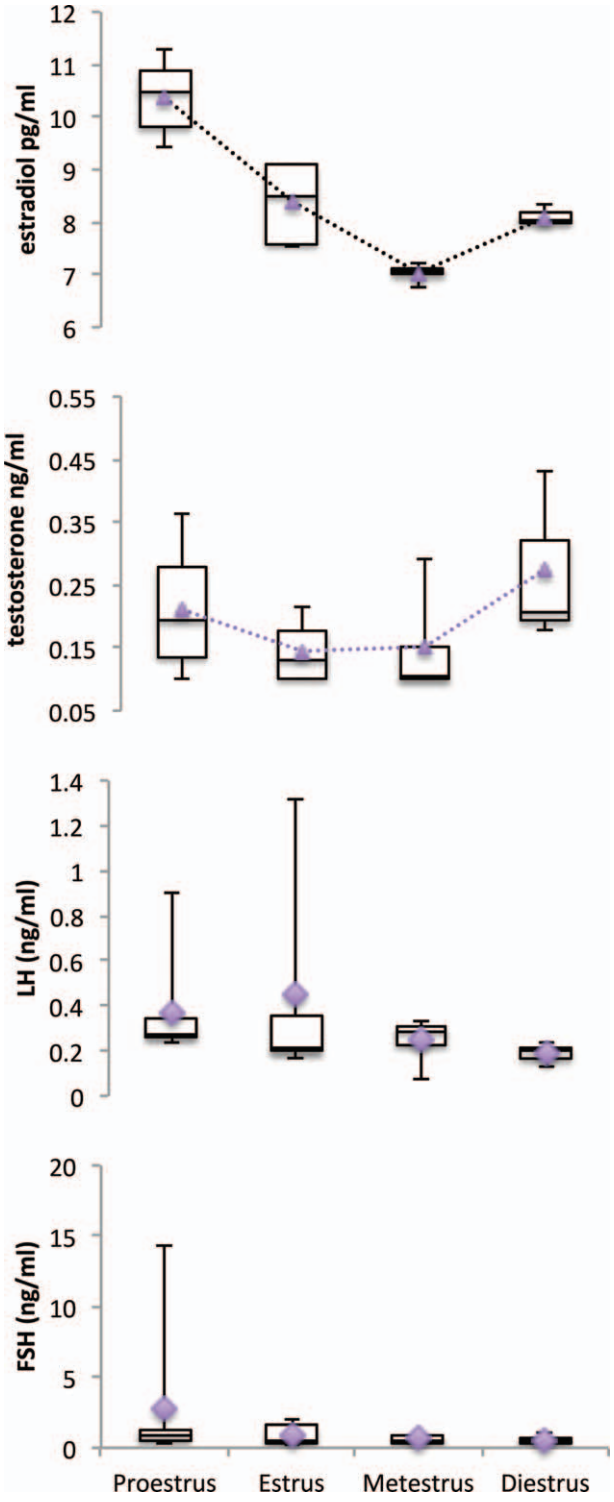

FIGURE 3.—Box plot graphic data of serum estradiol, testosterone, LH, and FSH concentrations during proestrus ($n = 7$), estrus ($n = 5$), metestrus ($n = 4$), and diestrus ($n = 3$) from 3-month-old C57BL/6 naturally cycling female mice. Serum estradiol progressively increased from metestrus through proestrus, being lowest at metestrus and highest at proestrus ($p < .001$). Serum testosterone was not statistically different between the estrus stages ($p = .253$), was low during metestrus and estrus, and peaked during diestrus, starting again to decrease during proestrus. Serum LH and FSH levels were not statistically different across the entire estrous cycle ($p = .333$ and $p = .643$, respectively). The bottom and top of the boxes represent the first and third quartiles, respectively, and the band inside the box represents the median. Whiskers represent the minimum and maximum of the data. Diamonds or triangles represent the mean. FSH = follicle-stimulating hormone. LH = luteinizing hormone.

(Brothers et al. 2010; Caligioni 2009; Spencer et al. 2008; Nelson et al. 1981; Nelson et al. 1982), either direct smears or stained smears, but not both, have been utilized for the assessment of mouse estrous stages. Therefore, our comparison between direct and Giemsa-stained vaginal exfoliative cytology cannot be directly contrasted with any previous work. Our results indicate that both methods have similar inconsistencies in predicting the correct estrous stage (Table 1). Therefore, when there is a need to follow the estrous cycle in mice, either method may be used according to the preference of the user, as long as the investigator is comfortable and acquainted with performing the technique and interpreting the results.

However, an important observation from this study is that cytological evaluation of vaginal smears in mice may only roughly approximate the estrous stage. If a research end point is estrous stage dependent, for example, temporal expression of a protein (Spencer et al. 2008; Cohen et al. 2002), then at the time of animal euthanasia it is essential that vaginal tissue samples are collected and histologically classified for the correct estrous stage. Therefore, we suggest utilization of vaginal fold histology as the final method that would classify the appropriate estrous stage. The advantages of vaginal fold histology are that each estrous cycle stage has its own unique characteristics (Rendi et al. 2011; Li and Davis 2007; Walmer et al. 1992; Rubio 1976) that are different from the other stages; therefore, it is easy to determine the estrous stage without confusion, and multiple tissue sections can be easily mounted on a single slide thus increasing the accuracy of classification. In addition, in a preceding pilot study, we did not find uterine histology informative in classifying the estrous stage in the mouse because of high variability, and therefore in this article only vaginal fold histology was utilized.

When evaluating the mismatches in classification of the estrous stages between the 2 cytological methods (Table 2), it is evident that the highest prevalence of mismatches is between 2 consecutive estrous stages (e.g., estrus and metestrus) and the lowest prevalence of mismatches is between 2 stages that do not occur one after the other (e.g., proestrus and metestrus or estrus and diestrus). Because the cytological classification of the estrous stages relies on differences in the proportions of anucleate and nucleate vaginal epithelium and neutrophils (Goldman, Murr, and Cooper 2007), and because the transition between 2 consecutive estrous stages is continuous and not abrupt (Nelson et al. 1982), we expected to find higher mismatches between successive estrous cycle stages. In view of this inherent methodological bias, when planning a study design that involves comparisons of an outcome variable between stages, it would be better to choose 2 opposing stages as study end points (e.g., estrus and diestrus) than 2 consecutive

Downloaded from tpx.sagepub.com at COLORADO STATE UNIV LIBRARIES on April 9, 2014

stages. By doing so, the variability in the outcome variable will decrease because of reduced probability of misclassification of the estrous cycle stage.

Our secondary goal was to correlate the levels of estradiol, testosterone, and serum gonadotropins with the estrous cycle stages through vaginal fold histology. We found that a single morning blood sample was sufficient to demonstrate changes in serum estradiol and testosterone levels across the estrous cycle. The pattern of serum estradiol levels was similar to a previous publication (Nelson et al. 1981), although the absolute values differed between the studies, most likely because of different assay methodology. Despite a significant difference in estradiol levels at different estrous stages, daily sampling for serum estradiol levels by phlebotomy cannot be considered as a good tool for monitoring the estrous stage in mice, because it may lead to unwarranted morbidity and mortality (Forbes et al. 2010). To the best of our knowledge, this is the first study to report serum testosterone levels across the estrous cycle in adult C57BL/6 mice. Albeit the change in serum testosterone levels was similar in pattern to that of serum estradiol, it did not reach a statistically significant difference, possibly because of a small sample size. A plausible explanation for the similarity in the patterns of serum estradiol and testosterone levels is that testosterone, an aromatizable source of estradiol in the ovary, is derived from growing follicles (Tsonis, Carson, and Findlay 1984). In addition, testosterone may play a role in hypothalamic regulation of the estrous cycle, similar to the well-established role that estradiol has (Berga and Naftolin 2012; Caraty, Franceschini, and Hoffman 2010; Christian and Moenter 2010; Caraty and Franceschini 2008). For example, in the hypothalamus, testosterone action may be mediated by androgen receptors that are expressed by kisspeptin neurons (Clarkson et al. 2012), the key regulators of GnRH release (Clarkson et al. 2010; Colledge and d'Anglemont de Tassigny 2010; Caraty and Franceschini 2008). Hence, the potential role of testosterone in regulation of the estrous cycle is yet to be determined. In contrast to serum estradiol and testosterone, there was no change in serum gonadotropins across the estrous cycle. This is consistent with previous studies that indicated that the timing of sampling has a pronounced impact on serum gonadotropin hormone levels (Kovacic and Parlow 1972). Moreover, the release of serum gonadotropins from the pituitary is pulsatile (Steyn et al. 2013; Lumpkin, DePaolo, and Negro-Vilar 1984), and therefore repeated sampling over time, rather than once daily sampling, should be more appropriate for monitoring serum gonadotropins (Steyn et al. 2013).

A limitation in our study involved the assessment of serum estradiol and testosterone in mouse sera by diagnosis-related group EIA kits (DRG EIA kits). These kits have not been previously validated for use with mouse serum. Nevertheless, in a preliminary analysis, we found that after extending the detection limit of assays to 0.156 pg and 0.0025 ng for estradiol and testosterone, respectively, the recovery rates were within an acceptable range ($\pm 15\%$). Therefore, we think that the observed trends in serum estradiol and testosterone are representative of the actual changes during the mouse estrous cycle.

In conclusion, when a research end point is dependent upon a correct classification of the estrous cycle stage, we suggest monitoring the estrous cycle by vaginal exfoliative cytology. Then, when the desired end point is met, vaginal tissue should be collected for routine histology. The evaluation of vaginal fold histology will enable accurate classification of the desired estrous stage. Otherwise, using cytology alone as a basis for attributing treatment-related effects may increase the variability in the results.

REFERENCES

Achiraman, S., Archunan, G., Sankarganesh, D., Rajagopal, T., Rengarajan, R. L., Kokilavani, P., Kamalakkannan, S., and Kannan, S. (2011). Biochemical analysis of female mice urine with reference to endocrine function: A key tool for estrus detection. *Zoolog Sci* **28**, 600–5.

Berga, S., and Naftolin, F. (2012). Neuroendocrine control of ovulation. *Gynecol Endocrinol* **28**, 9–13.

Brothers, K. J., Wu, S., DiVall, S. A., Messmer, M. R., Kahn, C. R., Miller, R. S., Radovick, S., Wondisford, F. E., and Wolfe, A. (2010). Rescue of obesity-induced infertility in female mice due to a pituitary-specific knockout of the insulin receptor. *Cell Metab* **12**, 295–305.

Caligioni, C. S. (2009). Assessing reproductive status/stages in mice. *Curr Protoc Neurosci* Appendix 4, Appendix 4I, A.4I.1–A.4I.8.

Caraty, A., and Franceschini, I. (2008). Basic aspects of the control of GnRH and LH secretions by kisspeptin: Potential applications for better control of fertility in females. *Reprod Domest Anim* **43**, 172–8.

Caraty, A., Franceschini, I., and Hoffman, G. E. (2010). Kisspeptin and the preovulatory gonadotrophin-releasing hormone/luteinising hormone surge in the ewe: Basic aspects and potential applications in the control of ovulation. *J Neuroendocrinol* **22**, 710–5.

Christian, C. A., and Moenter, S. M. (2010). The neurobiology of preovulatory and estradiol-induced gonadotropin-releasing hormone surges. *Endocr Rev* **31**, 544–77.

Clarkson, J., Han, S. K., Liu, X., Lee, K., and Herbison, A. E. (2010). Neurobiological mechanisms underlying kisspeptin activation of gonadotropin-releasing hormone (GnRH) neurons at puberty. *Mol Cell Endocrinol* **324**, 45–50.

Clarkson, J., Shamas, S., Mallinson, S., and Herbison, A. E. (2012). Gonadal steroid induction of kisspeptin peptide expression in the rostral periventricular area of the third ventricle during postnatal development in the male mouse. *J Neuroendocrinol* **24**, 907–15.

Cohen, P. E., Zhu, L., Nishimura, K., and Pollard, J. W. (2002). Colony-stimulating factor 1 regulation of neuroendocrine pathways that control gonadal function in mice. *Endocrinol* **143**, 1413–22.

Colledge, W. H., and d'Anglemont de Tassigny, X. (2010). The role of kisspeptin signalling in the regulation of the GnRH-gonadotrophin ovarian axis in mice. *Ann Endocrinol (Paris)* **71**, 198–200.

Craig, Z. R., Leslie, T. C., Hatfield, K. P., Gupta, R. K., and Flaws, J. A. (2010). Mono-hydroxy methoxychlor alters levels of key sex steroids and steroidogenic enzymes in cultured mouse antral follicles. *Toxicol Appl Pharmacol* **249**, 107–13.

Forbes, N., Brayton, C., Grindle, S., Shepherd, S., Tyler, B., and Guarnieri, M. (2010). Morbidity and mortality rates associated with serial bleeding from the superficial temporal vein in mice. *Lab Anim (NY)* **39**, 236–40.

Goldman, J. M., Murr, A. S., and Cooper, R. L. (2007). The rodent estrous cycle: Characterization of vaginal cytology and its utility in toxicological studies. *Birth Defects Res B Dev Reprod Toxicol* **80**, 84–97.

Gupta, P. D., Vijayasaradhi, S., and Reddy, A. G. (1989). Keratinization of rat vaginal epithelium. III. Effect of estradiol on keratinization. *Biol Cell* **65**, 281–9.

Kalra, S. P., and Kalra, P. S. (1974). Temporal interrelationships among circulating levels of estradiol, progesterone and LH during the rat estrous cycle: Effects of exogenous progesterone. *Endocrinol* **95**, 1711–18.

Downloaded from tpx.sagepub.com at COLORADO STATE UNIV LIBRARIES on April 9, 2014

Kovacic, N., and Parlow, A. F. (1972). Alterations in serum FSH-LH ratios in relation to the estrous cycle, pseudopregnancy, and gonadectomy in the mouse. *Endocrinol* **91**, 910–15.

Li, S., and Davis, B. (2007). Evaluating rodent vaginal and uterine histology in toxicity studies. *Birth Defects Res B Dev Reprod Toxicol* **80**, 246–52.

Lumpkin, M. D., DePaolo, L. V., and Negro-Vilar, A. (1984). Pulsatile release of follicle-stimulating hormone in ovariectomized rats is inhibited by porcine follicular fluid (inhibin). *Endocrinol* **114**, 201–6.

Marcondes, F. K., Bianchi, F. J., and Tanno, A. P. (2002). Determination of the estrous cycle phases of rats: Some helpful considerations. *Braz J Biol* **62**, 609–14.

Martins, R. R., Pereira, N. M., and Silva, T. M. (2005). Liquid-base cytology: A new method for oestral cycle study in Wistar's rats. *Acta Cir Bras* **20**, 78–81.

McLean, A. C., Valenzuela, N., Fai, S., and Bennett, S. A. (2012). Performing vaginal lavage, crystal violet staining, and vaginal cytological evaluation for mouse estrous cycle staging identification. *J Vis Exp* **67**, e4389.

Montes, G. S., and Luque, E. H. (1988). Effects of ovarian steroids on vaginal smears in the rat. *Acta Anat (Basel)* **133**, 192–9.

Nelson, J. F., Felicio, L. S., Osterburg, H. H., and Finch, C. E. (1981). Altered profiles of estradiol and progesterone associated with prolonged estrous cycles and persistent vaginal cornification in aging C57BL/6J mice. *Biol Reprod* **24**, 784–94.

Nelson, J. F., Felicio, L. S., Randall, P. K., Sims, C., and Finch, C. E. (1982). A longitudinal study of estrous cyclicity in aging C57BL/6J mice: I. Cycle frequency, length and vaginal cytology. *Biol Reprod* **27**, 327–39.

Parakkal, P. F. (1974). Cyclical changes in the vaginal epithelim of the rat seen by scanning electron microscopy. *Anat Rec* **178**, 529–37.

Pessina, M. A. (2005). Differential effects of estradiol, progesterone, and testosterone on vaginal structural integrity. *Endocrinol* **147**, 61–69.

Rendi, M. H., Muehlenbachs, A., Garcia, R. L., and Boyd, K. L. (2011). Female reproductive system. In *Comparative Anatomy and Histology: A Mouse and Human Atlas* (P. Treuting and S. Dintzis, eds.), pp. 253–84. Elsevier Inc., San Diego, CA.

Rubio, C. A. (1976). The exfoliating cervico-vaginal surface. II. Scanning electron microscopical studies during the estrous cycle in mice. *Anat Rec* **185**, 359–72.

Spencer, J. L., Waters, E. M., Milner, T. A., and McEwen, B. S. (2008). Estrous cycle regulates activation of hippocampal Akt, LIM kinase, and neurotrophin receptors in C57BL/6 mice. *Neurosci* **155**, 1106–19.

Spornitz, U. M., Socin, C. D., and Dravid, A. A. (1999). Estrous stage determination in rats by means of scanning electron microscopic images of uterine surface epithelium. *Anat Rec* **254**, 116–26.

Steyn, F. J., Wan, Y., Clarkson, J., Veldhuis, J. D., Herbison, A. E., and Chen, C. (2013). Development of a methodology for and assessment of pulsatile luteinizing hormone secretion in juvenile and adult male mice. *Endocrinol* **154**, 4939–45.

Tsonis, C. G., Carson, R. S., and Findlay, J. K. (1984). Relationships between aromatase activity, follicular fluid oestradiol-17 beta and testosterone concentrations, and diameter and atresia of individual ovine follicles. *J Reprod Fertil* **72**, 153–63.

Walmer, D. K., Wrona, M. A., Hughes, C. L., and Nelson, K. G. (1992). Lactoferrin expression in the mouse reproductive tract during the natural estrous cycle: Correlation with circulating estradiol and progesterone. *Endocrinol* **131**, 1458–66.

Yoshinaga, K., Hawkins, R. A., and Stocker, J. F. (1969). Estrogen secretion by the rat ovary in vivo during the estrous cycle and pregnancy. *Endocrinol* **85**, 103–12.

For reprints and permissions queries, please visit SAGE's Web site at http://www.sagepub.com/journalsPermissions.nav.

Downloaded from tpx.sagepub.com at COLORADO STATE UNIV LIBRARIES on April 9, 2014