

Nte A R
Gabriel-Job N

Tetanus with multiple wedge vertebral collapses: A case report in a 13 year old girl

DOI:<http://dx.doi.org/10.4314/njp.v40i2.17>

Accepted: 6th July 2012

Nte A R (✉)
Gabriel-Job N
Department of Paediatrics,
University of Port Harcourt Teaching
Hospital,
PMB 6173 Port Harcourt, Nigeria.
E-mail: alicernte@yahoo.com
Tel: +2348033410046

Abstract Data from the case records of a 13 year old Junior Secondary School Class two girl managed at the Department of Paediatrics of the University of Port Harcourt Teaching Hospital were extracted for presentation to highlight vertebral collapse as an uncommon complication of paediatric tetanus and the associated management challenges.

The girl presented with complaints of back pains-11 days, inability to open her mouth- 9 days, jerking of the body- 8 days and upper back swelling-6 days following bruises

from corporal punishment in her school. She was diagnosed to have tetanus with vertebral collapses of T3-T6. Tuberculosis and other causes of vertebral collapse were excluded. The tetanus was successfully treated but she left against medical advice and defaulted from follow-up for the management of the vertebral collapses. Poverty, ignorance and belief in traditional health care were major obstacles to her management.

Key words: Multiple wedge vertebral collapses in tetanus

Introduction

Tetanus occurs when spores of *C. tetani* gain access into tissues usually through puncture wounds or lacerations.^{1,2} In developing countries, post-neonatal tetanus is associated with traumatic injury, often a penetrating wound inflicted by dirty objects like nails, glass, unsterilized injection needle, broom sticks, circumcision and scarification wounds. The injury itself is often trivial and in 20% of cases, there may be no wound. The spores however germinate in the wound and release tetanospasmin which is taken up into motor nerve endings and transported into the central nervous system where it binds to gangliosides.³ There, it blocks the release of neurotransmitters from the presynaptic inhibitory neurons resulting in reflex irritability and autonomic hyperactivity- cardinal features of tetanus. Reflex spasms develop within one to four days of the first symptoms. Spasms may be precipitated by minimal stimuli such as noise, light, or touch and last from seconds to minutes. They are painful and dangerous, and may cause laryngeal spasms, apnoea, rhabdomyolysis or fractures.⁴ Vertebral fracture from tetanus is often undiagnosed and can be mistaken for spinal tuberculosis hence the need for a high index of suspicion. Although vertebral fracture complicating tetanus has been reported among adolescents and adults in Nigeria, none has been seen among the several cases of tetanus managed in this unit for about thirty years. The diagnosis of tetanus with multiple vertebral collapses and the management challenges necessitated the current case report.

Case Report

SA, aged 13 years, presented with complaints of back pains-11days, inability to open the mouth- nine days, jerking of the body- eight days, and upper back swelling – six days. She sustained bruises following corporal punishment in school. The parents massaged the wounds with warm water and applied gentian violet. Subsequently, she developed severe and sharp pains localized at the upper back and aggravated by movements but relieved by rest and analgesics. Two days after she became unable to open her mouth and her teeth clenched together. Subsequently she developed generalized jerking of the body provoked by sound, light and touch. She remained conscious and continent of faeces and urine. Although stiff, she could walk with support. With worsening of symptoms, she developed a swelling at her upper back which progressively increased in size. Home remedies for the swelling included massaging with hot water and the application of "mentholatum"; analgesics and ampiclox capsules. Failure to get relief for the symptoms made the parents take her to a prayer house where the back swelling was incised in several sites and olive oil and other concoctions applied. With further deterioration in her state, she was brought to the Teaching Hospital. She was unimmunized, had no positive history of contact with a case of tuberculosis and no significant past medical and surgical histories.

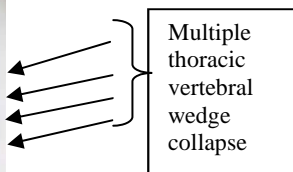
Significant findings on examination were an ill looking, mildly pale teenager with several spontaneous and provoked spasms, *trismus*, *risus sardonicus*, *opisthotonus*

and generalized rigidity. She had a firm, tender swelling at the upper third of the back with desquamation and excoriation of the overlying skin in some parts; and multiple scarification marks. Additionally, she had linear ulcers on the right arm and left lateral chest wall and an excoriation of the right popliteal area all attributed to the corporal punishment. She was conscious, well oriented to time, person and place and had no obvious cranial/peripheral nerve deficits. She had marked neck stiffness, generalised hypertonia but no sensory losses.

The initial diagnosis was tetanus co-existing with tuberculosis of the spine to exclude multiple vertebral fractures complicating the tetanus. Her full blood count showed a total white cell count of $11.5 \times 10^9 / l$; neutrophils- 80% and lymphocytes- 20%; packed cell volume - 33% and Erythrocyte sedimentation rate- 23mm/hour (Western Green Method). Mantoux test and retroviral screening were negative. The urinalysis and electrolyte, urea and creatinine assays were normal. X-rays of the cervical spine were normal except for the straightening of the vertebrae. Thoracic spine radiographs showed kyphoscoliosis, anterior wedge collapses of T3-T6 vertebral bodies with reduction of their intervening disc spaces (Fig. 1). The other vertebrae, paraspinal soft tissues and chest were normal on X-rays and did not suggest tuberculosis.

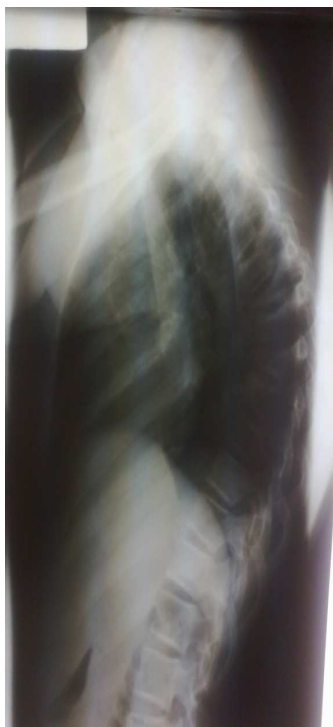

Fig 1 Radiograph of the thoracic vertebrae showing wedge collapse affecting T3 to T6



Multiple thoracic vertebral wedge collapse

Pending the receipt of the results of the investigations, she was commenced on rifampicin, pyrazinamide, isoniazid and streptomycin for tuberculosis but these were discontinued when the results were reviewed and tuberculosis excluded. She was managed with the Department's protocol for tetanus which comprised of antitetanus serum (after a test dose), crystalline penicillin, metronidazole, chropromazine, diazepam, phenobarbitone and methocarbamol (*Robaxin*-a central muscle relaxant used to reduce skeletal muscle spasms). Ortho-

paedic surgeons reviewed the child, agreed with the diagnosis and scheduled her for surgery for the repair of the vertebral collapses after her recovery from the tetanus. Follow up visits were made to the school authority to intimate it with the child's case and the need to institute measures to prevent recurrence of such abuses. The parents however opted for a peaceful settlement with the school/teacher. When her spasms stopped and she could walk unaided, she was taken home against medical advice. In spite of several home visits, she has not been brought for follow up because the parents want her managed locally.

Discussion

Lehndroff in 1907 first described spinal lesions from tetanus.^{1,2} Although the prevalence of the fractures is variable with males being more affected, some have reported them in about half the cases while Veronesi found vertebral changes in 87% of a group of tetanus patients aged 1-20 years like our patient⁵⁻⁷. Probably because most of the cases of tetanus in our setting follow injuries in the limbs, vertebral fractures have not been reported as complications compared to the situation in other centres in Nigeria.^{7,8}

The pathogenesis of the vertebral fractures is unknown but several factors have been suggested such as the predominant spasms of the flexor group of muscles over the extensors leading to a prosthonus with an increase in the thoracic kyphosis and fracture. Additional factors include the over acceleration of endochondral ossification during the periods of most active body growth, causing ossification in the metaphyses of the vertebral bodies to lag behind the predominant proliferation of columnar cartilage, vascular factors and metabolic changes.^{1,7,9} Furthermore, with the physiological kyphosis of the thoracic spine in juveniles, sustained muscular contraction and tetanic spasms combine to produce fractures of these spongy, relatively delicate bones with the apex of the thoracic kyphosis usually acting as the fulcrum. The presentation varies from asymptomatic to back pains and swelling as in our patient.⁹ There are usually no neurologic deficits as in our patient. As in this patient, the multiple consecutive vertebral fractures usually involve the fourth to the eighth thoracic (T4-T8) vertebrae with fractures of T5 and T6 being the most frequent and severe. It is not unusual to have involvements as high as T3 and as low as T9. The cervical and lumbar vertebrae are almost never affected.⁷

Although tuberculosis of the spine is one of the commonest causes of vertebral wedge collapse in our environment, and was initially considered in this patient, the acute onset of the child's illness as opposed to the insidious onset in spinal tuberculosis with slow disease progression and the other features excluded tuberculosis. The usual presentation in tuberculosis consists of pain overlying the affected vertebrae, low-grade fever, chills,

weight loss, and nonspecific constitutional symptoms of varying duration. Paraplegia could be the first sign of spinal disease in tuberculosis. Varying degrees of weakness, nerve-root compression and sensory involvement can occur. Weight loss has been recorded in 58% of patients¹⁰ and 90% to 100% of patients had back pain.¹¹ Neurological involvement varied in different studies from 32% to 76% with notable differences in severity.¹² None of these features were found in our patient. Although a positive test with the Purified Protein Derivative by Mantoux method was reported in 62-95% of cases of vertebral tuberculosis,¹ a negative test should not be considered as completely excluding tuberculosis infection. Furthermore, although, leukocytosis and elevated Erythrocyte Sedimentation Rate (ESR) of over 100 mm/h¹¹(Westergreen Method) are suggestive, our patient did not have these features. Radiographic changes associated with Pott's disease present relatively late and plain radiographs describe changes consistent with TB spine in 91-99% of cases.¹⁰⁻¹² Radiographs may reveal advanced lesions with vertebral osteolysis and disc space narrowing affecting more commonly the lower thoracic vertebrae than the lumbar and cervical vertebrae.

There may be single or multiple vertebral involvement and skip lesions can occur. Paraspinal abscesses responsible for soft tissue swelling may be visible on plain radiograph. The presence of calcifications within the abscess is virtually diagnostic of spinal TB. None of these features was present in this patient.

Conclusion

This 13 year old girl presented with active tetanus complicated by multiple wedge collapses of T3-T6. She responded to the regimen for tetanus but defaulted from treatment for the vertebral fractures. Poverty, ignorance and resort to local treatment remain barriers to successful treatment of children.

Conflict of interest: None

Funding: None

References

- O. Theodore Roberg J.R. Spinal Deformity Following Tetanus and its relation to juvenile kyphosis. *Journal of Bone and Joint Surgery*, 1937; 19: 603-629.
- Bande E.O, Akinyanju O.O, Bojuwoye B .J. An Analysis of Tetanus Deaths in Lagos. *J. Natl Med. Assoc.* 1991; 1: 55 -58.
- Bleck TP. Pharmacology of tetanus. *Clin Neuropharmacol* 1986; 9:103-120
- Alfery DD, Rauscher A. Tetanus: a review. *Crit Care Med* 1979; 7:176-181
- Davis P.R, Rowland H.A: Vertebral Fractures in West Africans Suffering from tetanus. A Clinical and Osteological Study. *J Bone Joint Surg.* 1965; 47(1): 61-71
- Cornelius C. Compression Fractures of the thoracic vertebrae in patients with tetanus. *JAMA.* 1959; 170 (4): 455 -657
- Veronesi R: Clinical Observation on 712 cases of Tetanus subjected to four different Methods of Treatment: 18.2% Mortality rate under New Method of Treatment. *Am J.M.Sc.* 1956; 232:629-647.
- Yaguo Ide L.E, Nte AR. Post-Neonatal Tetanus: An apparently neglected disease. *Highland Med Res J;* 2011; 9/10(1-2): 24-29
- Perova L. B. Case of Fracture of Spine in Tetanus. *Klin Med.* 1957; 35: 153-155.
- Pertuiset E, Johann B, Liote F. Spinal tuberculosis in adults. A study of 103 cases in a developed country, 1980-1994. *Medicine* 1999; 78: 309-320.
- Azzam NI, Tammawy M. Tuberculous spondylitis in adults: diagnosis and treatment. *Br J Neurosurg* 1988; 2: 85-91.
- Perronne C, Saba J, Behloul Z. Pyogenic and tuberculosis spondylodiskitis (vertebral osteomyelitis) in 80 adult patients. *Clin Infect Dis* 1994; 19: 746-750.